

# Lesion Localization in Neurologic Disease

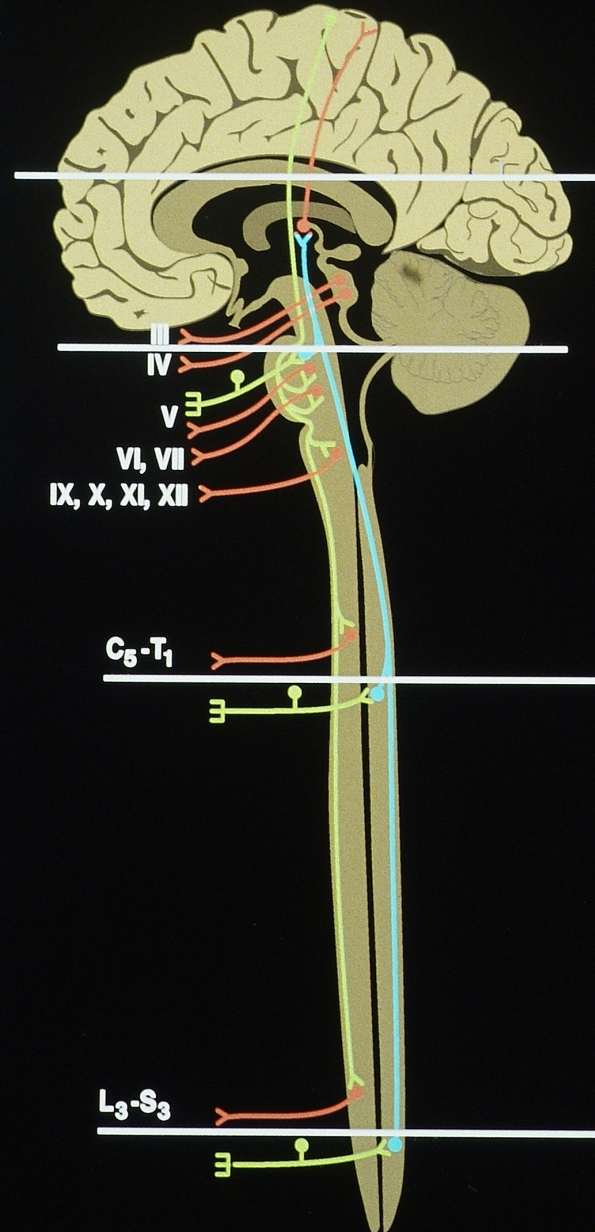
## Neurological Exam

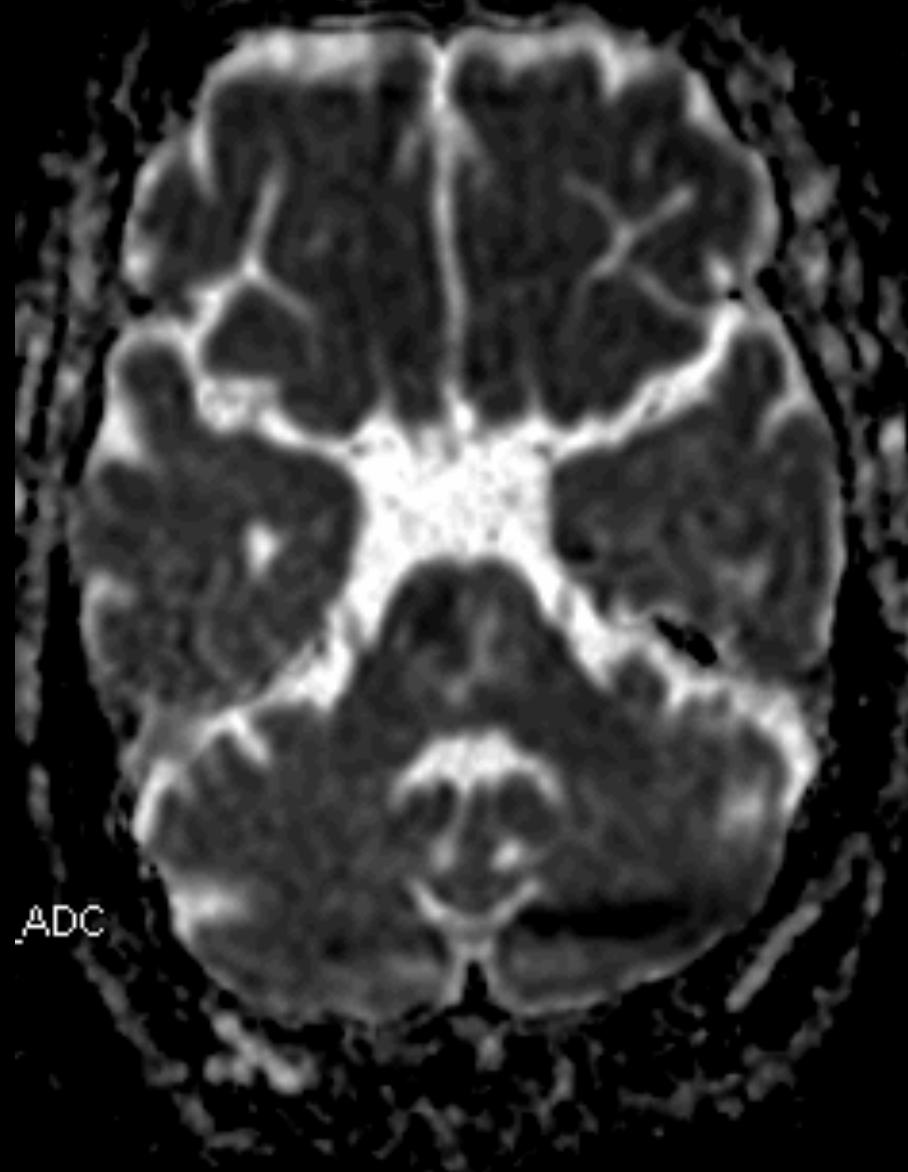
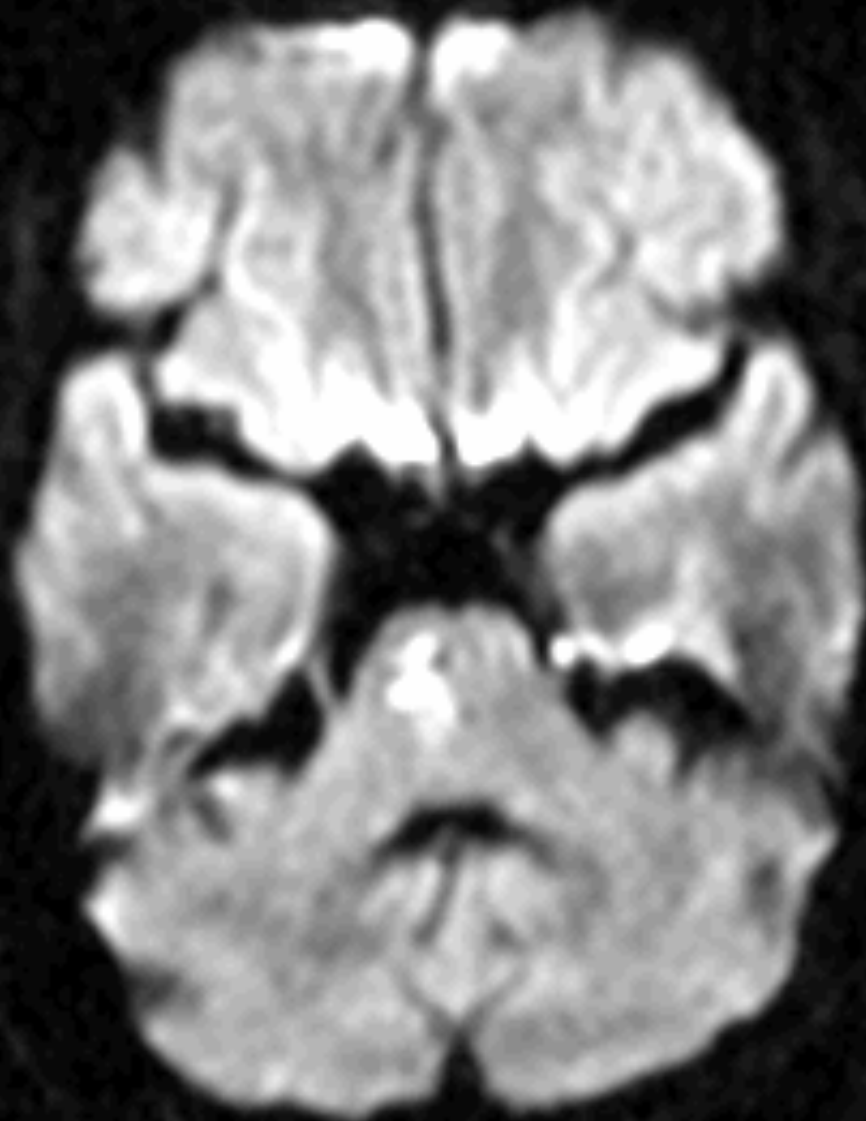
### Motor and Sensory Exams

Mental Status Exam

Cranial Nerve and Cerebellar Exams

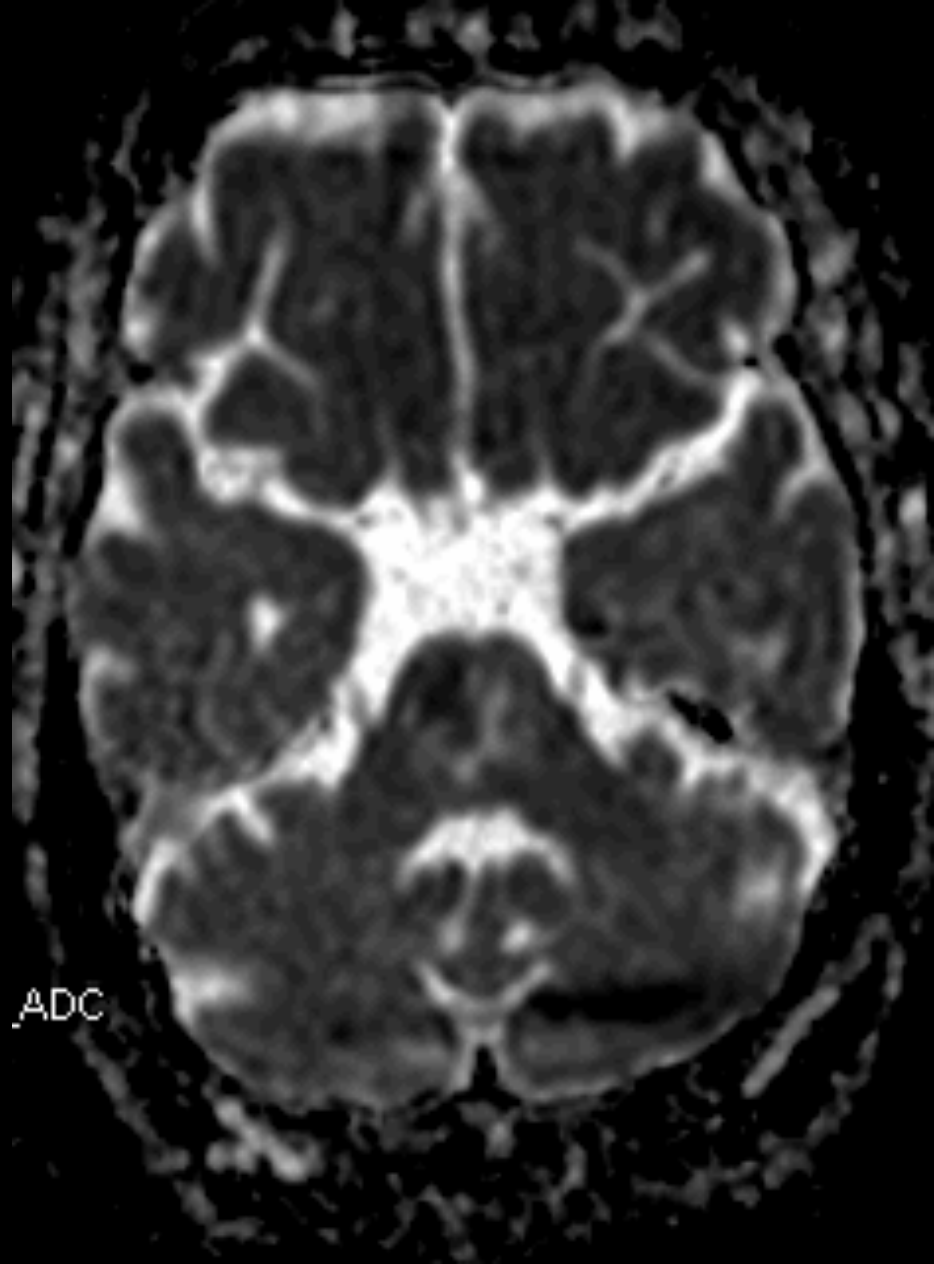
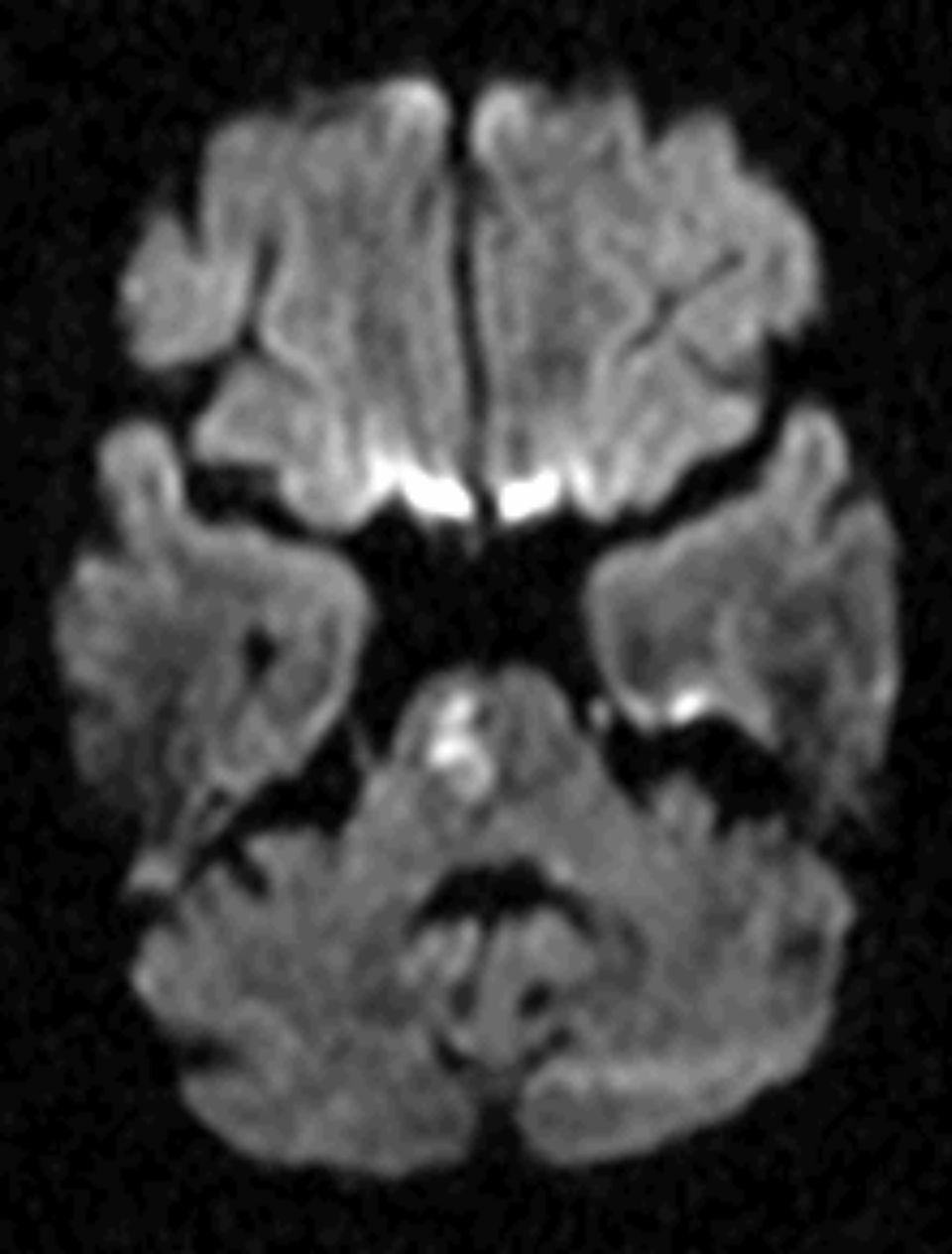
Reflexes





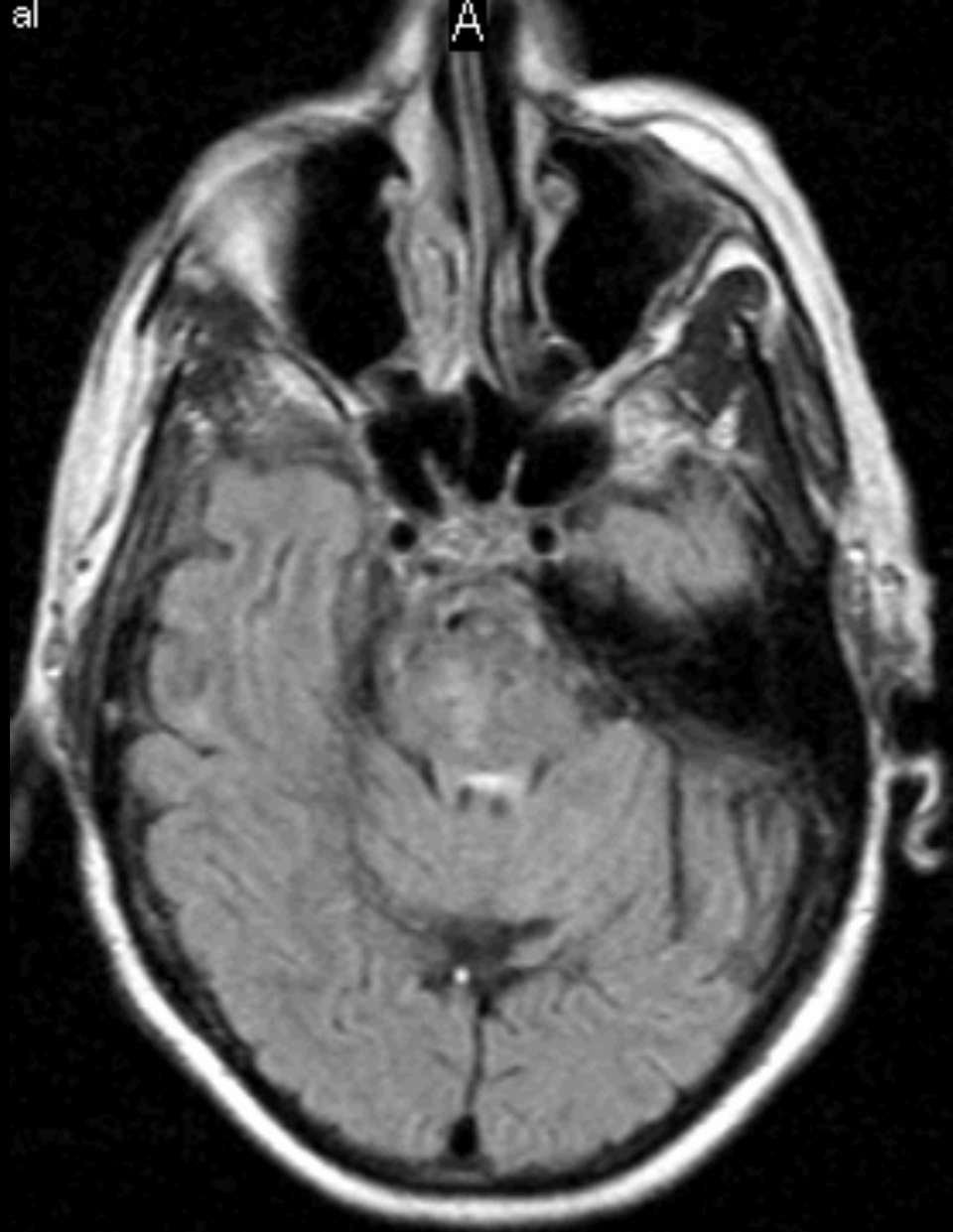
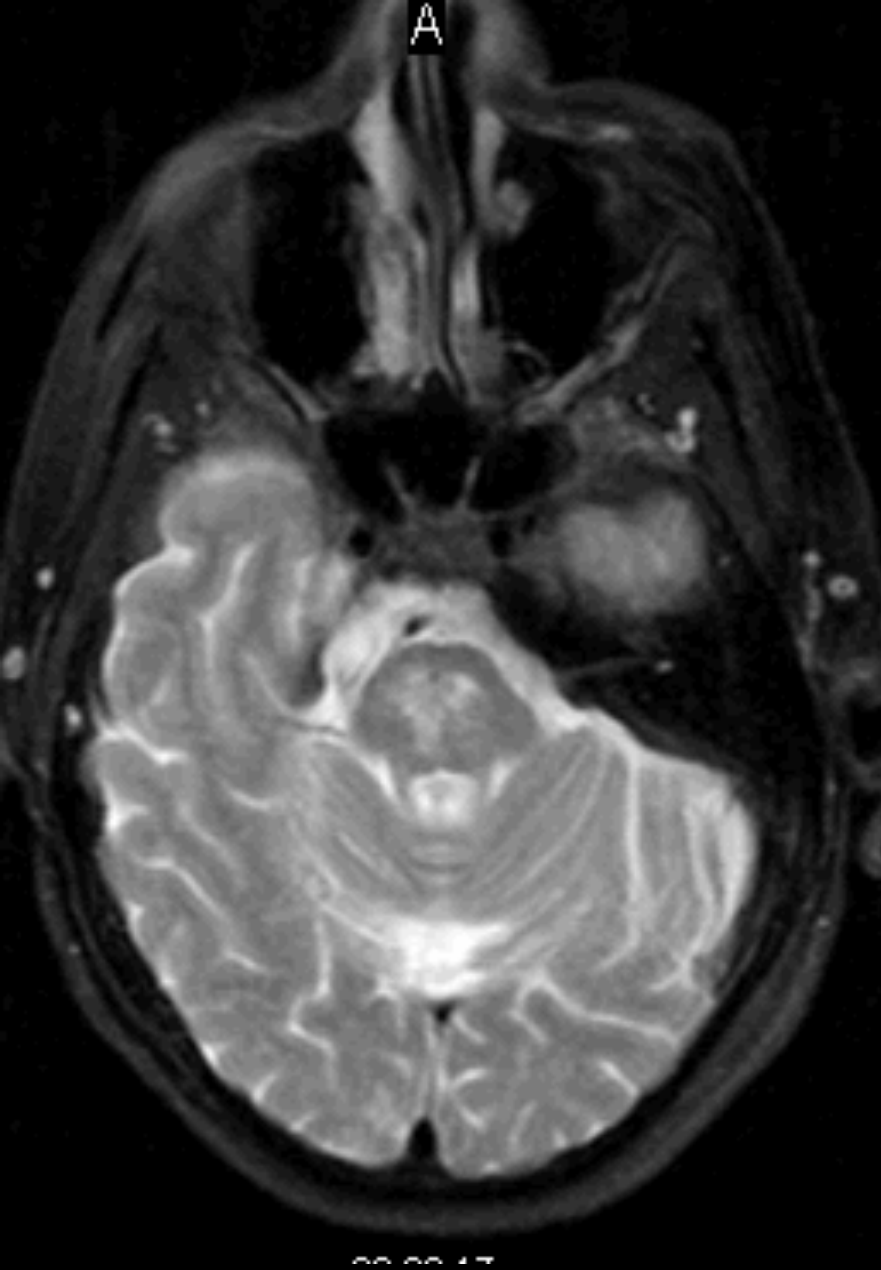
Horizontal DWI [left] & ADC [right] MRI Scan

6/2/06



Horizontal DWI [left] & ADC [right] MRI Scan

6/2/06



Horizontal T2W [left] & FLAIR [right] MRI Scan

6/2/06







