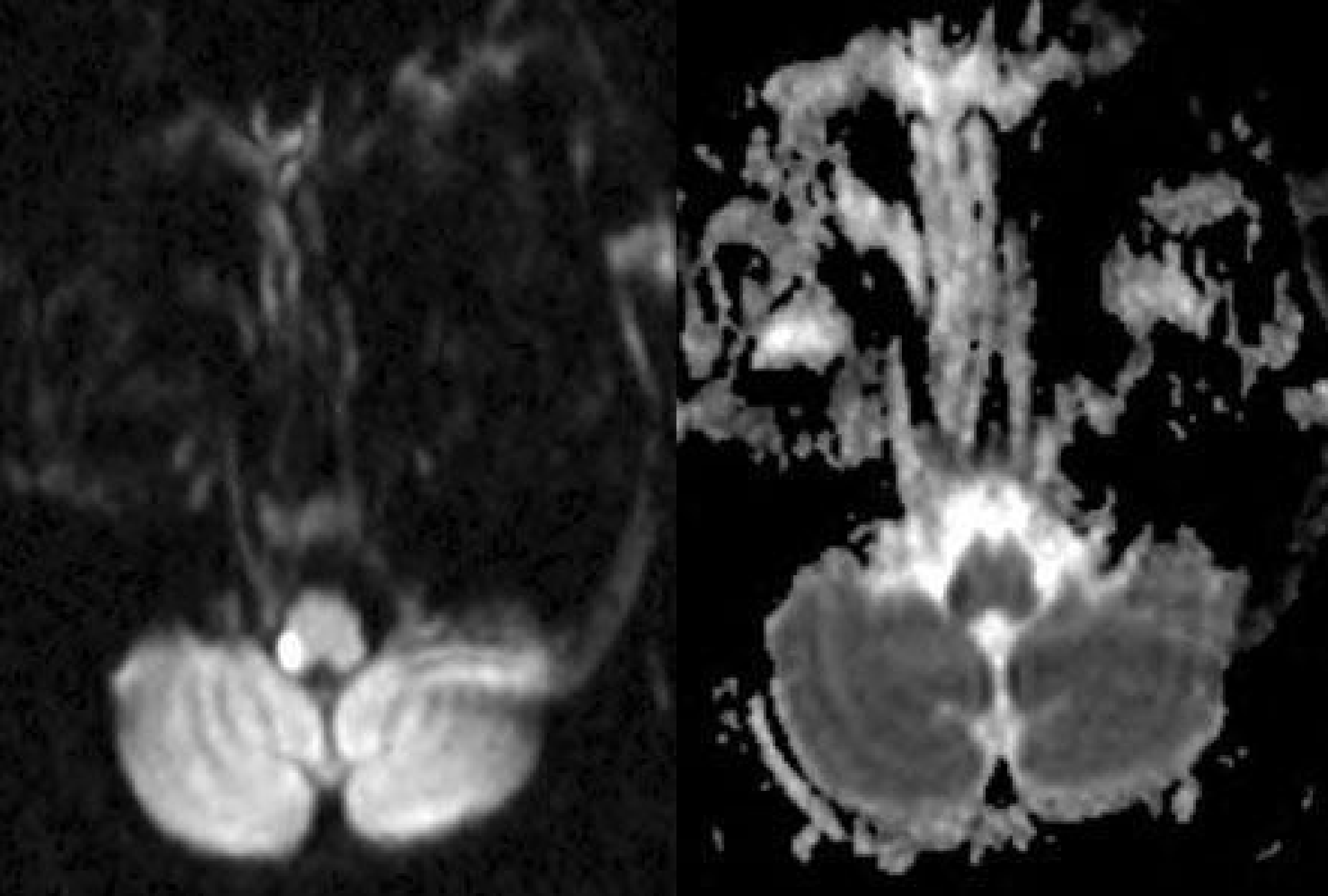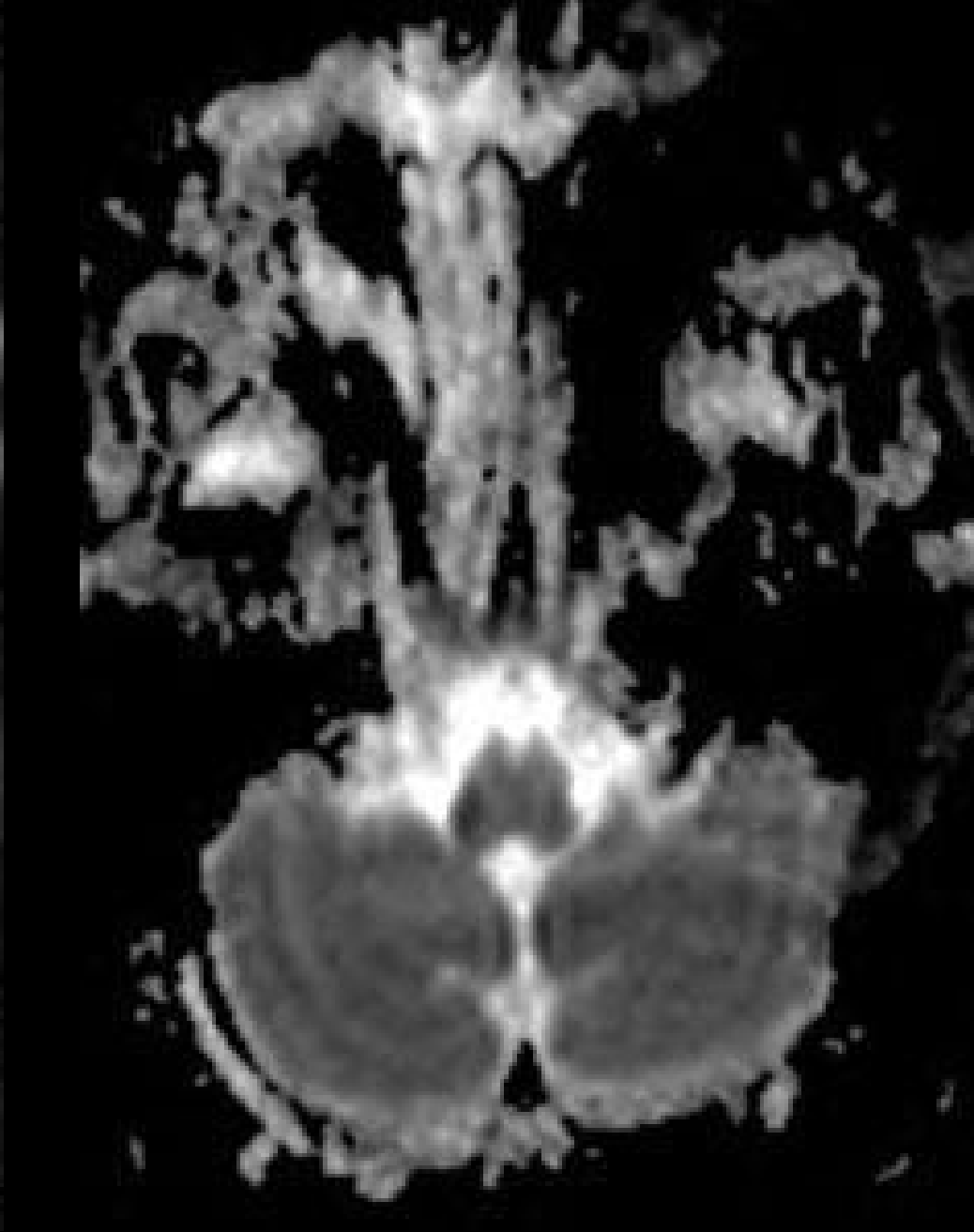
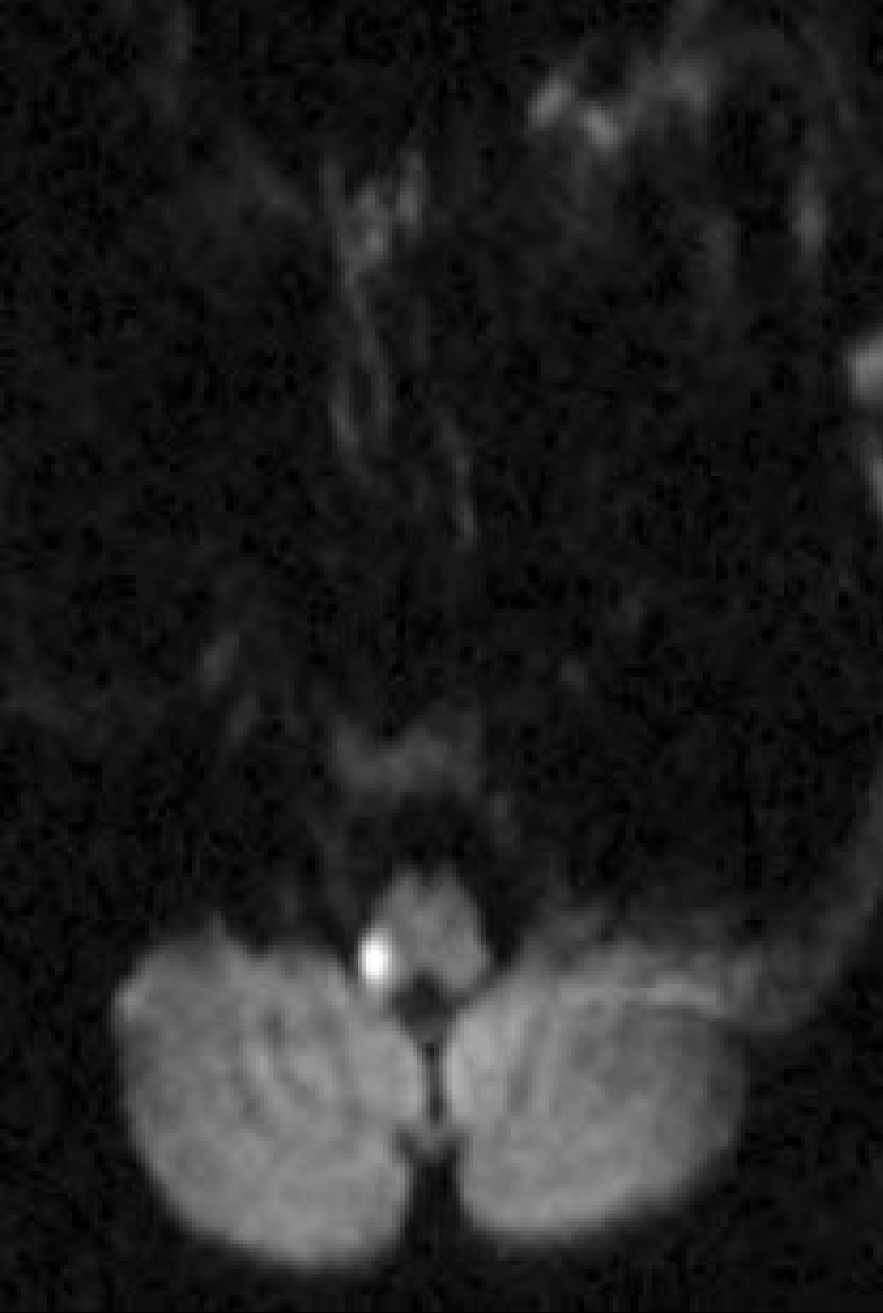
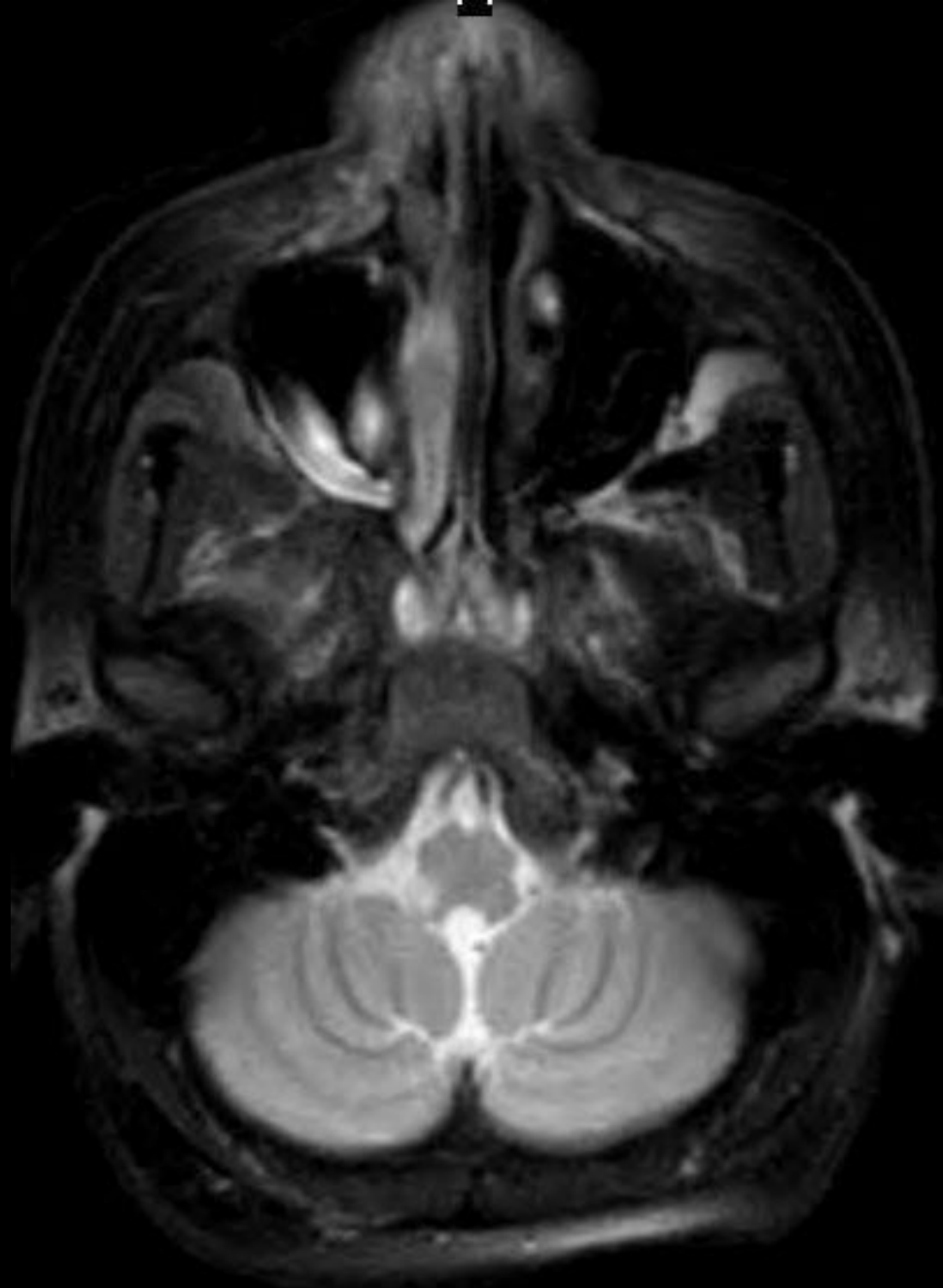


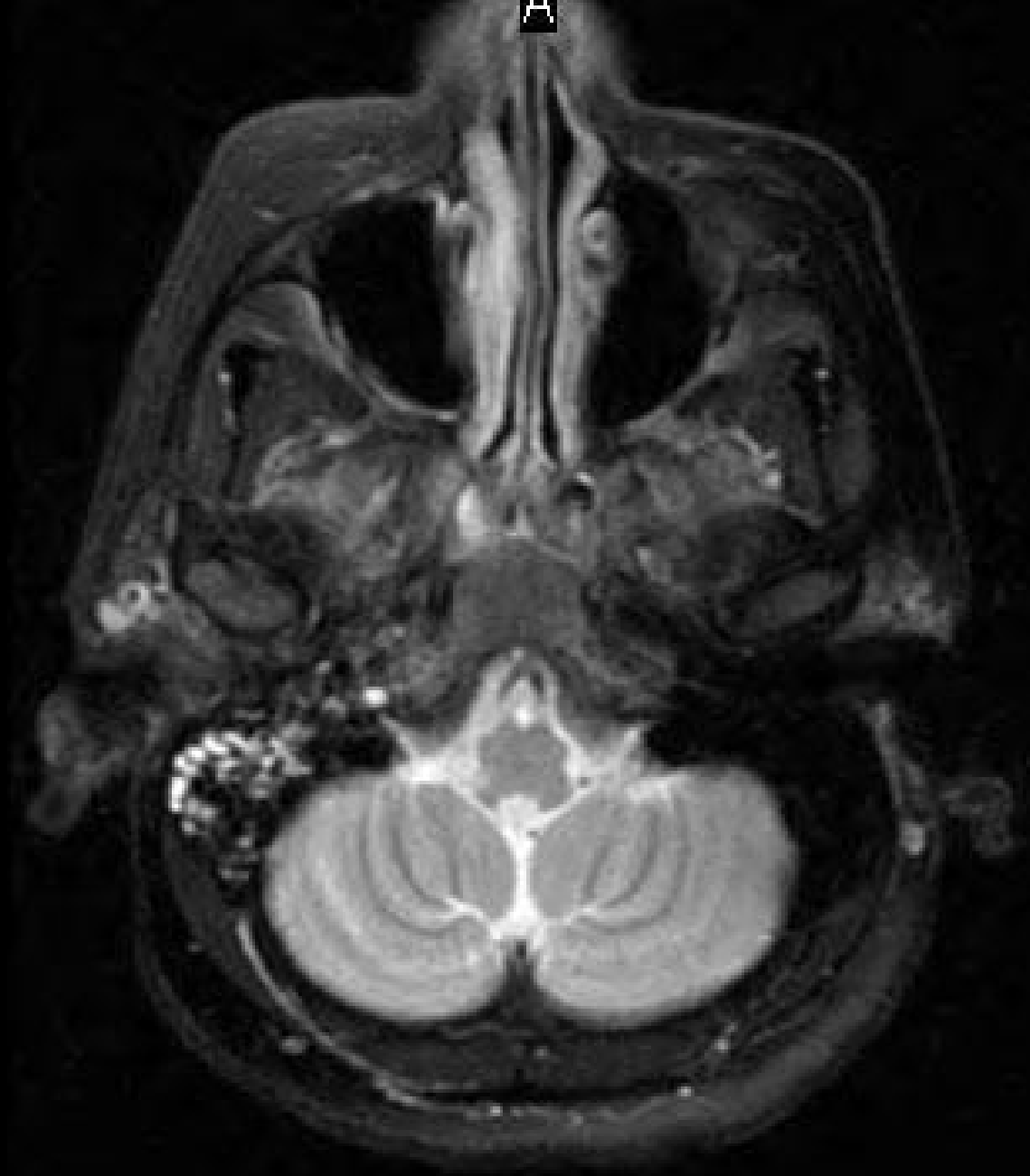Horizontal DWI [left] & ADC [right] MRI Scan



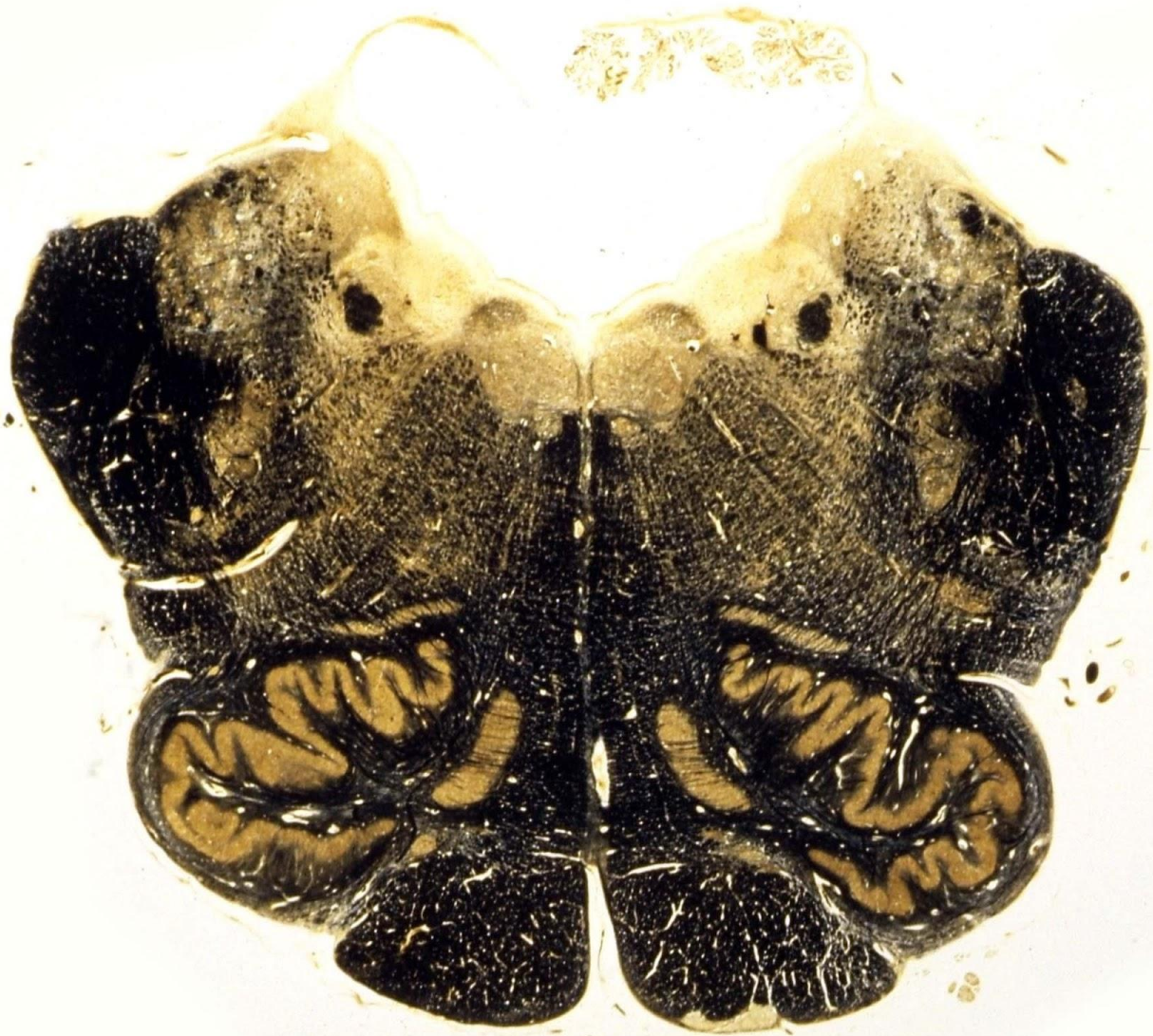Horizontal DWI [left] & ADC [right] MRI Scan

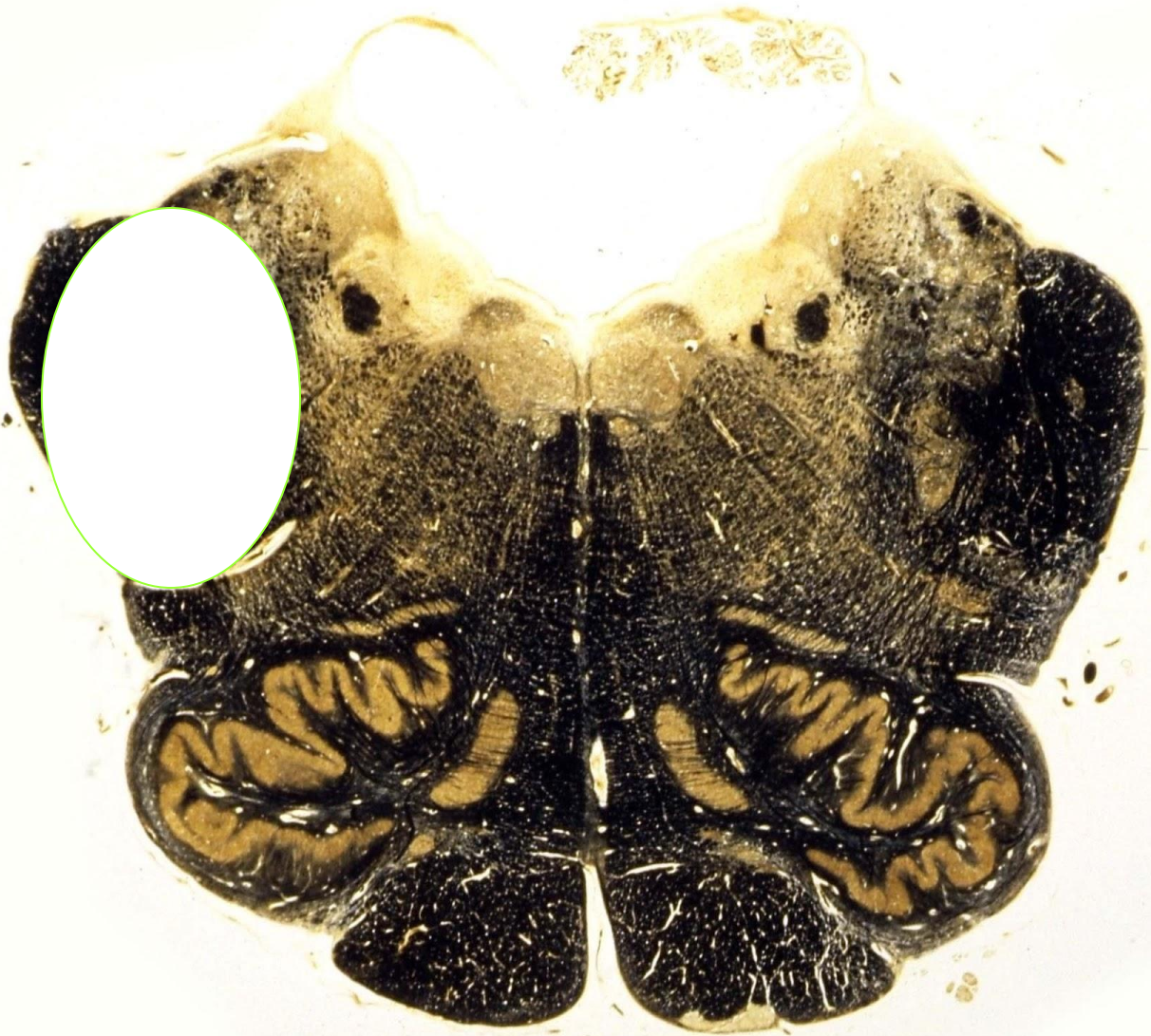


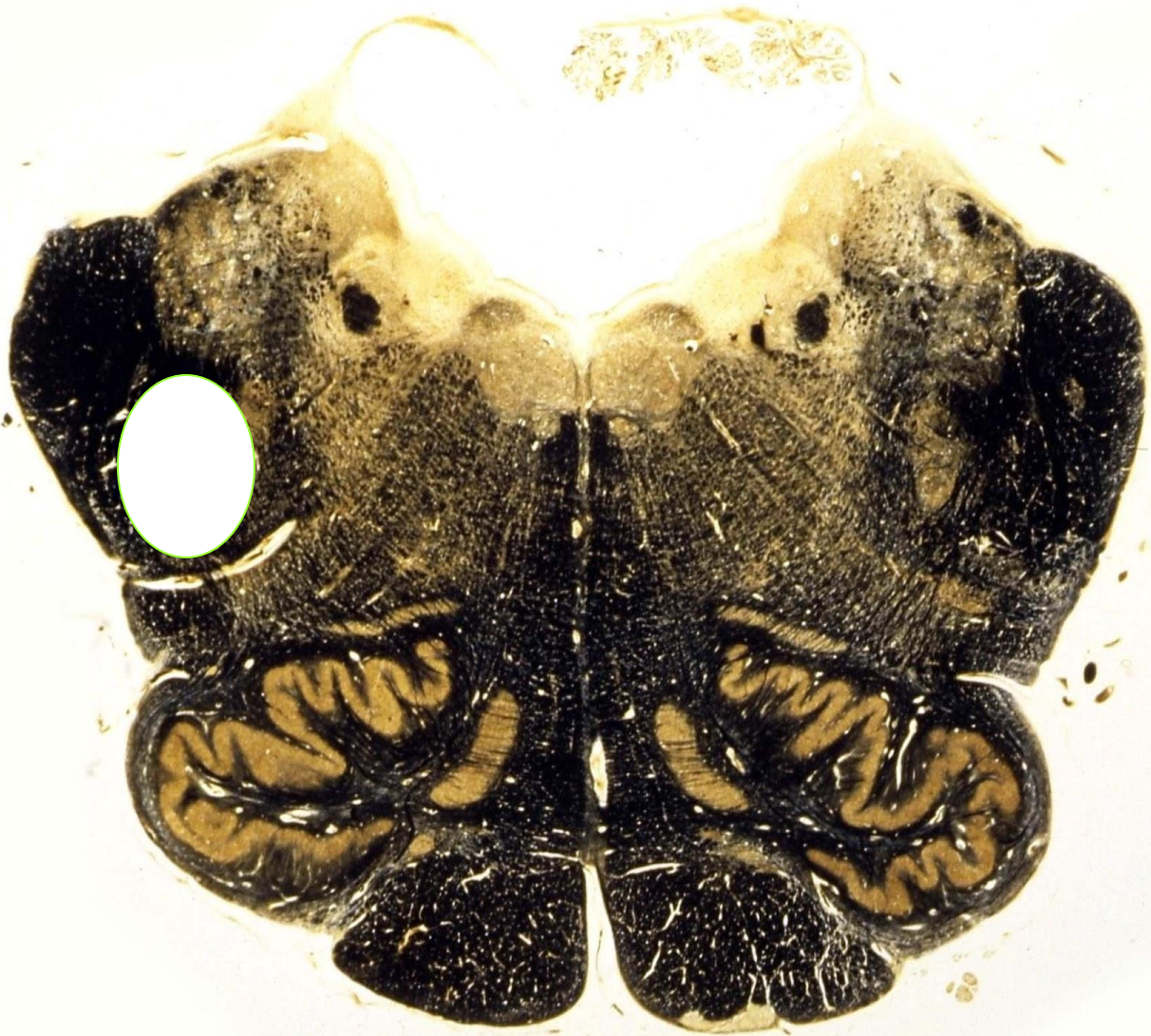Horizontal T2W MRI

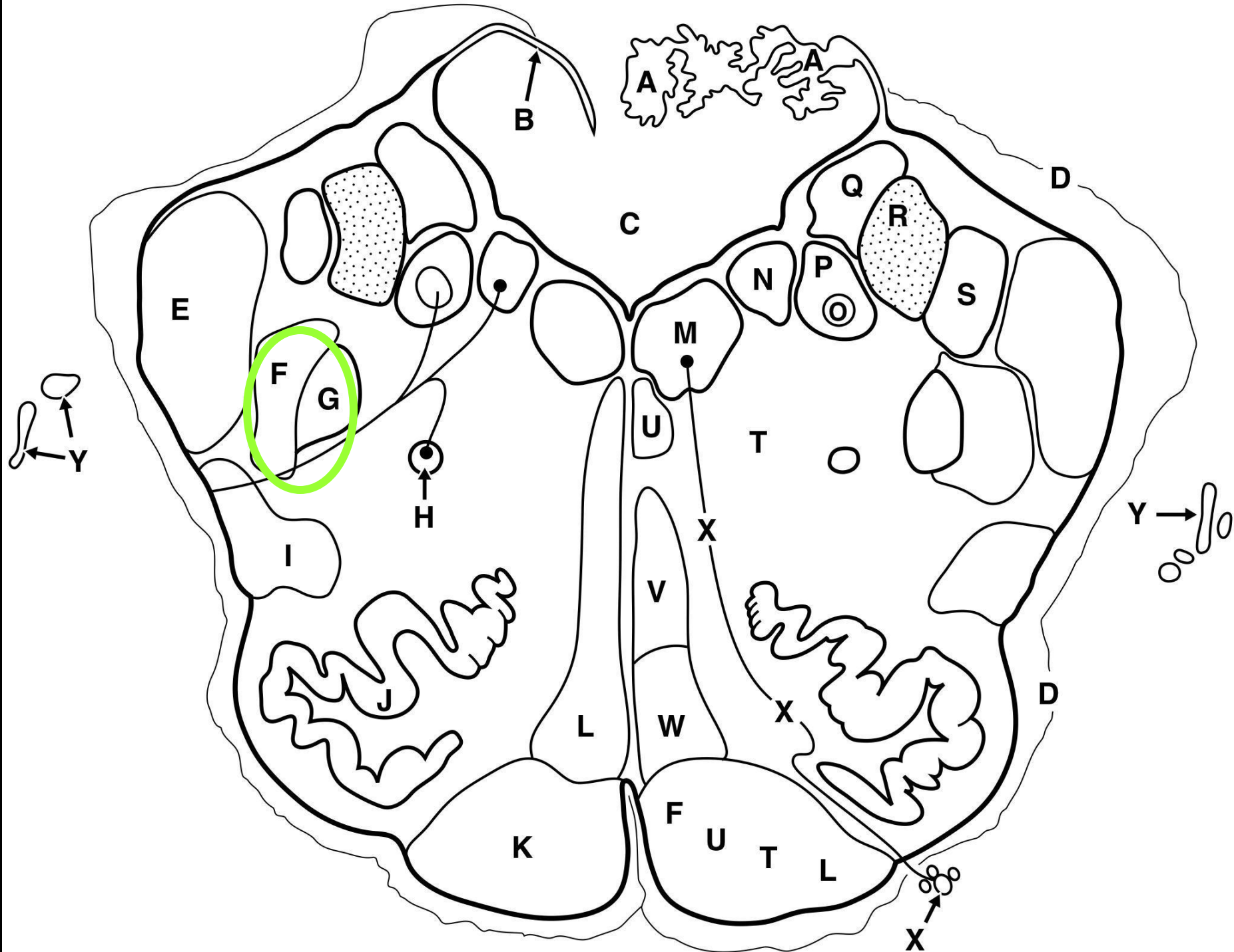


Horizontal T2W MRI


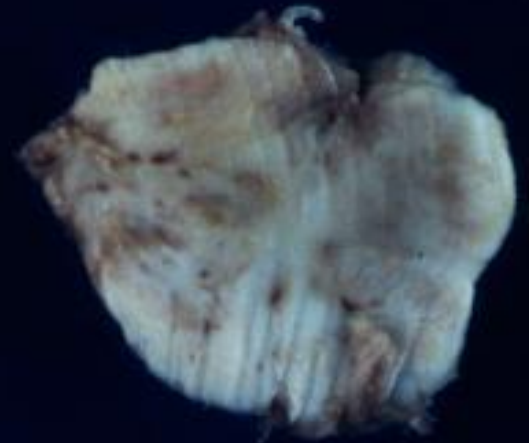
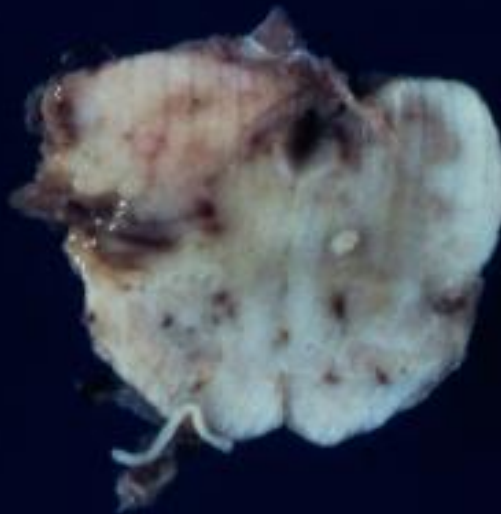
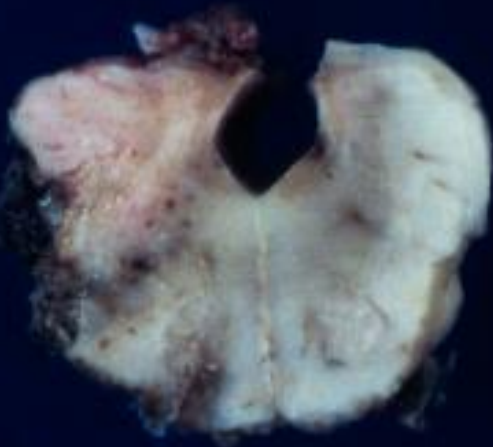




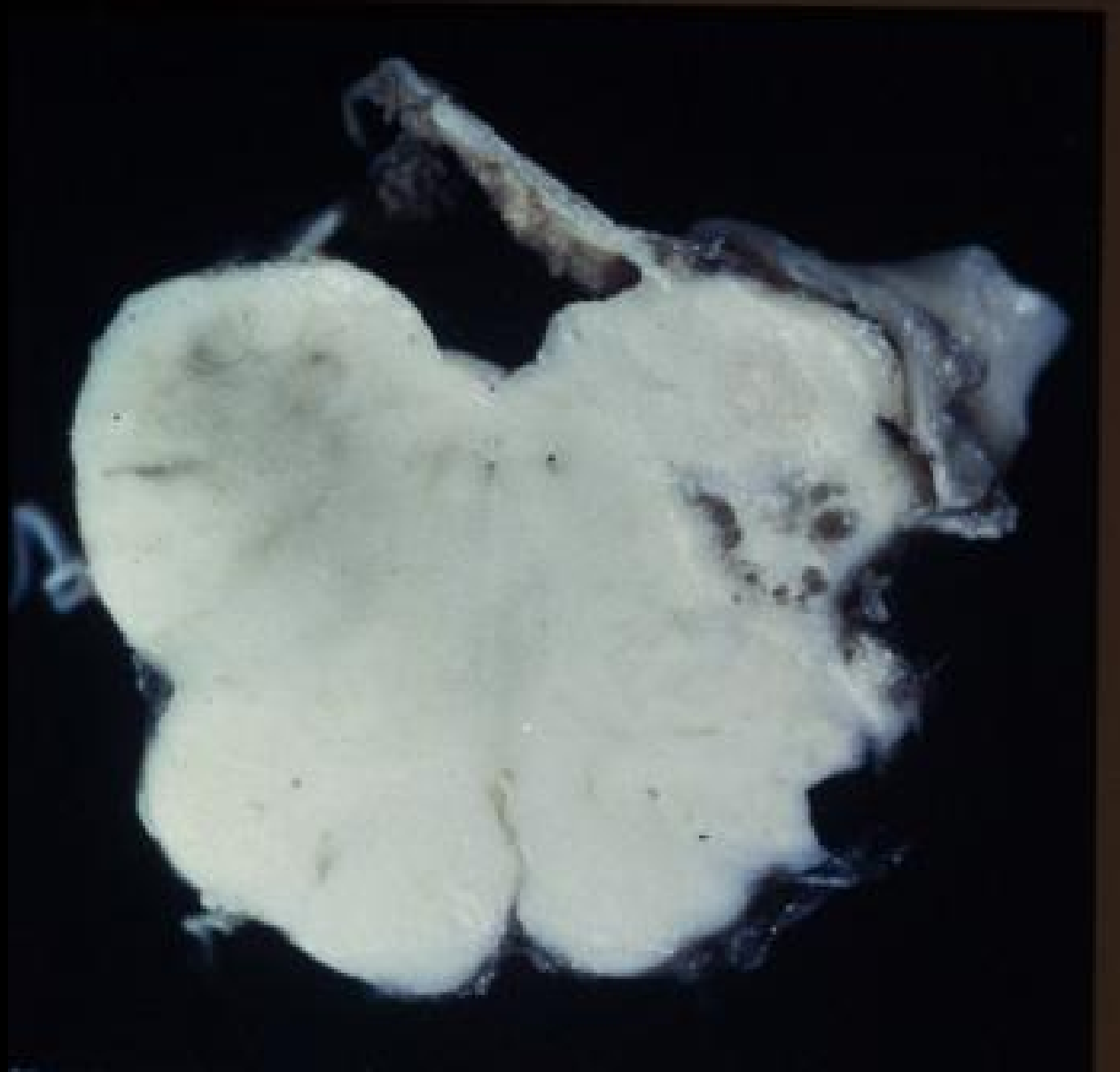








Acute Lateral Medullary Syndrome Infarct



Old Lateral Medullary Syndrome Infarct