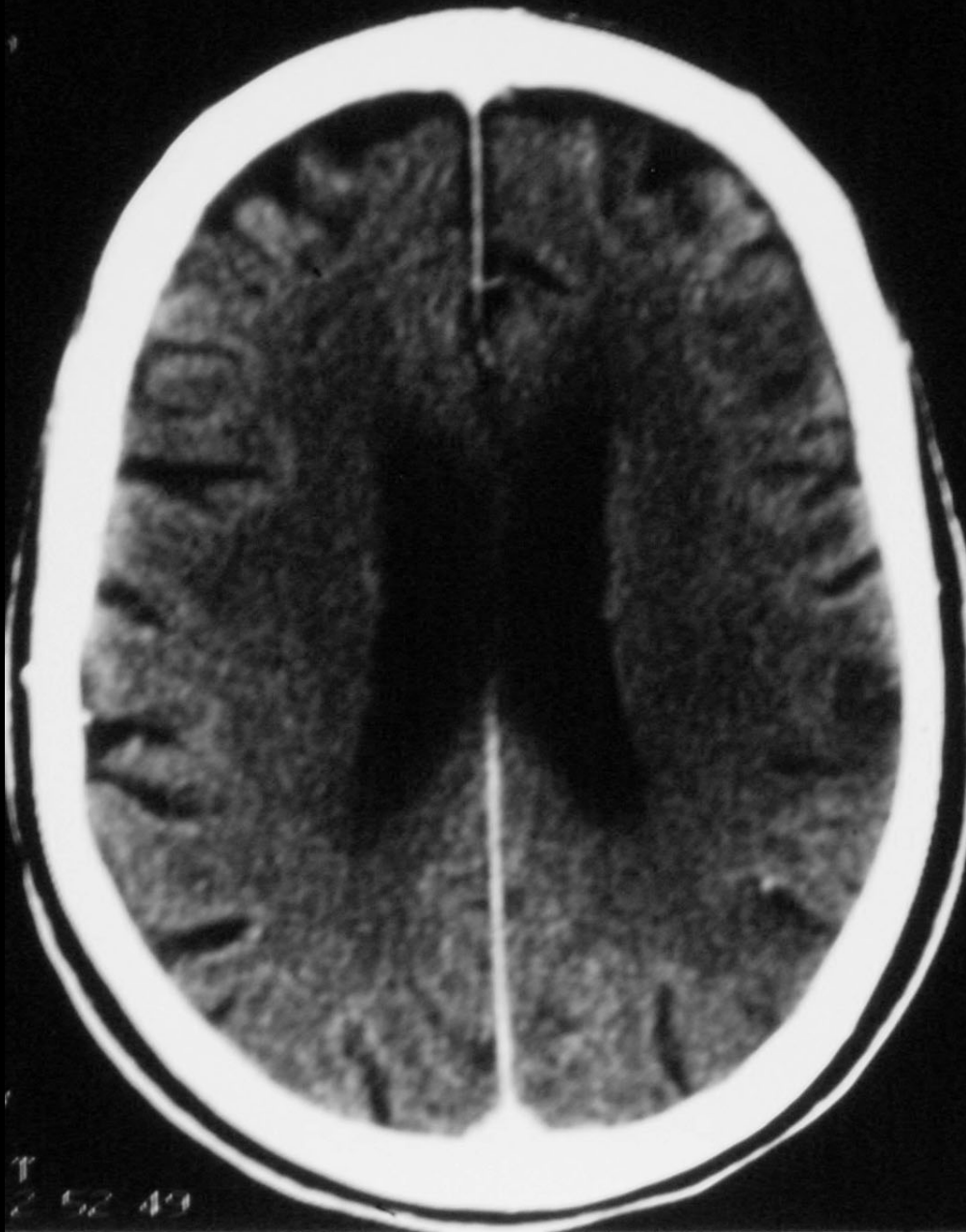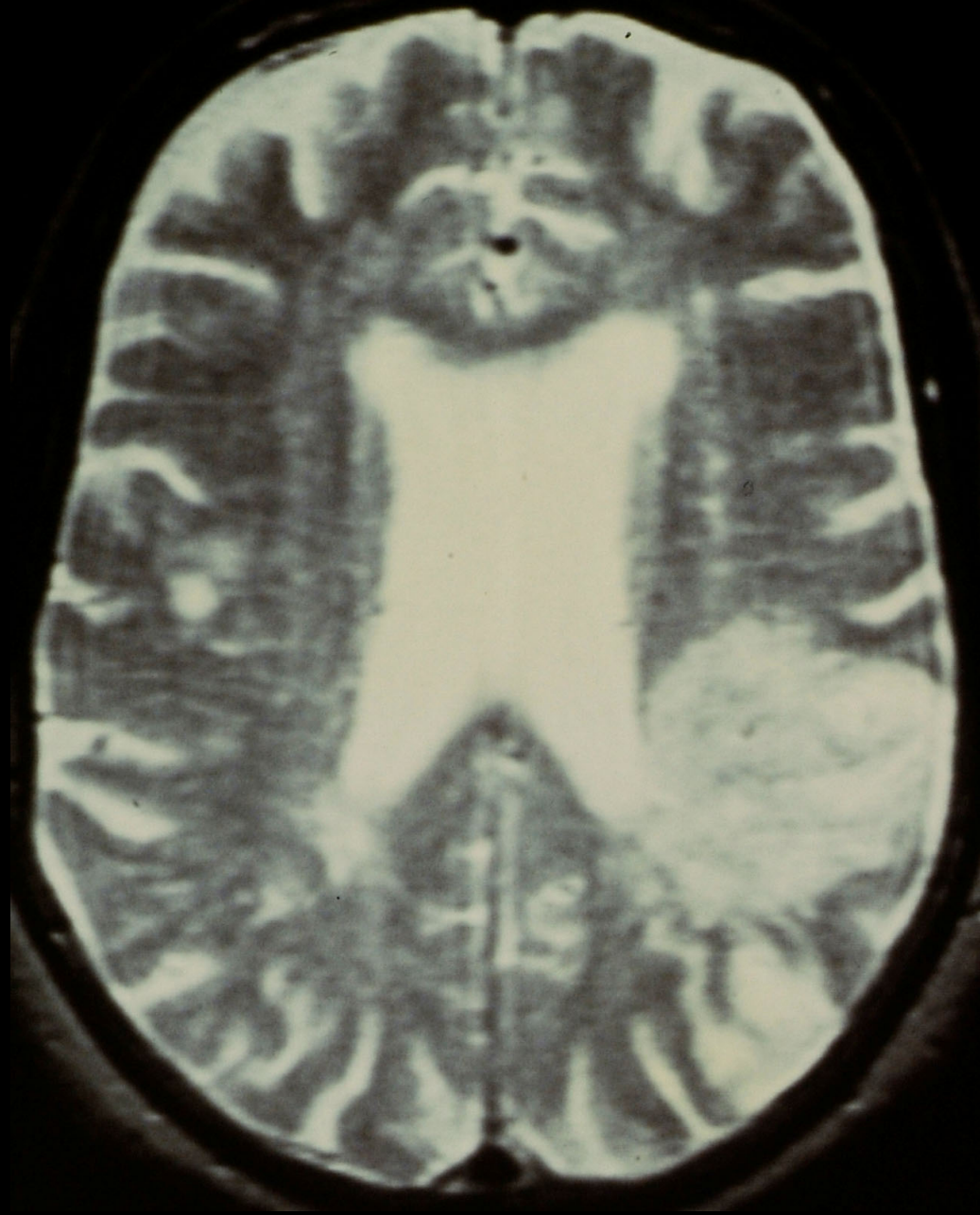


Right

Left

CT Scan without Contrast

11/29/87



Right

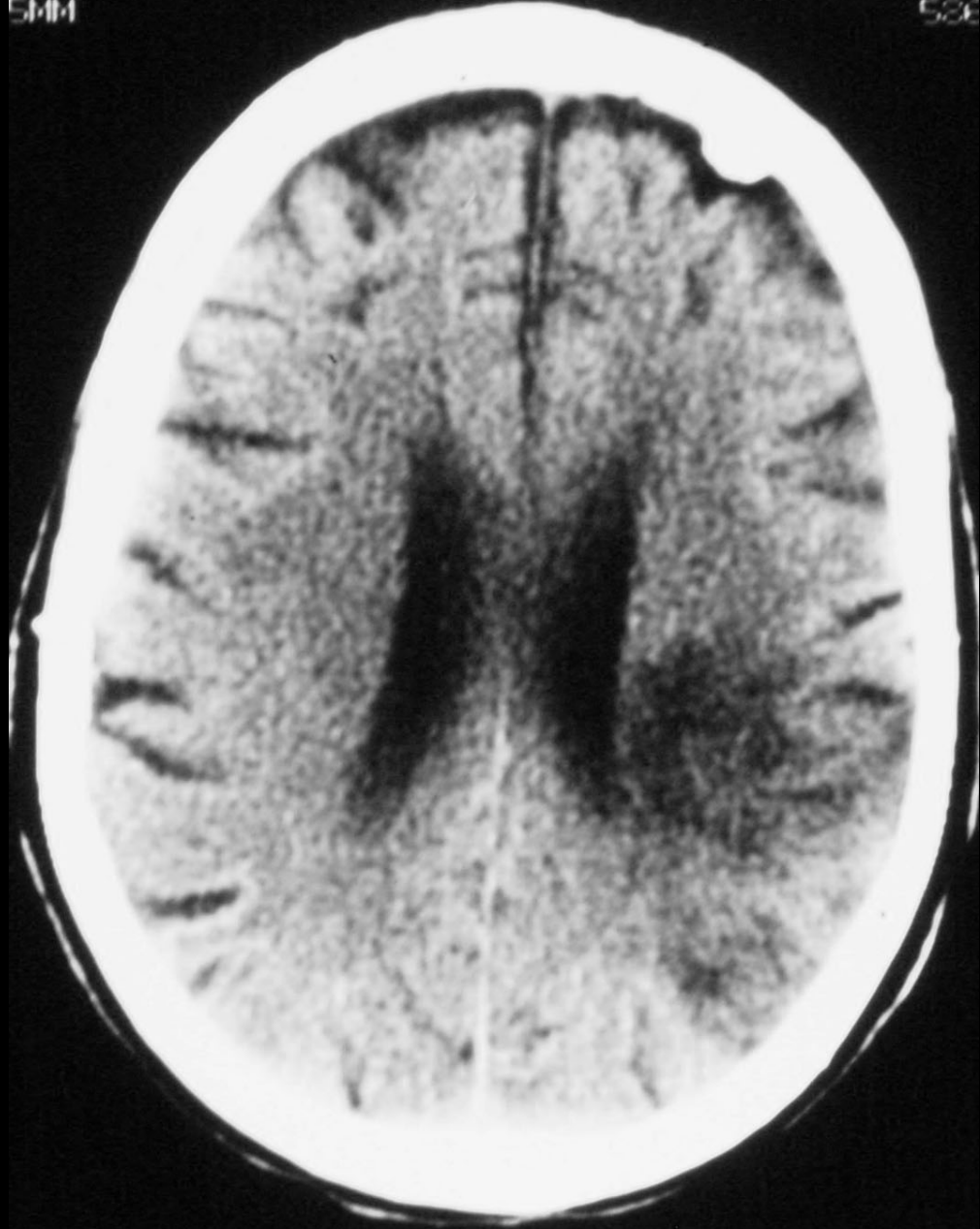
Left

Horizontal T2W MRI Scan

11/30/87

511

538



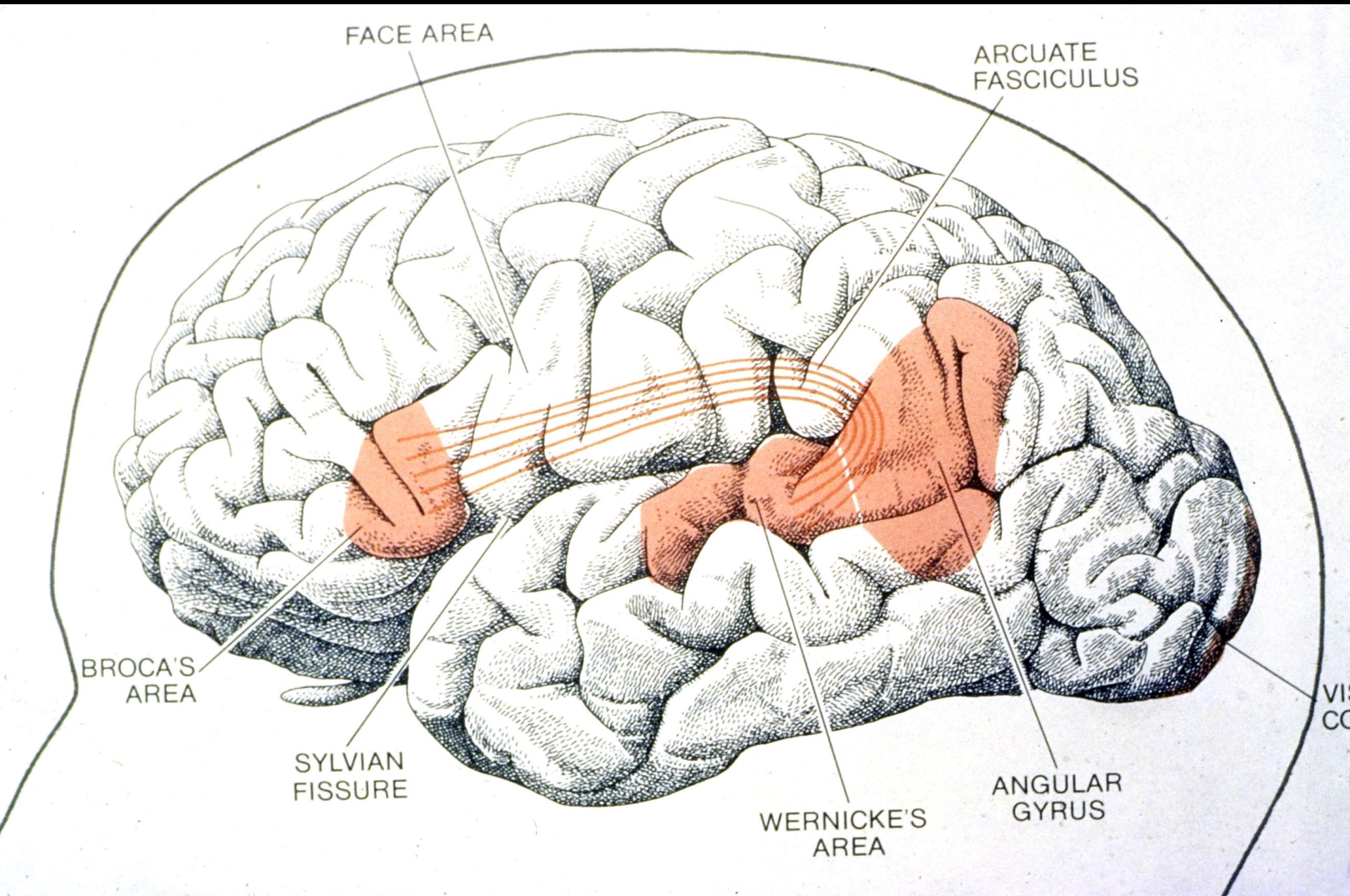
Right

Left

CT Scan without Contrast

12/6/87





FACE AREA

ARCUATE FASCICULUS

BROCA'S AREA

SYLVIAN FISSURE

WERNICKE'S AREA

ANGULAR GYRUS

VI  
CO

# Diagnosis of Aphasia

