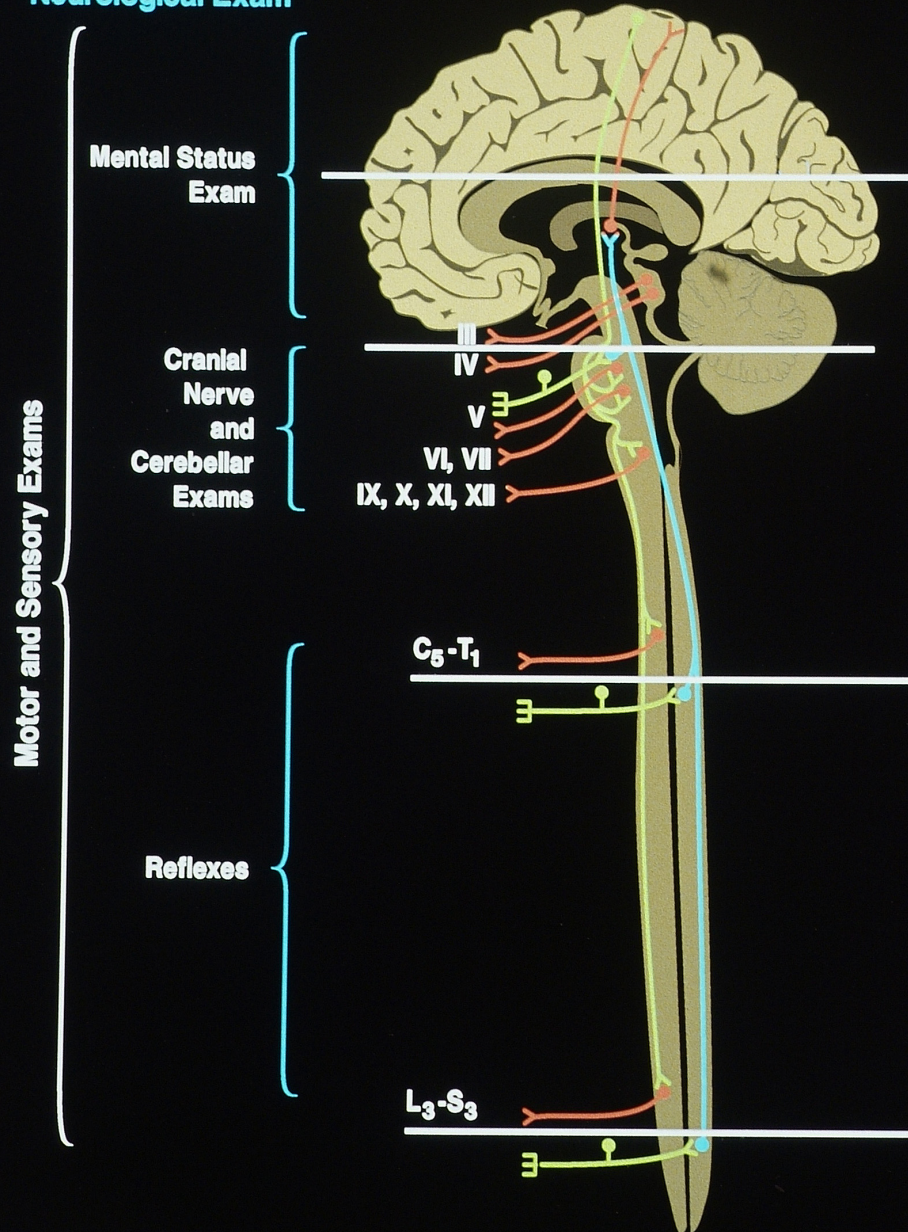
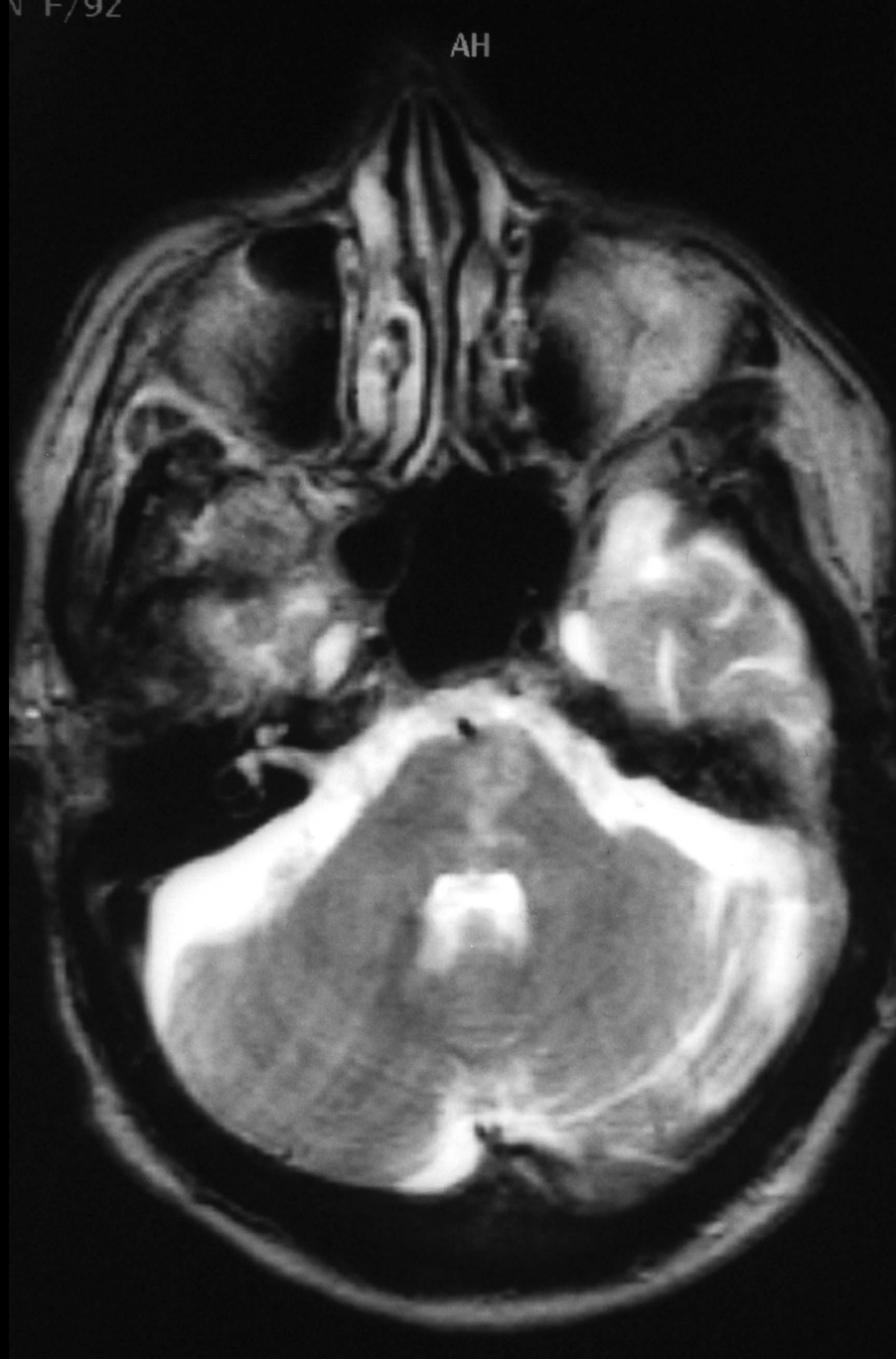

Lesion Localization in Neurologic Disease

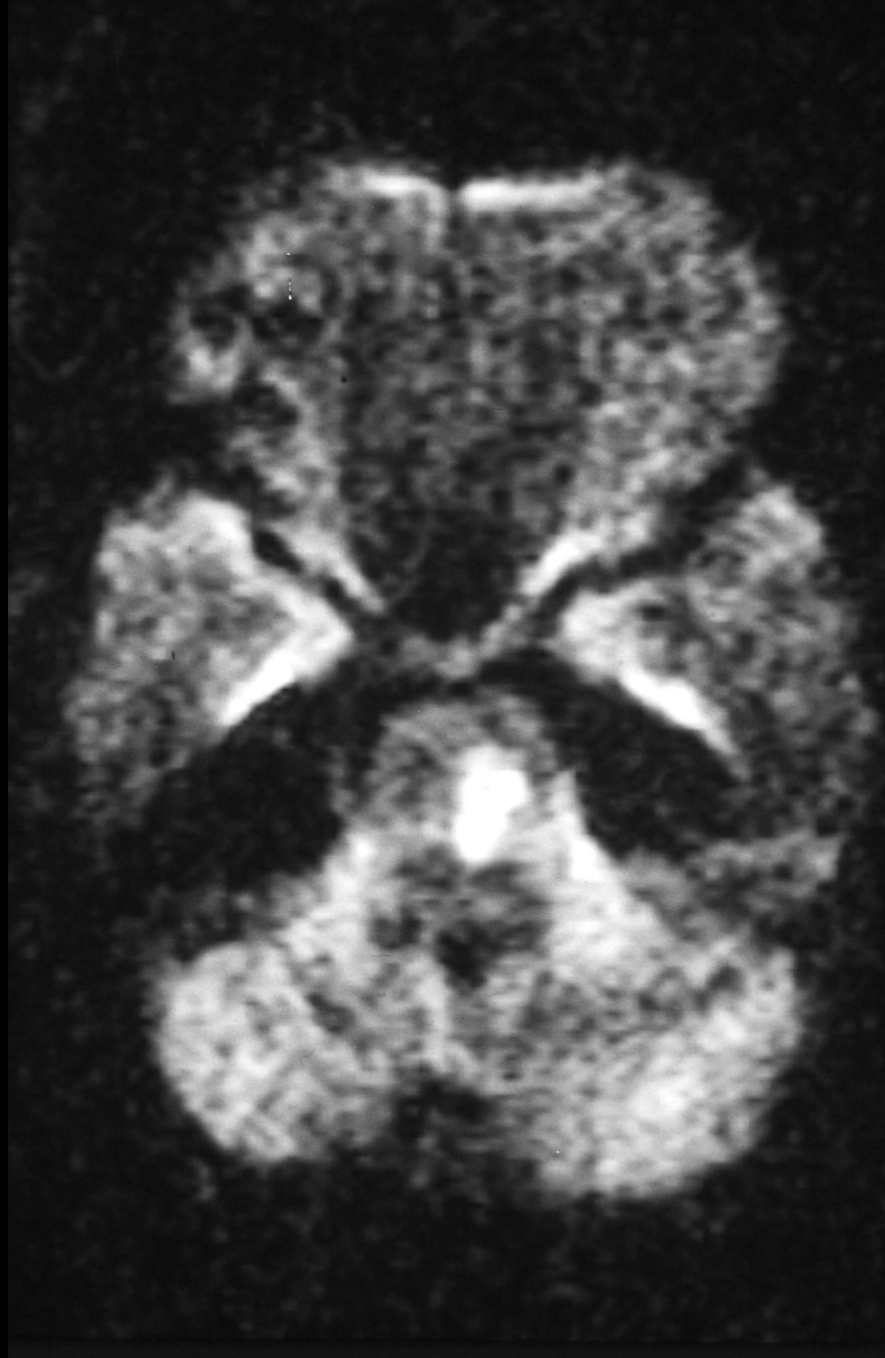Neurological Exam





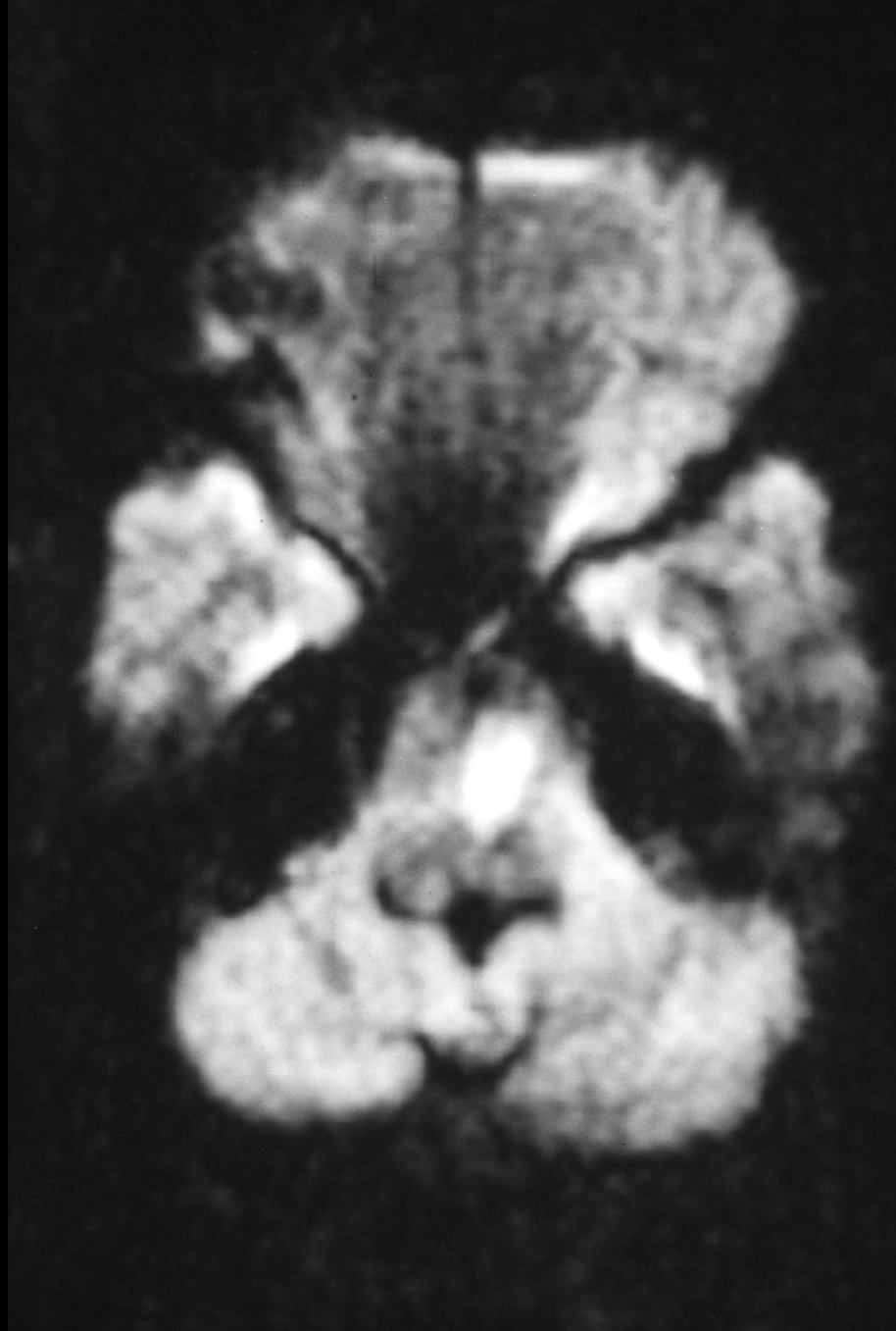Horizontal T2W MRI Scan

2/25/98



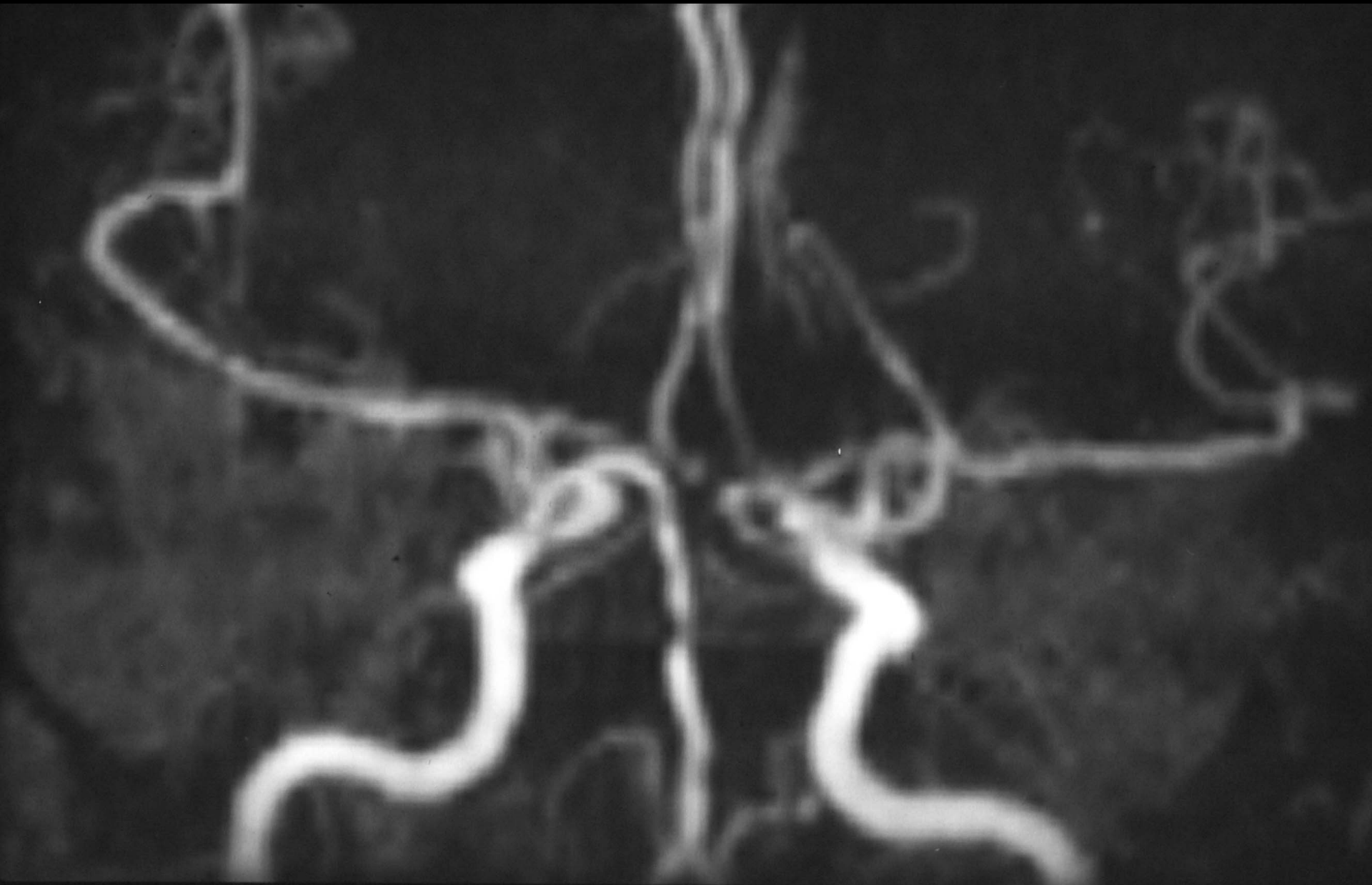
Horizontal DWI MRI Scan

2/25/98



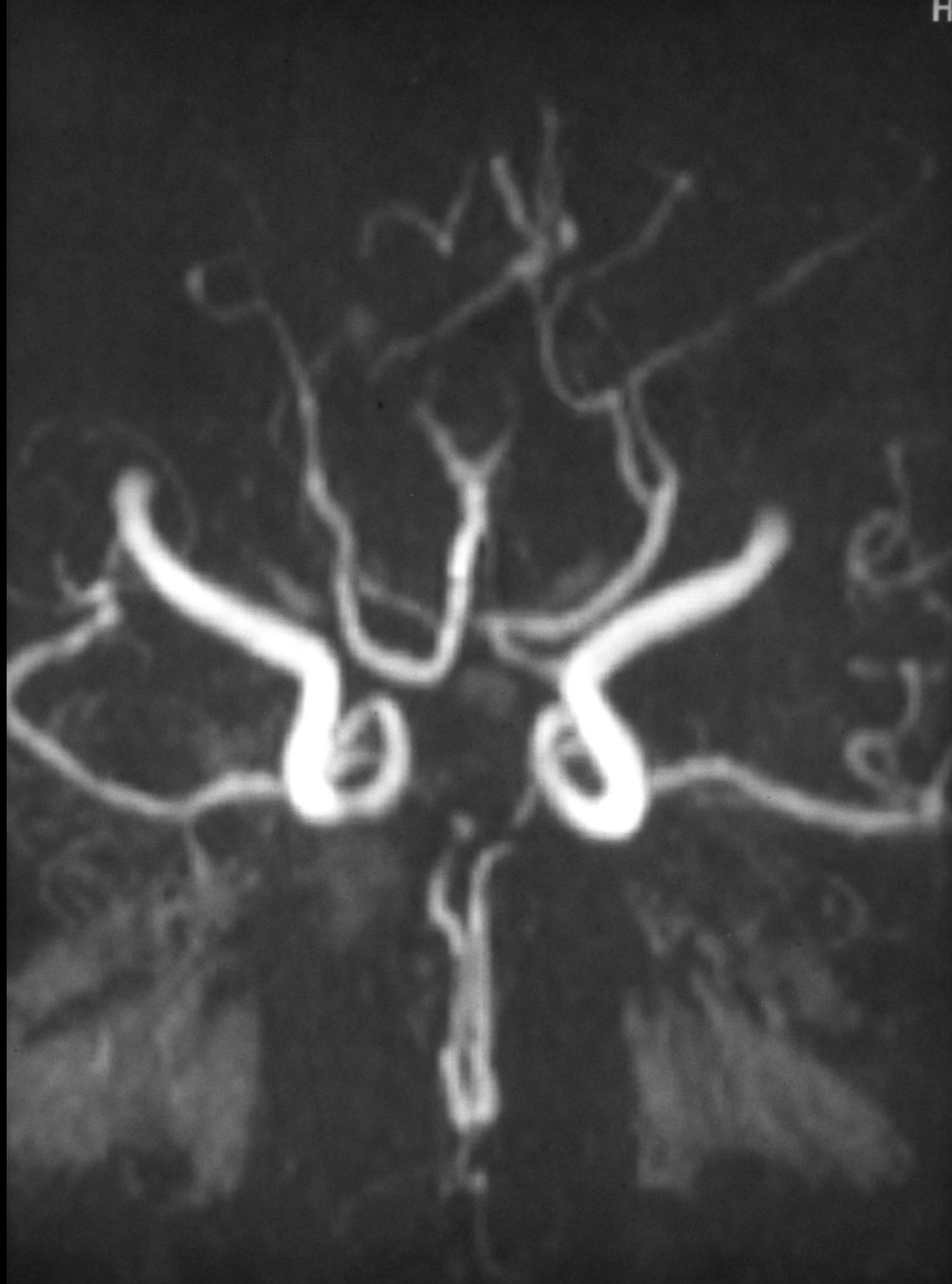Horizontal DWI MRI Scan

2/25/98



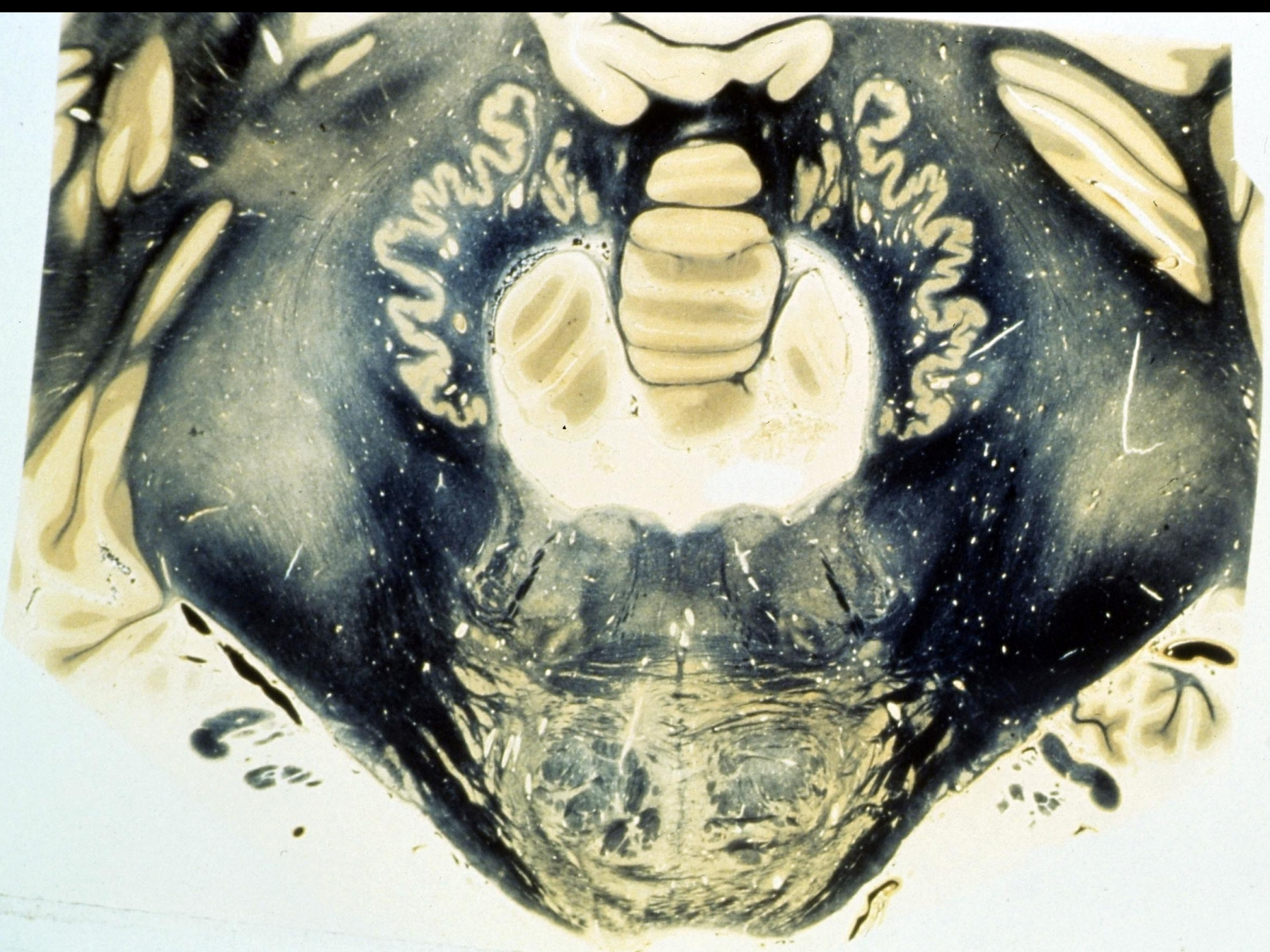
MR Angiogram (P-A View)

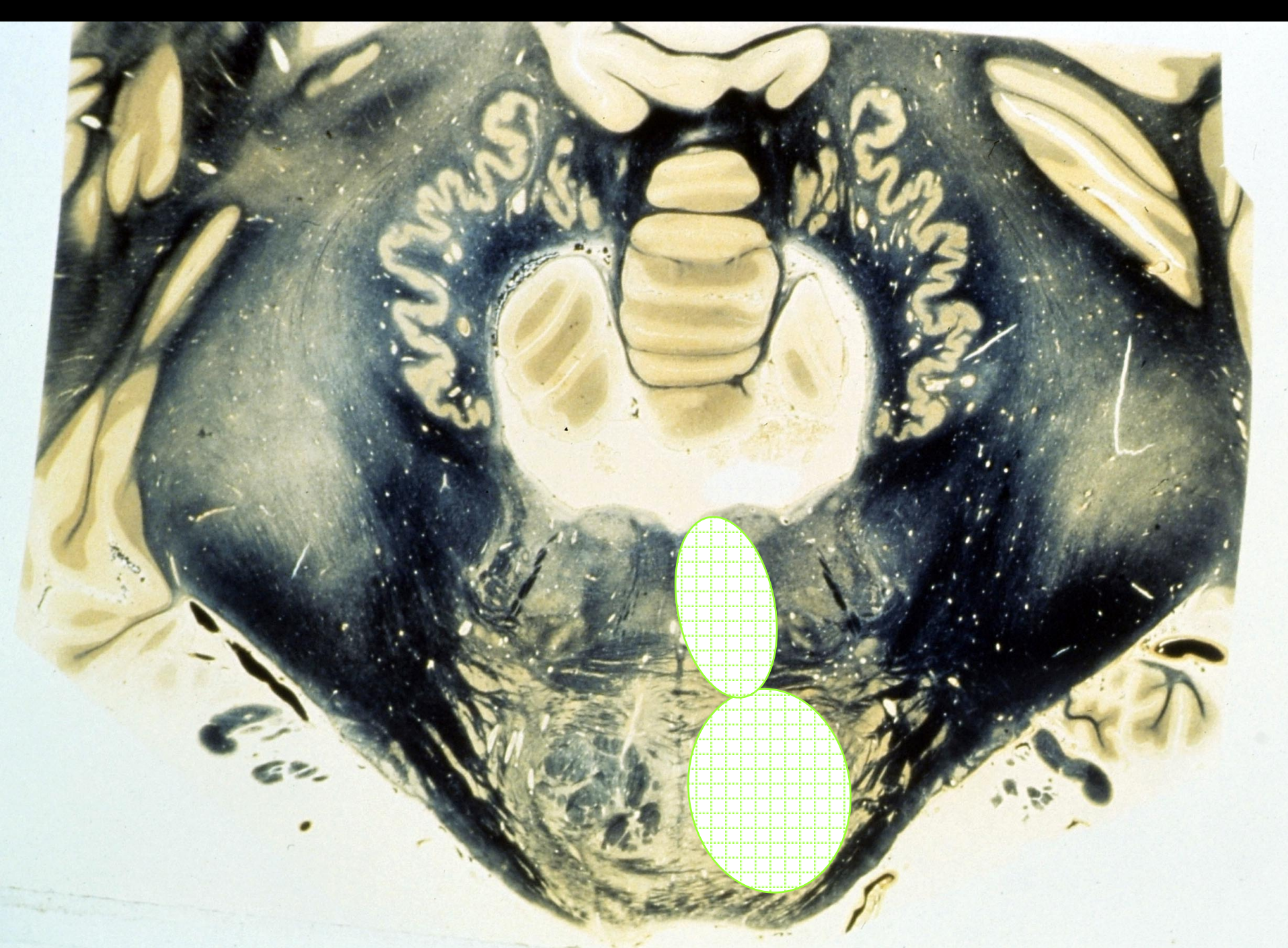
2/25/98

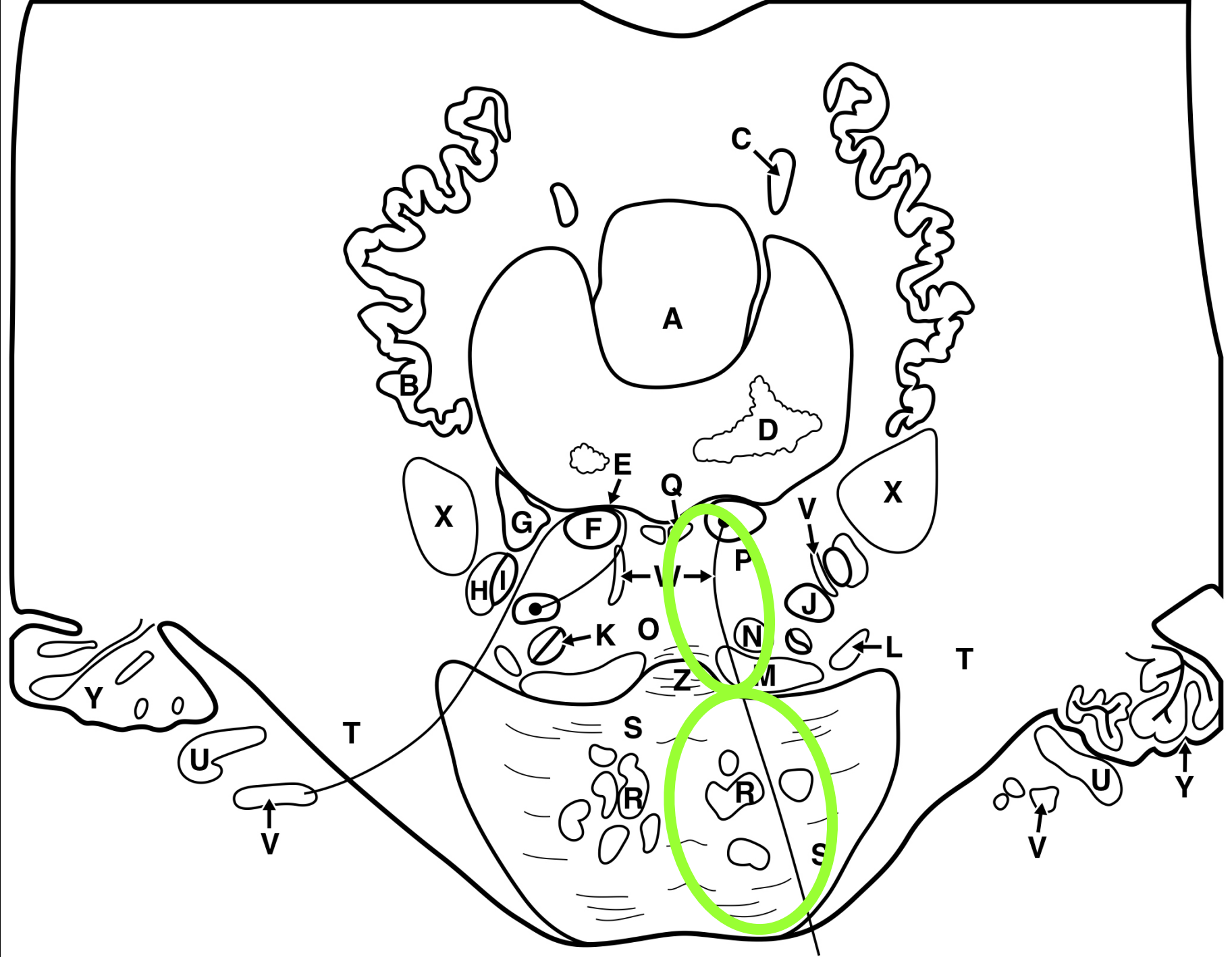


MR Angiogram (Superior View)

2/25/98







Horizontal Saccadic Eye Movement Pathways

