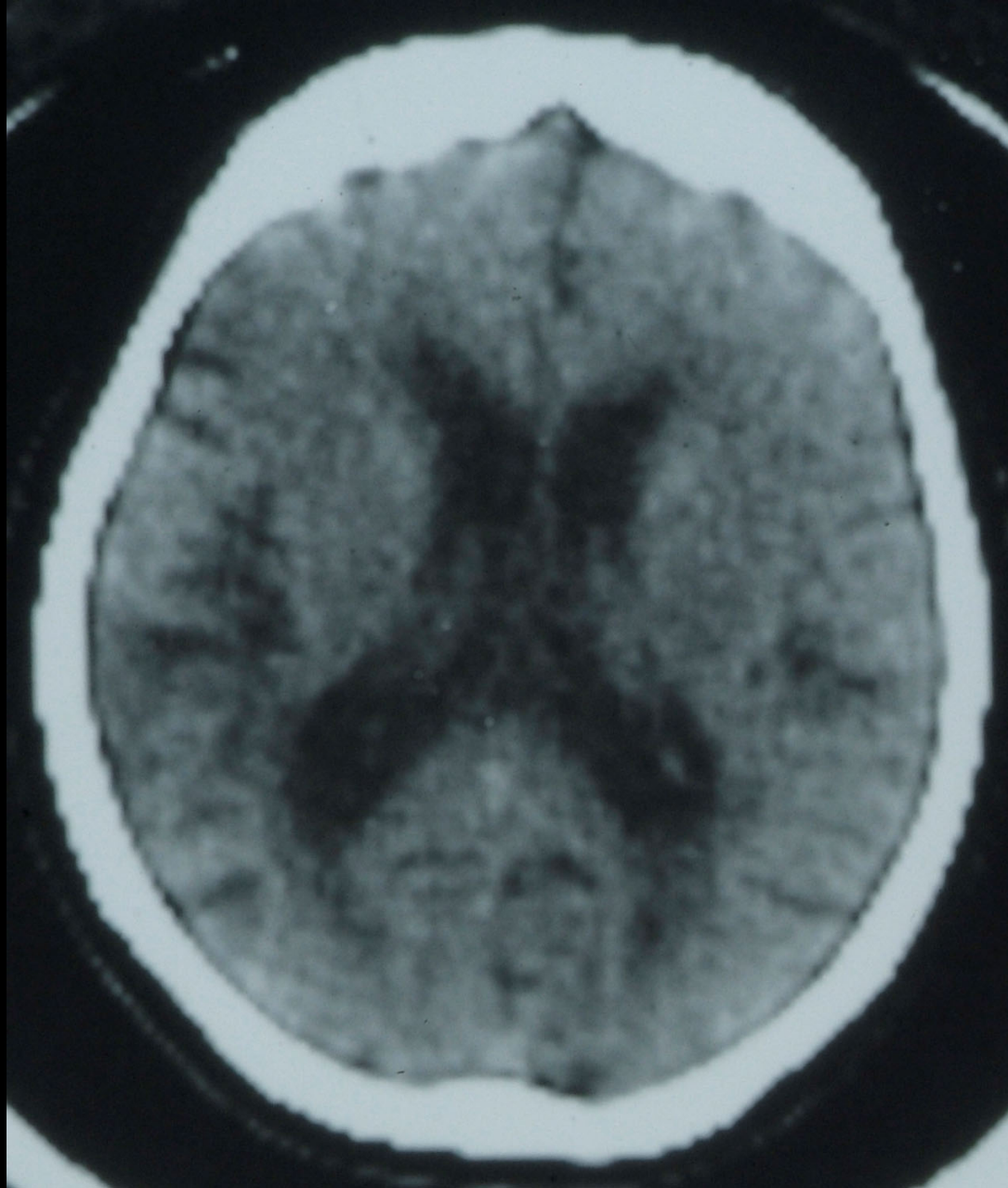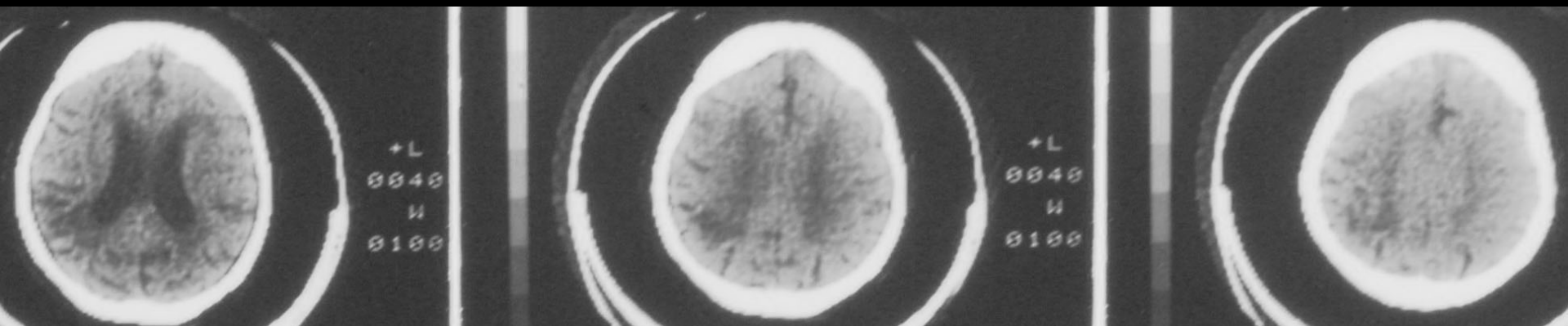


Left

Right

CT Scan without Contrast

8/1/79

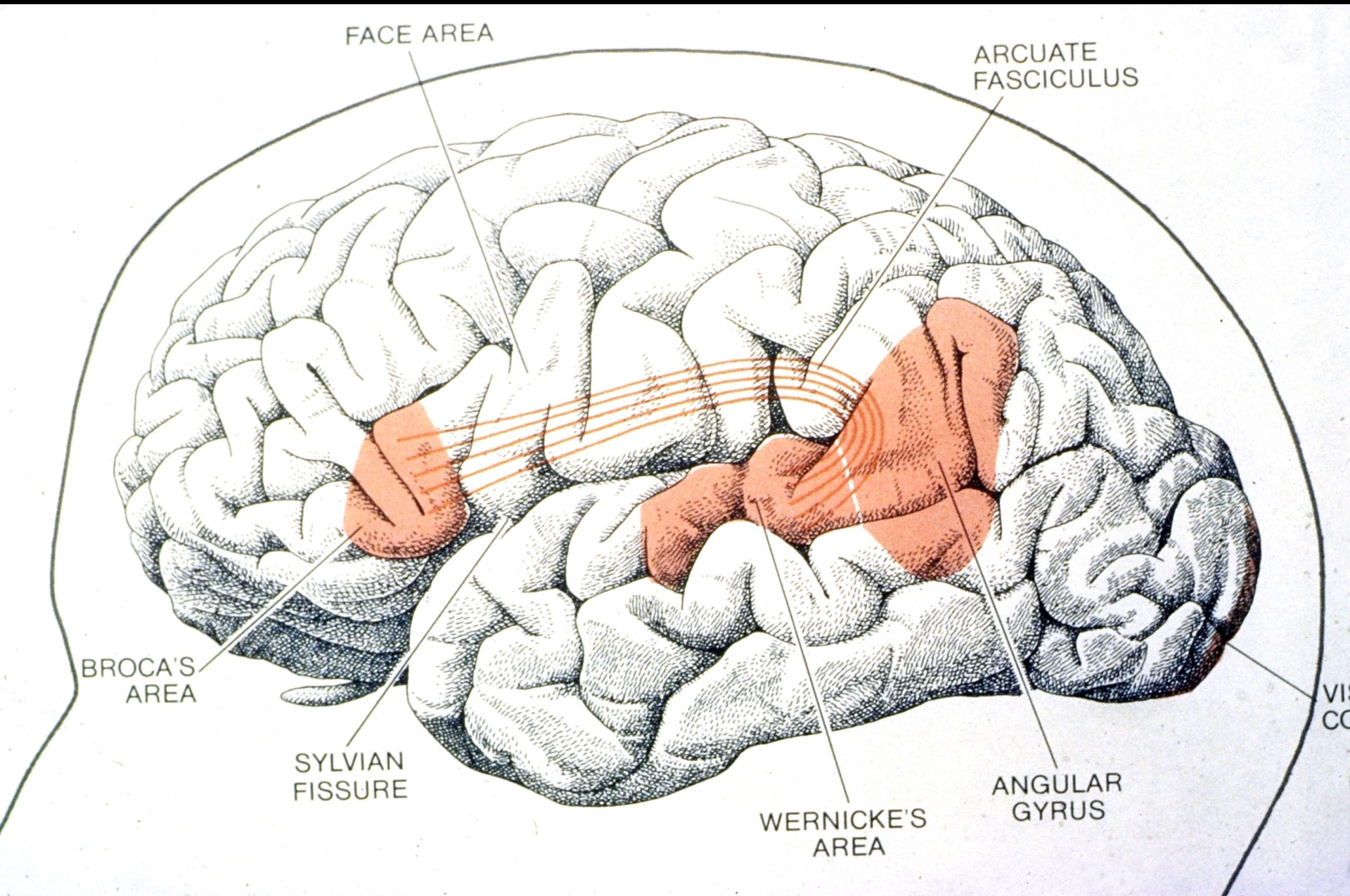


CT Scan without Contrast

Left

Right

8/1/79



FACE AREA

ARCUATE FASCICULUS

BROCA'S AREA

SYLVIAN FISSURE

WERNICKE'S AREA

ANGULAR GYRUS

Diagnosis of Aphasia

