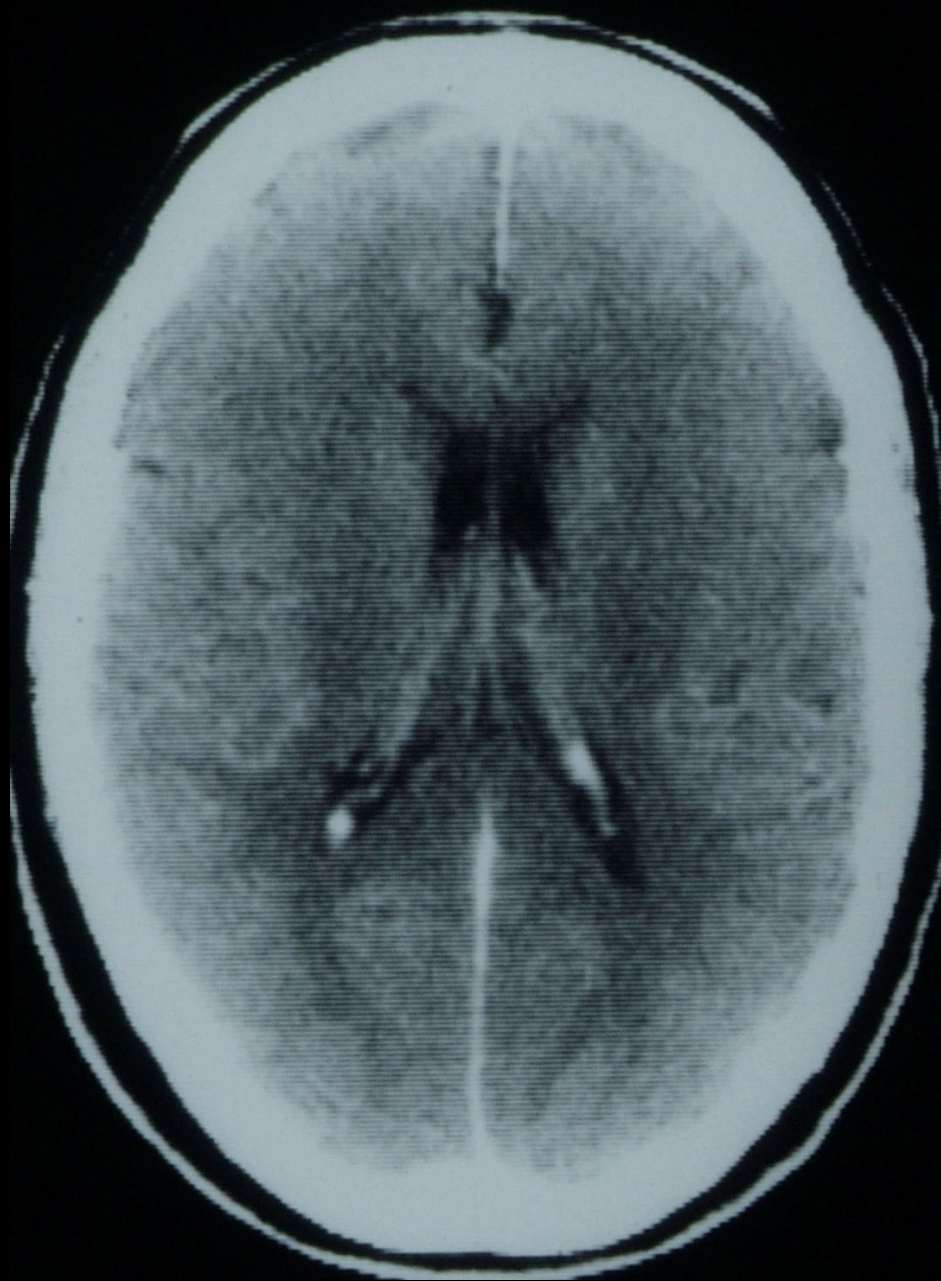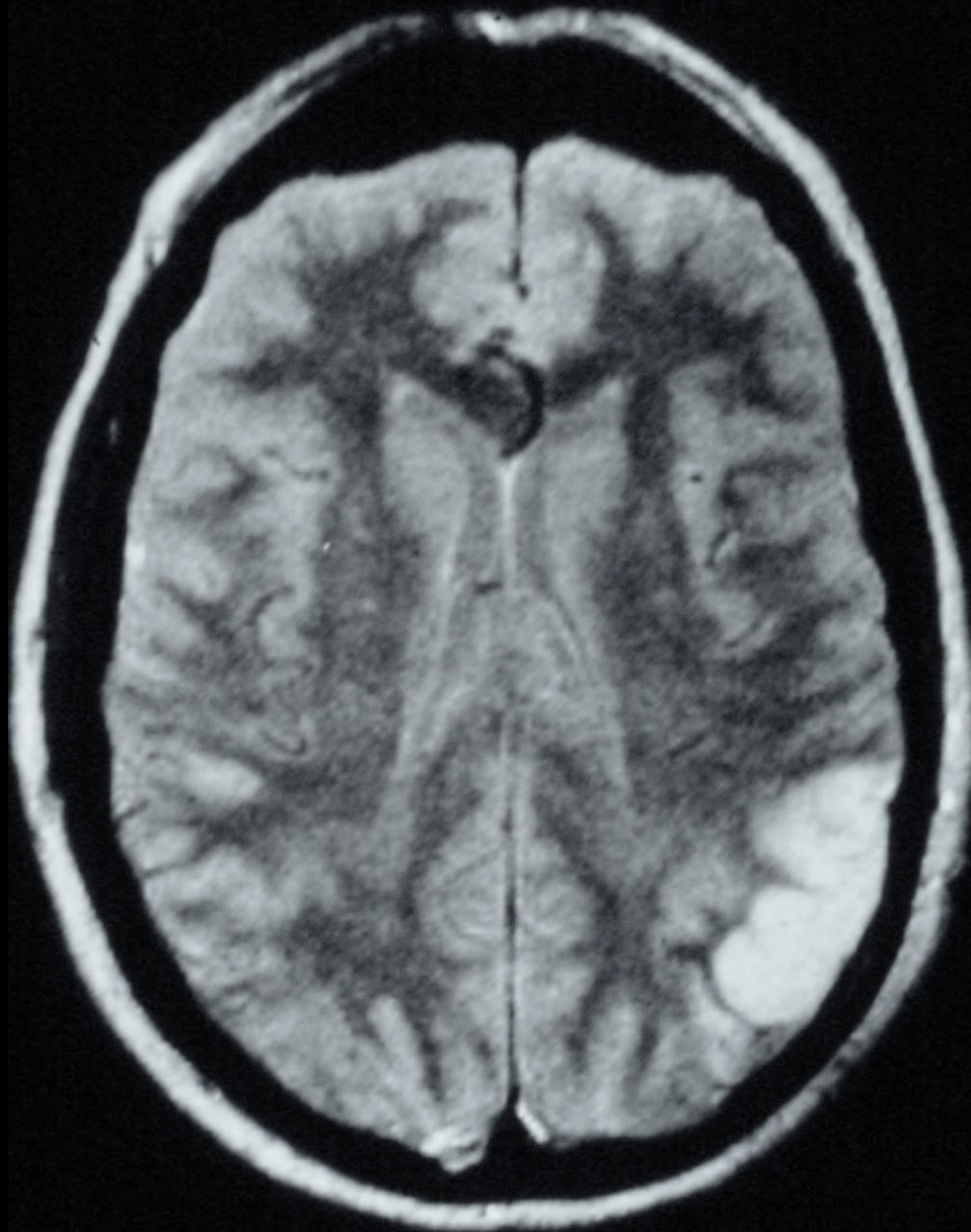


Right

Left

CT Scan with Contrast

5/3/87

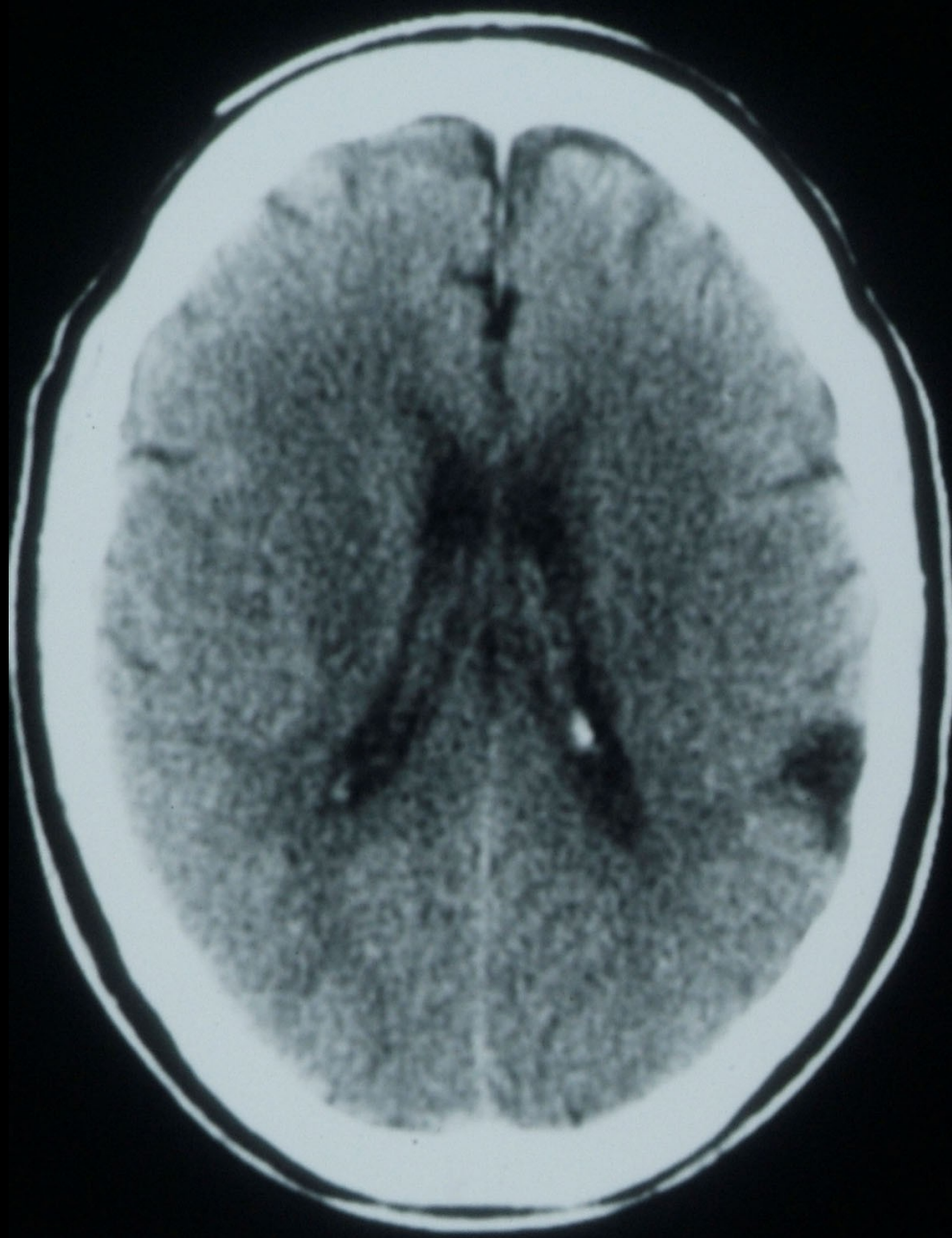


Right

Left

Horizontal PDW MRI Scan

5/5/87

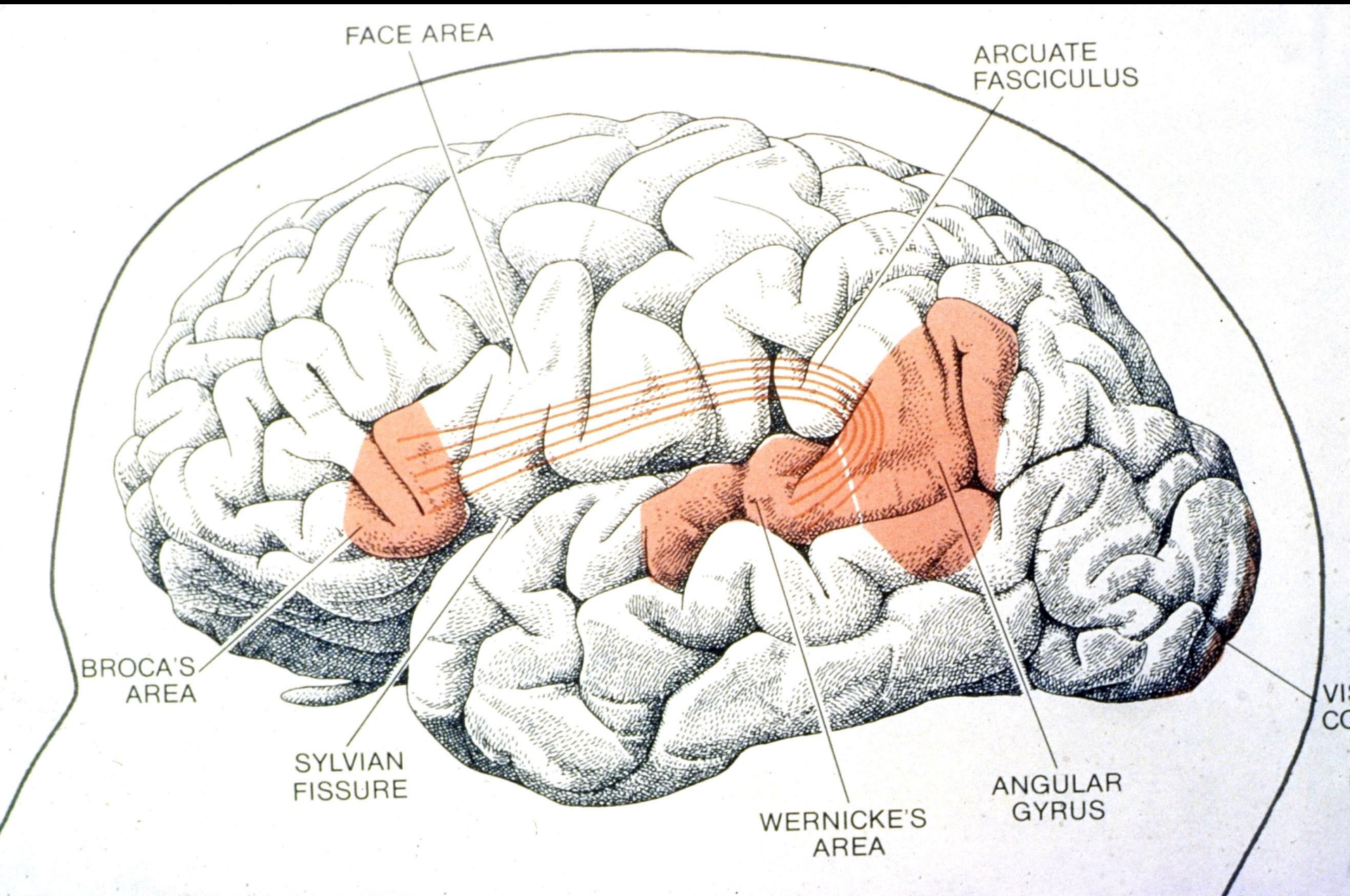


Right

Left

CT Scan without Contrast

5/6/88



FACE AREA

ARCUATE FASCICULUS

BROCA'S AREA

SYLVIAN FISSURE

WERNICKE'S AREA

ANGULAR GYRUS

VI
CO

Diagnosis of Aphasia

