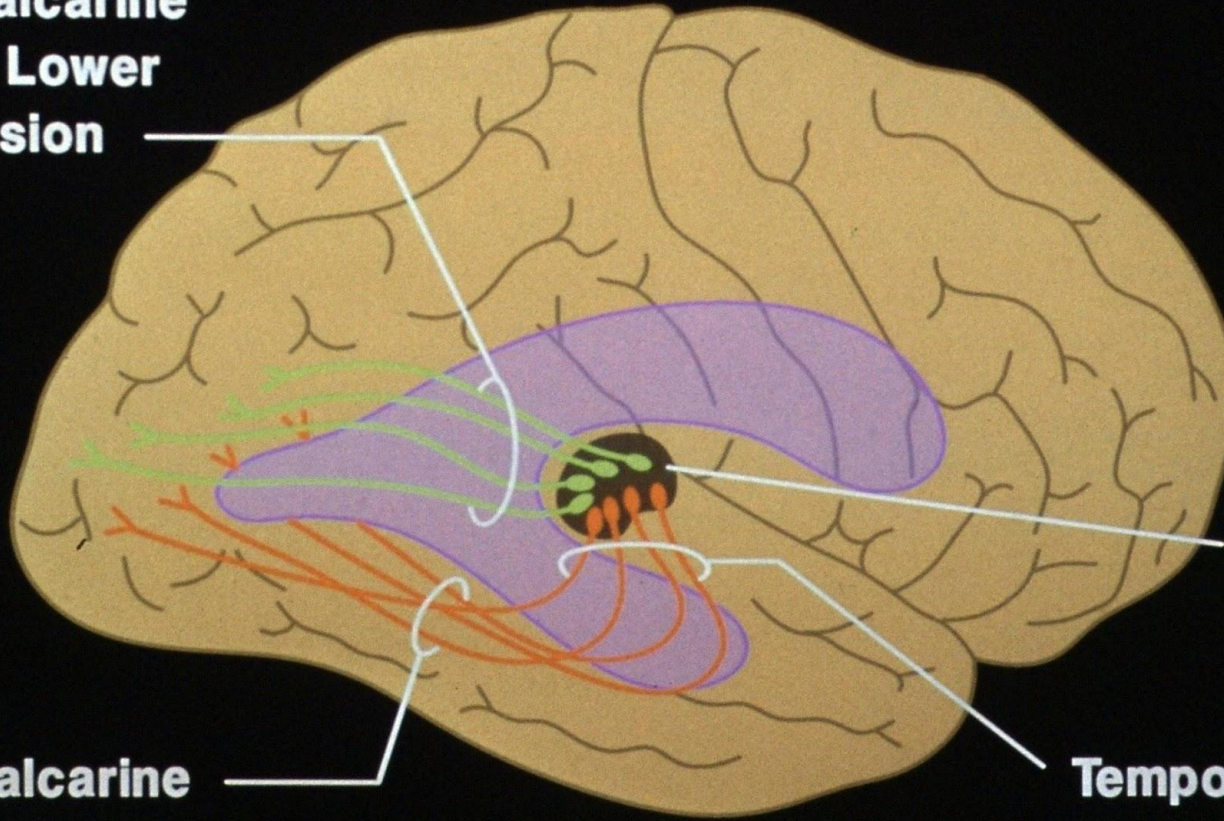


Optic Radiations

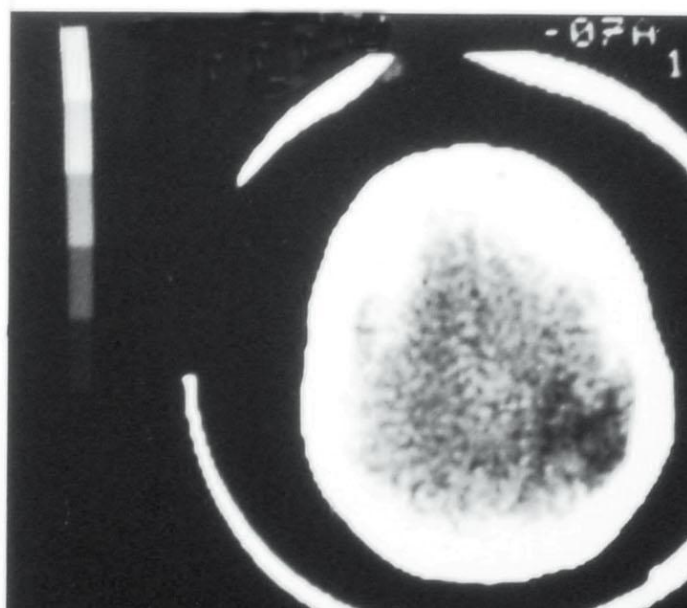
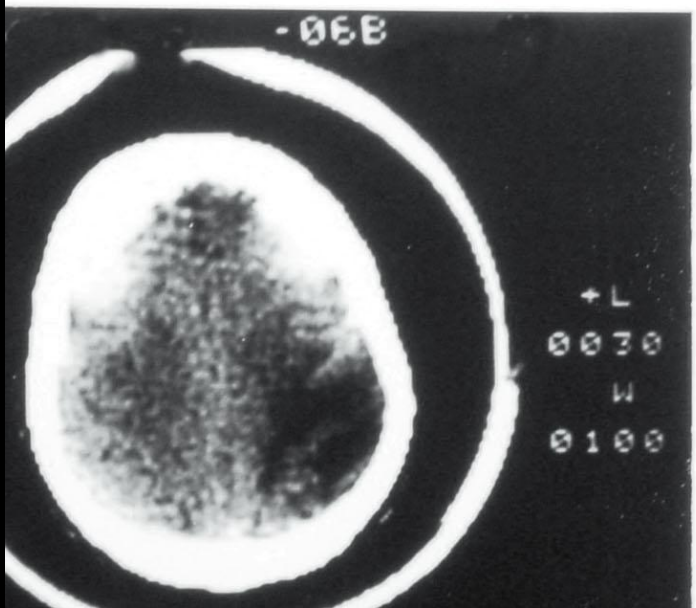
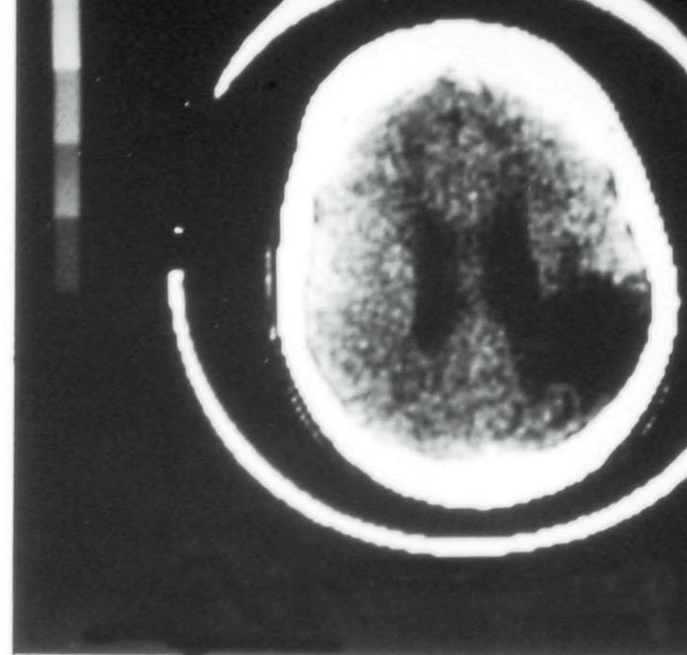
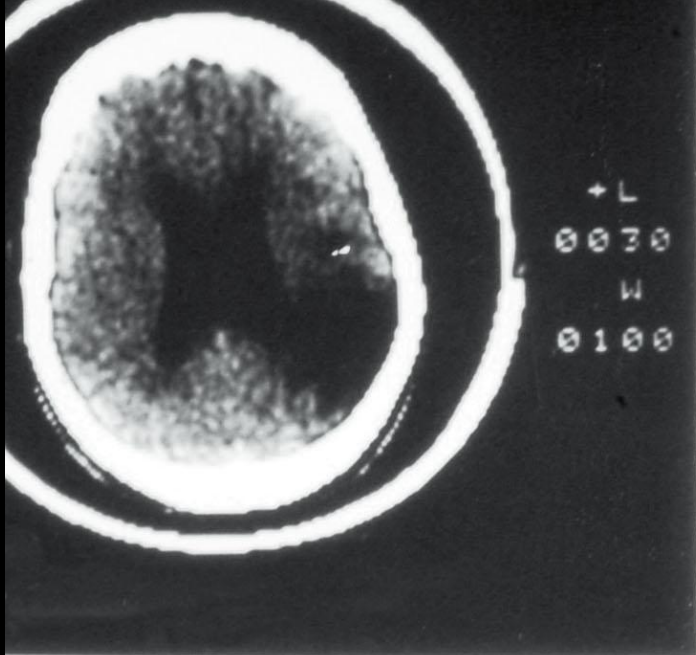
**Geniculocalcarine
Fibers for Lower
Field of Vision**



**Lateral
Geniculate
Body**

**Geniculocalcarine
Fibers for Upper
Field of Vision**

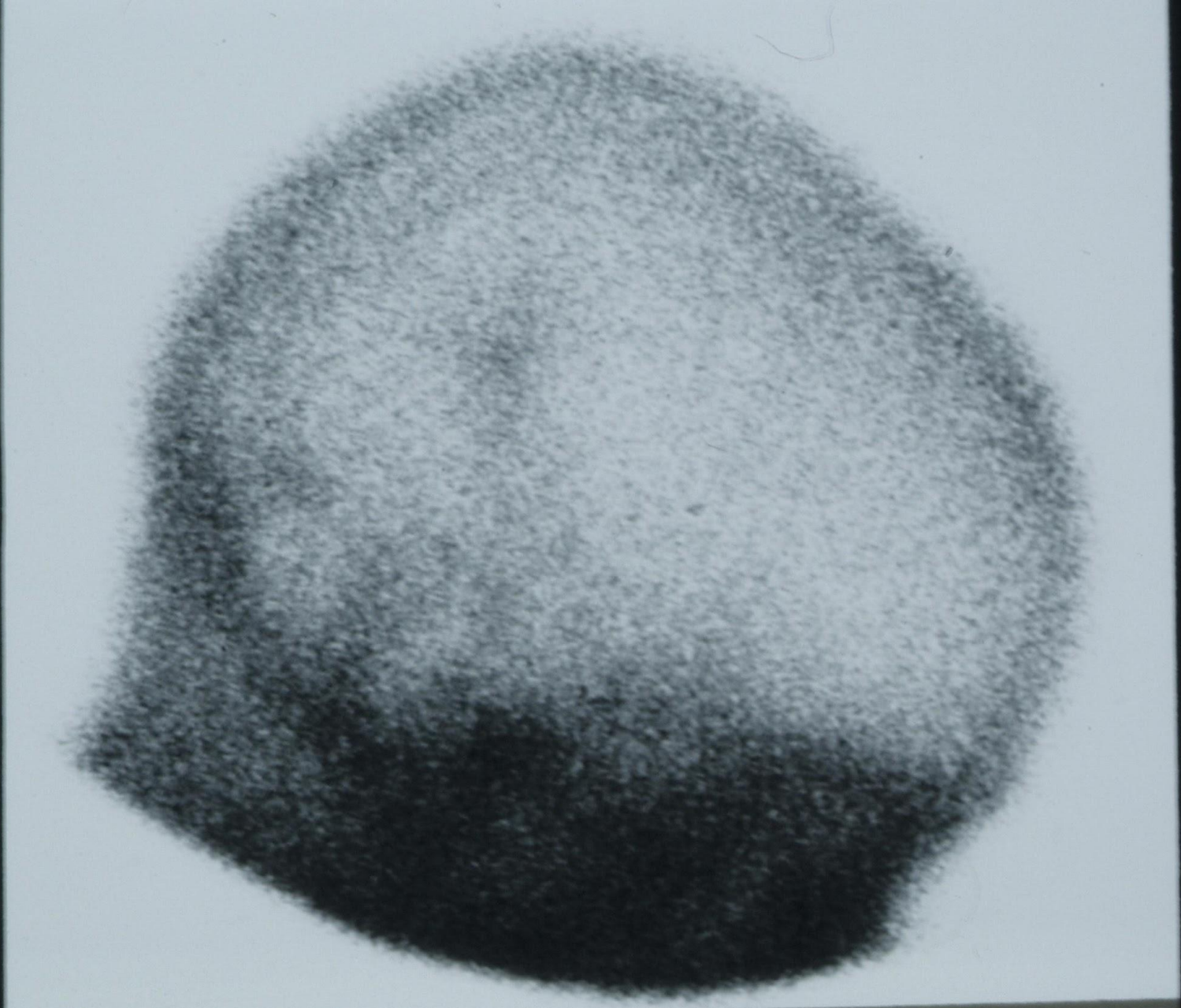
**Temporal
Loop**



Left

CT Scan without Contrast

Right

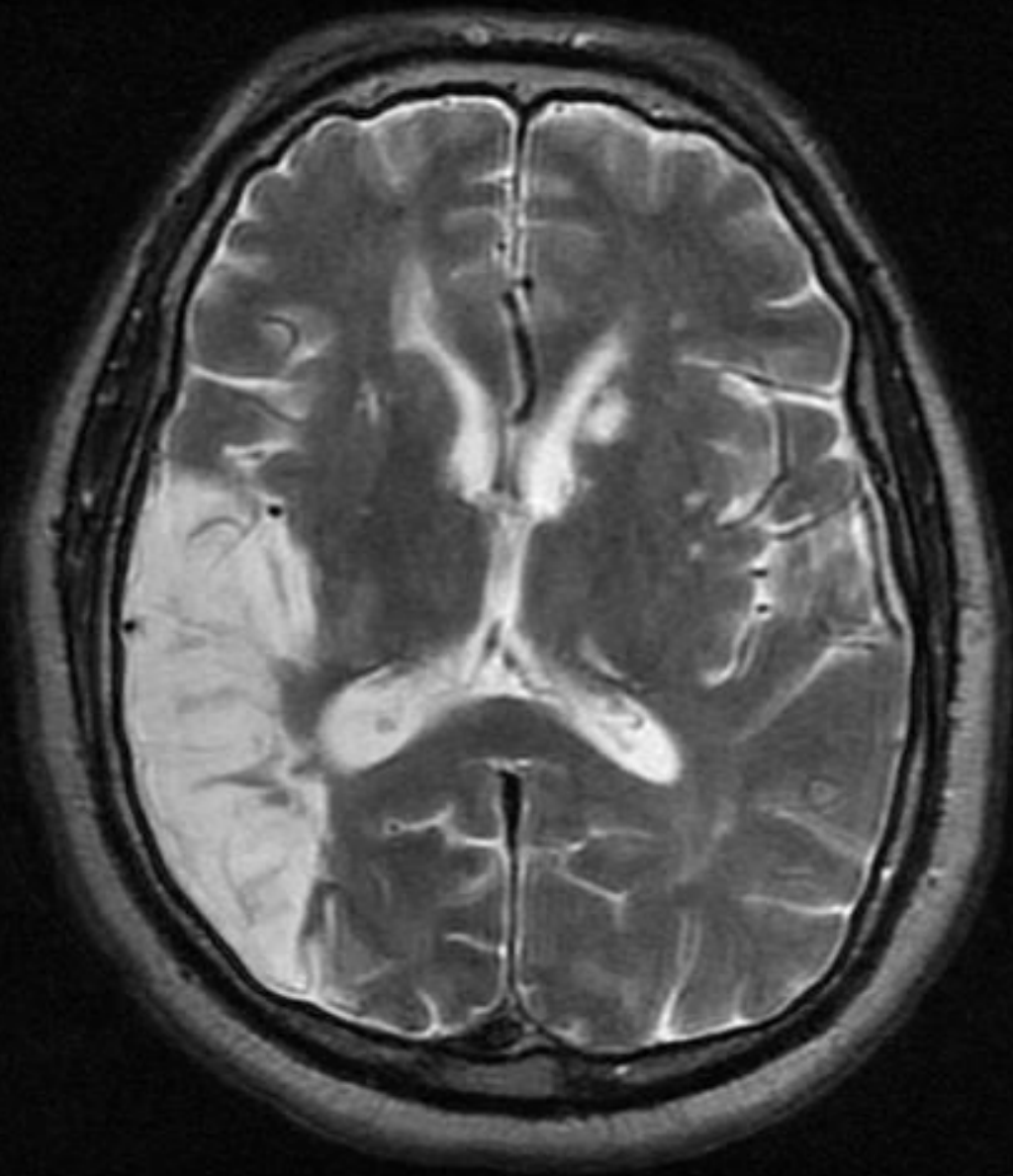


Posterior

Right Lateral View

Anterior

Another Example of a Similar Patient, Using More Modern MRI Imaging Sequences



Right

Horizontal T2W MRI Scan

Left