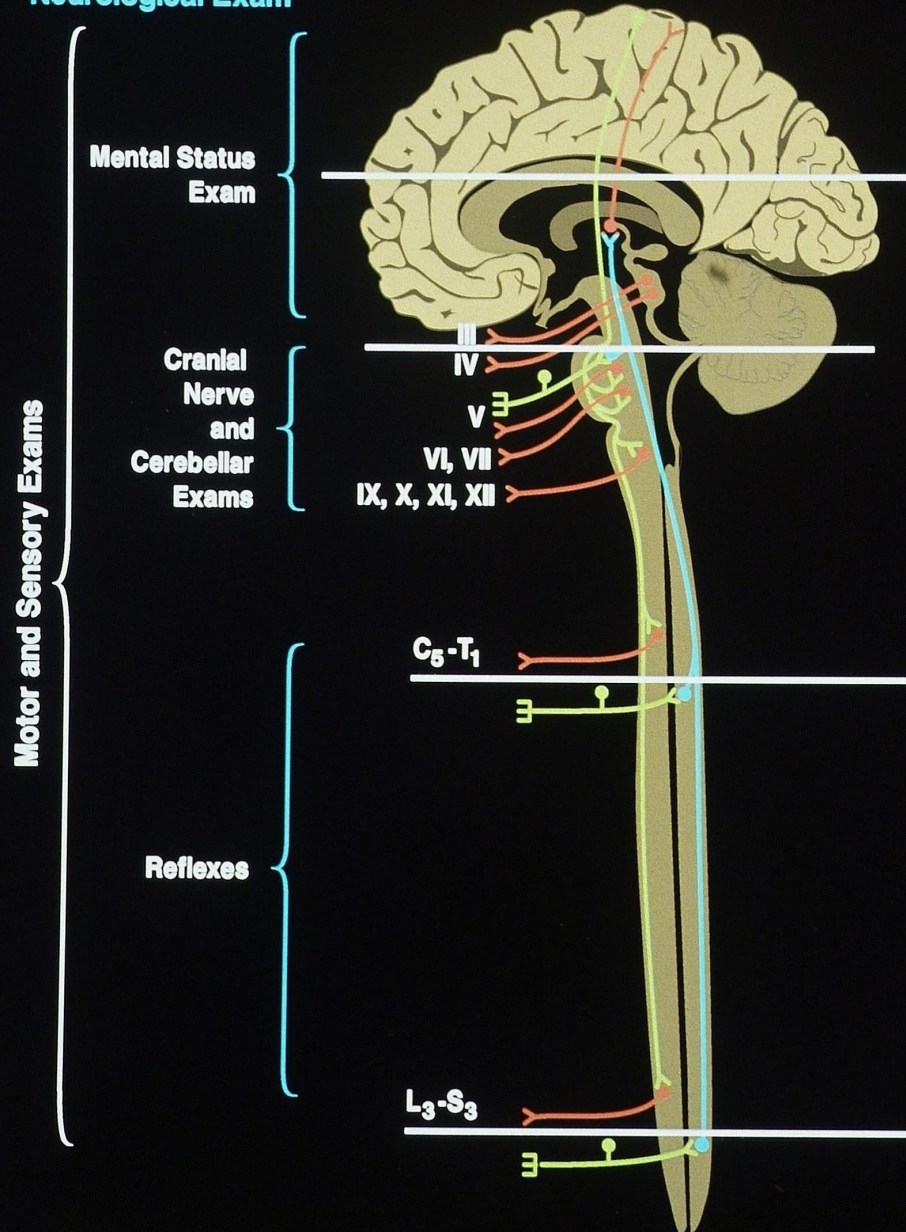
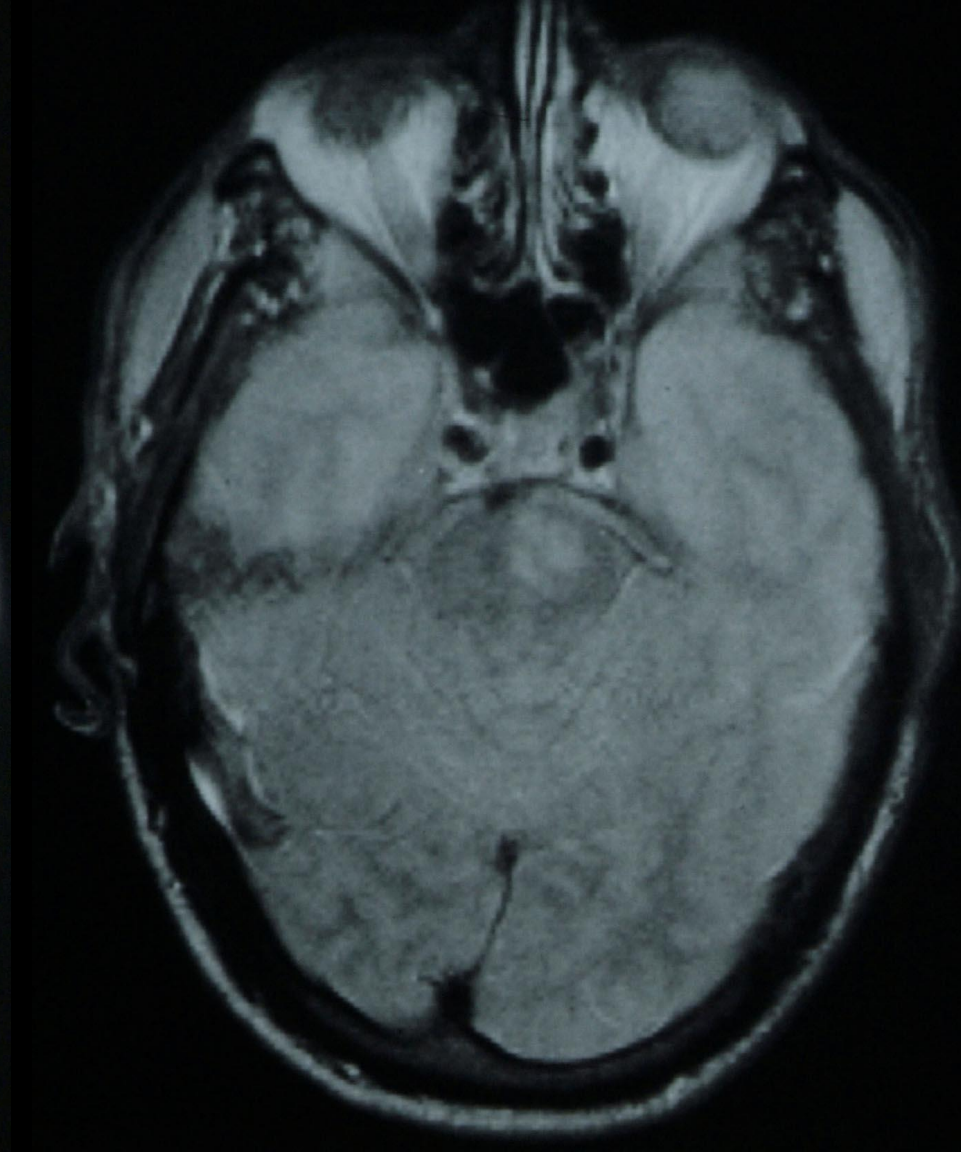
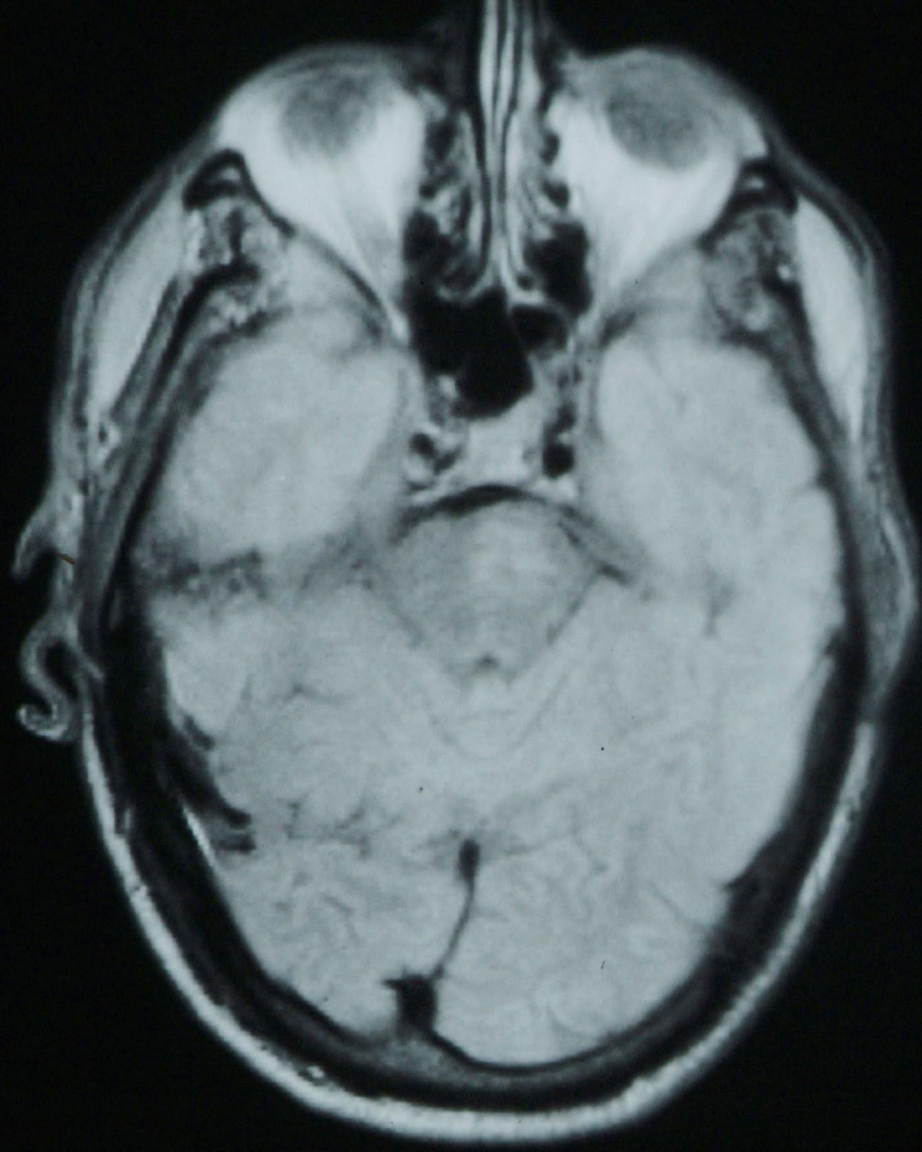


Lesion Localization in Neurologic Disease

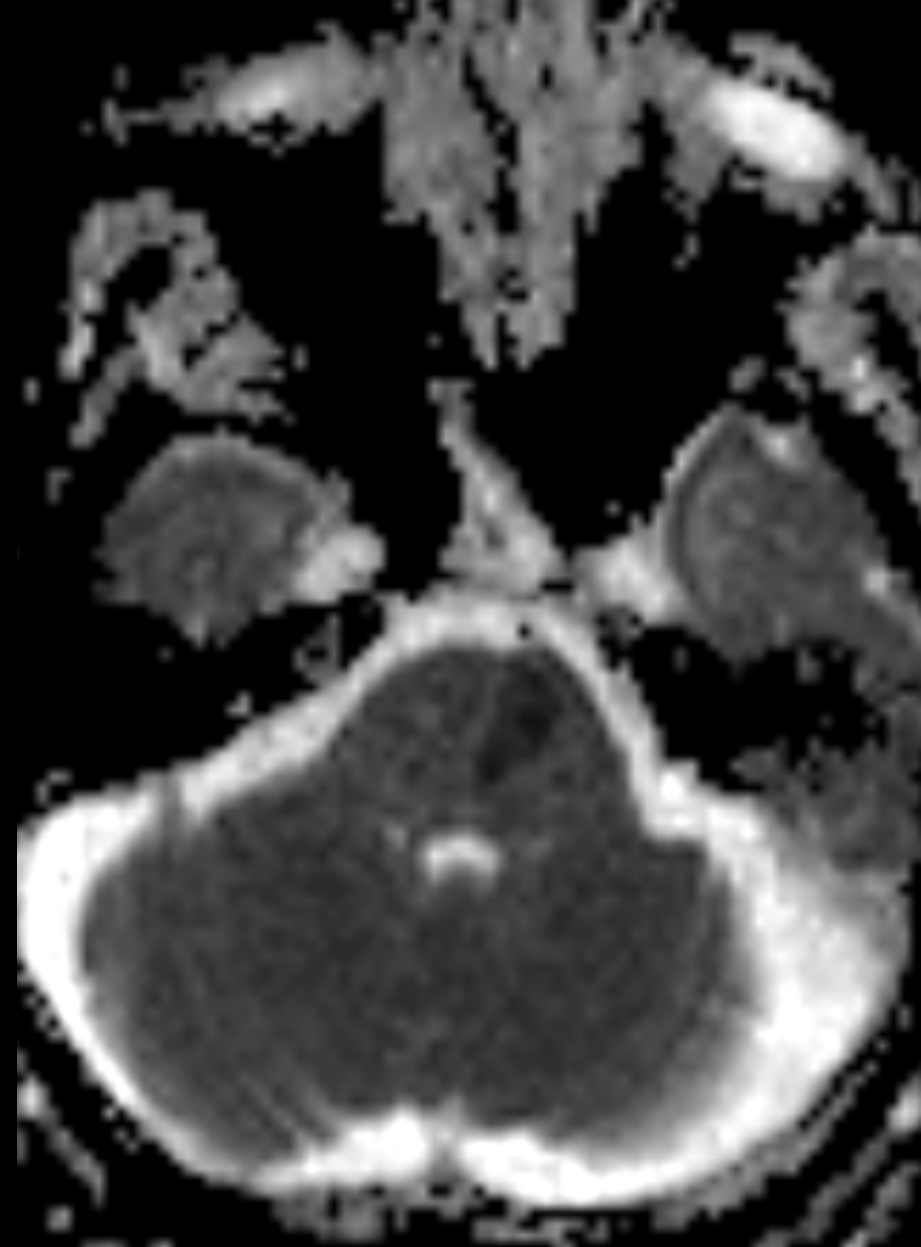
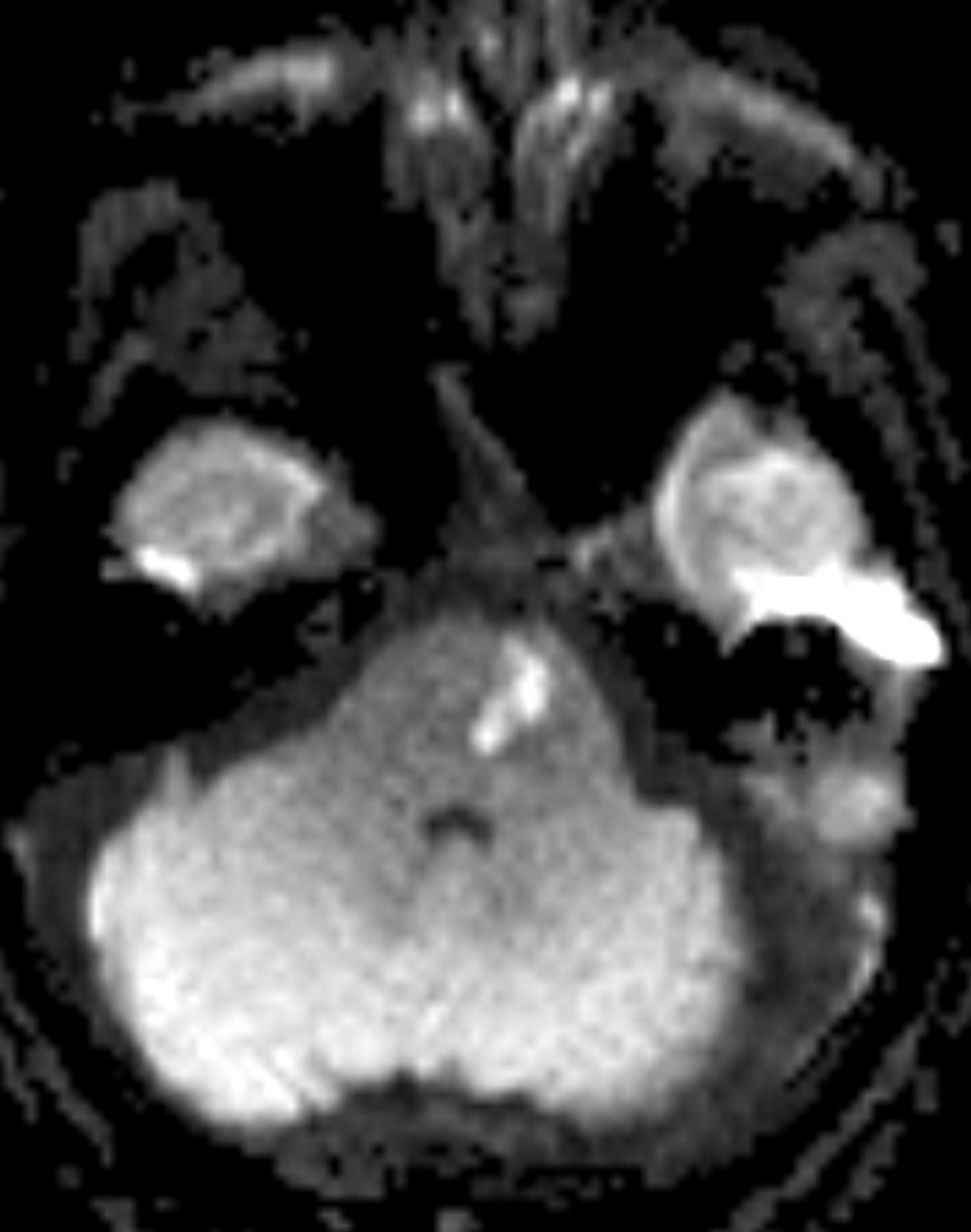
Neurological Exam





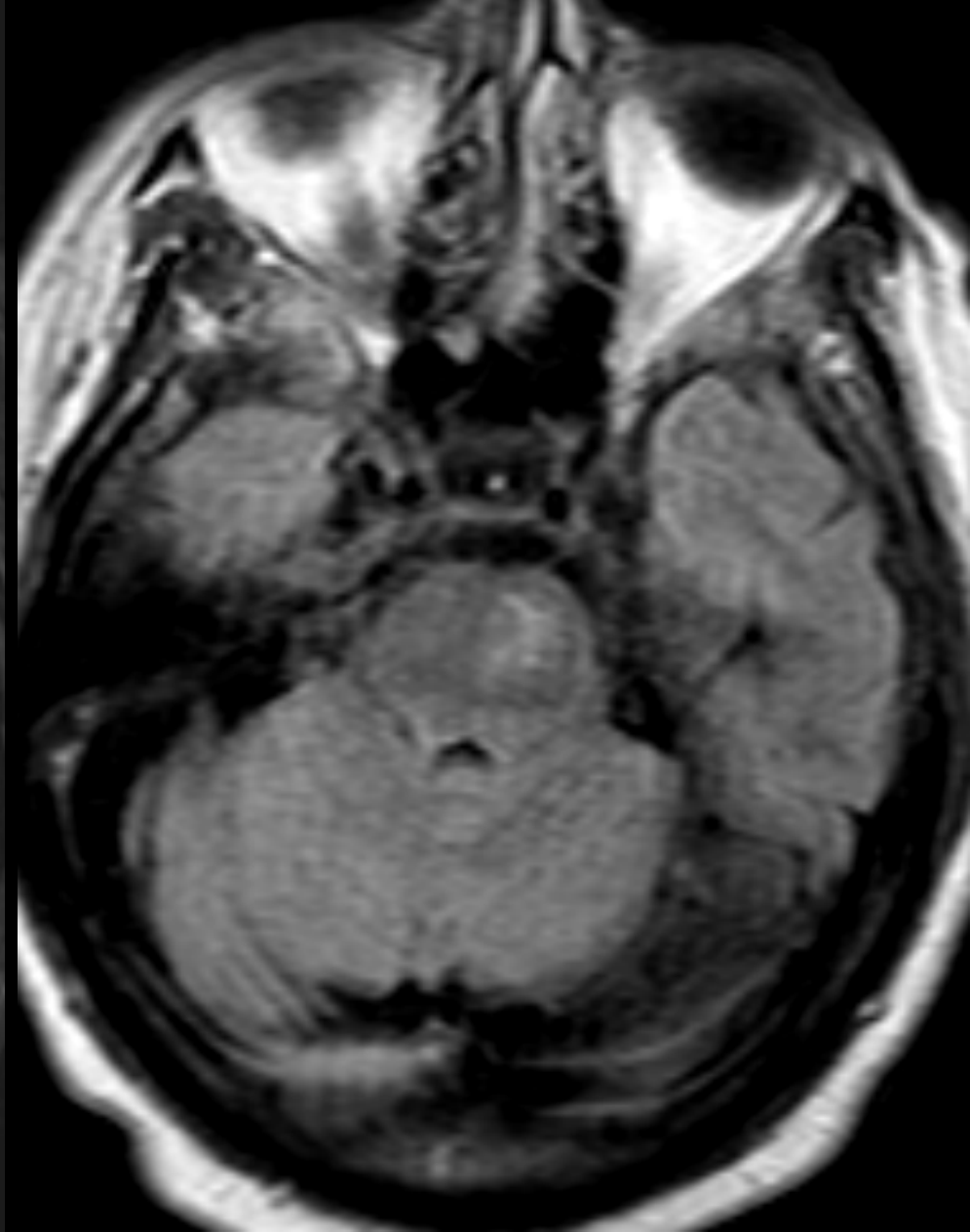
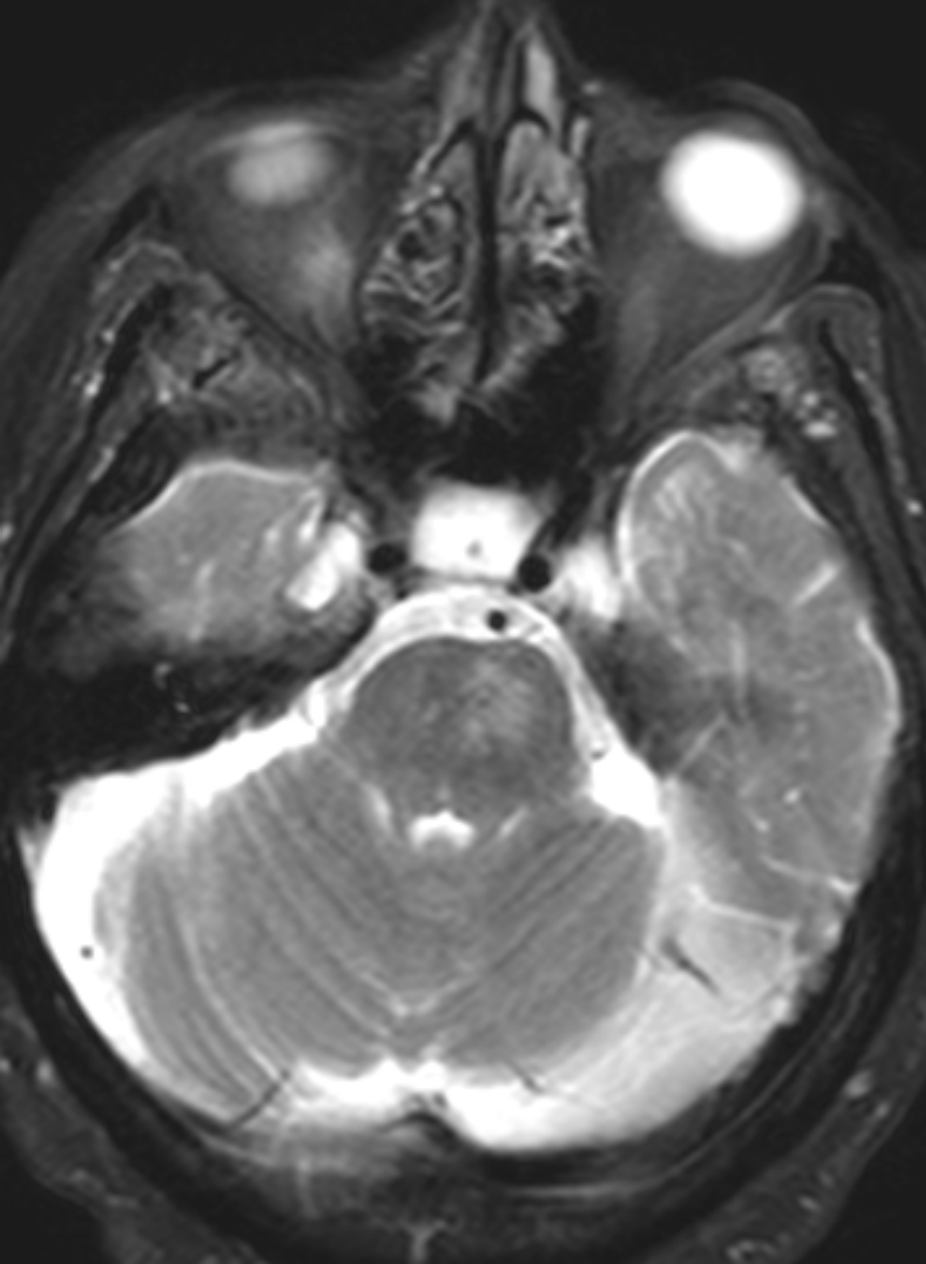
Horizontal PDW [left] & T2W [right] MRI Scan

**Another Example of a Small
Deep Infarct of the Basilar
Part of the Pons, Using More
Modern MRI Imaging
Sequences**



Horizontal DWI [left] & ADC [right] MRI Scan

7/27/12



Horizontal T2W [left] & FLAIR [right] MRI Scan

7/27/12



