



CASE REPORT I

Oral Lichenoid Drug Reaction to Allopurinol



SUHAIB ALQUDAH
DOCTOR OF CLINICAL DENTISTRY - ORAL MEDICINE
THE UNIVERSITY OF MELBOURNE
NOVEMBER 2019

Abstract

Oral lichen planus (OLP) is a chronic immune mediated inflammatory condition of unknown etiology. Lesions of OLP are chronic and rarely undergo spontaneous remission. The disease fluctuates in activity and symptoms from asymptomatic mild mucosal striation to intractable widespread oral mucosal ulceration with significant impact on the quality of life.

Introduction

OLP is one of the most common oral mucosal conditions in clinical oral medicine practice, the prevalence rate ranges from 0.5-2% in studied populations ^(1, 2). A recent Egyptian study reported a prevalence of 1.43% among the cohort studied of 4470 Egyptian patients, aged 15-75 years ⁽³⁾. The usual age of presentation is between 30-60 years with a slight female predilection ⁽¹⁾. OLP can happen in children but it is less prevalent with a reported rate of 0.4% in the studied cohort ⁽⁴⁾.

Clinically, OLP is manifested as bilateral diffuse white striation with mild erythema affecting the buccal mucosae and lateral borders of the tongue. Less commonly it can affect the gingivae, labial mucosae, hard and soft palate, and rarely the floor of the mouth ^(5, 6). In severe case, confluent erythema and ulceration can be seen associated with pain and causing considerable morbidity to patients and affect their quality of life ^(7, 8).

Etiology of OLP has not been fully explained and no single etiologic factor has been identified. Most available data suggest an immune T-cell mediated chronic inflammatory reaction, the trigger of which is still unknown. The antigen could be extrinsic, altered self-antigen or super antigen ⁽⁹⁾. Genetic factors have been suggested with reports of familial cases of OLP ⁽¹⁰⁾, infectious agents (viral and bacterial) with possible association with hepatitis C virus ⁽⁹⁾, drugs and hypersensitivity reactions, trauma, psychological factors and stress, smoking, systemic association (diabetes and hypertension), and graft versus host disease ^(2, 5, 9).

Pathogenesis of OLP is thought to be a T-cell mediated keratinocyte degeneration in the basal cell layer. It is hypothesised that one or more of the putative etiologic factors alter antigen expression by lesional keratinocytes which is then detected by antigen presenting cells in the basal layer leading to an increase in Th1 cytokines particularly IFN- γ and TNF- α , to mount cytotoxic CD8+ response against basal keratinocytes leading to apoptosis with further CD8+ T-cells and keratinocytes releasing chemokines that attract additional lymphocytes and other immune cells into the developing OLP lesion causing further tissue destruction and chronic inflammation ^(5, 11).

Cases of OLP that present with the classical features of bilaterally symmetrical radiating white striae (Wickham's striae) can be diagnosed based on clinical features only. However, due to the chronicity of the disease, heterogeneity of clinical features, the need for long-term treatment and monitoring, and the risk of malignant transformation; a histopathological confirmation and correlation with clinical features is required ^(1, 5, 6). The microscopic features of OLP include hyperkeratosis, acanthosis, basal cell degeneration and Civatte body formation, diffuse band-like inflammatory T-cell infiltrate at the epithelial connective tissue interface and absence of epithelial dysplasia ^(12, 13). Confirmation of diagnosis requires correlation between the clinical and histopathological features based on the modified WHO diagnostic criteria of OLP and OLL as suggested by van der Meij and van der Waal 2003 ⁽¹³⁾. (*Table 1*)

Oral lichenoid Lesions (OLL) is a term that is used to describe several clinical presentations that mimic OLP clinically and histopathologically. OLL comprises Oral Lichenoid Drug Reactions (OLDR), Oral Lichenoid Contact Lesions (OLCL), and Oral Lichenoid Lesions of Graft versus Host Disease (OLL GvHD). As suggested by van der Meij and van der Waal 2003, this term is to be used for lesions that partially fulfil the clinical and histopathological diagnostic criteria for OLP ⁽¹³⁾. OLDR appear in temporal relationship with exposure to certain new medication and may be associated with cutaneous lesions ⁽¹⁾. The lesions may appear a few months to years after the start of the medication and may persist even after cessation of the offending drug ^(6, 14). Multiple drugs have been reported to cause OLDR and the list includes but not limited to angiotensin-converting enzyme inhibitors, nonsteroidal anti-inflammatory drugs, oral hypoglycaemic drugs, beta-blockers, methyldopa, quinidine, quinine, diuretics, antifungals, anticonvulsants, gold salts, penicillamine, sulfasalazine, and lithium ^(14, 15).

Histopathologically, OLDR resembles OLP. However, a more diffuse lymphocytic infiltrate mixed with plasma cells and eosinophils can be seen, and the inflammatory infiltrate frequently extends deeper in the connective tissue layer and in perivascular region. None of these characteristics are consistent or specific to OLDR ⁽¹⁶⁾. The most reliable way to diagnose OLDR is resolution of the lesions upon discontinuation of the drug and recurrence of the clinical appearance when the patient is rechallenged with the same medication. However, this is both impractical and unethical as it may take months to years for the lesions to reappear and exposes patient to unnecessary and avoidable adverse reactions ⁽¹⁾.

The malignant potential of OLP and OLL has been a debated topic among researchers and clinicians for years. Recent systematic reviews and meta-analyses have reported malignant transformation rates ranging from 0% - 3.5% for OLP and 0.15%-4.95% for OLL, with most accurate estimation at around 1.1% over a period of 83 months. This rate obviously varies

among different clinical presentations and patient-specific risk factors, with a very low rate of 0.1% reported for classical reticular cases of OLP⁽¹⁷⁻²⁰⁾.

Allopurinol is a medication classically used in the treatment of gout and kidney stones. Allopurinol's most common side effects are gastrointestinal distress, hypersensitivity reactions (fever, vasculitis, eosinophilia, and worsening of renal function), and skin rash. The hypersensitivity reaction may occur months or even years after starting on the medication⁽²¹⁾. Until now, there has been only one case series that reported OLDR to allopurinol in 3 patients. In all cases, stopping the allopurinol treatment had resulted in considerable improvement of the oral lesions⁽²²⁾. Here, we report a case where after few months of commencing allopurinol treatment in a 50-year-old man, a widespread OLL occurred, and stopping the medication resulted in almost complete resolution of the lesions.

Case Report

A 50-year old man was referred to the Oral Medicine Department of The Royal Dental Hospital of Melbourne, with a complaint of rough and itchy sensation inside the mouth upon eating spicy food for the past 3 months. His local dentist noticed diffuse white patches on multiple sites inside the mouth. These findings were incidental when the patient attended his community dental clinic for his regular dental check-up and clean. Patient thought the lesions became more obvious after having his teeth cleaned.

The medical history was significant for gout, for which patient was started on Zyloprim (Allopurinol) 300 mg daily tablets, 12 months prior. He reported 8-10 months history of skin eruptions that were itchy and causing erythematous patches that last for 2-3 weeks then spontaneously heal without scarring. His medical doctor had investigated both these oral and cutaneous lesions. Patient had viral serology (HSV, Hep C, Hep B, HIV), ANA and ENA testing, full blood exam, haematinics, and syphilis serology. All of these tests were within normal limits and did not suggest a diagnosis.

Extra-oral examination did not reveal any pathology. There was no regional lymphadenopathy, swelling, or tenderness. There was no visible head and neck cutaneous pathology. Mouth opening was wide and straight with no detectable TMJ pathology.

Intra-oral examination was significant for diffuse widespread bilateral buccal mucosal white reticular striations, and thick white patches and striation on the lateral borders of the tongue. There were no other oral mucosal sites involved and no other oral mucosal pathology detected.

Based on the classical bilateral presentation of the lesions and the presence of typical striation, a clinical diagnosis of Oral Lichen Planus (OLP) was made. Clinical photographs were taken (*Fig. 1*), and patient was educated about the condition. As the patient had no spontaneous symptoms or active ulceration, no medical management was required, instead he was advised to avoid food triggers and was booked for a review in 8-week time with a plan to do a biopsy for histopathological confirmation of the diagnosis. Furthermore, at this initial presentation there was a suspicion of possible drug reaction to allopurinol as there was a temporal relationship between the use of the allopurinol and the appearance of the cutaneous lesions. Therefore, a letter was sent to the patient's general practice doctor suggesting possible drug reaction and requesting change of medication if suitable alternative was available.

Eight weeks later, patient returned for a review. He was completely asymptomatic and reported complete resolution of the mucocutaneous lesions. He mentioned that allopurinol was stopped by his dermatologist 6 weeks ago, and within two weeks he felt everything was back to normal. Clinical examination revealed significant reduction of the buccal mucosal lesions, with a very faint white reticular striation and two discrete spots of inflammatory hyperpigmentation on the left buccal mucosae. There were no evident lesions on the tongue or the right buccal mucosa (*Fig.2*). Consequently, and due to this significant improvement in the clinical appearance, a decision was made not to proceed with biopsy, clinical photographs were updated (*Fig.2*), and patient was booked for a review after six months.

In the third review, patient continued to be asymptomatic without a need for medical treatment. There were two small areas less than 4mm² of very faint white striation on the posterior buccal mucosa bilaterally adjacent to teeth 37,47 (*Fig.3*) classical of OLP. There were no other areas of keratosis, erythema, ulceration or swelling. Patient was reassured, new clinical photographs taken, and patient was placed on 12 months recall list.

Discussion

Allopurinol is a xanthine oxidase inhibitor that is used for the treatment of gout. The mechanism of action is inhibition of xanthine oxidase, which is an essential enzyme for uric acid formation. Allopurinol is considered as a standard treatment of hyperuricemia associated with gout. It is also used in the treatment of uric acid nephropathy and chemotherapy induced hyperuricemia ⁽²¹⁾. Allopurinol reaches peak plasma concentrations within 30 to 60 minutes; its half-life is 1-3 hours, and 80-90% of the drug is absorbed from the gastrointestinal tract. It is metabolised in the liver and 20% is excreted in faeces ⁽²¹⁾.

Allopurinol is associated with a wide spectrum of side effects and extensive drug interactions, these include vomiting, diarrhea, drowsiness, headache, muscle pain, hypersensitivity reactions, and skin rash. These side effects may develop in 2–5% of patients. The hypersensitivity reactions to allopurinol range from mild form of maculopapular eruptions to severe cutaneous adverse reactions (SCAR), which include Stevens– Johnson syndrome/toxic epidermal necrolysis (SJS/TEN). Those cutaneous reactions may occur even after months or years of starting the medication and have a reported incidence of 0.69 per 1,000 person-years (23, 24).

Compared to cutaneous reactions, OLDR is a rare entity with considerably fewer reported cases and fewer drugs implicated. Cutaneous lesions present as skin eruptions characterized by purplish, pruritic keratotic papules and plaques, while oral lesions are clinically and histopathologically indistinguishable from OLP, and as mentioned earlier may happen months to years after introduction of a new medication (14).

The reduction of uric acid levels in the body after allopurinol therapy and resultant reduction of salivary uric acid may lead to reduction in the Total Antioxidant Capacity (TAC) and enhanced oxidative stress in patients. This provides a potential theory about the pathogenic mechanism implicated in allopurinol hypersensitivity reaction.

Uric acid is a major antioxidant in the body, it is a naturally occurring compound as a product of the metabolic breakdown of purine nucleotides in humans. High levels of uric acid in the body can cause gout, hypertension, or cardiovascular disease. Whereas low uric acid levels may lead to neurodegenerative diseases. Reduced uric acid levels in the body may increase the risk of toxicity caused by reactive oxygen and nitrogen species that form as a result of the inflammation, which in turn can cause oxidative stress tissue damage and endothelial injury (21, 25-27). Moreover, uric acid is the major antioxidant component of whole saliva, and it accounts for 85% of the TAC of saliva (27).

Reactive oxygen and nitrogen species are natural by-products of biochemical reactions and are essential for certain biological process such as cell signalling and haemostasis. These free radicals are released by phagocytes in response to microbial infection and are essential factors in the intracellular killing mechanism. Excess production of free radicals during inflammatory processes can cause damage to tissue and cellular components and have a key role in inflammation mediated carcinogenesis (28).

Recently, few studies have found changes in the salivary antioxidants levels and oxidative stress (OS) markers in OLP patients compared to control groups ^(29, 30), and this may suggest a role of OS in the pathogenesis of OLP. Battino et al. found decreased uric acid and increased gamma-glutamyl transferase (GGT) in the saliva and serum of OLP patients compared to control group ⁽²⁹⁾. While Tvarijonavičiute et al. have found statistically significant increase in the level of Nitric Oxide (NO), nitrites, and C-reactive protein in the saliva of OLP patients in comparison to control group ⁽³⁰⁾. Another study by Totan et al. found significant decrease in salivary and serum uric acid in OLP patients compared to control group, as well as the total TAC of saliva ⁽²⁸⁾.

Other studies have reported significantly low serum and salivary uric acid levels in OLP patients; and decreased uric acid levels with periods of OLP exacerbation when compared to healthy controls ⁽³¹⁻³³⁾. Additionally, there was significant increase in serum uric acid levels after remission of OLP symptoms ⁽³³⁾.

So far, only three cases of allopurinol related OLDR have been reported in the literature ^(14, 15, 22). The three cases were reported in a case series by Chau et al. 1984 from patients who attended the Oral Medicine Department of the Royal Dental Hospital of Melbourne ⁽²²⁾. These patients presented with longstanding ulcerative OLP lesions that were resistant to topical steroid therapy. Stopping allopurinol therapy resulted in timely complete resolution of the ulceration in two patients and considerable clinical improvement in the third case ⁽²²⁾. In these previously reported cases, as well as our herein reported one, stopping allopurinol resulted in significant improvement in the clinical appearance and symptoms, but mild striation and clinical features suggestive of OLP remain. This raises the question of whether these lesions and OLDR are a true allergic reaction to a certain medication with distinct pathophysiology, or the medication potentiated the clinical behaviour of a previously existing asymptomatic disease. In the presented cases, it is unknown if patients had healthy oral mucosa or asymptomatic faint OLP prior to allopurinol therapy. Moreover, allopurinol enhanced oxidative stress and reduction of antioxidant level (uric acid) could be the etiological mechanism involved in the appearance of the oral lichenoid lesions rather than true allergic reaction. This theory previously presented by Lacey et al. 1983 concluded that “Drug-induced OLP ... is probably an amplification by a drug of an existing lichen planus diathesis rather than a specific drug-induced condition with a simple cause-and-effect relationship” ⁽³⁴⁾.

References

1. Al-Hashimi I, Schifter M, Lockhart PB, Wray D, Brennan M, Migliorati CA, et al. Oral lichen planus and oral lichenoid lesions: diagnostic and therapeutic considerations. *Oral Surgery Oral Medicine Oral Pathology Oral Radiology & Endodontics*. 2007;103 Suppl:S25.e1-12.
2. Scully C, Beyli M, Ferreiro MC, Ficarra G, Gill Y, Griffiths M, et al. Update on oral lichen planus: etiopathogenesis and management. *Critical reviews in oral biology and medicine : an official publication of the American Association of Oral Biologists*. 1998;9(1):86-122.
3. Mostafa B, Ahmed E. Prevalence of oral lichen planus among a sample of the Egyptian population. *Journal of clinical and experimental dentistry*. 2015;7(1):e7-e12.
4. Bakhtiari S, Taheri JB, Toossi P, Azimi S, Kawosi Nezhad S. Prevalence of oral lichen planus in Iranian children and adolescents: a 12-year retrospective study. *European archives of paediatric dentistry : official journal of the European Academy of Paediatric Dentistry*. 2017;18(6):419-22.
5. Eisen D, Carrozzo M, Bagan Sebastian J-V, Thongprasom K. Number V Oral lichen planus: clinical features and management. *Oral Diseases*. 2005;11(6):338-49.
6. Carrozzo M, Porter S, Mercadante V, Fedele S. Oral lichen planus: A disease or a spectrum of tissue reactions? Types, causes, diagnostic algorithms, prognosis, management strategies. *Periodontology 2000*. 2019;80(1):105-25.
7. Lopez-Jornet P, Camacho-Alonso F. Quality of life in patients with oral lichen planus. *Journal of evaluation in clinical practice*. 2010;16(1):111-3.
8. Parlatescu I, Tovar M, Nicolae CL, Sfeatcu R, Didilescu AC. Oral health-related quality of life in different clinical forms of oral lichen planus. *Clinical Oral Investigations*. 2019.
9. Khudhur AS, Di Zenzo G, Carrozzo M. Oral lichenoid tissue reactions: diagnosis and classification. *Expert Review of Molecular Diagnostics*. 2014;14(2):169-84.
10. Scully C, El-Kom M. Lichen planus: review and update on pathogenesis. *Journal of Oral Pathology & Medicine*. 1985;14(6):431-58.
11. Ismail SB, Kumar SKS, Zain RB. Oral lichen planus and lichenoid reactions: etiopathogenesis, diagnosis, management and malignant transformation. *Journal of Oral Science*. 2007;49(2):89-106.
12. Cheng Y-SL, Gould A, Kurago Z, Fantasia J, Muller S. Diagnosis of oral lichen planus: a position paper of the American Academy of Oral and Maxillofacial Pathology. *Oral Surgery, Oral Medicine, Oral Pathology and Oral Radiology*. 2016;122(3):332-54.
13. van der Meij EH, van der Waal I. Lack of clinicopathologic correlation in the diagnosis of oral lichen planus based on the presently available diagnostic criteria and suggestions for modifications. *Journal of oral pathology & medicine : official publication of the International Association of Oral Pathologists and the American Academy of Oral Pathology*. 2003;32(9):507-12.
14. McCartan B, McCreary C. Oral lichenoid drug eruptions. *Oral Diseases*. 1997;3(2):58-63.
15. Scully C, Bagan JV. Adverse Drug Reactions in the Orofacial Region. *Critical Reviews in Oral Biology & Medicine*. 2004;15(4):221-39.
16. Chiang C-P, Yu-Fong Chang J, Wang Y-P, Wu Y-H, Lu S-Y, Sun A. Oral lichen planus – Differential diagnoses, serum autoantibodies, hematinic deficiencies, and management. *Journal of the Formosan Medical Association*. 2018;117(9):756-65.
17. Aghbari SMH, Abushouk AI, Attia A, Elmaraezy A, Menshawy A, Ahmed MS, et al. Malignant transformation of oral lichen planus and oral lichenoid lesions: A meta-analysis of 20095 patient data. *Oral Oncol*. 2017;68:92-102.
18. Fitzpatrick SG, Hirsch SA, Gordon SC. The malignant transformation of oral lichen planus and oral lichenoid lesions: a systematic review. *Journal of the American Dental Association (1939)*. 2014;145(1):45-56.
19. Giuliani M, Troiano G, Cordaro M, Corsalini M, Gioco G, Lo Muzio L, et al. Rate of malignant transformation of oral lichen planus: A systematic review. *Oral Dis*. 2019;25(3):693-709.
20. González-Moles MÁ, Ruiz-Ávila I, González-Ruiz L, Ayén Á, Gil-Montoya JA, Ramos-García P. Malignant transformation risk of oral lichen planus: A systematic review and comprehensive meta-analysis. *Oral Oncology*. 2019;96:121-30.
21. Pacher P, Nivorozhkin A, Szabó C. Therapeutic effects of xanthine oxidase inhibitors: renaissance half a century after the discovery of allopurinol. *Pharmacological reviews*. 2006;58(1):87-114.
22. Chau NY, Reade PC, Rich AM, Hay KD. Allopurinol-amplified lichenoid reactions of the oral mucosa. *Oral Surgery, Oral Medicine, Oral Pathology*. 1984;58(4):397-400.
23. Stamp LK, Day RO, Yun J. Allopurinol hypersensitivity: investigating the cause and minimizing the risk. *Nature Reviews Rheumatology*. 2015;12:235.
24. Kim SC, Newcomb C, Margolis D, Roy J, Hennessy S. Severe cutaneous reactions requiring hospitalization in allopurinol initiators: a population-based cohort study. *Arthritis care & research*. 2013;65(4):578-84.

25. Ames BN, Cathcart R, Schwiers E, Hochstein P. Uric acid provides an antioxidant defense in humans against oxidant- and radical-caused aging and cancer: a hypothesis. *Proceedings of the National Academy of Sciences*. 1981;78(11):6858-62.
26. Becker BF. Towards the physiological function of uric acid. *Free Radical Biology and Medicine*. 1993;14(6):615-31.
27. Kutzing MK, Firestein BL. Altered Uric Acid Levels and Disease States. *Journal of Pharmacology and Experimental Therapeutics*. 2008;324(1):1-7.
28. Totan A, Miricescu D, Parlatescu I, Mohora M, Greabu M. Possible salivary and serum biomarkers for oral lichen planus. *Biotechnic & histochemistry : official publication of the Biological Stain Commission*. 2015;90(7):552-8.
29. Battino M, Greabu M, Totan A, Mohora M, Bullon P, Bucur A, et al. Oxidative stress markers in oral lichen planus. *BioFactors*. 2008;33(4):301-10.
30. Tvarijonaviciute A, Aznar-Cayuela C, Rubio CP, Ceron JJ, López-Jornet P. Evaluation of salivary oxidate stress biomarkers, nitric oxide and C-reactive protein in patients with oral lichen planus and burning mouth syndrome. *Journal of Oral Pathology & Medicine*. 2017;46(5):387-92.
31. Bakhtiari S, Toosi P, Samadi S, Bakhshi M. Assessment of Uric Acid Level in the Saliva of Patients with Oral Lichen Planus. *Medical principles and practice : international journal of the Kuwait University, Health Science Centre*. 2017;26(1):57-60.
32. Chakraborti G, Biswas R, Chakraborti S, Sen PK. Altered Serum Uric Acid Level in Lichen Planus Patients. *Indian Journal of Dermatology*. 2014;59(6):558-61.
33. Gupta A, Mohan RPS, Gupta S, Malik SS, Goel S, Kamarthi N. Roles of serum uric acid, prolactin levels, and psychosocial factors in oral lichen planus. *Journal of Oral Science*. 2017;59(1):139-46.
34. Lacy MF, Reade PC, Hay KD. Lichen planus: A theory of pathogenesis. *Oral Surgery, Oral Medicine, Oral Pathology*. 1983;56(5):521-6.

Table 1. Modified WHO diagnostic criteria of OLP and OLL (van der Meij and van der Waal 2003) ⁽¹³⁾

Clinical criteria

- Presence of bilateral, more or less symmetrical lesions
- Presence of a lacelike network of slightly raised grey-white lines (reticular pattern)
- Erosive, atrophic, bullous, and plaque-like lesions are only accepted as a subtype in the presence of reticular lesions elsewhere in the oral mucosa

In all other lesions that resemble OLP but not complete with the aforementioned criteria, the term “clinically compatible with” should be used

Histopathological criteria

- Presence of well-defined band-like zone of cellular infiltration that is confined to the superficial part of the connective tissue, consisting mainly of lymphocytes
- Signs of “liquefaction degeneration” in the basal cell layer
- Absence of epithelial dysplasia

When the histopathological features are less obvious, the term “histopathologically compatible with” should be used

Final diagnosis of OLP or OLL

To achieve a final diagnosis, clinical as well as histopathological criteria should be included.

OLP: a diagnosis of OLP requires fulfillment of both clinical and histopathological criteria.

OLL: the term OLL will be used under the following conditions

- (1) Clinically typical of OLP but histopathologically only “compatible with” OLP
- (2) Histopathologically typical of OLP but clinically only “compatible with” OLP
- (3) Clinically “compatible with” OLP and histopathologically “compatible with” OLP

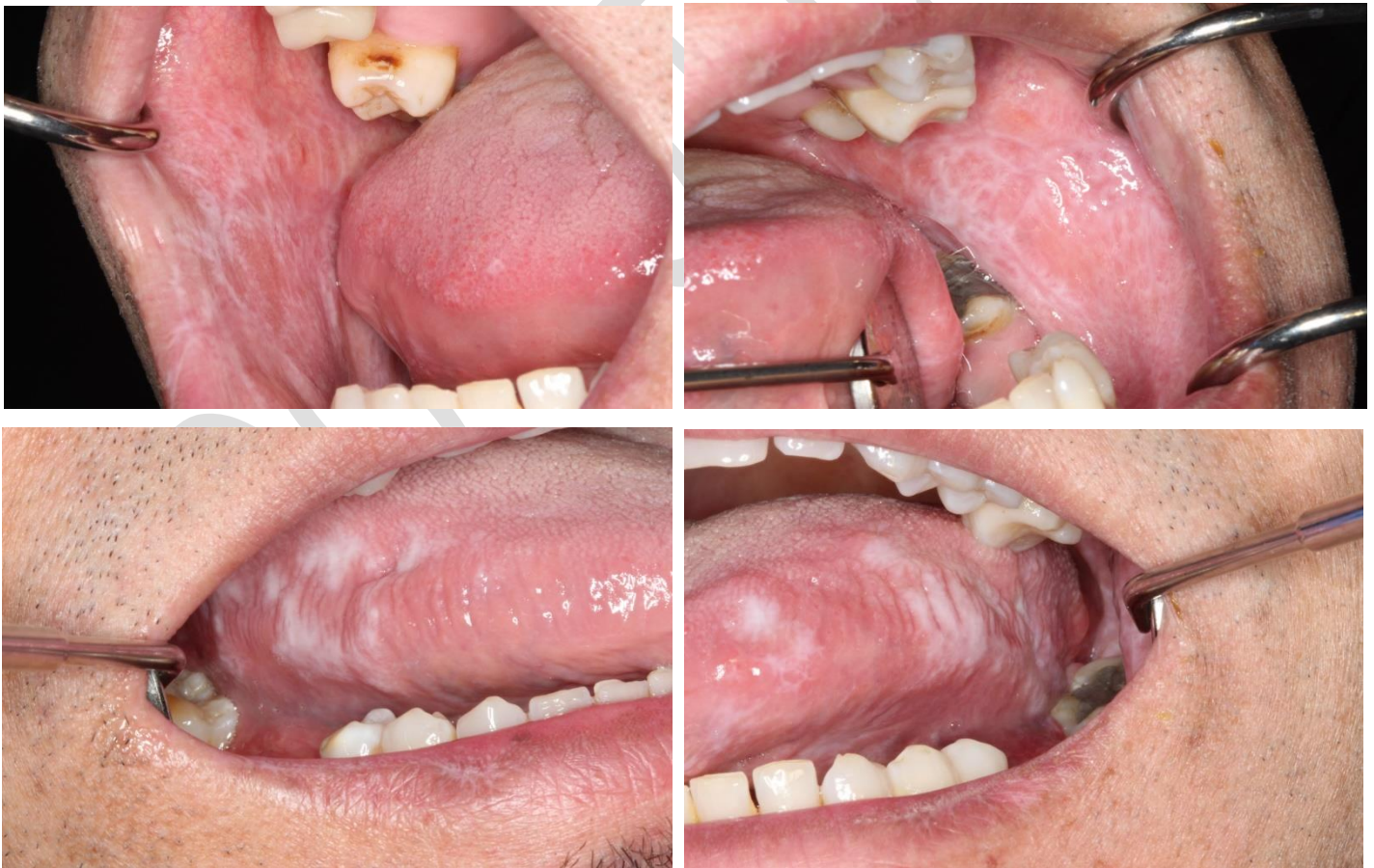

Figure 1. Initial presentation, right and left buccal mucosae and lateral borders of the tongue.

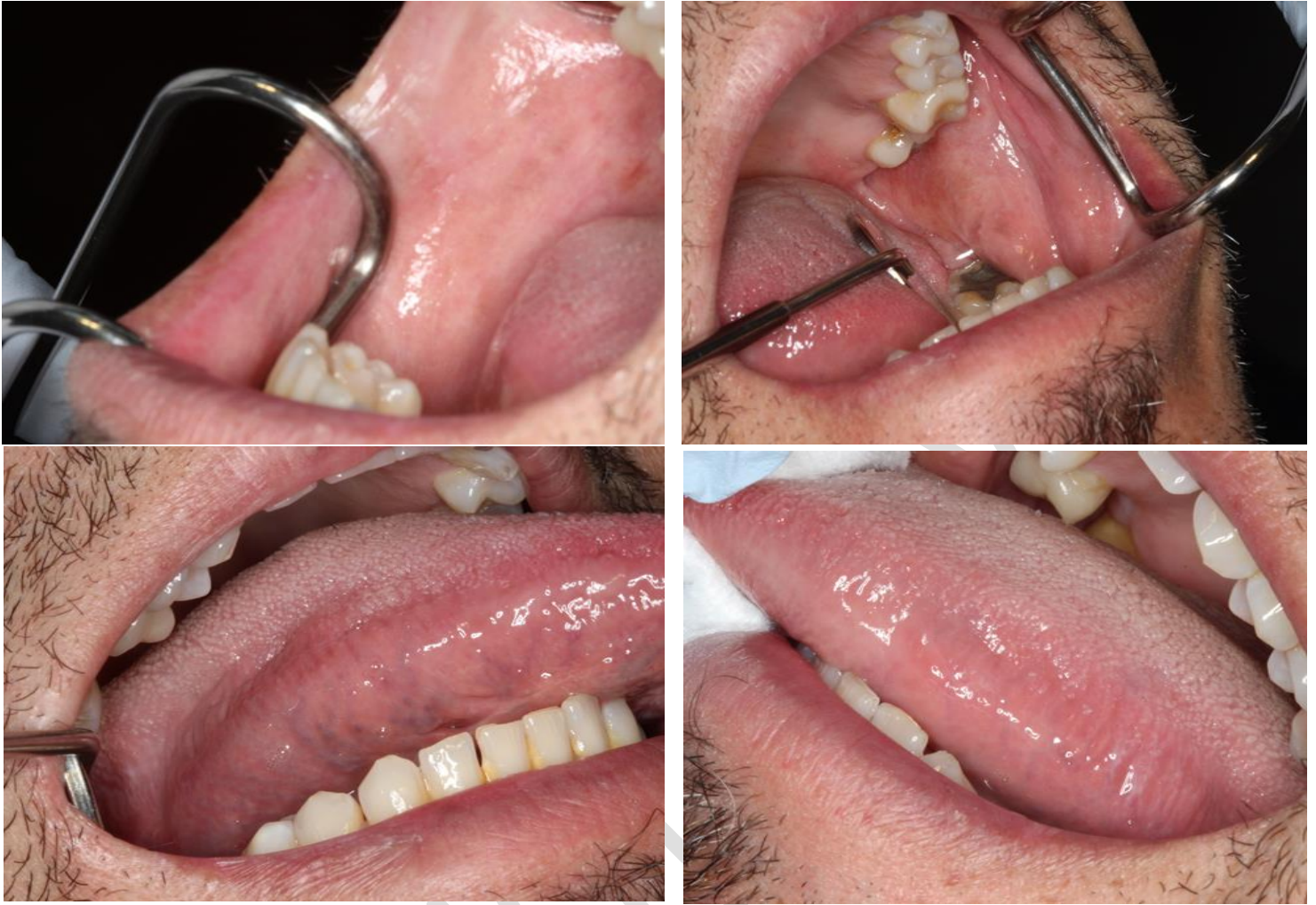

Figure 2. 2-month review, right and left buccal mucosae and lateral borders of the tongue. Faint striation and inflammatory hyperpigmentation on the left buccal mucosa, and complete resolution of tongue lesions.

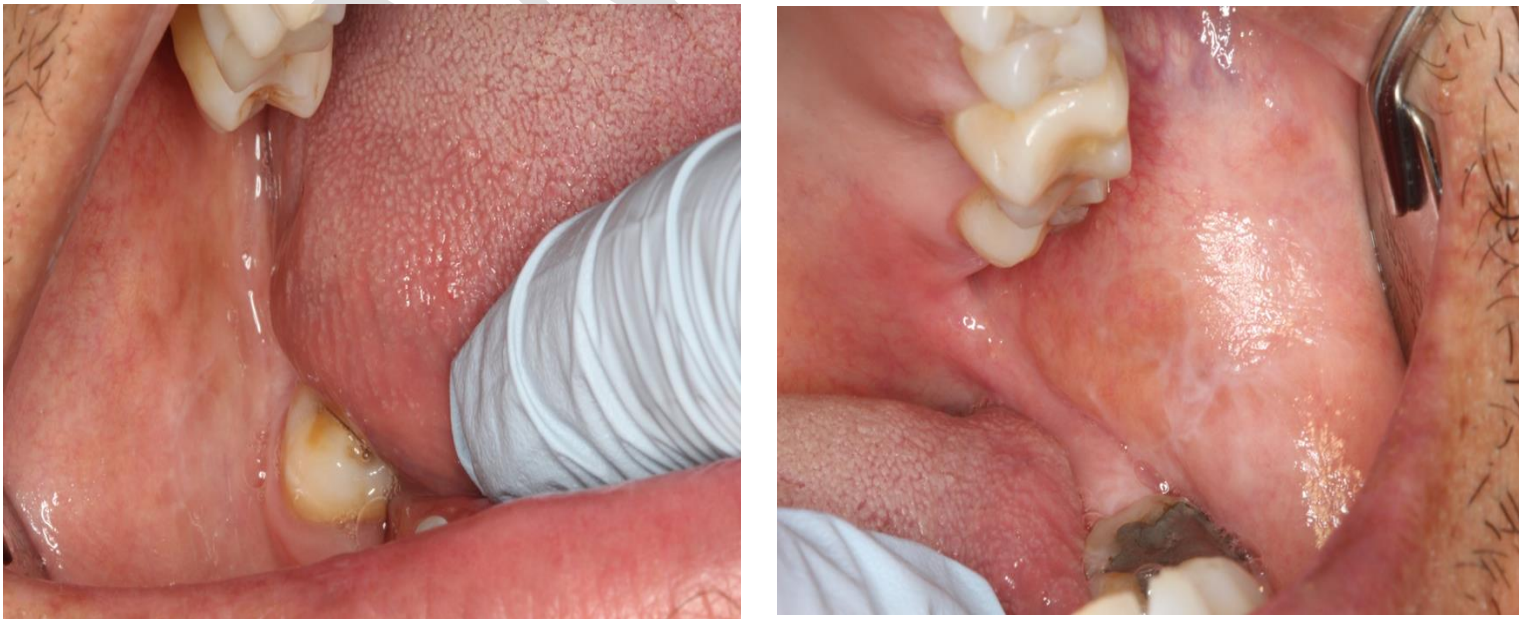


Figure 3. 6-month review, right and left buccal mucosae. Very faint reticular striations classical of OLP.
