



Normal Heart Anatomy

Lorna Carruthers

ACHD NS

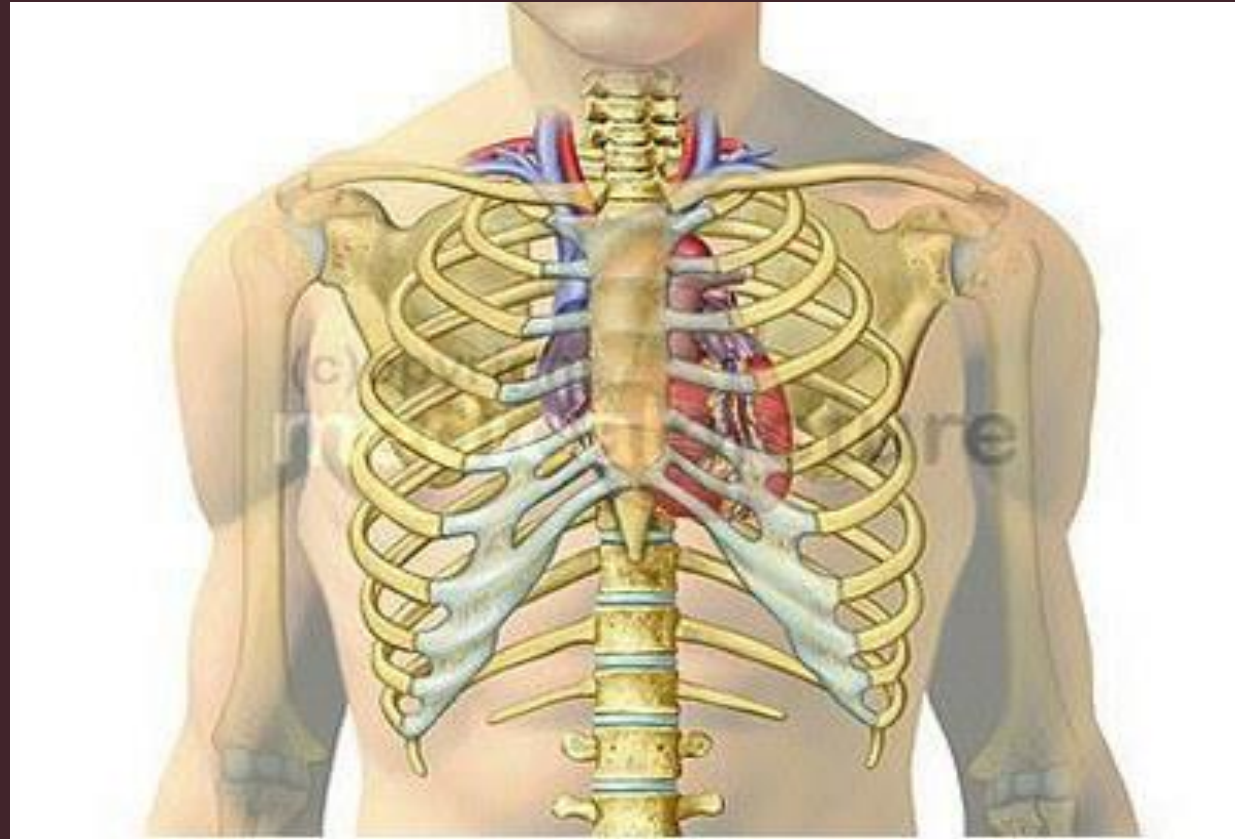
**THE GRANNIES' SCHOOL
FOR ADVANCED
EGG SUCKING**



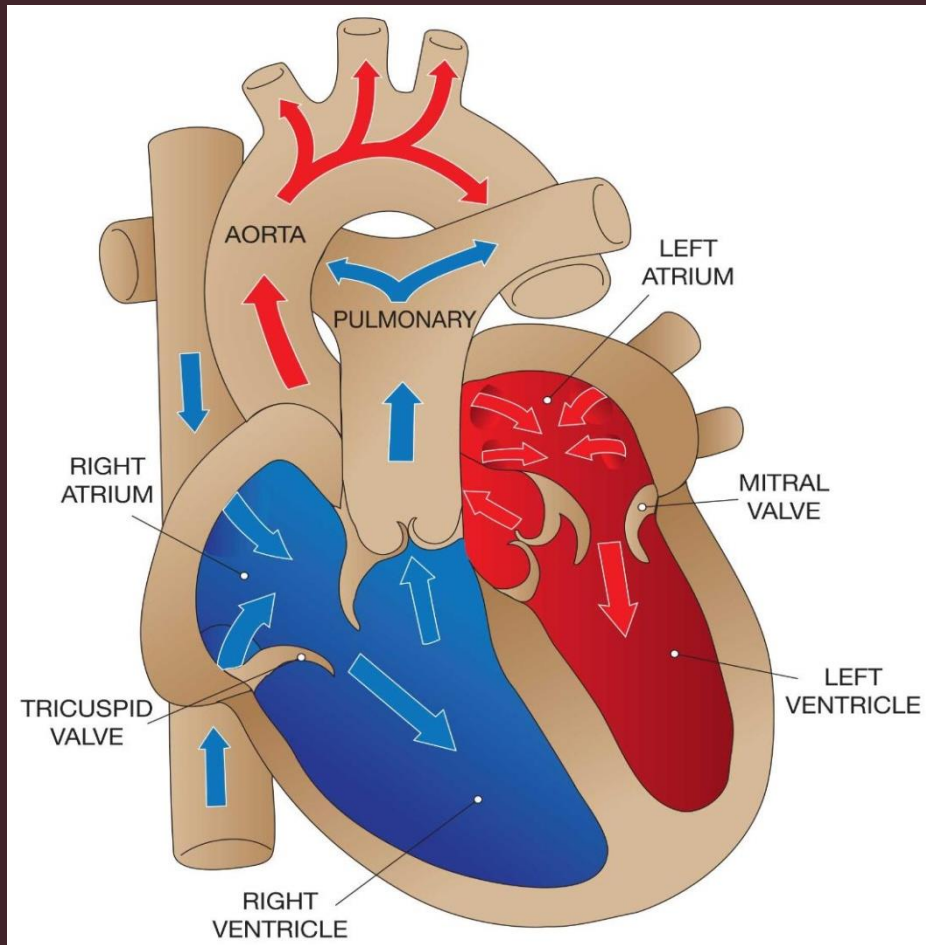
Aim of Session

- Normal Heart Anatomy
- Blood Supply to Heart
- Chambers of the Heart
- Heart Valves

Heart Position

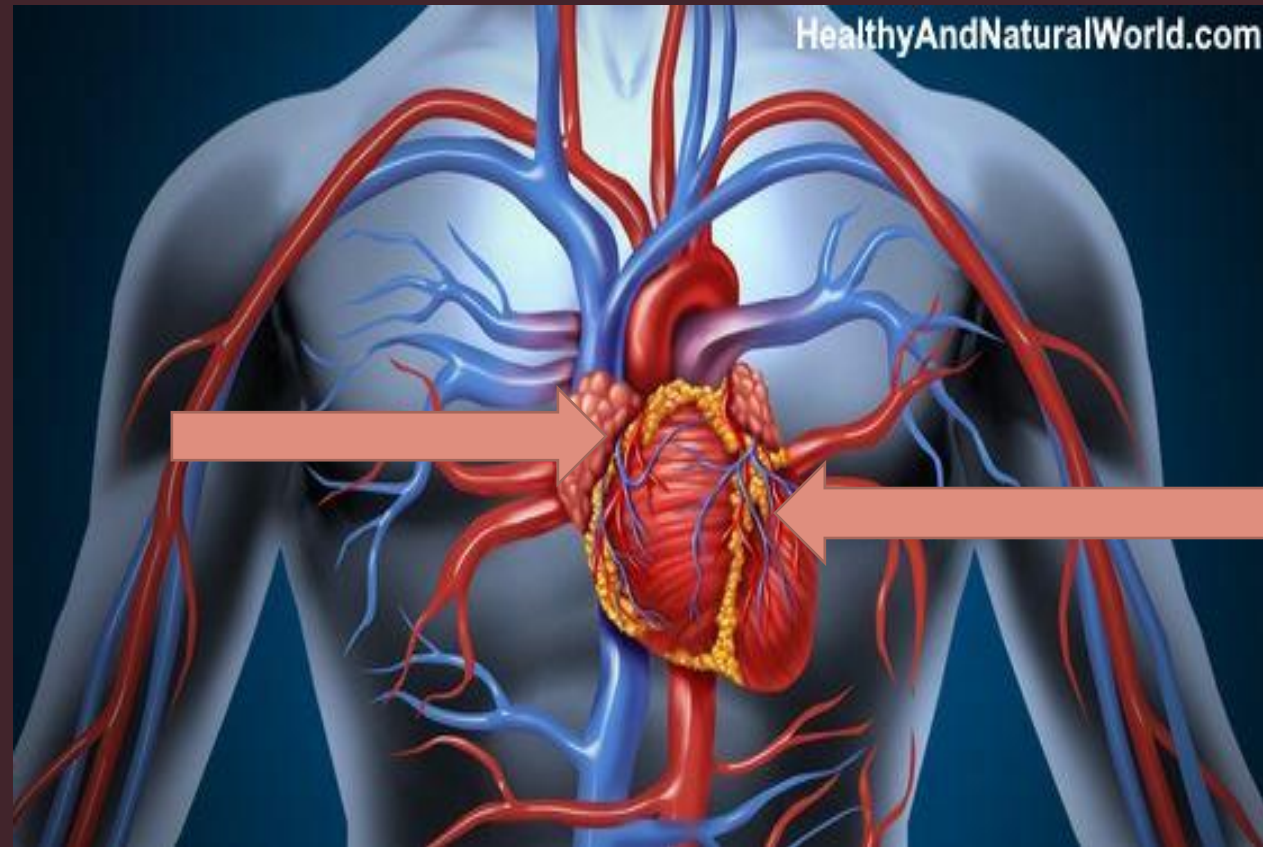


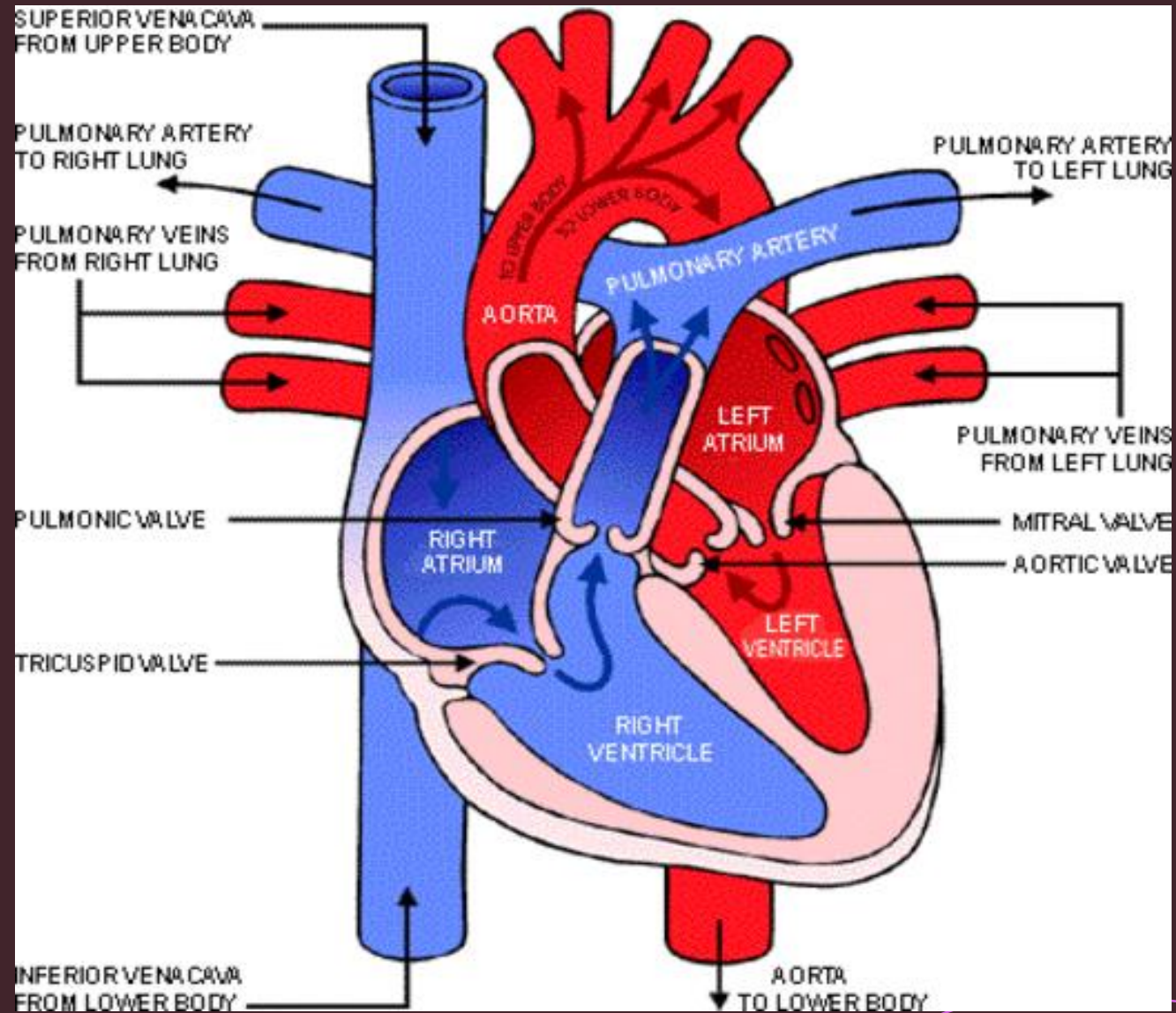
Anatomy & Valves



- Tricuspid valve between right atrium & right ventricle
- Right ventricle pumps to pulmonary valve - Lungs
- Pulmonary veins return blood to left atrium
- Left atrium through mitral valve to left ventricle
- Left ventricle to aortic valve and through aorta round the body

Blood Flow








In Summary

Knowing the normal cardiac anatomy, valve placement and blood flow, will allow you to understand the significance of simple, moderate and complex congenital heart lesions.





Questions?

