

Dynamic Sensorineural Hearing Loss: Implications for Audiologists: Case Reports

James W. Hall III*
Gene W. Bratt*†
Mitchell K. Schwaber*
Jane E. Baer*

Abstract

Although many persons with sensorineural hearing loss (SNHL) seeking hearing care do not have active ear disease, audiologists must appreciate the potentially dynamic and treatable nature of some etiologies of SNHL. This is particularly important now as audiologists are increasingly employed in private practice or other clinical settings that may serve as the point of entry for hearing care. In this paper, we review a variety of clinical entities affecting newborn infants, children, and adults that are associated with dynamic SNHL. Using a case report format, we illustrate treatment-related changes in SNHL, emphasizing the audiologist's role in patient management.

Key Words: Autoimmune disease, ear disease, Meniere's disease, progressive hearing loss, sensorineural hearing loss (SNHL)

According to conventional audiologic wisdom, sensorineural hearing loss (SNHL) is not treatable surgically or medically. For example, in the 1979 edition of his textbook, Newby states that "In contrast to conductive impairments, which are frequently susceptible to medical or surgical treatment, sensorineural hearing loss generally cannot be helped through treatment, with the exception of the loss due to Meniere's disease and sudden, severe deafness. . ." (p. 95). Martin (1991) concurs, noting that "habilitation and rehabilitation of patients with sensorineural hearing losses of cochlear origin is considerably more difficult than that of patients with conductive lesions. Medical or surgical correction is usually obviated by the very nature of the disorder" (p. 316).

In fact, however, there is growing clinical evidence that the SNHL associated with a vari-

ety of diseases may be amenable to medical or surgical treatment (Table 1). Numerous laboratory tests, radiologic studies, and other diagnostic medical procedures are employed in the detection and diagnosis of the clinical entities listed in Table 1. A discussion of these medical procedures is, however, beyond the scope of this paper. Our focus is on the role of audiologic assessment and diagnosis of SNHL. Proper and timely intervention may slow, stop, or, in some cases, reverse the progression of some inner ear disorders and the corresponding SNHL. Although many persons with SNHL seeking hearing care do not have active ear disease (Yaremchuk et al, 1990), audiologists must appreciate the potentially dynamic and treatable nature of SNHL. This is particularly important now as the majority of audiologists are employed in private practice or other clinical settings (American Academy of Audiology, 1992) that may serve as the point of entry for hearing care. In this paper, we review briefly selected clinical entities that may have, as a component, dynamic SNHL. Using a case report format, we illustrate treatment-related changes in SNHL, and the audiologist's role in patient management.

*Division of Hearing and Speech Sciences and Department of Otolaryngology, School of Medicine, Vanderbilt University, Nashville, Tennessee; and †V.A. Medical Center, Nashville, Tennessee

Reprint requests: James W. Hall III, Vanderbilt Balance and Hearing Center, 1500 21st Avenue South, Suite 2600, Nashville, TN 37212-3102

Table 1 Selected Clinical Entities Associated with Dynamic and/or Treatable Sensorineural Hearing Loss (SNHL)

<i>Entity</i>	<i>Characteristics</i>	<i>Medical Treatment</i>	<i>Surgical Treatment</i>	<i>Audiologist's Role</i>
Autoimmune disease	Rapid, progressive SNHL	Steroids, cyclophosphamide, plasmapheresis	None	Detection, audiologic monitoring, amplification
Meniere's disease	Fluctuating SNHL, episodic vertigo, ear fullness, tinnitus	Salt and caffeine restriction, diuretics, vestibular suppressants, aminoglycosides	Endolymphatic sac decompression/shunt, vestibular neurectomy	Neurodx (ABR, ECoChG, vestibular assessment) Intraoperative, vestibular, and audiologic monitoring
Meningitis	Progressive or reversible SNHL	Antibiotics	None	Early detection; audiologic assessment, monitoring, and management
Syphilis	Variable SNHL, some symptoms as in Meniere's disease	Steroids, antibiotics	None	Detection, neurodx, amplification
Otosclerosis	Conductive or apparently mixed hearing loss	Fluoride	Stapedectomy	Pre-, post-operative audiologic assessment
Otosclerosis (cochlear)	Flat SNHL, usual family history	Fluoride, calcium, Vitamin B	None	Detection, amplification
Sudden deafness	Rapid (< 72 hr) SNHL, possible vertigo	Steroids, carbogen, IV contrast media	None	Detection and audiologic monitoring
Perilymph fistula	SNHL, dizziness	Bedrest, stool softeners, cough suppressants	Tympanotomy with fistular grafting	Neurodx
Ototoxic drugs	SNHL, which may progress or reverse	Cessation, or reduction of drugs	None	Early detection; audiologic assessment, monitoring, and management
Head injury	Flat, reversible SNHL	Bedrest	None	Audiologic assessment and monitoring

Adapted with permission from Hicks and Wright, 1991.

CASE REPORTS

Case 1: Meniere's Disease

Clinical Findings

A 65-year-old woman with the chief complaint of recurrent vertigo was referred from an otolaryngologist in an outlying community. She reported a 20-year history of dizzy spells. More recently, the episodes of vertigo occurred approximately once per month without warning and lasted for about 1 hour. Extended periods of medical therapy for relief of her vertigo had been unsuccessful. On physical examination, otoscopic, nose, and throat findings were normal, and no nystagmus was observed. Initial

audiologic assessment (Fig. 1) showed a moderate-to-severe SNHL bilaterally, greater for the left ear. Tympanometry was consistent with slightly negative middle ear pressure. Crossed and uncrossed acoustic reflexes, however, were recorded at normal stimulus intensity levels in dB HL and, actually, very reduced sensation levels (5–25 dB), suggesting a SNHL of cochlear origin.

Auditory brainstem response (ABR) assessment was recommended, in view of very poor word-recognition scores and acoustic reflex decay for the left ear. A well-formed ABR was recorded bilaterally. All interwave latency values were within normal limits and bilaterally symmetrical. There was no evidence of retrocochlear auditory dysfunction. On electro-

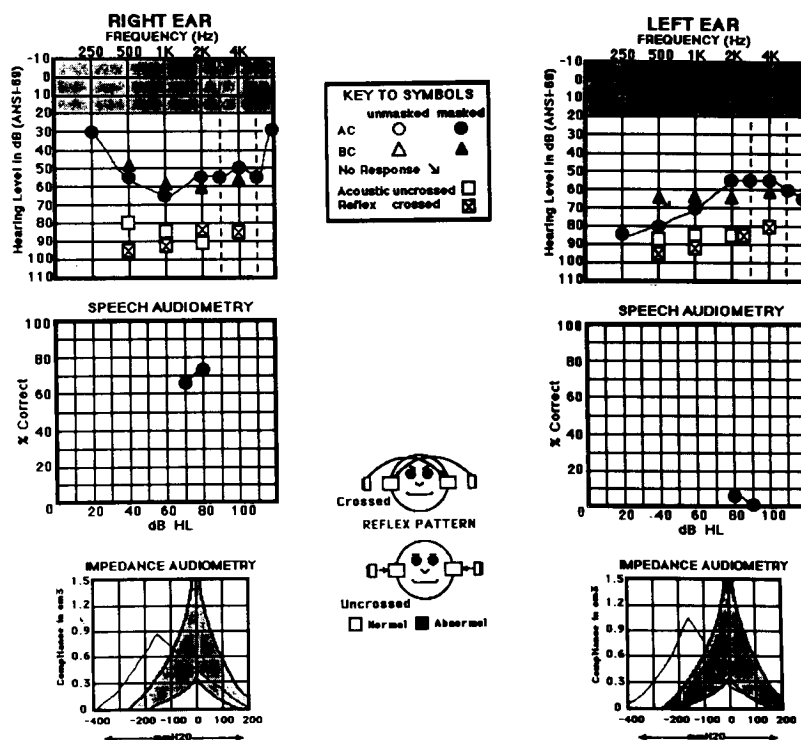


Figure 1 Initial audiogram for 65-year-old female with Meniere's disease (case 1).

cochleography (ECochG), there was a clear summating potential (SP) and action potential (AP) with stimulation of each ear. The SP/AP ratio did not appear enlarged (i.e., greater than 0.5) for either ear. Caloric stimulation during electronystagmography (ENG) produced a left unilateral weakness, consistent with left peripheral vestibular pathology. The diagnosis was left Meniere's disease.

The patient was presented with four surgical options: left endolymphatic sac decompression; left vestibular nerve section (neurectomy); left labyrinthectomy; and also streptomycin infusion. Given the severe degree of hearing loss on the left, and also the possibility of right-sided Meniere's disease involvement, a left labyrinthotomy with streptomycin infusion was recommended for treatment of her vestibular disorder. Hearing preservation was a secondary objective of this essentially medical treatment approach. The patient elected this treatment option.

Two weeks following treatment, her vertigo was much improved, but hearing on the left ear was decreased (Fig. 2). There was no response to pure-tone signals at equipment limits for the left ear, whereas right ear findings were unchanged. One month later (Fig. 2), left ear hearing had improved substantially. The audiometric configuration resembled preoperative findings, although thresholds were approxi-

mately 20 dB poorer. Hearing status thereafter remained essentially unchanged. Amplification was considered.

Comment

Fluctuating SNHL is a characteristic feature of Meniere's disease (Schuknecht and Guyla, 1983). The audiologist is often involved on multiple occasions during the diagnosis and management of patients with Meniere's disease and other vestibular disorders (Schwaber and Hall, 1991, 1992). Involvement usually begins with auditory neurodiagnostic assessment, including routine audiometry and measurement of ECochG, ABR, and otoacoustic emissions, and also vestibular assessment with ENG, rotary vestibular tests, and perhaps other vestibular measures. The audiologist may also monitor the patient's auditory and/or vestibular status during the various types of treatment that are employed for relief of severe vertigo (Schwaber and Hall, 1990, 1991, 1992). Monitoring approaches include serial audiograms during conventional medical therapy, intraoperative ABR and ECochG monitoring during endolymphatic sac decompression or vestibular neurectomy, and a combination of audiograms, otoacoustic emissions, and vestibular measures (e.g., rotary vestibular tests, coupled with ENG, to provide assessment of central compensation),

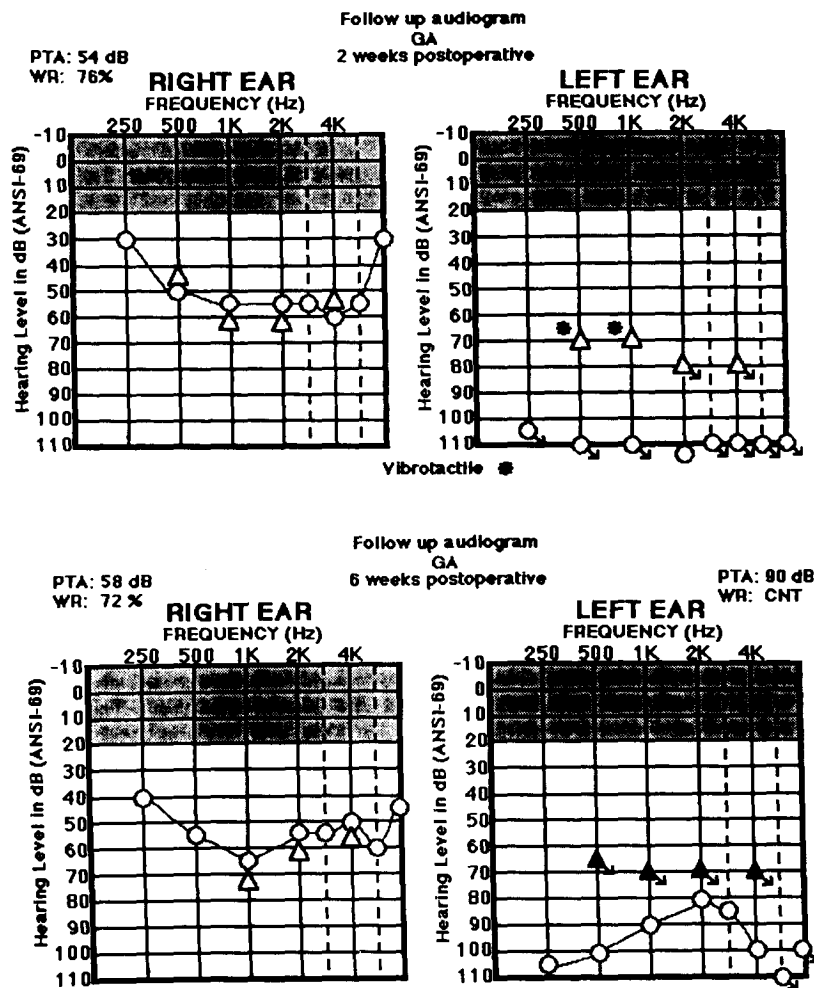


Figure 2 Audiograms for case 1, 2 weeks (top portion) and 1 month (bottom portion) after streptomycin treatment for vertigo.

during chemical (aminoglycoside) ablation of vestibular function (Nedzelski et al, 1992). Finally, if a bilateral, communicatively handicapping hearing impairment persists, the audiologist may select and dispense amplification. The latest digital and programmable hearing-aid technology is particularly appropriate for patients with Meniere's disease, since their hearing loss is likely to fluctuate and their configuration is often difficult to fit with conventional hearing aids.

Case 2: Autoimmune Sensorineural Hearing Loss

Clinical Findings

A 42-year-old male veteran was first evaluated audiologically in 1978 at the age of 28. He reported loss of hearing in the left ear and a slight hearing loss in the right ear following military-related head trauma and temporal bone fracture. History was also positive for military

noise exposure. At that time, there was a moderate-to-severe high-frequency SNHL on the right ear (Fig. 3) and a profound SNHL on the left ear (not shown). The patient was again evaluated within the past year, after reportedly experiencing a sudden decrease in hearing and increased bilateral ringing tinnitus for 2 months. Magnetic resonance imaging was negative for retrocochlear auditory pathology. An audiogram showed a moderate low-to-mid-frequency SNHL in the right ear, sloping to the severe range (Fig. 3). Word-recognition scores were poor. Two days later, ABR assessment with right ear stimulation was within normal limits (normal interwave latencies). Also on this date, pure-tone hearing thresholds and word-recognition scores for the right ear were improved (Fig. 3). Over the course of the next 5 months, the patient repeatedly experienced decreases in hearing thresholds, which were managed with steroid (prednisone) therapy. Reductions in steroid levels were associated with increased hearing loss and vice versa, until hearing was stabilized (Fig. 3). The




Figure 3 Serial audiograms (right ear only) for a male veteran with autoimmune inner ear disease (currently 42 years old). Initial audiogram was obtained 14 years previously (case 2).

patient was then successfully fitted with BICROS amplification and monitored audiologically. Recently, hearing thresholds have begun to fluctuate, and the patient is again under otologic care.

Comment

Autoimmune SNHL is a complex and poorly understood disorder that, within recent years, has been the focus of much basic investigation and clinical interest among otolaryngologists (e.g., McCabe, 1979; Harris and Sharp, 1990; Helfgott et al, 1991; Ruckenstein and Harrison, 1991; Soliman, 1992). The immune system normally functions to protect a person from invading microorganisms (environmental pathogens). To do this, the immune system must, through an intricate sequence of biochemical activities, differentiate between "self" and "nonself" (Harris and Sharp, 1990; Ruckenstein and

Harrison, 1991). Even a cursory explanation of the mechanisms of the immune response is beyond the scope of this paper. An autoimmune reaction occurs when the immune system fails to distinguish between self and nonself. The inner ear is "attacked" by its defense system (e.g., lymphocytes, macrophages, and endolymph immunoglobulin components) as if it were foreign, with resulting inflammation, vasculitis, and disruption of normal physiologic processes. The clinical presentation of autoimmune SNHL, which may occur at any age, is highly variable, but usually includes a bilateral SNHL, which progresses over weeks or months. The SNHL, however, may be asymmetric or even unilateral and may fluctuate. Vestibular symptoms are often, but not invariably, reported.

Immediate recognition of the possibility of autoimmune disease in a patient with bilateral, progressive SNHL and prompt otologic referral

are clearly the most important contributions an audiologist can make to management. Routine audiologic assessment will establish a SNHL, but a thorough history is required to verify the progressive course of the disease. Numerous laboratory tests have been reported for confirmation of suspected autoimmune SNHL, among them tests for cellular immunity, humoral immunity, and nonspecific screening tests for serologic antigens (e.g., Western blot analysis of serum to identify autoantibodies that are directed against inner ear antigens). If one of the immune screen tests is positive, treatment is begun immediately. There is currently no consensus as to the most appropriate medical therapy, but steroids (e.g., dexamethasone), vasodilators, cyclophosphamide, methotrexate, immunosuppressants, and plasmapheresis have all been used clinically. The efficacy of medical therapy for autoimmune disease is also the topic of ongoing research. In any event, there is clear-cut evidence that autoimmune SNHL can be reversed, partially or completely, with prompt diagnosis and appropriately aggressive medical treatment.

Cases 3 and 4: Otosclerosis

Clinical Findings for Case 3

A 70-year-old male veteran complained of

no hearing in the right ear, decreased hearing in the left ear, difficulty discriminating between sounds, and difficulty localizing sounds. He had been aware of a progressive hearing deficit for approximately 40 years. He described long-standing occupational and military noise exposure. The history included left ear trauma and an abscess with a perforation that healed, but no prior ear infections, drainage, or surgery. The ear examination was unremarkable.

Initial audiologic assessment (Fig. 4) revealed a moderate, sloping, apparently SNHL in the left ear and a severe mixed hearing loss in the right ear. Bone-conduction thresholds in the right ear were in the 60 to 70 dB range. Tympanograms were type A bilaterally, although slightly shallower in the right ear. Crossed acoustic reflexes were not observed, and uncrossed acoustic reflexes were not measured. Word-recognition scores were good (92%) for the left ear and poor (24%) for the right ear. Two weeks later, the patient underwent a stapedectomy on the right ear. The postoperative audiogram showed a marked improvement (40–45 dB) in air-conduction thresholds, but also a 10 to 20 dB improvement for bone-conduction thresholds. Results for the right ear only are displayed in Figure 5.

Clinical Findings for Case 4

The patient was a 32-year-old woman with

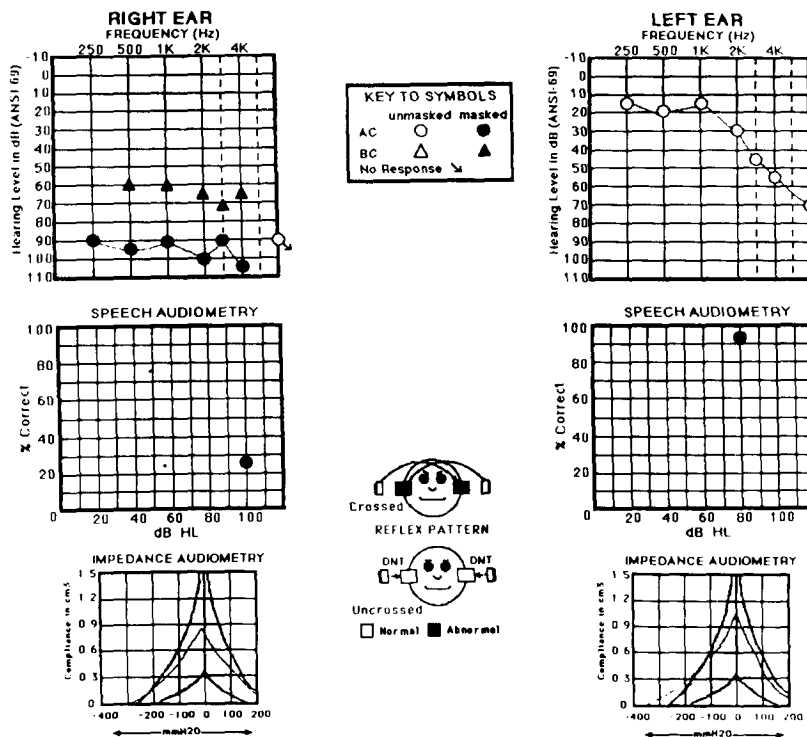


Figure 4 Initial audiogram for a 70-year-old male veteran with stapedial otosclerosis (case 3).

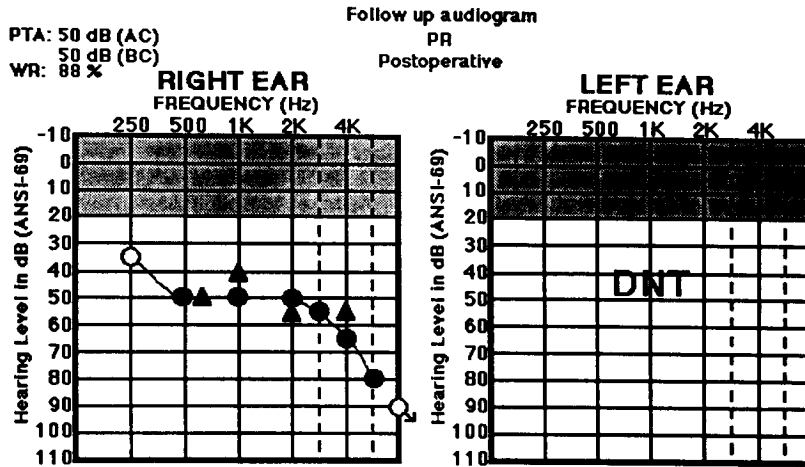


Figure 5 Postoperative audiogram for case 3.

a history of gradually progressive hearing loss in both ears, greater on the left ear. Otoloscopic findings were normal. Her initial audiogram (Fig. 6) showed a severe, apparently mixed hearing loss bilaterally. Bone-conduction thresholds were abnormal, but the masking dilemma precluded complete bone-conduction pure-tone audiometry. The sensorineural acuity level (SAL) test confirmed ear-specific bone-conduction findings for the left ear. On immittance measurement, tympanograms were type A_s and no acoustic reflexes were observed. The diagnosis was stapedial otosclerosis, and the patient elected to undergo a small fenestra stapedectomy on the left. Gross fixation and obliteration of the

stapes footplate were documented during surgery. A 4.5-mm Causse prosthesis (0.6 mm in diameter) was attached to the incus, inserted into the vestibule, and secured with bits of fascia. Palpation showed good movement of the ossicular prosthesis. Postoperatively, the patient experienced some nausea but was otherwise in satisfactory condition.

The first postoperative audiogram, obtained 1 week after surgery, revealed an approximately 20 dB decrease in air- and bone-conduction thresholds on the left ear, mostly in the low-frequency region (top portion of Fig. 7). A masking dilemma was again encountered during bone-conduction pure-tone measurement, but

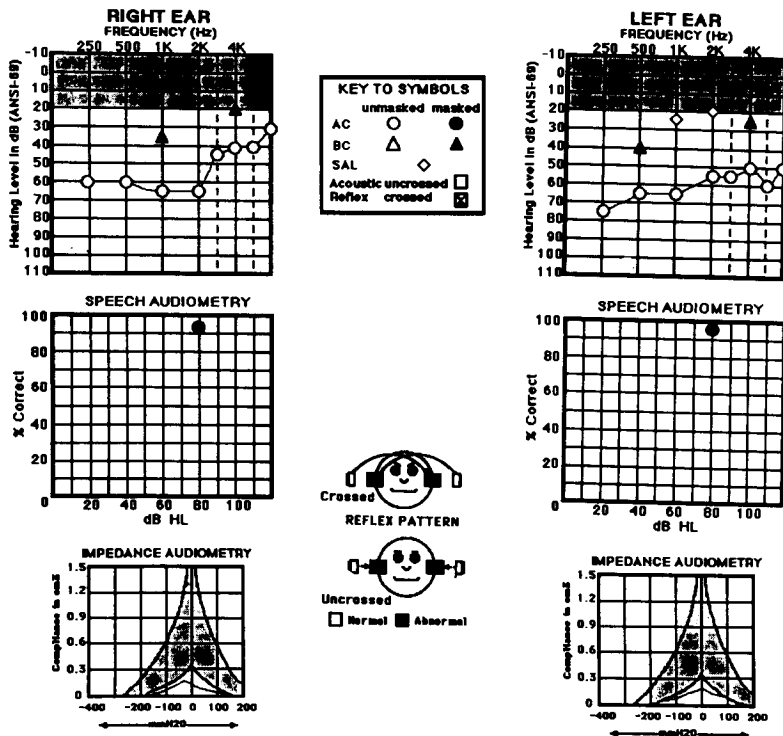


Figure 6 Initial audiogram for a 32-year-old female with stapedial otosclerosis (case 4).

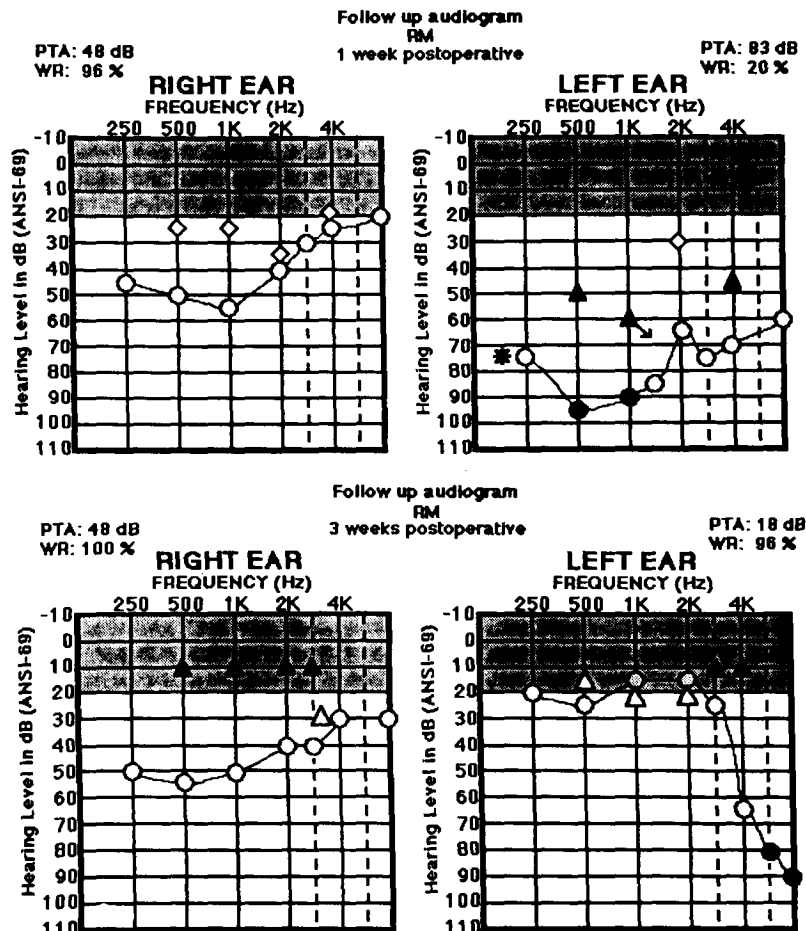


Figure 7 Audiogram recorded after stapedectomy (top portion) and after revision surgery with removal of granulation tissue (bottom portion) for case 4.

the SAL test confirmed ear-specific bone-conduction responses on the left. Word-recognition score was also markedly decreased post-operatively. The patient had, over the previous 2 days, experienced vertigo and noticed decreased hearing on the left. The patient was admitted to the hospital and, on the following day, treated with antibiotics and steroids and taken back to the operating room. A large, granulomatous reaction to the prosthesis was noted. The granulation tissue was carefully removed from the incudostapedial and footplate region. The former prosthesis was then replaced with a 4.0-mm Robinson prosthesis. The patient tolerated the procedure well. An audiogram 2 weeks after this second surgical procedure (bottom portion of Fig. 7) showed hearing sensitivity within normal limits through 2000 Hz and a severe hearing loss at frequencies of 4000 Hz and above. Word recognition was excellent.

Comment

Otosclerosis of the stapes footplate is an ear disease with clinical features that are readily

recognized by most audiologists (Hall and Ghorayeb, 1991). The characteristic audiometric pattern is a conductive hearing loss with a rising configuration and a slight, but distinct, decrease in the hearing threshold level at 2000 Hz ("Carhart's notch"). Immittance measurement typically shows a normally shaped but shallow (type A_s) tympanogram, with no detectable acoustic reflex activity (crossed or uncrossed) with the probe in the involved ear.

A sensorineural component, however, may also be a feature of otosclerosis involving the stapes footplate. The relationship between middle ear and cochlear mechanics, especially in pathologic ears, has been appreciated and investigated experimentally and clinically for many years. Stapes footplate immobility and mechanical restriction of perilymph can affect cochlear function and produce an apparent deficit in bone-conduction pure-tone thresholds. After a series of experiments, for example, Tonndorf (1964) noted that "a combination of a large mass adhering to the stapes (e.g., a so-called 'iceberg' otosclerotic focus of the footplate) if associated with minimal fixation may

produce a BC loss which clinically may be interpreted as being indicative of a diminished 'cochlear reserve' and thus be considered a contraindication to surgery" (p. 661). With surgical reconstruction of the ossicular chain, particularly an improvement in mobility at some point on the stapes footplate, cochlear fluids are "released" and bone-conduction pure-tone thresholds improve. In addition, the osseotympanic component of bone-conduction hearing is probably restored by the surgery. That is, the acoustical energy in the medial ear canal, produced by vibration of the bony ear canal walls in that portion of the ear canal, is transduced to mechanical energy and transmitted more effectively through the middle ear system after the surgery. Surgery may also restore, to some extent, the ossicular inertia contribution to bone-conduction hearing.

Decisions on whether surgical or nonsurgical (e.g., fluorical) management of otosclerosis is most appropriate depend, in part, on accurate definition of bone-conduction, as well as air-conduction, thresholds. It would be ideal if bone-conduction measurement were minimally influenced by middle ear status. As illustrated by cases 2 and 3, however, conventional bone-conduction audiometry may overestimate the degree of sensorineural component and underestimate the size of the air-bone gap in otosclerosis. In some cases, bone-conduction hearing status appears to be reflected more accurately by the sensory acuity level (SAL) test than conventional bone-conduction technique. When a patient presents with a modest air-bone gap by pure-tone audiometry and appears to be a candidate for amplification, but the air-bone gap is accompanied by immittance findings that are consistent with otosclerosis (type A_s tympanograms and absent acoustic reflexes), the audiologist should defer a hearing aid consultation and fitting pending otologic consultation. Failure to do so in such cases may deny the patient the possibility of improved hearing through medical or surgical therapy. Amplification may, of course, still remain the management of choice for the hearing impairment.

Case 5: Head Injury

Clinical Findings

A 23-year-old male college student was involved in an altercation, fell backward, and struck his head at the occiput. He lost consciousness briefly. He then complained of a headache

in the right frontoparietal region and bilateral tinnitus. One day after the accident, he also experienced nausea and vomiting. Physical examination of the ear was unremarkable, with no evidence of hemotympanum or other signs of trauma-related otologic pathology. On a high-resolution computerized tomography (CT) scan of the temporal bone, there was evidence of a fracture on the left side, but the right side appeared normal, yet the patient's initial audiogram 2 days post injury (Fig. 8) showed a severe, flat sensorineural hearing loss on the right and a mild, rising sensorineural hearing loss on the left ear. Middle ear function was normal by immittance measurement. The diagonal pattern of acoustic reflex abnormality was consistent with severe sensory hearing loss on the right. The word-recognition score on the right was poor. Auditory evoked responses (auditory brainstem, middle latency, late, and P300 responses) recorded on the same day (not shown) were normal. Over the course of the next 3 weeks, there was a gradual improvement in pure-tone hearing threshold levels and word-recognition scores on the right ear (Fig. 9). Synthetic sentence identification (SSI) performance (ipsilateral mode, MCR = 0 dB) also improved over this time period. There was no further change in hearing status after the testing at 21 days post injury (bottom portion of Fig. 9).

Comment

Head injury, with or without temporal bone fracture, may produce a variety of audiometric patterns, ranging from normal hearing to profound SNHL (Schuknecht, 1974; Ghorayeb et al, 1987; Hall, 1988). As illustrated by this case, there is not always a direct link between CT evidence of temporal bone fracture and audiologic findings. That is, hearing may remain normal on the side with temporal bone fracture, if the middle ear, cochlea, and eighth nerve are spared. Conversely, hearing may be severely affected on the side without temporal bone fracture. The mechanism in such cases may be soft tissue (membranous labyrinth) damage—a "cochlear concussion." With spontaneous repair of the labyrinthine structures and at least partial restoration of cochlear physiologic processes, SNHL may be reversed. For case 5, serial audiometry documented a gradual improvement in sensory hearing status over the course of weeks after head injury. In patients with bilateral trauma-related hearing loss, audiologic management,

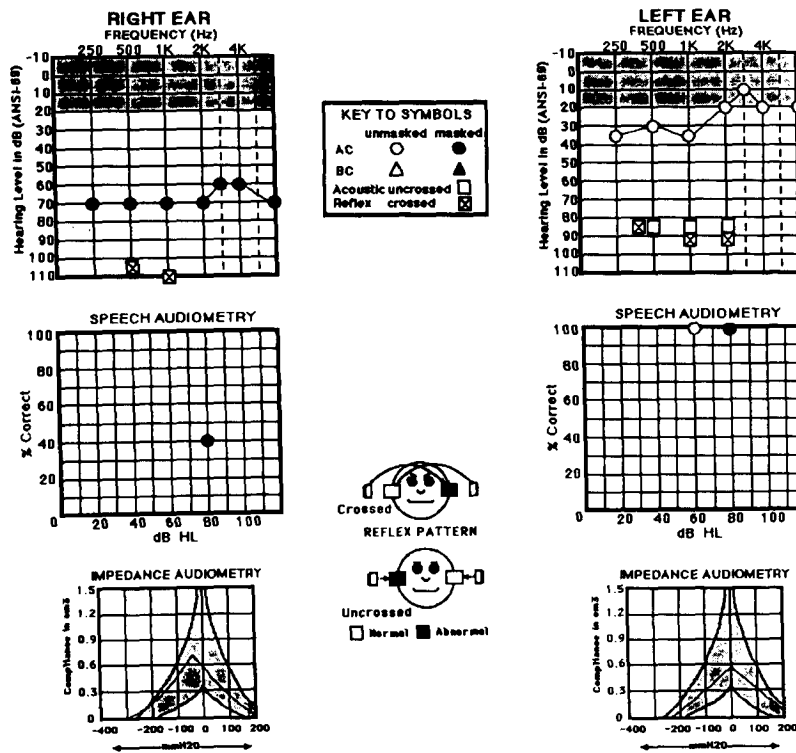


Figure 8 Initial audiogram for a 23-year-old male 2 days after head injury (case 5). CT scan showed a temporal bone fracture on the left side and no evidence of fracture on the right side.

including hearing-aid fitting, should be deferred until hearing appears stable. Since, however, additional changes in sensorineural status may occur even months after an injury (Hall, 1988), a flexible hearing-aid strategy should be employed.

CONCLUSIONS

In this paper, we review a variety of clinical entities that are associated with dynamic SNHL, that is, hearing loss that progressively worsens without treatment or improves with treatment. These etiologies are not always entirely distinct or mutually exclusive. For example, immune complex abnormalities have been reported in patients with Meniere's disease and otosclerosis (e.g., Hughes et al, 1983; Helfgott et al, 1991), and obstruction of the vestibular aqueduct in otosclerosis may lead to endolymphatic hydrops and Meniere's disease (Schuknecht and Gulya, 1983; Yoon et al, 1990). In addition, immune responses may contribute to protection of the cochlea from viral causes of SNHL, such as cytomegalovirus (Harris, 1989), yet an overly strong immune response, while adequately combating the pathogen (e.g., syphilis), may go on to produce a progressive SNHL (Harris, 1989). The listing of clinical entities in Table 1 is certainly not complete. Subgroups of some of these disease classifications exist. Par-

tial or complete reversal of SNHL with treatment may occur in a variety of autoimmune diseases, such as Behçet's disease (Elidan et al, 1991), polyarteritis nodosa, systemic lupus erythematosus, and Cogan's disease (Harris and Sharp, 1990). And there are recent reports that SNHL secondary to vascular lesions can also be reversed with medical and surgical therapy (Weidner et al, 1990).

The dynamic SNHL encountered in newborn infants and young children may pose an especial challenge to prompt, yet rational, audiologic management. Several risk criteria for hearing impairment in infants and children, as defined by the 1990 Joint Committee on Infant Hearing (Joint Committee, 1991), are associated with progressive or, less often, reversible SNHL. Among them are bacterial meningitis, hyperbilirubinemia, congenital and perinatal infection (e.g., cytomegalovirus, syphilis, and toxoplasmosis), and ototoxicity. Hearing loss related to ototoxicity may, in fact, progress for weeks and even months after drugs are no longer detectable in the blood (Hall et al, 1985, 1986, 1987; Hall, 1992). Conversely, however, there is also long-standing evidence in adult humans (Hawkins, 1959; Fee and Stanford, 1980) that sensory (cochlear) hearing impairment due to aminoglycoside ototoxicity may, likewise within weeks or months, reverse after the drugs are discontinued. More recently, re-

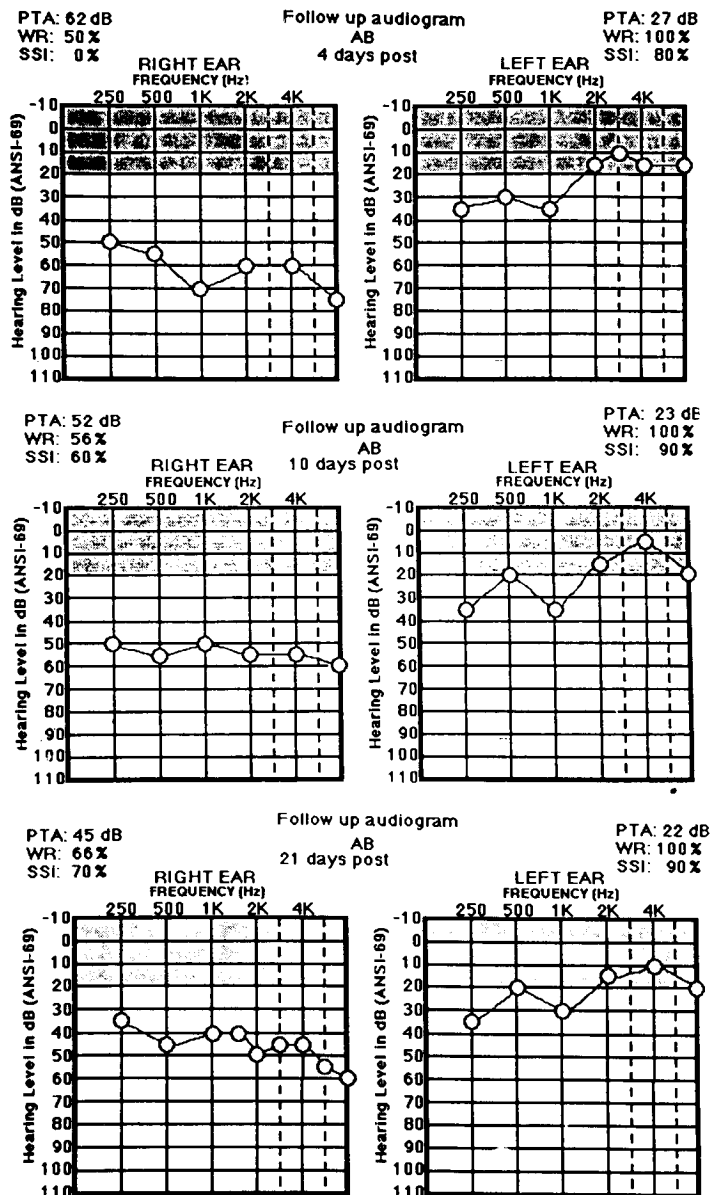


Figure 9 Serial post injury audiograms for case 5.

versible drug-induced SNHL in guinea pigs and in newborn infants was also reported for neonates (e.g., Colding et al, 1989; Nicol et al, 1992).

One of the most exciting reports within the past few years is evidence, in newly hatched chicks, that gentamicin-induced sensory hearing loss, which first progresses to include the entire frequency region, may then over the course of weeks reverse, and hearing may show almost complete recovery (Girod et al, 1991). Auditory status in these and related studies by the authors was documented with ABRs. Remarkably, return of hearing in these studies is related to cochlear hair cell regeneration. Hearing impairment associated with drugs may have a central as well as a cochlear component. Lippe

(1991) demonstrated a decrease and then a recovery of auditory brainstem (cochlear nucleus) cell area within 40 days following aminoglycoside toxicity. These central auditory nervous system changes are probably related to decreased and then increased spontaneous and evoked activity of afferent fibers in the eighth nerve, which, in turn, was related to aminoglycoside-induced changes (loss and regeneration) of cochlear hair cells. These exciting findings have important implications for early detection and appropriately aggressive audiologic and medical management of drug-induced sensorineural hearing loss in infants and young children.

Which audiologic procedures are optimal for rapid, cost-effective, and accurate descrip-

tion of sensorineural auditory dysfunction? Currently, most clinicians continue to rely on air- and bone-conduction pure-tone audiometry, speech threshold measurement, aural immitance measurement (tympanometry and acoustic reflexes), and a simple measure of word recognition. This rather traditional basic audiologic test battery, however, is likely to undergo radical revision before the end of the century. Advances in technology and techniques, such as the emergence of transient and distortion product-evoked otoacoustic emissions, the expansion of compact disc (CD) speech audiometry materials, and algorithms for computer-assisted auditory evoked response recording and analysis, permit for the first time the potential for comprehensive, precise, and very rapid assessment of peripheral auditory function in virtually all patient populations. Such advances, coupled with major changes in the principles of health care delivery, are sure to exert an effect on the day-to-day audiologic assessment of sensorineural hearing loss.

Patients with the chief complaint of hearing loss (which, by audiometry, is symmetric with no consistent conductive component) who, by history, have no other otologic symptoms (e.g., dizziness, ear pain, tinnitus), are unlikely to have ear disease. The majority of these patients have SNHL that is not amenable to medical or surgical treatment (Yaremchuk et al, 1990). In this paper, we review selected clinical entities associated with SNHL that may respond to otologic intervention. The audiologist must always attempt to minimize the rate of false negative clinical management decisions, that is, the failure to refer patients with active ear disease for otolaryngologic evaluation. Toward this end, the audiologist is well advised to always consider the possibility of dynamic and treatable SNHL in the interpretation of a patient's history and hearing test findings.

Acknowledgment. Cases reported in this paper were presented at weekly Vanderbilt Audiology Clinical Conferences, June–December, 1992.

REFERENCES

American Academy of Audiology. (1992). Academy profile. *Audiology Today* 4(1):14–15.

Colding H, Andersen AE, Prytz S, Wulffsberg H, Andersen GE. (1989). Auditory function after continuous infusion of gentamicin to high-risk newborns. *Acta Paediatr Scand* 6:840–843.

Elidan J, Levi H, Cohen E, BenEzra D. (1991). Effect of cyclosporine A on the hearing loss in Behçet's disease. *Ann Otol Rhinol Laryngol* 100:464–468.

Fee WE, Stanford F. (1980). Aminoglycoside ototoxicity in the human. *Laryngoscope* 90:1–19.

Ghorayeb BY, Yeakley JW, Hall JW III, Jones EB. (1987). Unusual complications of temporal bone fractures. *Arch Otolaryngol Head Neck Surg* 113:749–753.

Girod DA, Tucci DL, Rubel EW. (1991). Anatomical correlates of functional recovery in the avian inner ear following aminoglycoside ototoxicity. *Laryngoscope* 101:1139–1149.

Hall JW III. (1988). Auditory evoked responses in acute brain-injured children and adults. *Am J Otol* 9 (Suppl): 36–46.

Hall JW III. (1992). *Handbook of Auditory Evoked Responses*. Needham Heights, MA: Allyn & Bacon.

Hall JW III, Brown DP, Mackey-Hargadine J. (1985). Pediatric applications of serial auditory brainstem and middle latency measurements. *Int J Pediatr Otorhinolaryngol* 9:201–218.

Hall JW III, Fletcher SA, Winkler JB. (1987). Pediatric auditory brainstem responses in intensive care units. *Semin Hear* 8:103–114.

Hall JW III, Ghorayeb B. (1991). Middle ear disease and conductive hearing loss. In: Jacobson JT, Northern JL, eds. *Diagnostic Audiology*. Needham Heights, MA: Allyn & Bacon.

Hall JW III, Winkler JB, Herndon DN, Gary LB. (1986). Auditory brainstem response in young burn wound patients treated with ototoxic drugs. *Int J Pediatr Otorhinolaryngol* 9:201–218.

Harris JP. (1989). Autoimmunity of the inner ear. *Am J Otol* 10:193–195.

Harris JP, Sharp PA. (1990). Inner ear autoantibodies in patients with rapidly progressive sensorineural hearing loss. *Laryngoscope* 100:516–524.

Hawkins JE Jr. (1959). The ototoxicity of kanamycin. *Ann Otol Rhinol Laryngol* 68:698–715.

Helfgott SM, Mosciski RA, Martin JS, Lorenzo C, Kieval R, McKenna M, Nadol J, Trentham DE. (1991). Correlation between antibodies to type II collagen and treatment outcome in bilateral progressive sensorineural hearing loss. *Lancet* 337:387–389.

Hicks GW, JW Wright III. (1991). Treatment of sensorineural hearing loss. *Indiana Medicine* (August):540–544.

Hughes GB, Kinney SE, Barna BP, Calabrese LH. (1983). Autoimmune reactivity in Meniere's disease: a preliminary report. *Laryngoscope* 93:410–417.

Joint Committee on Infant Hearing. (1991). 1990 Position Statement. *Audiology Today* 3:14–17.

Lippe WR. (1991). Reduction and recovery of neuronal size in the cochlear nucleus of the chicken following aminoglycoside intoxication. *Hear Res* 51:193–202.

Martin FN. (1991). *Introduction to Audiology*. 4th ed. Englewood Cliffs, NJ: Prentice-Hall.

McCabe B. (1979). Autoimmune sensorineural hearing loss. *Ann Otol Rhinol Laryngol* 88:585-589.

Nedzelski JM, Schessel DA, Bryce GE, Pfeiderer AG. (1992). Chemical labyrinthectomy: local application of gentamicin for the treatment of unilateral Meniere's disease. *Am J Otol* 13:18-22.

Nicol KMM, Hackney CM, Evans EF, Pratt SR. (1992). Behavioral evidence for recovery of auditory function in guinea pigs following kanamycin administration. *Hear Res* 61:117-131.

Newby HA. (1979). *Audiology*. 4th ed. Englewood Cliffs, NJ: Prentice-Hall.

Ruckenstein MJ, Harrison RV. (1991). Autoimmune inner ear disease: a review of basic mechanisms and clinical correlates. *J Otolaryngol* 20:196-203.

Schuknecht HF. (1974). *Pathology of the Ear*. Cambridge, MA: Harvard University Press.

Schuknecht HF, Gulya AJ. (1983). Endolymphatic hydrops: an overview and classification. *Ann Otol Rhinol Laryngol* 92:1-20.

Schwaber MK, Hall JW III. (1990). A simplified approach for transtympanic electrocochleography (ECochG). *Am J Otol* 11:260-265.

Schwaber MK, Hall JW III. (1991). Intraoperative monitoring of facial and cochleovestibular nerves: II. Cochleovestibular nerves. *Insights in Otolaryngology* 6(6):1-8.

Schwaber MK, Hall JW III. (1992). Cochleovestibular nerve compression syndrome: I. Clinical features and audiovestibular findings. *Laryngoscope* 102:1020-1029.

Soliman AM. (1992). Immune-mediated inner ear disease. *Am J Otol* 13:575-589.

Tonndorf J. (1964). Animal experiments in bone conduction: clinical conclusions. *Ann Otol Rhinol Laryngol* 73:659-678.

Weidner DJ, Kuo A, Spiegel PK, Musiek FE. (1990). Objective tinnitus of vascular origin with hearing improvement after treatment. *Am J Otol* 11:437-443.

Yaremchuk K, Schmidt J, Dickson L. (1990). Entry of the hearing impaired into the health care system. *Henry Ford Hosp Med J* 38:13-15.

Yoon TH, Paparella MM, Schachern PA. (1990). Otosclerosis involving the vestibular aqueduct and Meniere's disease. *Otolaryngol Head Neck Surg* 103: 107-112.