



Diagnosis and Surgical Management of a Traumatic Temporal Artery Pseudoaneurysm



Karishma Setia, BS¹ Ayesha Farooq, MD¹ Michael F. Amendola, MD MEHP FACS FSVS ^{1,2} Kedar Lavingia, MD FACS FSVS ^{1,2}

1. Virginia Commonwealth University School of Medicine, Richmond, Virginia 2. Central Virginia VA Health System, Richmond, Virginia

Introduction

- A pseudoaneurysm is a focal widening of the vascular lumen due to a collection of blood between the tunica media and the external adventitial layer of an artery.¹ Due to this weakened structure, pseudoaneurysms are more prone to rupture if unrepaired, increasing the risk of life-threatening hemorrhage.
- Pseudoaneurysms of the superficial temporal artery (STA) are rare vascular lesions often incited by an episode of blunt trauma to the region
- Complications of untreated pseudoaneurysms include rupture, distal embolization, local pain, neuropathy and local skin ischemia.²
- There have only been a few hundred cases of STA pseudoaneurysms reported since the first documented instance in 1740.³

Imaging

- Doppler will show characteristic “to-fro” flow which highlights blood flow into and out of the aneurysmal sac.⁴

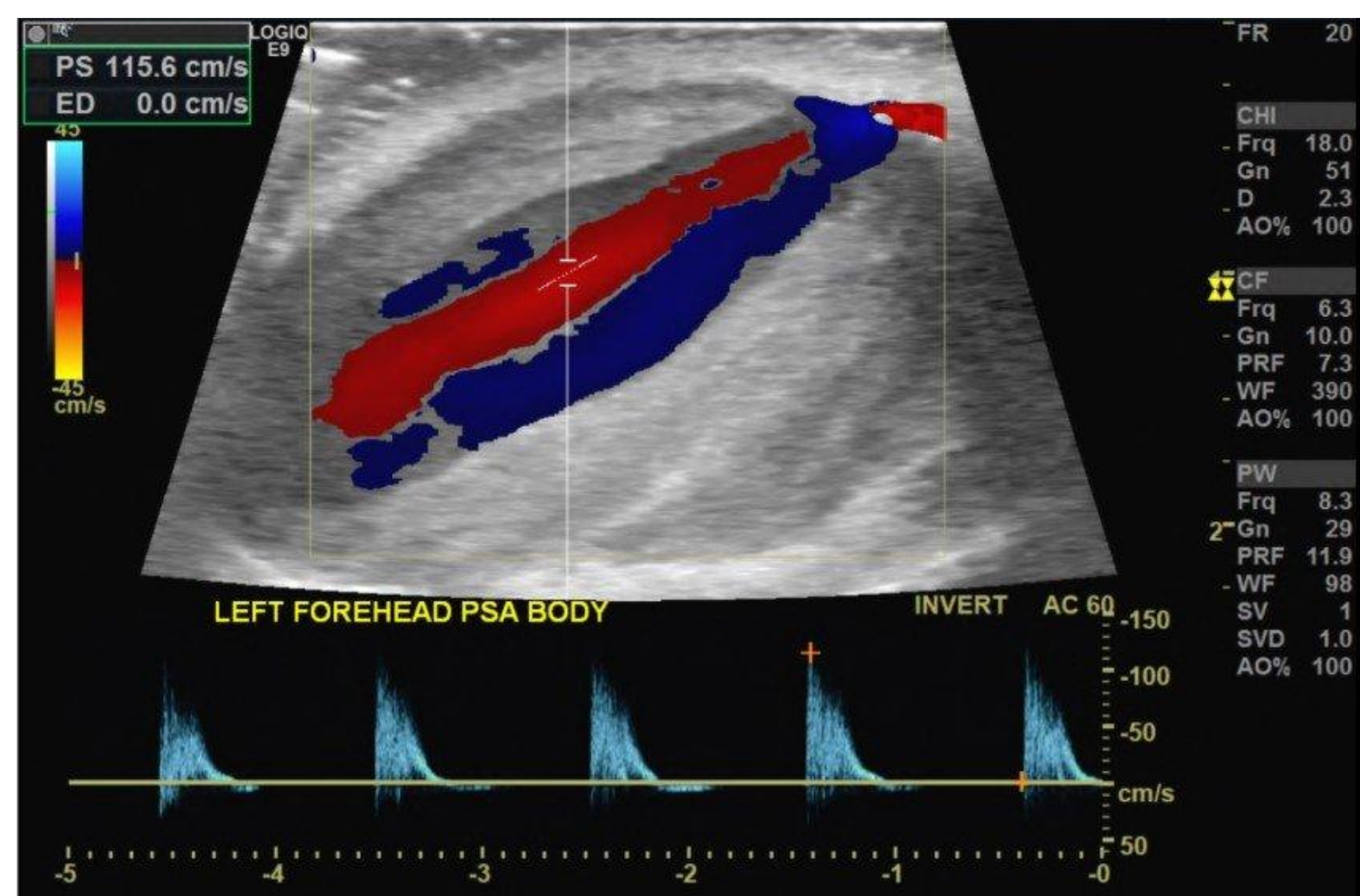


Image 1: Duplex ultrasound of the forehead revealed it to be a pseudoaneurysm of the temporal artery

Case Details

- A 57-year-old male with known seizure disorder and type 2 diabetes mellitus presented to the vascular surgery clinic following a lacerating injury to the head from a mechanical ground-level fall.
- The patient initially developed a large hematoma then the formation of a pulsatile mass.
- Given the cosmetic appearance of the mass as well as the risk of rupture, the patient wished to proceed with surgical excision.

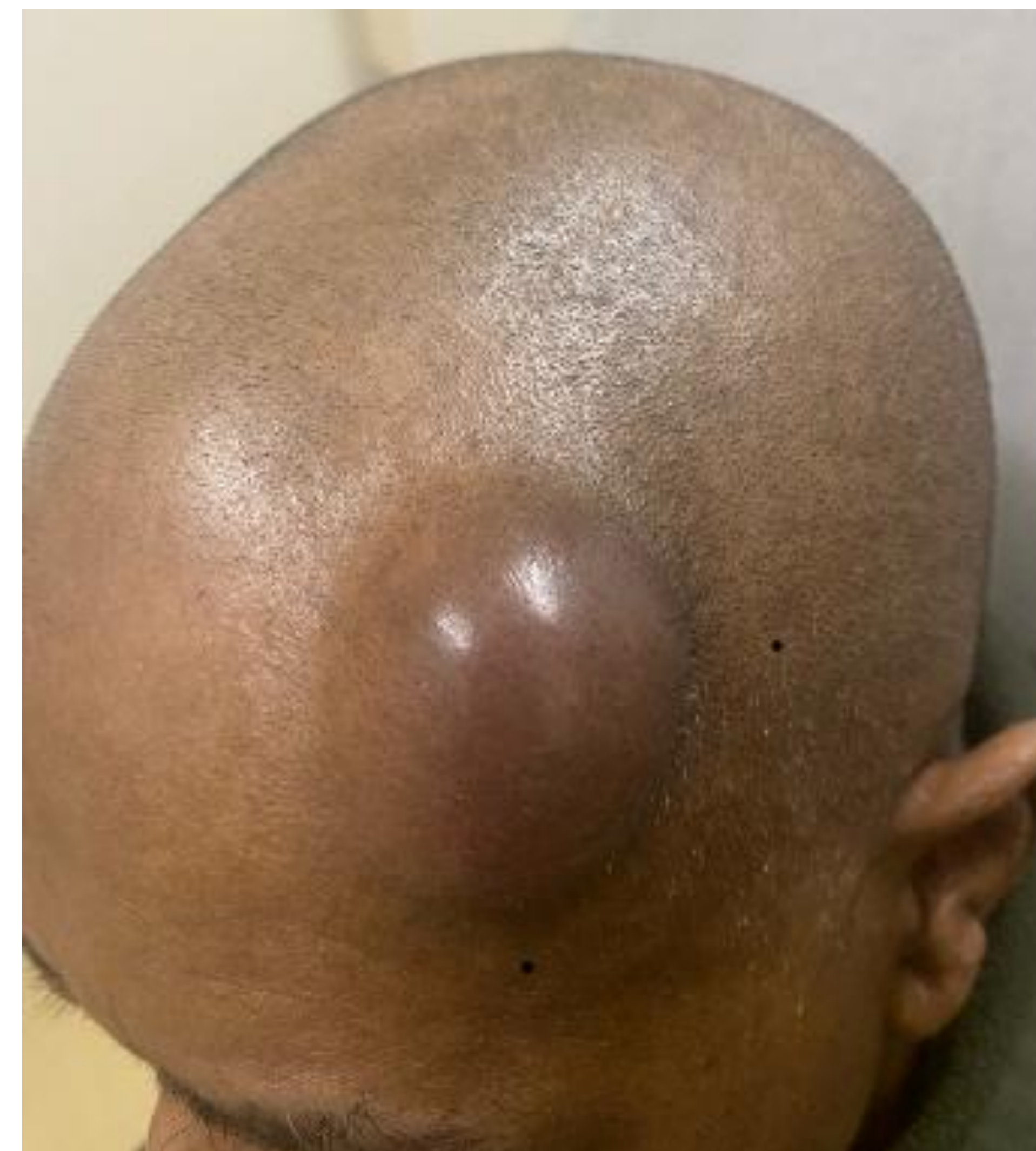

Image 2: Left forehead swelling measuring 4x3 cm

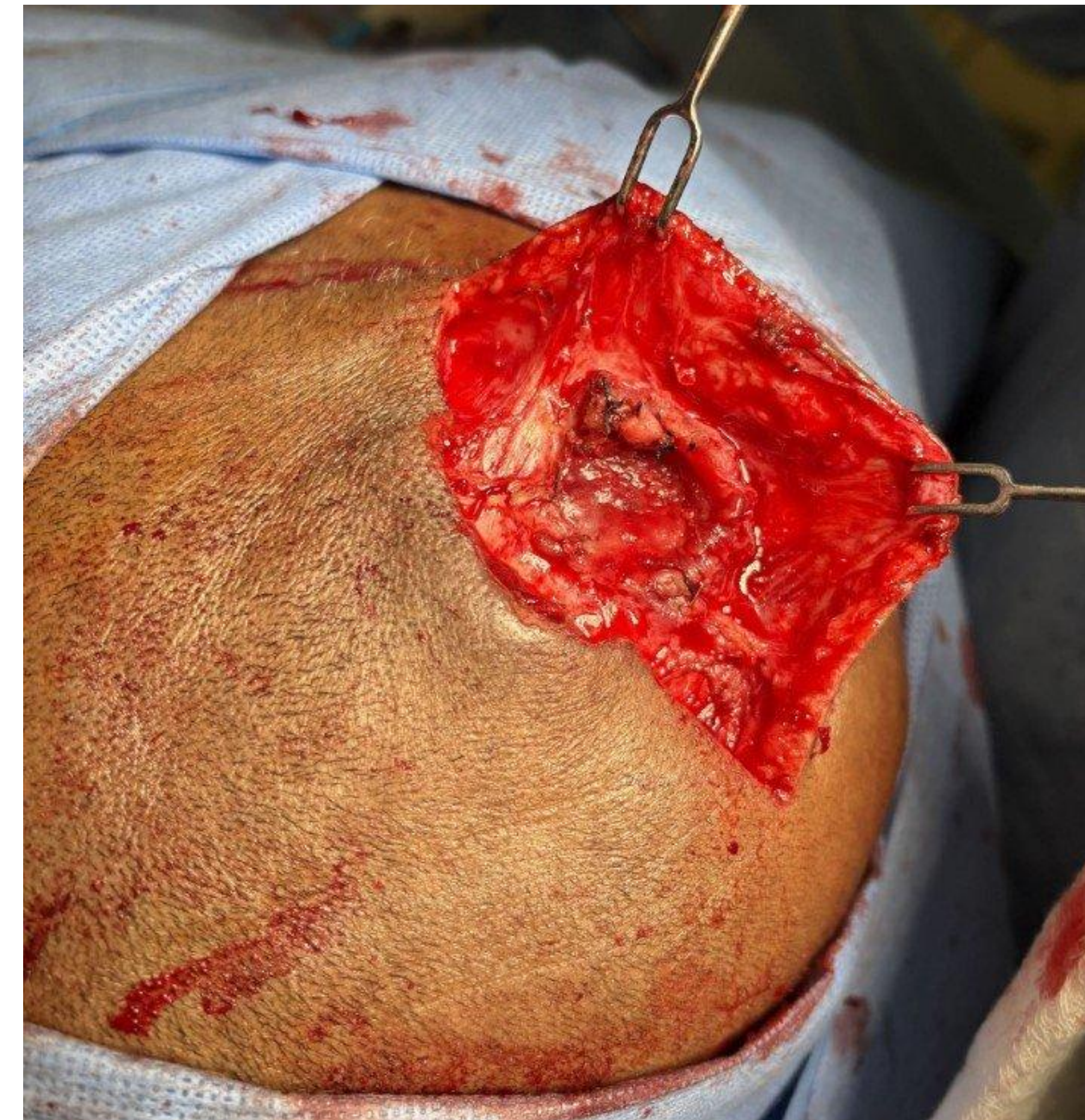


Image 3: Intraoperatively the pseudoaneurysm was found to be thrombosed and was removed piecemeal

Operative Intervention

- Intraoperatively, the pseudoaneurysm was found to be thrombosed and crossing a branch of the facial artery, which was ligated.
- The pseudoaneurysm was successfully excised and plastic surgery assisted with primary wound closure
- A Jackson-Pratt (JP) drain was left in place, and by the second postoperative day the patient was recuperating well and discharged home.

Conclusions

- We report a case demonstrating the classic presentation, diagnosis, and treatment of a STA pseudoaneurysm following head trauma.
- It further highlights the role of vascular surgery in management and the importance of considering consultation when there is suspicion for this pathology.
- Due to the risks of untreated STAs, they should remain on the differential when evaluating a forehead mass.

References

- Rivera PA, Dattilo JB. Pseudoaneurysm. [Updated 2024 Feb 17]. In: StatPearls [Internet]. Treasure Island (FL): StatPearls Publishing; 2026 Jan-. Available from: <https://www.ncbi.nlm.nih.gov/books/NBK542244/>
- Burleson SL, Cirillo FN, Gibson CB, Gullett JP, Pigott DC. Superficial Temporal Artery Pseudoaneurysm Diagnosed by Point-of-Care Ultrasound. Clin Pract Cases Emerg Med. 2019 Jan 7;3(1):77-78. doi: 10.5811/cpcem.2018.11.40958. PMID: 30775675; PMCID: PMC6366385.
- Sarioglu O, Capar AE, Belet U. Interventional treatment options in pseudoaneurysms: different techniques in different localizations. Pol J Radiol. 2019 Aug 23;84:e319-e327. doi: 10.5114/pjr.2019.88021. PMID: 31636766; PMCID: PMC6798774.
- van Uden DJ, Truijers M, Schipper EE, Zeebregts CJ, Reijnen MM. Superficial temporal artery aneurysm: Diagnosis and treatment options. Head Neck. 2013 Apr;35(4):608-14. doi: 10.1002/hed.21963. Epub 2012 Feb 2. PMID: 22302542

The information contained in this poster is not intended to provide interpretation of Veterans Affairs policy nor specific details about how individual Veterans Affairs Medical Centers operate services within their jurisdiction. The contents do not represent the views of the U.S. Department of Veterans Affairs nor the United States Government.