


Osgood Schlatter's Disease



December 30th, 2020

Osgood Schlatter's Disease

Outline

- I. Introduction
- II. Osgood Schlatter's Disease
 - a. History
 - b. Why it happens
 - c. Symptoms
- III. Those Affected
- IV. Diagnosis
- V. Imaging
 - a. X-ray
 - b. Computed Tomography
 - c. Ultrasound
 - d. MRI
- VI. Related Pathologies
 - a. Jumper's Knee/Patellar tendinitis
 - b. Patellofemoral pain syndrome
 - c. Sinding-Larsen Johansson
 - d. Osteochondritis Dissecans
- VII. Treatment
 - a. Conventional
 - b. Medication/Injection
 - c. Physical Therapy
 - d. Surgery
- VIII. Case Study
- IX. Conclusion

Learning Objectives

1. Explain what Osgood Schlatter's Disease is and why it occurs
2. Understand who is affected by Osgood Schlatter's Disease
3. Identify the diagnosis of Osgood Schlatter's Disease
4. Differentiate between Osgood Schlatter's Disease and other similar pathologies
5. Understand the different ways to treat Osgood Schlatter's Disease
6. Learn about a patient's experience with Osgood Schlatter's Disease throughout her life

Abstract

Osgood Schlatter's Disease is a common pediatric injury in those who are physically active and are currently going through a growth spurt. Diagnosis of the condition requires diagnostic imaging, such as x-ray, magnetic resonance imaging (MRI), or ultrasound, each with their own insight to the condition. This paper discusses who it affects, the cause, symptoms and diagnosis, and treatment of Osgood Schlatter's Disease. There are many forms of treatment that can be utilized to relieve symptoms of this condition. This paper discusses: conventional treatment, medications, physical therapy, and surgery.

Introduction

Osgood Schlatter's Disease is in fact, not a disease, but rather a painful injury that occurs during skeletal maturity in children. It appears more often in boys than in girls and is said to be resolved within a year or two, or when the skeleton reaches full maturity and the growth plate has closed. Symptoms, however, can continue into adulthood in some cases. Diagnostic imaging is required to diagnose this disease and to rule out other pathologies. Conservative treatment is most common and resolves symptoms in 90% of patients.¹ If this method is unsuccessful, other options, such as physical therapy, medications, or surgery may be used to relieve pain.

Osgood Schlatter's Disease

About 35 million adolescents in the United States participate in organized or recreational sports. Two of the most common pediatric sports injuries are soft-tissue overuse and growth plate injuries.² Osgood Schlatter's Disease is a condition related to growth in active adolescents that involves the overuse of the soft tissue of the knee.¹ In 1903, Robert Osgood and Carl Schlatter first described this painful overuse of the tibial tuberosity after recognizing a pattern in their patients.³ This disease occurs most often with rapid changes in bones, muscles, tendons, and other structures during a growth spurt.

The disease is described as inflammation of the patellar tendon on the tibial tubercle. When active, the quadriceps muscles pull on the patellar tendon, which, in turn, pulls on the tibial tubercle. The repetitive traction leads to the inflammation of both the tubercle and tendon, creating a pronounced ununited prominence.⁴ In almost ten percent of patients, the bone fragments do not fuse.¹ When this happens, the patient may experience pain in the front of the

knee after the slightest physical activity, and extreme pain with kneeling.⁵ Small avulsion fractures from the contractions of the quadriceps muscles at the insertion into the proximal tibial apophysis is said to be another cause of Osgood Schlatter's Disease.³ In some cases, symptoms occur bilaterally, although one knee may be worse than the other.

Those Affected

Adolescents who are physically active, especially running and jumping, put more stress on their bones and muscles and are at a higher risk of developing this condition.⁴ Around 20% of adolescent athletes will be affected by this condition, but there is a chance that less active adolescents may also experience this disease.⁶ Osgood Schlatter's Disease is said to last between 12 and 24 months, with 90% of patients having resolution of their symptoms.⁶ Over half of patients take more than two years to fully recover.^{1,6}

When a child completes the adolescent growth spurt, around ages 14 and 16 for girls and boys respectively, most symptoms will completely disappear, due to the growth plate closing at skeletal maturity.^{4,6} Once the growth plate is closed and the symptoms have subsided, a prominence or bump at the site of the tibial tubercle will remain. Complete recovery is expected when the growth plate closes, but some patients may have recurrent symptoms into adulthood that may require surgical treatment. Adults whose symptoms resolved at skeletal maturity, but have a history of Osgood Schlatter's Disease, may have more problems with activities of daily living, sports activity, and impaired knee function compared to those without a history of the condition.¹

Diagnosis

In order to diagnose Osgood Schlatter's Disease, doctors look for specific symptoms. Some of those symptoms include swelling and tenderness at the tibial tubercle, tight muscles in the front or back of the thigh, and a small effusion.³ The symptoms are aggravated by activities that require the knee to be extended against resistance. During examination of the knee, the doctor will apply pressure to the tibial tubercle to test for pain or tenderness. They may also have the patient walk, run, jump, or kneel to see if any of these movements are uncomfortable or painful.⁴ Radiographic examination is considered necessary to confirm an Osgood Schlatter's

Disease diagnosis. Diagnostic imaging helps to rule out other conditions such as a patellofemoral pain syndrome, patellar tendinitis, and osteochondritis dissecans.⁷

Imaging

There are many imaging modalities that can help verify the diagnosis, including conventional radiography, computed tomography, ultrasound, and magnetic resonance imaging. The first step is typically conventional imaging, which may show an enlarged and fragmented tibial tubercle. In more severe cases, there may be evidence of separation and fragmentation of the apophysis. There may also be an irregular ossification of the tubercle.⁸ In less severe cases, there may be no radiographic evidence in the bony anatomy, but soft tissue swelling may be present. This is most evident on the infrapatellar fat pads, which may be the only evidence of this disease.⁸ Computed tomography is only used in atypical or non-clear cases.⁹

Ultrasound

Ultrasound may be used to visualize any swelling of the soft tissue, cartilage, bursa, and tendon.⁵ It may also detect the presence of any new bone formation in the area. Ultrasound helps to differentiate between three stages of Osgood Schlatter's Disease based on the presence or absence of a large anechoic region and ossicles, as well as irregularity of the apophyseal surface.⁷ The first stage, known as cartilage attachment, is described as a large anechoic region in the apophyseal cartilage with or without ossicles. Stage two, or insertional cartilage, shows the attachment of the collagen fibers onto the bone surface with a thin anechoic layer of cartilage. The third stage is where the mature attachment of the collagen fibers onto the surface of the bones is demonstrated.⁷ Under high-frequency ultrasonogram, with the use of a linear probe, the painful area may be examined. This method may unveil a hyperechoic lesion that is surrounded by a hypoechoic lesion of unossified cartilage that has a hypoechoic thickened distal patellar tendon.¹⁰

MRI

Magnetic resonance imaging is able to identify five different stages of Osgood Schlatter's Disease compared to ultrasound: normal, early, progressive, terminal, and healing.⁷ The normal stage of this condition shows no changes on the MRI scan, but the patient is symptomatic. The early stage may show signs of inflammation in the area of the secondary ossification center. Next, the progressive stage, reveals partial cartilage avulsion at the level of the secondary ossification center. The terminal stage then shows separated ossicles at the level of the tibial tubercle. Finally, the healing stage, described as osseous healing, demonstrates separated ossicles at the tibial tuberosity.⁷ MRI is preferred due to its higher sensitivity than ultrasound, and it can determine soft tissue swelling at the tibial tubercle, edema of the patellar tendon, bone marrow edema, and deep infrapatellar bursitis.⁵

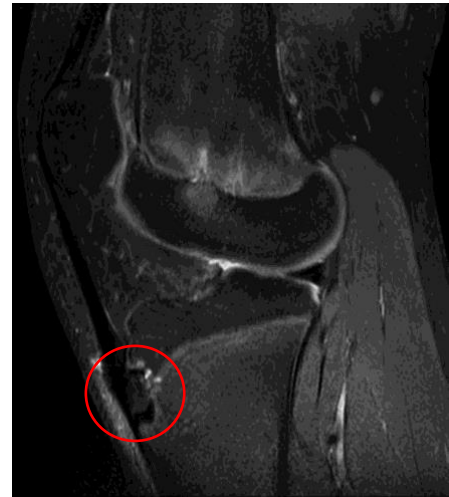

Figure 1
Sagittal MRI of right knee.
Demonstrates the terminal stage of
Osgood Schlatter's Disease.⁷

Related Pathologies

Osgood Schlatter's Disease is commonly referred to as "jumper's knee", which is diagnostically incorrect. Jumper's knee, although an entirely different condition, is frequently a complication of Osgood Schlatter's. Patellar Tendonitis, jumper's knee, is an injury or the inflammation of the patellar tendon. This condition can weaken the tendon, which can lead to tears.¹¹

Another pathology that can result from Osgood Schlatter's is patellofemoral pain syndrome. This is a broad term to describe pain at the front of the knee and around the patella. This condition can result from problems with the alignment of the kneecap and overuse from physical activities.¹²

Inferior patellar pole traction apophysitis also known as Sinding-Larsen Johansson Syndrome, is maximum tenderness at the inferior pole of the patella rather than the tibial tubercle as with Osgood Schlatter's. With Sinding-Larsen Johansson Syndrome, conventional

radiography shows that the tibial tuberosity is normal, but there is an ossicle at the lower pole of the patella.⁵

Osteochondritis Dissecans is a pathology that is commonly confused with Osgood Schlatter's. This condition is where pain is located at the anterior or anteromedial aspect of the knee. Pain or tenderness is localized to the medial joint line, but no sensitivity on the tibial tuberosity. There is a lesion that is apparent on conventional radiography in the lateral aspect of the medial femoral condyle.⁵

Treatment

There are different forms of treatment for Osgood Schlatter's Disease. These can include reduced physical activity, analgesia, physical therapy, and surgery. Limiting physical activity includes restricting stairs and running for 12 weeks.⁸ Ice and elevation are encouraged to decrease swelling and pain. Treating this condition as an acute injury has been successful in decreasing the severity and length of symptoms. Some physicians encourage the use of an infrapatellar strap during activities in order to decrease the pull of the quadriceps against the tibial tubercle. 92% of patients report improvement with the use of the strap. Complete recovery is expected when the tibial growth plate closes.⁹

Medication/Injection

Analgesics, such as a steroid injection, may be used when the restriction of activities has failed to reduce the pain. An injection of the tubercle with hydrocortisone or lidocaine HCL combined with the hydrocortisone, dexamethasone, triamcinolone, or methylprednisolone may be used to improve pain levels.⁸ It has been reported that 52 of 72 patients had relief after just one injection. Nine more patients reported having relief after two or three injections. Only three patients did not respond to the injection. A dextrose injection with 1% lidocaine may be injected monthly for 3 months with a 27-gauge needle. The injection is inserted on painful areas of the tibial tubercle, mainly under the patellar tendon.⁸

The use of nonsteroidal anti-inflammatory drugs (NSAIDs) may also be helpful in decreasing the swelling and pain at the tibial tubercle. Meloxicam is an example of an NSAID that may be prescribed by a physician to help with this condition. Meloxicam is an oral medication that is used to help reduce swelling, pain, and stiffness in the joint.

Physical Therapy

Physical therapy may be prescribed by the physician to try and strengthen the muscles surrounding the patellar tendon in order to take the load off the tendon. Physical therapy starts with an assessment of the patient's knee pain, whether it is unilateral or bilateral, as well as its duration. Severity is indicated if there is pain followed by brief physical activity or prolonged activity. The presence or absence of pain while walking, running, ascending and descending stairs, and kneeling is documented. Confirming the diagnosis of Osgood Schlatter's Disease is the first task of the therapist. Both knees are compared in a 90° flexion to identify if an enlarged apophysis is present and to assess the pain level. Range of motion is evaluated while the patient is prone, and the knee is flexed by the therapist to the end of range or until pain occurs. Muscle tightness and location of pain when stretching are documented for use in treatment. The primary goal of treating Osgood Schlatter's Disease is pain relief in the area of the tubercle. The use of anti-inflammatory medication and local anesthetics are beneficial in decreasing swelling and pain at the site. In order to relieve pain at the tubercle, different stretches are used to strengthen the muscles around the source of pain. Most often, at the beginning of treatment, isometric stretches are utilized to decrease the flexion of the knee. Throughout treatment, these stretches are reevaluated and made more difficult and inclusive to the flexion of the knee.⁸

Surgery

Surgery is rarely indicated due to this condition being a typical condition in adolescents who are skeletally immature; however, it can be successful for those who have intolerable symptoms with no success from other forms of treatment. It is suggested that surgery is explored as an option when symptoms have persisted for more than two years.⁵

An endoscopic procedure may be indicated in the case of symptomatic Osgood Schlatter's Disease with the avulsed ossicle anterior to the patellar tendon. This technique can provide a better cosmetic result as there is less risk of painful surgical scars and less damage to the patellar tendon insertion.

An arthroscopic excision of the ossicle and debridement of the tibial tubercle may be performed. During the procedure, the patient is supine with a pneumatic thigh tourniquet to provide a bloodless operating field.¹³ At the bony prominence of the tibial tubercle, a proximal-lateral portal is made on the proximal-lateral side of the prominence and a distal-medial portal is made on the distal-medial side of the prominence. These incisions are made deliberately away from the ossicle to avoid the formation of a painful scar over the area. Anterior to the bony prominence, a plane is developed by a hemostat to be the working area for the endoscopy.¹¹ The portal on the proximal-lateral side is the viewing portal. The arthroscope is used through the distal-medial portal and the anterior surface of the patellar tendon is identified and traced distally. This area is probed to identify the ossicle, which is embedded into the distal patellar tendon. Through the proximal-lateral portal, the thin layer of tendinous tissue over the ossicle is arthroscopically shaved.¹¹ It is important that the borders of the ossicle are defined before resection to prevent the damage of normal tendinous tissue. The ossicle itself is resected with an arthroscopic acromionizer through the proximal-lateral portal. During the resection, the knee is flexed to increase tension on the patellar tendon immobilizing the ossicle.¹³

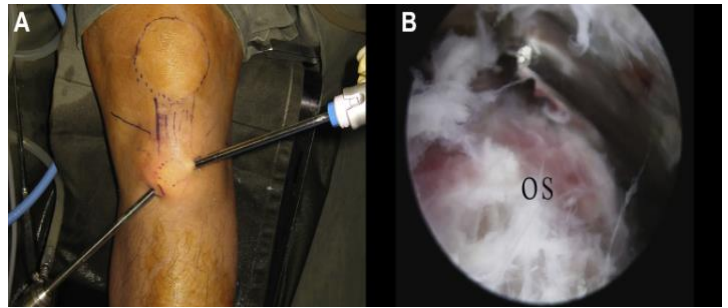


Figure 2
Arthroscopic excision of an ossicle
on the tibial tubercle.³

After the ossicle is resected, the prominent tubercle follows. This is done by starting the bone shaving from the proximal end of the prominence with preservation of the patellar tendon insertion site. The acromionizer faces distally with the sheath protecting the tendon from damage.¹³ This surgery technique is favored as activity may be allowed earlier because the patellar tendon is not violated with this endoscopic approach. Endoscopic resection of the ossicle and debridement of the tibial tuberosity comprise a reasonable surgical choice for unresolved Osgood Schlatter's lesions.¹³

Case Study

In 2007, a 10-year-old female presented with right knee pain. The patient's mother informed the physician that her daughter had recently been going through a growth spurt with severe pain at the knee. The pain was localized to the tibial tubercle, where the formation of a

bony prominence was found. The patient was diagnosed with Osgood Schlatter's Disease. There was no diagnostic imaging performed at this time. The patient was advised to ice and elevate, take ibuprofen as needed, as well as, reduce physical activity. She was informed that she will grow out of this pain in a few years. The patient returned to normal daily activities, including basketball practices. She did not want this pain to impede her activity, so she continued through the pain.

Two years later, in 2009, the patient's pain had not subsided as predicted. She was seen by her local chiropractor who tested the mobility of the knee and pain tolerance. It was found the pain had not diminished at all over the last two years. The patient was prescribed a cho-pat brace, also known as an infrapatellar strap, to reduce the use of the patellar tendon attached to the area of pain. This treatment approach was found ineffective and actually brought more pain to the patient. The use of an accelerated recovery and performance machine was used after bouts of physical activity to attempt to lessen the pain. This method was also unsuccessful in treating the patient's pain. Treatment using the Graston Method, a manual therapy technique used to break down scar tissue around areas of pain and increase function was the next approach. The Graston method was effective in treating pain for the patient from 2013-2014, but soon after the relief found in this treatment had subsided. The patient went through four years of high school sports pushing through the pain as her doctor believed it would subside in a few years.

In 2020, 13 years later, the patient revisited the reoccurring pain with her current physician. The physician ordered diagnostic x-rays, and it was found that the patient has an ununited ossicle on the tibial tubercle, confirming Osgood Schlatter's Disease. The patient was then referred to an orthopedic physician. She met with the physician and discussed the symptoms along with the timeline of the condition. The doctor had the patient perform a series of tests including; walking, flexing and extending the knee, as well as stretching the muscles surrounding the knee. The patient was asked to rate the level of pain after each exercise. The patient was diagnosed with not only Osgood Schlatter's Disease, but also patellar tendinitis and patellofemoral pain syndrome. She was prescribed physical therapy

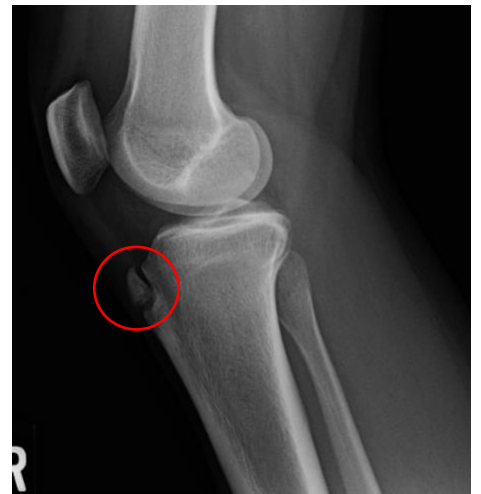

Figure 3 shows an ununited ossicle at the center of the tibial tubercle indicating Osgood Schlatter's Disease.¹⁴

for six weeks to attempt to strengthen the muscles surrounding the patellar tendon. After six weeks the patient will revisit with the physician and discuss any changes.

During physical therapy, the patient worked with a therapist who tested her tolerance each week with specific activities. It was discovered that the patient had severe swelling in between the bony prominence and the patella. This was cause for concern from her therapist, who recommended wearing a compression sleeve around her knee every day. This approach seemed to help decrease the swelling. Isometric stretches are the main course of treatment in order to decrease the constant flexion of the knee which irritates the tendon and increases swelling. After six weeks of physical therapy and an at home program of stretches, the patient's pain has not lessened, but rather intensified. The patient had the check-in visit with the orthopedic physician after the six weeks of physical therapy. At this visit they discussed how physical therapy went and what would be the next step. The next step in the treatment plan is to obtain an MRI of the knee as the physician expressed concern for a medial meniscus tear. The patient was prescribed a nitroglycerin patch which is cut into fourths and applied the affected knee every day for 24 hours. Research shows that the nitroglycerin patch helps to restore good blood flow to the tendon that has been damaged over the years. The patient will attempt this treatment for 4-8 weeks and will determine if there is improvement.

After two weeks of attempting treatment with the nitroglycerin patch, the patient met with the physician to discuss the MRI results, and how the patch was working. The results of the MRI showed no tears in any of the ligaments, but there is patellar tendonitis seen distally. Mild bone marrow edema is seen in the ununited ossicle, and at the synchondrosis, it was noted these findings represent sequelae of Osgood-Schlatter's Disease. After discussion with the physician, it was determined the nitroglycerin patch was making symptoms worse and a new approach needed to be implemented. Conservative treatment was considered failed at this time and the patient was referred to an orthopedic surgeon.

After meeting with the surgeon and discussing what the next step in treatment should be, it was decided that the ossicle is to be excised. Treatment using

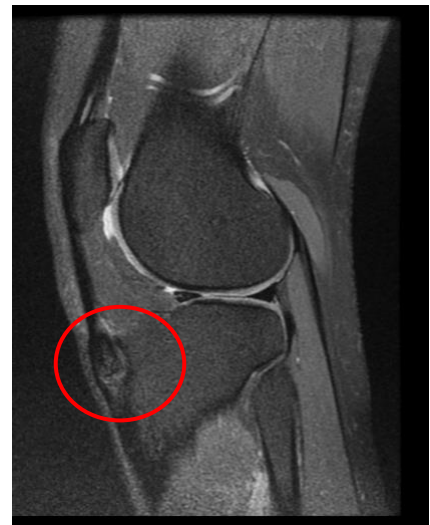

Figure 4 Sagittal MRI image showing edema at the ossicle and the synchondrosis.¹⁵

injections was briefly discussed, but ultimately it was decided that an injection may be more harmful to the tendon and would not be a permanent solution. The main concern during this surgery is to refrain from damaging the tendon surrounding the ossicle. The hope is that after surgery, the patient's symptoms will completely disappear, and she will be able to return to normal activities with no pain.

Conclusion

Osgood Schlatter's Disease mainly affects adolescents but can affect patients into adulthood as well. Diagnostic imaging is a key factor in being able to diagnose Osgood Schlatter's Disease. Conventional imaging, ultrasound, and MRI are all used to rule out pathologies that have symptoms comparable to Osgood Schlatter's. The symptoms stay the same from when the condition first arises, and some patients find no pain relief with any of the conservative treatments. Treatment options for those diagnosed with this condition vary on the severity and length of time it has been affecting the patient. Depending on the patient's symptoms, the physician may suggest different treatment options for Osgood Schlatter's Disease.

References

1. Osgood-Schlatter Disease (Knee Pain) - OrthoInfo - AAOS. OrthoInfo. <https://orthoinfo.aaos.org/en/diseases--conditions/osgood-schlatter-disease-knee-pain/>. Accessed November 19, 2020.
2. Mulcahey MK, Hettrich CM, Liechti D. Patellofemoral Pain Syndrome - OrthoInfo - AAOS. OrthoInfo. <https://orthoinfo.aaos.org/en/diseases--conditions/patellofemoral-pain-syndrome/>. Published 2020. Accessed November 19, 2020.
3. Pal S. MRI Keeps Pace with Rapidly Evolving Musculoskeletal Systems of Young Athletes. Radiology, News, Education, Service. <https://www.auntminnie.com/index.aspx?sec=sup>. Published May 2007. Accessed November 19, 2020.
4. Mayo Clinic Staff. Patellar tendinitis. Mayo Clinic. <https://www.mayoclinic.org/diseases-conditions/patellar-tendinitis/symptoms-causes/syc-20376113>. Published October 16, 2019. Accessed November 19, 2020.
5. Guldhammer C, Rathleff MS, Jensen HP, Holden S. Long-term Prognosis and Impact of Osgood-Schlatter Disease 4 Years After Diagnosis: A Retrospective Study. Orthopaedic journal of sports medicine. <https://www.ncbi.nlm.nih.gov/pmc/articles/PMC6823982/>. Published October 31, 2019. Accessed November 19, 2020.
6. Lui TH. Endoscopic Management of Osgood-Schlatter Disease. Arthroscopy techniques. <https://www.ncbi.nlm.nih.gov/pmc/articles/PMC4811213/>. Published February 8, 2016. Accessed November 19, 2020.
7. Narayan N, Mitchell PD, Latimer MD. Complete resolution of the symptoms of refractory Osgood-Schlatter disease following percutaneous fixation of the tibial tuberosity. BMJ case reports. <https://www.ncbi.nlm.nih.gov/pmc/articles/PMC4330449/>. Published February 12, 2015. Accessed November 19, 2020.
8. Parmar H. Osgood Schlatter Disease: A Rare Condition in Young Athletes - A Case Study. 2014;1(5)(2348-8336):265-268.
9. Maher PJ, Ilgen JS. Osgood-Schlatter disease. BMJ case reports. <https://www.ncbi.nlm.nih.gov/pmc/articles/PMC3603844/>. Published February 27, 2013. Accessed November 19, 2020.
10. Antich TJ, Brewster CE. Osgood-Schlatter Disease: Review of Literature and Physical Therapy Management. The Journal of Orthopaedic and Sports Physical Therapy. 1985. <https://www.jospt.org/doi/pdf/10.2519/jospt.1985.7.1.5>. Accessed November 18, 2020.

11. Vaishya R, Azizi AT, Agarwal AK, Vijay V. Apophysitis of the Tibial Tuberosity (Osgood-Schlatter Disease): A Review. Cureus. <https://www.ncbi.nlm.nih.gov/pmc/articles/PMC5063719/>. Published September 13, 2016. Accessed November 19, 2020.
12. Vreju F, Ciurea P, Rosu A. Osgood-Schlatter disease - ultrasonographic dignostic. medultrason. 2010;12(4):336-339. <http://www.medultrason.ro/assets/Magazines/Medultrason-2010-vol12-no4/Vreju.pdf>. Accessed November 18, 2020.
13. Siddiq MAB. Osgood-Schlatter Disease Unveiled Under High-frequency Ultrasonogram. Cureus. <https://www.ncbi.nlm.nih.gov/pmc/articles/PMC6281446/>. Published October 4, 2018. Accessed November 19, 2020.
14. Hospital PACS System. 2020 October 12. Retrieved December 2020.
15. Hospital PACS System. 2020 December 3. Retrieved December 2020.