


Minimally Invasive Realignment for Slipping Rib Syndrome

The American Surgeon
2023, Vol. 0(0) 1–2
© The Author(s) 2023
Article reuse guidelines:
sagepub.com/journals-permissions
DOI: 10.1177/00031348231157893
journals.sagepub.com/home/asu


Nehal Ninad, MD¹ and Dudley B. Christie, MD¹

Abstract

Slipping rib syndrome has remained a lesser-known entity despite its presence in the medical literature for over 100 years. If left undiagnosed, it can be associated with significant morbidity. Operative repair for the syndrome remains the definitive treatment. Traditional repair involved rib resection which can be technically challenging and have painful recovery. Minimal invasive techniques have been described recently which circumvent these issues. Here, we present our experience with our minimally invasive realignment technique for slipping rib syndrome. Our data suggested early hospital discharge, minimal perioperative complication, and near complete resolution of symptoms. We advocate for further research to enhance timely recognition and management for this entity and additionally recommend minimally invasive operative approach for definitive treatment.

Keywords

slipping rib syndrome, minimally invasive repair, slipped rib

Slipping rib syndrome (SRS) has remained an unrecognized cause of lower chest and upper abdominal pain. Slipping rib syndrome is secondary to an anatomic defect involving the costal cartilage of lower rib cage.^{1,2} Lower costal cartilages (ribs 8-10) are not directly connected to the sternum, rather they attach to adjacent cartilages with cartilaginous cap or fibrous band. There could be a congenital anomaly, a direct trauma causing disruption of cartilaginous or fibrous articulation, or hypermobility of unknown origin causing the costal cartilage to sublux and slip out of its normal anatomic position.² The anterior false rib slides underneath the immediate superior rib. Impingement of the branches of intercostal nerves secondary to this subluxation manifests as lower chest wall discomfort.

The lower chest wall discomfort can be intermittent or constant and last minutes to hours. It can be dull and aching or sharp and burning in nature.^{1,2} Exacerbating factors include valsalva maneuvers or axial rotation. Often, SRS disguises as vague upper abdominal pain creating a broad differential and a diagnostic dilemma. Radiologic findings and laboratory findings often show no abnormalities. Physical exam for these patients typically involves positive Hooking maneuver during which examiner feels a click after hooking the finger under the anterior costal margins and pulling the rib anteriorly.^{1,2} Real-time ultrasound can demonstrate the subluxation with valsalva or axial rotation, but this can be very operator dependent.

Treatment starts with conservative means to achieve pain control, but operative repair is the definitive treatment.¹ Traditional surgical approach involved resection of the cartilaginous portion of slipped rib. In recent years, vertical rib plating³ and minimally invasive realignment⁴ of slipped rib using sutures have been described which do not require cartilaginous excision. We present our experience with the minimally invasive realignment of the slipped rib.

IRB approval was obtained. A retrospective review of all patients who underwent minimally invasive realignment of the slipped rib between 01/20 and 06/22 (n = 11) was included. We used a self-reported pain scale in which patients were asked about their pain level on a scale of 1-10 with 1 being the least and 10 being the worst pain. We recorded the following data for each patient: age, gender, imaging obtained prior to diagnosis, preoperative pain (self-reported scale) length of stay, postoperative complication, and pain during post-op visit (self-reported scale).

For our operative approach, the patient is placed in supine position. Prior to induction of general anesthesia,

¹Department of Surgery, Atrium Health Navicent, Macon, GA, USA

Corresponding Author:

Nehal Ninad, MD, Department of Surgery, Atrium Health Navicent, 777 Hemlock Street, Macon, GA 31201-2102, USA.
Email: Nehal.ninad@atriumhealth.org

physical exam is performed to identify the point of tenderness. After induction, markings are made overlying the lower costal cartilages and ribs for identification. A linear 3 cm incision is centered over the point of tenderness, and Bovie cauterization is used to dissect to the level of the ribs. The tissue overlying the rib is cleared. A wound protector is now placed. A repeat exam is performed to confirm the rib in question. We now proceed to secure the slipped rib to the rib immediately above in two places: 1. medially, we perform a chondroplasty by using #1 Ethibond suture to place a U-stitch through the cartilages of the two ribs. 2. Laterally, we use a #1 Ethibond to secure the ribs to each other in a figure-of-eight fashion (Figure 1). While facilitating the medial and lateral realignment, we place a right angle underneath each rib and pass the suture, taking care to avoid entrance into the pleural space. Chest X-ray is now performed to rule out a pneumothorax. After obtaining hemostasis, we close in standard fashion.

We have 11 patients undergo minimally invasive realignment for SRS between 01/20 and 06/22. 54% of our patients were male, and the average age for our patients was 48 years. 36% (n = 4) of our patients had received unremarkable imaging prior to diagnosis. The average length of hospital stay for our patients was one day. Among postoperative complication, one of our patients developed post-op seroma and one developed pneumothorax. 64% of our patients (n = 7) reported pain to a nonexistent level at the first postoperative visit, while all of our patients reported decrease in pain levels.

Despite more than 100 years in medical literature, SRS remains a lesser-known entity which carries significant morbidity. One of the challenges of the disease is lack of prompt diagnosis. Patient often seeks medical attention for the same problem multiple times before coming to the diagnosis, and additionally, they receive multiple imaging in the process.^{1,2} 36% of our patient had imaging performed prior to being referred to us. With surgery being the definitive treatment, surgeons should be well versed in diagnosis and management of this entity.

The standard procedure in the past had been costal cartilage resection, but it has its disadvantages. It can be technically difficult, is associated with painful recovery, and involves resection of 2-3 ribs cartilage which can undermine normal functioning of the rib cages.⁴ Minimal invasive repair methods circumvent this problem. Our technique avoids excision of the cartilage, and realignment of the rib cage preserves the functional component of the chest wall. Our complications (seroma and pneumothorax) were treated conservatively without any surgical intervention.

Our data suggests early hospital discharge, minimal perioperative complication, and near complete resolution

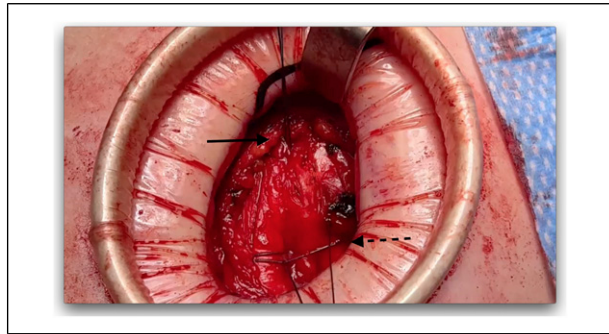


Figure 1. Medial chondroplasty using a U-stitch (solid arrow) and lateral suture fixation in figure-of-eight manner (dotted arrow).

of symptoms. Self-reported resolution of symptoms further corroborates for the well-tolerated nature of the procedure. Our study is however limited given its retrospective nature and small sample size. These limitations can be attributed to the low prevalence of the disease and high rate of misdiagnosis to capture adequate sample. Given the sparsity of medical literature for a morbid entity, further research is indicated to enhance prompt recognition and management.

Declaration of Conflicting Interests

The author(s) declared no potential conflicts of interest with respect to the research, authorship, and/or publication of this article.

Funding

The author(s) received no financial support for the research, authorship, and/or publication of this article.

References

1. McMahon LE. Slipping rib syndrome: A review of evaluation, diagnosis and treatment. *Semin Pediatr Surg.* 2018; 27(3):183-188. doi:10.1053/j.sempedsurg.2018.05.009
2. Gress K, Charipova K, Kassem H, et al. A comprehensive review of slipping rib syndrome: Treatment and management. *Psychopharmacol Bull.* 2020 June 7; 50(4 suppl 1):189-196. <https://pubmed.ncbi.nlm.nih.gov/33633425/>
3. Rudolph HC, Nam BT. Combined excision of costal cartilage and rib plating for slipped rib syndrome. *Ann Thorac Surg.* 2022;113(3):e207-e209. doi:10.1016/j.athoracsur.2021.05.019
4. Hansen AJ, Toker A, Hayanga J, Buenaventura P, Spear C, Abbas G. Minimally invasive repair of adult slipped rib syndrome without costal cartilage excision. *Ann Thorac Surg.* 2020;110(3):1030-1035. doi:10.1016/j.athoracsur.2020.02.081