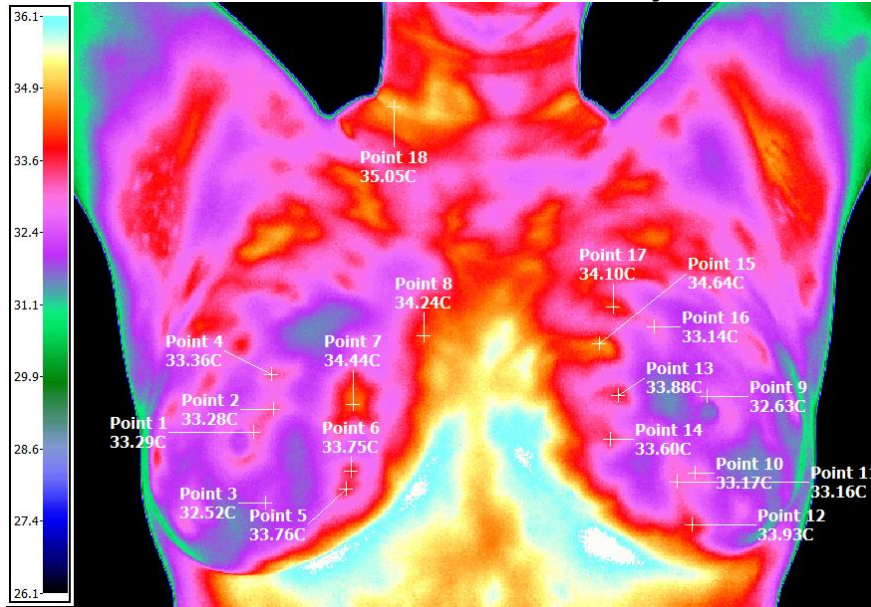


Date of Study

ANALYSIS OF BREAST THERMOLOGY

Sample Patient DOB: Date of Birth

Scan ID: AB12CD34 for Your Physician



Frontal Thorax

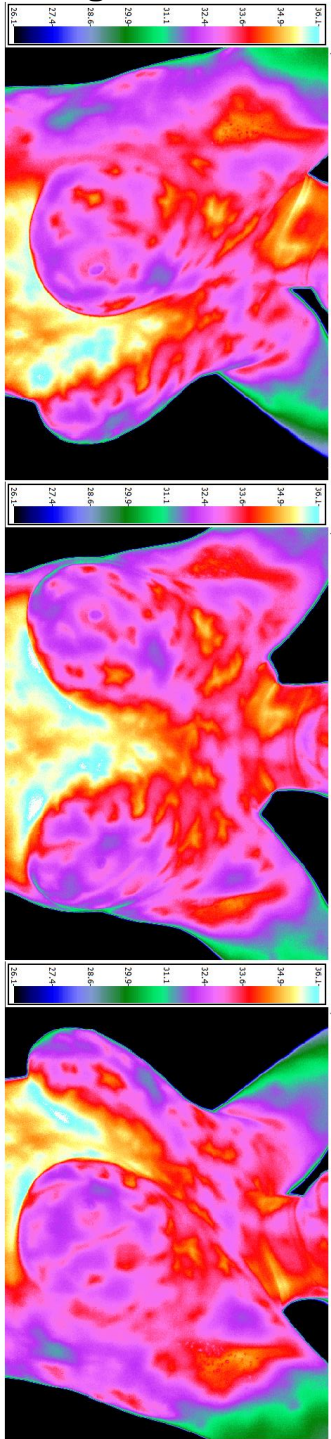
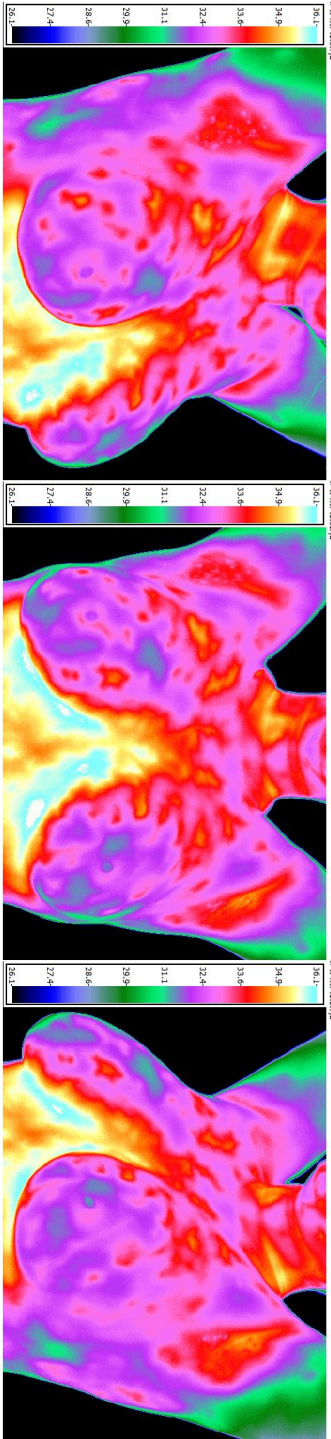
BACKGROUND: Two (2) replicate sets of three (3) high-resolution radiometric infrared images were made of the anterior and the right and left lateral aspects of the thorax to feature the breasts. The second set of images was made immediately after the patient withdrew both hands from a one-minute immersion in cold (approx. 11°C) water. This procedure is a deliberate and simple dynamic functional challenge that anticipates the adaptive constriction of normal blood vessels with consequent cooling of the skin. The challenge is intended to differentially indicate regions of unregulated hyperemia that are reliably and proximately associated with solid cancerous neoplasm. The results of this challenge are coupled with specific features of vascular configuration, quantitative thermal differentials and, where available, time-based evolution of thermal patterns and levels to provide a multi-parametric risk assessment for malignant breast disease. The patient's related history includes a familial and two (2) personal risk factor(s) for breast cancer. The patient's related history includes no symptom(s) associated with breast disease.

Study Date(s)	Right Breast TH Score	Left Breast TH Score
08 October 2014	TH-2	TH-2
None		

ANALYSIS: The infrared images of the right and left breasts demonstrate essentially symmetric, distinct, large-caliber, hyperthermic and vascular-like patterns in the peri-areolar areas (please refer to the 08 October 2014 Frontal Thorax thermogram above for specific features and locations). None of the vascular-like patterns in the right or left breast demonstrate asymmetric complexity. No significantly (+2.0°CΔ) hyperthermic foci or vascular-like patterns; asymmetric, global and significantly (+2.0°CΔ) hyperthermic patterns involving an entire breast or asymmetric physical distortions are discerned from the right or the left breast. However, discrete and significantly hypothermic patterns are discerned in the right and left breasts. The post-challenge images demonstrate symmetric and adaptive attenuation of the emission levels from all of the thermal features of the right and left breasts.

RISK ASSESSMENT: Quantitative analysis of the infrared images does **not** indicate any thermology signs or criteria that establish risk for malignant disease in the right or left breast. However, the thermal features of prominent vascular-like patterns are consistent with estrogen-promoted benign glandular hyperplasia, fibrocystic disease and related moderate to high tissue density the right and left breasts.

SUMMARY: Benign-type atypical thermology; graded TH-2 for the right breast and TH-2 for the left breast. Annual thermology restudy is recommended for comparative analysis. © Copyright 2001-2014. This report format, its text and image color pallet are copyrighted and may not be duplicated or replicated in any manner. All Rights Strictly Reserved. Therma-Scan Reference Laboratory, LLC 34100 Woodward Ave. Suite 100 Birmingham, MI 48009 USA. +248.593.8700 <http://www.thermascan.com>



**Date of Study, Sample Patient, DOB: Date of Birth, Scan ID: AB12CD34
for Your Physician Page 3 of 3
About Breast Thermology**

Medical Infrared Imaging is the process of obtaining highly detailed and sensitive infrared images of the human body. Thermology is the diagnostic analysis of those images by a Board-Certified medical specialist using an objective and quantitative method derived from extensive medical science and sixty (60) years of clinical development. Thermology (thermography) is listed by the US Dept. of Health and Human Services as an adjunctive diagnostic modality for breast cancer detection. Thermology evaluates tissue function and is distinctly different from tissue structure modalities, such as X-Ray mammography, MRI and ultrasound. Thermology does not replace other diagnostic modalities but rather they add to its diagnostic power and complement it as part of a comprehensive program of screening. Thermology is especially useful in instances where the diagnostic power of X-Ray mammography is compromised; such as for women who are pre-menopausal, have used hormone replacement therapy (HRT), have glandular or dense breasts, have fibrocystic disease, had prior biopsies, have implants or had breast reduction, are pregnant, are nursing or have small or large breasts. Thermology has a very high (approx. 95%) sensitivity indicating breast cancer, however, the specificity of thermology for breast cancer is compromised by tissue inflammation, infection, hormone imbalances or certain rare types of blood vessel abnormalities. The presence of these conditions may cause false-positive findings, especially on initial studies of an individual. Over time and with repeated studies, a questionable thermology feature will either resolve, demonstrate stability or evolve to reveal features distinctive of breast cancer. False-negative errors are rare and usually a consequence of a latent (resting, non-growing) stage in the development of breast cancer. Masses, physical distortions and recent developments of skin thickening, rashes or discharge from the nipple require further evaluation regardless of the thermology findings.

About the Scoring System

In 1972, a group of breast cancer experts at the renowned Louis Pasteur University in Marseille, France established an objective scoring system for breast thermology that was validated in a 1975 large-scale clinical outcomes study at that institution. Termed the Marseille System, this method of scoring thermology for the risk of breast cancer is the international standard by convention. The Marseille System provides for a TH-1 – TH-5 scores as a means of indicating the statistical risk for breast cancer based on the discernment of specific thermology features termed Signs and Criteria. The Marseille System long predates the American College of Radiology's BI-RADS™ scoring system but is similar in concept and provides parallel indications.

Understanding This Report

The **TH-2** score defines a qualified normal result with moderate levels of thermal energy from regularly configured blood vessels that are symmetrically distributed in both breasts and responded normally to the functional (cold) challenge. TH-2 results are frequently associated with benign (non-cancerous) conditions such as hormonal imbalances, dense tissue and fibrocystic disease. The TH-2 score does not indicate breast cancer but it does not rule-out all possibility of breast cancer. Any concerning physical symptoms should not be ignored and other means of routine evaluation should not be neglected.

Ongoing breast care is a valuable part of an overall health plan and should include the review of breast thermology reports by primary care and specialist physicians. **Physicians** may obtain more information about breast thermology by reviewing the **PROFESSIONAL** section of <http://www.thermascan.com> website, requesting literature from us or directly speaking with our knowledgeable staff. © Copyright 2001-2014. This report format, its text and image color pallet are copyrighted and may not be duplicated or replicated in any manner. All Rights Strictly Reserved. Therma-Scan Reference Laboratory, LLC. 34100 Woodward Ave. Suite 100 Birmingham, MI 48009 USA. +248.593.8700 <http://www.thermascan.com>