



ANATOMY

HEARING & BALANCE

The human ear contains two components: auditory (cochlea) & balance (vestibular).

ARTICLE

04

**DID THIS ARTICLE
HELP YOU?
SUPPORT VEDA @
VESTIBULAR.ORG**

5018 NE 15th Ave.
Portland, OR 97211
1-800-837-8428
info@vestibular.org
vestibular.org

Anatomy of the Ear & Glossary of Terms

By Vestibular Disorders Association

ANATOMY

The human inner ear contains two divisions: the hearing (auditory) component—the **cochlea**, and a balance (vestibular) component—the **peripheral vestibular system**. Peripheral in this context refers to a system that is outside of the central nervous system (brain and brainstem). The peripheral vestibular system sends information to the brain and brainstem.

The vestibular system in each ear consists of a complex series of passageways and chambers within the bony skull. Within these passageways are **tubes (semicircular canals)**, and **sacs (a utricle and saccule)**, filled with a fluid called **endolymph**. Around the outside of the tubes and sacs is a different fluid called **perilymph**. Both of these fluids are of precise chemical compositions, and they are different. The mechanism that regulates the amount and composition of these fluids is important to the proper functioning of the inner ear.

Each of the semicircular canals is located in a different spatial plane. They are located at right angles to each other and to those in the ear on the opposite side of the head. At the base of each canal is a **swelling (ampulla)** and within each ampulla is a **sensory receptor (cupula)**.

MOVEMENT AND BALANCE

With head movement in the plane or angle in which a canal is positioned, the endo-lymphatic fluid within that canal, because of inertia, lags behind. When this fluid lags behind, the sensory receptor within the canal is bent. The receptor then sends impulses to the brain about movement.

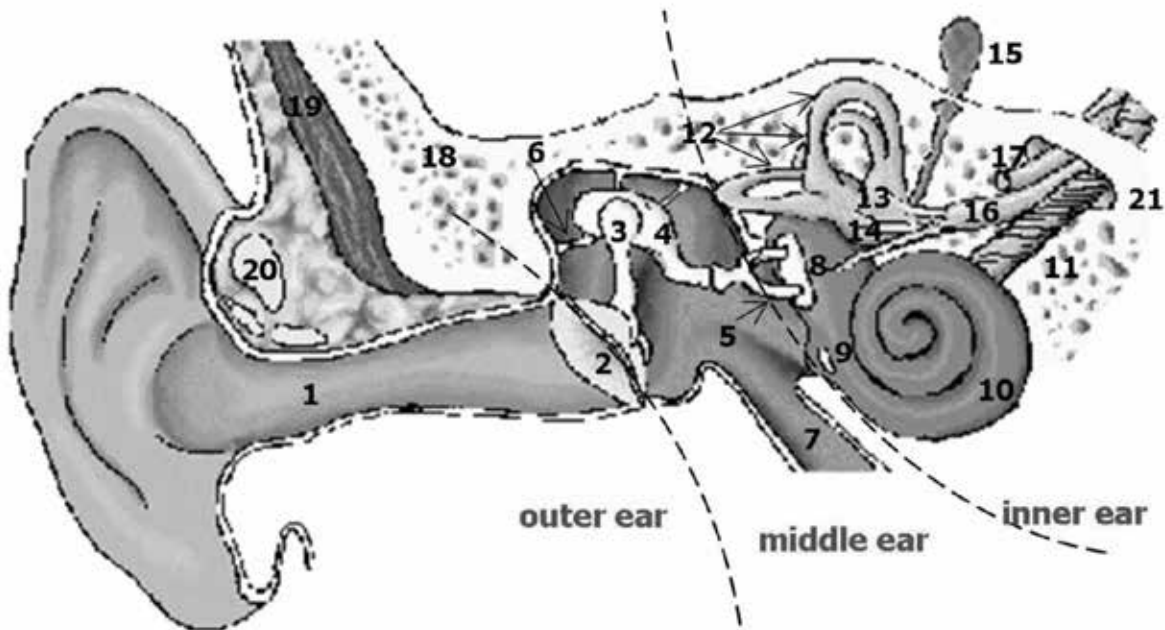
When the vestibular apparatus on both sides of the head are functioning properly, they send symmetrical impulses to the brain. That is, the impulses coming from the right side conform to (agree with) the impulses coming from the left side.

In response to the nerve impulses from the peripheral vestibular system, the brain sends commands to the eyes—enabling clear vision during movement and to the muscles of the body—so that balance is maintained during position changes and movement.



Ear Anatomy

© Vestibular Disorders Association



- | | | |
|--------------------------------|-------------------------|--------------------------------------|
| 1. external auditory canal | 8. oval window | 15. endolymphatic sac |
| 2. tympanic membrane (eardrum) | 9. round window | 16. vestibular nerve |
| 3. malleus | 10. cochlea | 17. facial nerve |
| 4. incus | 11. cochlear nerve | 18. temporal bone |
| 5. stapes | 12. semicircular canals | 19. muscle |
| 6. ligament | 13. utricle | 20. cartilage |
| 7. Eustachian tube | 14. saccule | 21. internal auditory canal to brain |

GLOSSARY

auditory: related to the sense of hearing.

canalithiasis: the theory of BPPV (*Benign Paroxysmal Positional Vertigo*), where free-floating debris can migrate into a semicircular canal and cause short episodes of vertigo when it moves within the canal.

central vestibular system: parts of the central nervous system (brain and brainstem) that process information from the peripheral vestibular system about balance and spatial orientation.

cochlea: portion of the inner ear concerned with hearing.

cochlear implant: a prosthetic device that, unlike hearing aids which amplify sound, bypass the

outer, middle, and inner ear and directly stimulate auditory nerve fibers.

conductive hearing loss: hearing loss produced by abnormalities of the outer ear or middle ear. These abnormalities create a hearing loss by interfering with the transmission of sound from the outer ear to the inner ear.

cupulolithiasis: a variant of BPPV in which the debris is stuck to the cupula of a semicircular canal rather than being loose within the canal.

disequilibrium: unsteadiness, imbalance, or loss of equilibrium; often accompanied by spatial disorientation (a sensation of not knowing where one's body is in relation to the vertical and horizontal planes).



dizziness: lightheadedness; does not involve a rotational component (see [vertigo](#)).

endolymph: the fluid within the semicircular canals and vestibule (utricle and saccule).

Eustachian tube: connects the middle ear space with the throat; maintains equal air pressure on both sides of the tympanic membrane (eardrum).

labyrinth: complex system of chambers and passageways of the inner ear; includes both the hearing and balance portions of the inner ear.

labyrinthitis: an inflammation of the labyrinth.

middle ear: air-filled cavity containing the ossicles and tympanic membrane, the function of which is to transfer sound energy from the outer ear to the cochlea of the inner ear.

mixed hearing loss: hearing loss produced by abnormalities in both the conductive and sensorineural mechanisms of hearing.

nystagmus: involuntary, alternating, rapid and slow movements of the eyeballs.

ossicles (incus, malleus, stapes): tiny bones of the middle ear that conduct sound from the tympanic membrane to the oval window of the inner ear.

otoliths: calcium carbonate crystals found in the utricle and saccule of the inner ear. Damage to the otoliths may lead to BPPV.

oval window: oval-shaped opening from the middle ear into the inner ear. The footplate of the stapes fits into the oval window.

perilymph: the fluid that fills the space between the semicircular canals and vestibule (utricle and saccule) and the surrounding bone.

peripheral vestibular system: parts of the inner ear concerned with balance and body orientation; consists of the semicircular canals, utricle, and saccule. Peripheral in this context means outside the central nervous system (brain and brainstem), to which the peripheral system sends information.

perilymph fistula: abnormal opening that permits perilymph from the inner ear to leak into the middle ear.

pinna: external, visible portion of the ear.

Its primary function is to carry sounds to the middle ear. Also called the **auricle**.

round window: membrane-covered opening between the inner ear and the middle ear.

saccule: sac-like inner ear organ containing otoliths; senses vertical motion of the head.

sensorineural hearing loss: hearing loss produced by abnormalities of the cochlea or the auditory nerve or of the nerve pathways that lead beyond the cochlea to the brain.

temporal bone: part of the skull in which the inner ear is located.

tinnitus: noise or ringing in the ears.

tympanic membrane: eardrum; separates the external ear canal from the middle-ear air cavity.

utricle: sac-like inner ear organ containing otoliths; senses forward, backward, and side-to-side motion of the head.

vertigo: perception of movement (either of the self or surrounding objects) that is not occurring or is occurring differently from how it is perceived.

vestibulo-cochlear nerve: nerve that carries information from the inner ear to the brain. Also called the **eighth cranial nerve**, **auditory nerve**, or **acoustic nerve**.

©2014 Vestibular Disorders Association
VeDA's publications are protected under copyright.
For more information, see our permissions guide at
vestibular.org. ***This document is not intended as a substitute for professional health care.***



