



DISORDERS

FREQUENT ATTACKS

Nerve compression or irritation leads to frequent attacks of vertigo and unsteadiness.

ARTICLE

102

**DID THIS ARTICLE
HELP YOU?
SUPPORT VEDA @
VESTIBULAR.ORG**

5018 NE 15th Ave.
Portland, OR 97211
1-800-837-8428
info@vestibular.org
vestibular.org

Vestibular Paroxysmia

By Danielle Beatty, DPT, based on the consensus statement by the Barany Society *

Vestibular paroxysmia is an episodic vestibular disorder which usually presents with a high frequency of attacks. This disorder was first described by Jannetta in 1975 as “disabling positional vertigo.” It is also known as *microvascular compression syndrome (MVC)*. MVC is a syndrome of vestibular or positional auditory symptoms that respond to treatment with medications for neuralgia and in which other reasonable causes (i.e. Meniere’s disease, migraine, labyrinthitis, fistula) have been excluded. The course of the disease is usually chronic (i.e. longer than three months) with some patients suffering hundreds of attacks per year.

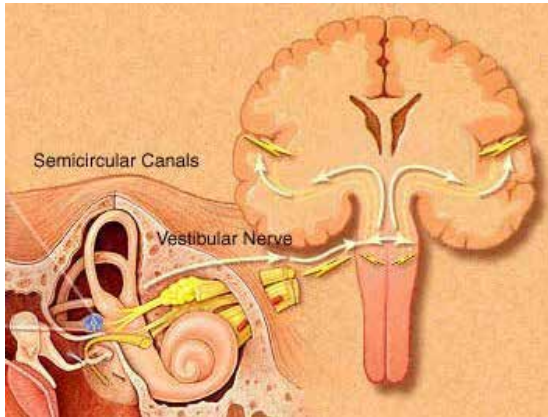
It is assumed that vestibular paroxysmia occurs due to compression of the *eighth cranial nerve* (otherwise known as the *vestibulocochlear nerve*) by an artery. This nerve supplies the inner ear (which assists with balance) and the *cochlea (the organ of hearing)*. Timothy Hain, MD, notes some controversy regarding the exact cause of this nerve compression, stating that symptoms seem to be due to nerve irritation, and that there are many other potential causes of nerve irritability besides vascular compression. He summarizes that the key features of this syndrome suggest an electrical problem. Thus, the exact cause of this nerve compression/irritation is unknown.

SYMPTOMS OF VESTIBULAR PAROXYSMIA INCLUDE:

- Attacks of spinning or non-spinning vertigo lasting a fraction of a second to a minute or more
- Attacks are usually very frequent, i.e. a few attacks per month to 30 attacks per day
- Most attacks occur spontaneously (“out of the blue”); some are provoked by head movements or by hyperventilation
- Unsteadiness if attacks occur while standing or walking
- Tinnitus (ringing) of one ear during the attack
- Sensitivity to sound during the attack
- Attacks are usually chronic lasting 3 months or longer



Diagnosis of this condition is often based on the patient's symptoms. It is important for your doctor to rule out other diagnoses, including Meniere's disease, vestibular migraine, benign paroxysmal positional vertigo (BPPV), epileptic visual aura, multiple sclerosis (MS), stroke/ mini strokes, superior canal dehiscence syndrome, perilymph fistula, and panic attacks.



Anatomy of the 8th Cranial Nerve
© Northwest University

MRI has been used to visualize the compression of the 8th cranial nerve. However the role of imaging to diagnose and identify the affected side is not clear, as there is a high rate of vascular compression of the 8th cranial nerve in healthy subjects.

Doctors have found that treatment with anti-seizure medication (carbamazepine/ oxcarbazepine) has been shown to reduce the intensity, frequency, and duration of attacks. A positive response to these medications helps to support the diagnosis of vestibular paroxysmia. Surgical treatment is not recommended.

Diagnostic criteria for definite and probable vestibular paroxysmia are listed below.

DEFINITE VESTIBULAR PAROXYSMIA:

- At least 10 attacks of spinning or non-spinning vertigo
- Duration less than 1 min
- Occurs spontaneously
- Stereotyped phenomenology in a particular patient
- Response to treatment with carbamazepine/ oxcarbazepine
- Not better accounted for by another diagnosis

PROBABLE VESTIBULAR PAROXYSMIA:

- At least 5 attacks of spinning or non-spinning vertigo
- Duration of less than 5 min
- Occurs spontaneously or provoked by certain head movements
- Stereotyped phenomenology in a particular patient
- Not better accounted for by another diagnosis

If you are experiencing symptoms of vertigo, consult your doctor for more information.

REFERENCES

1. Strupp M, Lopez-Escamez J, Kim J, et al. Vestibular paroxysmia: Diagnostic criteria. *J Vestib Res.* 2016;26(5-6):409-415
2. Strupp M, Hübner K, Brémová T, Bayer O. A randomized double-blind, placebo-controlled, cross-over trial (Vestparoxy) of the treatment of vestibular paroxysmia with oxcarbazepine. *J Neurol.* 2018; 265(2): 291-298.
3. Jannetta PJ. Neurovascular cross-compression in patients with hyperactive dysfunction symptoms of the eighth cranial nerve. *Surg Forum.* 1975;26:467-469.
4. Hain T. Microvascular compression syndrome, Vestibular Paroxysmia, and Quick Spins. *Dizziness and Balance Website.* <https://www.dizziness-and-balance.com/disorders/unilat/microvascular.htm>.

* The Barany Society is an international community of basic scientists, otolaryngologists, and neurologists who use vestibular research to generate consensus statements regarding vestibular conditions. This article summarizes their diagnostic criteria for vestibular paroxysmia.

©2019 Vestibular Disorders Association
VeDA's publications are protected under copyright. For more information, see our permissions guide at vestibular.org. ***This document is not intended as a substitute for professional health care.***

NOTES:
VESTIBULAR DISORDERS ASSOCIATION

5018 NE 15th Ave. Portland, OR 97211
 1-800-837-8428 info@vestibular.org vestibular.org

Did this free publication from VeDA help you?

You can ensure that educational articles like this continue to be available to vestibular patients like you by making a tax-deductible gift to VeDA today.

SUPPORT VEDA

One-time gift: \$40 \$50 \$75 \$100 \$250 other

Monthly gift: \$10 \$15 \$25 \$35 \$50 other

Check this box if you prefer that your donation remain anonymous.

PAYMENT INFORMATION

Donations gladly accepted online at <http://vestibular.org>. Check or money order in US funds, payable to VeDA.

Visa MC Amex Discover _____
Card number Exp. date CVV code

Billing address of card (if different from mailing information)

MAILING INFORMATION

Name _____ Telephone _____ Email _____
 Address _____ City _____ State/Province _____ Zip _____
 Country _____