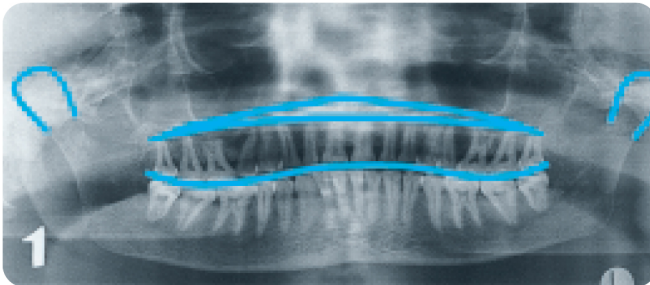


Orthophos Image Quality

Potential errors in positioning

1



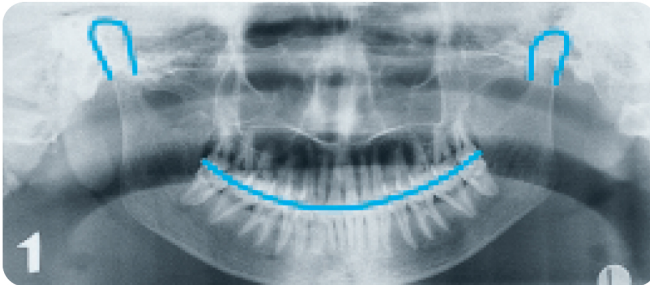
Symptoms

- The root apices of the maxillary teeth are hidden due to overlapping by hard gums
- Rows of teeth appear in the form of a wave
- The temporo-mandibular joints are inclined too far outwards
- The mandible was more sharply displayed than the maxilla

Cause

- The patient's head was tilted backwards
- The "Frankfurt Horizontal Plane" was not heeded when positioning

2



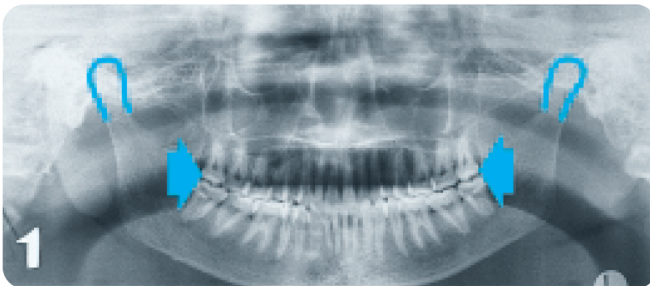
Symptoms

- The root apices of the mandibular front teeth are unsharp
- The rows of teeth are inclined upwards on each side
- The temporo-mandibular joints are inclined upwards on each side

Cause

- The patient's head was tilted too far forward
- The "Frankfurt Horizontal Plane" was not heeded when positioning

3



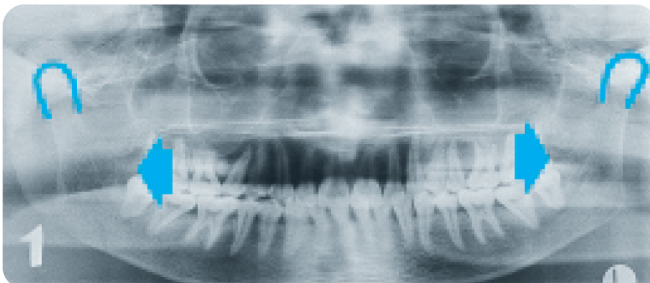
Symptoms

- The maxillary and mandibular front teeth and canines appear unsharp
- Overlapping in molar and pre-molar area
- Teeth appear crowded together

Cause

- The patient's head was positioned too far forward
- A bite-wing device was not used or was used incorrectly or the lateral positioning light lines (OP5/OP10) were not heeded
- The chin support was set too far to the front

4



Symptoms

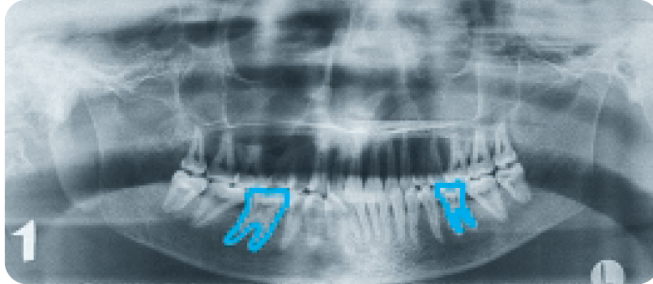
- The maxillary and mandibular front teeth and canines appear unsharp
- The rows of teeth appear "stretched apart"
- The temporo-mandibular joints project too far outwards

Cause

- The patient's head was positioned too far backwards
- A bite-wing device was not used or was used incorrectly or the lateral positioning light lines (OP5/OP10) were not heeded
- The chin support was set too far back (OP10)

Potential errors in positioning

5



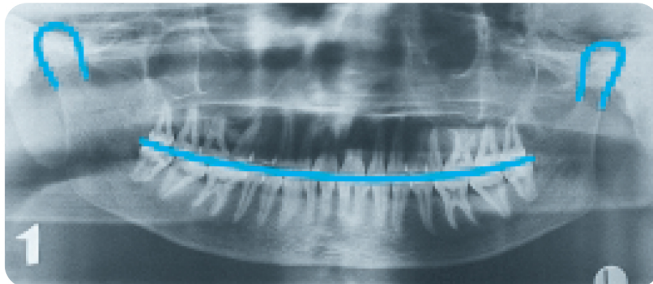
Symptoms

-Magnification of the maxillary and mandibular premolars and molars; on opposite sides of the mouth and the mirrored tooth appears smaller

Cause

-The patient's head was not in a central position
-The front teeth were not positioned using the centralizing beam of the visualizer (OP5, OP10 & ORTHOPHOS 5, Plus CD, Plus DS, Plus DS Ceph, Plus Ceph)

6



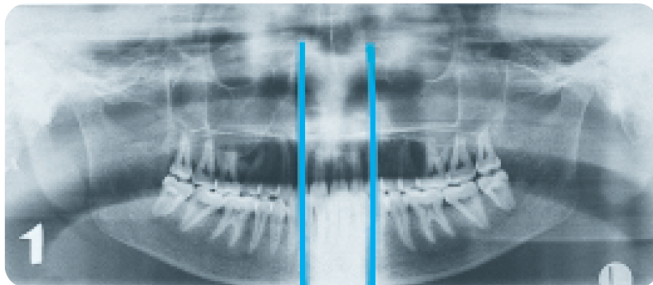
Symptoms

-The Axes of the front teeth lie obliquely
-One temporo-mandibular joint lies higher than the other
-A slight bilateral distortion of premolars and molars

Cause

-The patient's head was tilted to the side
-The patient's head was not positioned vertically using the centralizing beam of the visualizer (OP5, OP10 & ORTHOPHOS 5, Plus CD, Plus DS, Plus DS Ceph, Plus Ceph)

7



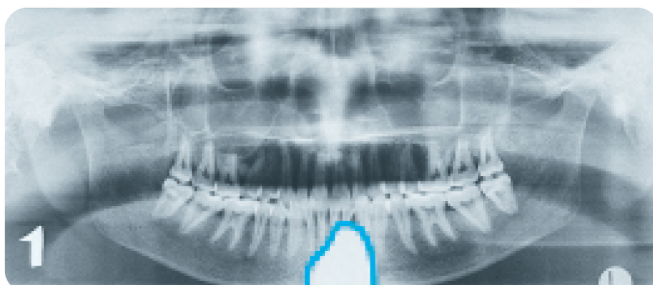
Symptoms

-The area of the front teeth is too bright and vague

Cause

-The spine was not stretched/patient was not standing straight
-The patient should have taken a small step forward in order to ensure correct posture

8



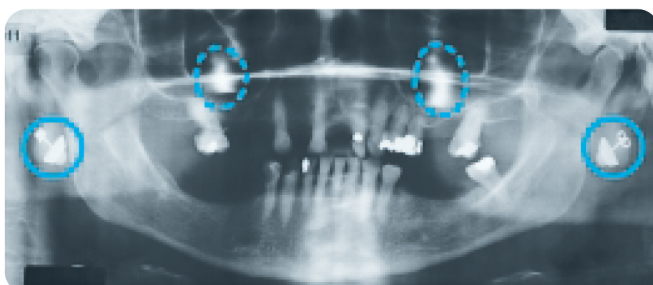
Symptoms

-Unexposed triangular "blank spot" originating from lower film edge

Cause

-The protective apron was placed too high on the patient's chest

9



Symptoms

-Irregular "bright spots" in the region of the upper and lower jaw

Cause

-The patient is wearing jewelry, hair pins or glasses, which are reproduced and/or reflected elsewhere in the image