



East of England Radiotherapy Network: Rectum Protocol V4.0

Contents

1.0 Indications and patient population	2
1.1 Curative treatment eligibility.....	2
1.1.a Inclusion criteria	2
1.1.b Exclusion criteria	2
1.1.c Essential Pre-Radiotherapy investigations for curative patients.....	3
2.0 Localisation.....	4
3.0 Dose prescription & chemotherapy.....	5
4.0 Target volumes.....	6
4.1 Curative radiotherapy GTV/CTV	6
Gross Tumour Volume (GTV).....	6
Internal clinical target volume (ICTV)	6
4.2 Palliative radiotherapy.....	12
5.0 Organs at risk.....	12
5.1 Dose Constraints (SCRT)	13
5.2 Dose Constraints (LCRT)	13
6.0 Planning process/ technique	14
7.0 Peer Review/ Contour QA.....	14
8.0 Target verification	15
9.0 Side effects	15
10.0 References.....	21
11.0 Members of the protocol drafting committee	22
12.0 Amendment History	23

EofE RTN Rectum Protocol V4

Date Agreed: 05 2026

Date to be reviewed: 05 2027





1.0 Indications and patient population

This protocol covers treatment in the following situations:

- a. Preoperative short course radiotherapy (SCRT) with the aim to reduce local relapse rates and to increase R0 resection rate
- b. Preoperative long course radiotherapy (LCRT) with the aim to reduce local relapse rates and to increase R0 resection rate
- c. Postoperative radiotherapy- Positive CRM of $\leq 1\text{mm}$
- d. Neoadjuvant chemotherapy and long course/short course radiotherapy \pm chemotherapy (Total Neo-adjuvant Therapy)
- e. Palliative radiotherapy to the rectum

1.1 Curative treatment eligibility

1.1.a Inclusion criteria

- Biopsy confirmed adenocarcinoma of the rectum (accept without biopsy if the MDT in agreement after repeated biopsy failure)
- Locally advanced rectal carcinoma confirmed on imaging
 1. T any, N1 or N2
 2. T3-T4, N0
 3. CRM positive or threatened
 4. EMVI positive
 5. Positive lateral nodes
 6. Planned AP excision and low/anterior tumour (at the surgeons/oncologist's discretion)
- Adequate performance status and functional reserve (ECOG 0-1, exceptionally 2)

1.1.b Exclusion criteria

1. Early-stage rectal cancer T1- T2, N0 (unless in a trial setting)
2. Relative contraindications:
 - Previous pelvic radiotherapy
 - Active inflammatory bowel disease
 - History of connective tissue disorder





1.1.c Essential Pre-Radiotherapy investigations for curative patients

- Bloods- FBC, U+Es, LFT, Mg as indicated for chemotherapy, CEA
- Digital Rectal Examination
- Colonoscopy and biopsy +/- endoscopic ultrasound (EUS) if MDT advised
- CT chest and abdomen and pelvis (consider repeat imaging post-op for adjuvant RT)
- MRI of the pelvis
- DPYD testing before chemotherapy
- FDG-PET (optional)





2.0 Localisation

Localisation	Notes	
Position	Preferably supine	Supine position to be used with comfortably full bladder (>250ml) using local bladder filling protocol. Prone with comfortably full bladder can be used at the consultant's discretion. For patients where disease extends to the anus and an anal bolus is required, placing the patient prone may be preferred by some centres.
Immobilisation and supports		If supine: Head rest and ankle and knee support are required. Arms on the chest. If prone: Prone pillow and ankle stockings and arms above head.
Organ pre-requisites		Anal marker to be requested at the time of referral if required and should be considered as a reference point especially for low rectal cancer.
Contrast		The use of intravenous and/or oral contrast to aid delineation of pelvic vessels, small bowel loops and GTV is recommended.
CT acquisition	Slice thickness:	2-3mm
	Scanning limits	Superior aspect of L2/3 vertebra For PA nodes: T10
	Scanning limits	4 cm below the lesser trochanter

EofE RTN Rectum Protocol V4
Date Agreed: 05 2026
Date to be reviewed: 05 2027

3.0 Dose prescription & chemotherapy

Intent	Dose (Gy)/#	#/week	Comments
a. Preoperative Short Course Radiotherapy (SCRT)	25/5	5	Neoadjuvant chemotherapy can be considered for more advanced tumours (RAPIDO criteria): T4 N2 or enlarged lateral node EMVI Mesorectal fascia (MRF) positive
b. Preoperative long course radiotherapy (LCRT)	45/25	5	Concurrent chemotherapy should be delivered unless there are contraindication or concerns regarding their ability to tolerate treatment. Neoadjuvant/post-radiotherapy chemotherapy can be considered for more advanced tumours (RAPIDO criteria): T4 N2 or enlarged lateral node EMVI Mesorectal fascia (MRF) positive
c. Preoperative LCRT with simultaneous integrated boost (SIB)	45/25 or Boost: 50/25 or 52/25	5	Consider SIB to higher risk tumours: T4 disease (bulky primary), N2 (heavy nodal burden), EMVI, for organ preservation and disease outside CRM. Deliver either as SIB (total of 50 Gy in 25 # to the boost volume) or as a phase 2 boost (5.4 Gy in 3 #). SIB of 52 Gy/25# or total of 54Gy/30# via phase 2 boost can be considered for organ preservation or disease outside CRM.
d. Adjuvant LCRT (Elective and postoperative bed)	45/25 or Boost: 50/25 or 52/25	5	Consider a SIB (50-52/25#) if residual macroscopic disease is present or R1 resection has been performed and the site of R1 can be identified by clips or landmarks.
e. Palliative radiotherapy	30 – 36 20 – 25 8	10 – 12 5 1	An appropriate regime should be chosen after considering the patients likely prognosis, disease burden, symptoms, and performance status. Palliative re-irradiation can be offered for symptom control e.g., to stop bleeding or pain. Dose and fractionation should be individualised.

Concurrent Chemotherapy:

Capecitabine 825mg/m² twice daily to be taken Monday-Fridays only for 5-6 weeks with long-course radiotherapy.

Alternatively, 5FU 225mg/m² given over 24 hour's infusion for 5 days/week during radiotherapy.

EofE RTN Rectum Protocol V4

Date Agreed: 05 2026

Date to be reviewed: 05 2027





4.0 Target volumes

4.1 Curative radiotherapy GTV/CTV

See National Rectal Cancer IMRT Guidance (RCR) for a full description of target volume definition. https://www.rcr.ac.uk/system/files/publication/field_publication_files/bfco211-rectal-imrt-guidance.pdf

Gross Tumour Volume (GTV)

This encompasses the macroscopic primary tumour (primary, nodal, and extramural vascular invasion) or residual macroscopic disease seen on postoperative imaging. This information is derived from diagnostic imaging (pelvic MRI, CT Pelvis and PET-CT if available).

- **GTV primary tumour (GTVp)**

This encompasses the macroscopic primary tumour, areas of adjacent EMVI or postoperative macroscopic disease identified on imaging. If the tumour can be confidently identified the GTVp does not need to encompass the whole lumen.

- **GTV primary tumour boost (GTVp_Boost)**

This is the area of the tumour that would benefit from a boost. The indication for this will be at the discretion of the treating clinician (please refer to section 3).

- **GTV nodes (GTVn)**

All nodes involved with tumour agreed at MDT.

- **GTV nodes (GTVn_Boost)**

This is the area of the GTVn that would benefit from a boost. The indication for this will be at the discretion of the treating clinician (please refer to section 3).


Internal clinical target volume (ICTV)

ICTV is the CTV that includes a margin for motion. It should encompass areas of microscopic spread beyond the defined GTV. Two distinct volumes should be delineated ICTV primary tumour (ICTVp) and ICTV nodes (ICTVn). The ICTVp, ICTVn, ICTVsb (if present, surgical bed for post-operative cases) and are then combined to form the final ICTV (ICTV_Final).

- **ICTVp_xxxx**

This is the defined GTVp + 10mm in all directions except anteriorly where 15mm





can be considered for tumours that may be anteriorly more mobile (tumour above the peritoneal reflection). A boost can be considered (ICTVp_Boost) if clinically indicated.

The ICTVp_XXXX should be edited off all bone except posteriorly towards the sacrum. The ICTVp_XXXX should be edited off pelvic muscles unless there are positive obturator nodes. In this case the obturator internus muscle on the involved side should be included.

- **ICTVn_XXXX**

GTVn + 5mm in all directions. A boost can be considered (ICTVn_Boost) if clinically indicated. The ICTVn_XXXX should be edited off all bone except posteriorly towards the sacrum. The

- **ICTV elective nodal groups (ICTVe_XXXX)**

All elective nodal groups combined. This should include nodal compartments of the mesorectum, presacral, obturator, internal iliac nodes and nodes surrounding Inferior mesenteric artery (IMA) and Superior rectal artery (SRA).

A 1cm margin should be added anterior to the mesorectum due to motion. The ICTVe_XXXX should be 2 cm above the most superior node at outset. If there is radiological evidence of nodal involvement in any other nodal compartments, consider including the whole compartment (For example, external iliac/inguinal lymph nodes).

ICTVe_XXXX delineation guide:

Pre-sacral nodes (PN) are lymph nodes within a thin space between the rectum and the sacrum. There are two sub-volumes: the abdominal and the pelvic PN. The abdominal PN start at the bifurcation of the aorta and end at the sacral promontory. The pelvic PN start at the level of the sacral promontory ending at the caudal end of the mesorectum.

Internal iliac nodes (IIN) are lymph nodes adjacent to the internal iliac artery and its branches. They lie anterior to the sacrum.

The mesorectum is the fat around the rectum bounded by the mesorectal fascia. The mesorectum begins at the rectosigmoid junction and can be identified by the bifurcation of the inferior mesenteric artery (IMA) into the superior rectal artery (SRA) and the sigmoid artery (SA). It extends to the end of the rectum at the level of the levator ani.

EofE RTN Rectum Protocol V4

Date Agreed: 05 2026

Date to be reviewed: 05 2027



Obturator nodes are lymph nodes adjacent to the obturator artery. Typically identified once the obturator internus is visible and ends at the point the obturator artery exits the pelvis.

The superior limit is at the level of the S1/S2 interspace or 2cm above the superior limit of the GTV, whichever is higher.

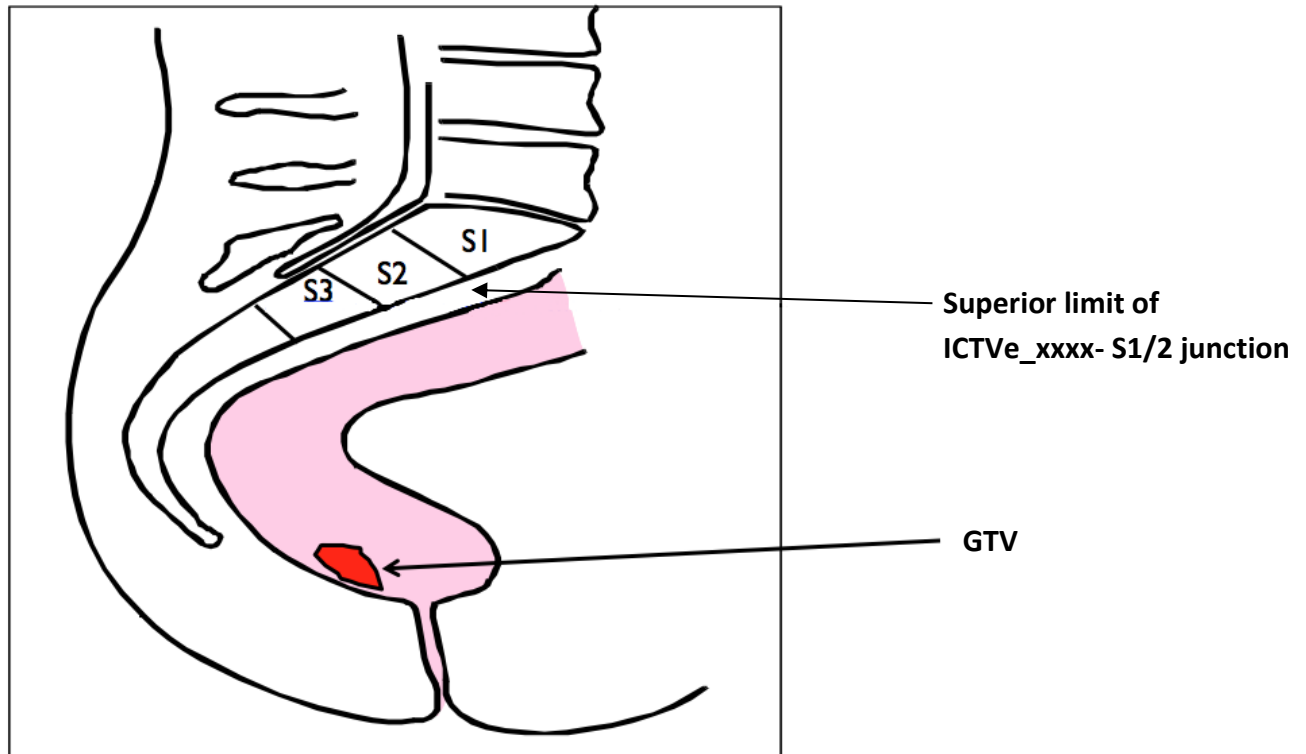


Figure 1: Superior limit of ICTVe_xxxx

Start at this level and outline the internal iliac vessels tracing them inferiorly and posteriorly until reaching the level of the obturator internus muscle with a 7mm margin around the vessels. Join all outlined areas with a 10mm roller ball to ensure coverage of PNs. This should extend to the anterior wall of the vertebrae.

Manually edit the volume to exclude the piriformis and iliopsoas muscle and to include the sacral notch.



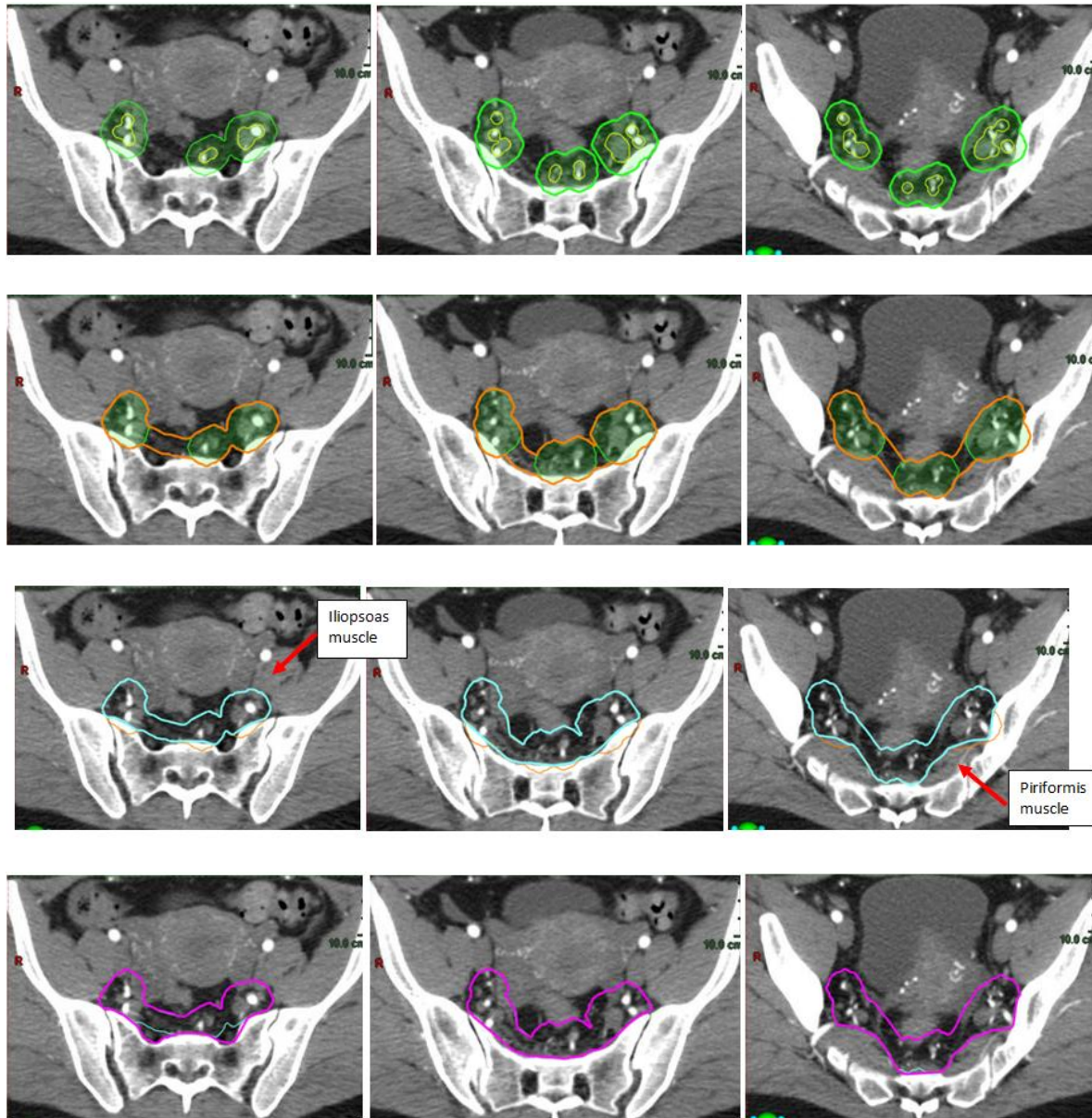


Figure 2: Delineation of PN and IINs

At the level of the superior border of the mesorectum (defined as either the bifurcation of IMA into the SA and SRA or at the anterior border of S2/3) delineate the whole mesorectum with an additional 1cm anteriorly for motion (when in contact with organs such as bladder, uterus, or prostate). The posterior border should extend to the anterior surface of the sacrum and coccyx to the level of the ischio-rectal fossae.

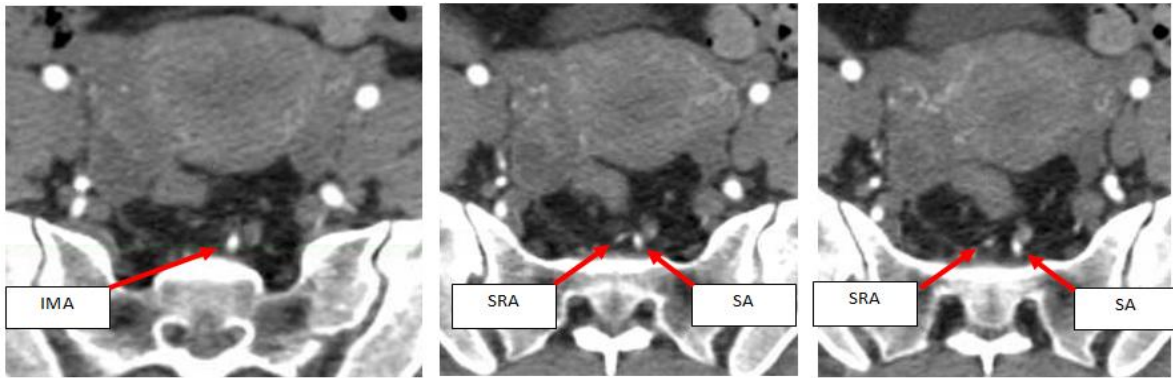


Figure 3: Superior border of the mesorectum

Continue delineating the mesorectum inferiorly until insertion of the levator ani muscle into the external sphincter muscle or 2cm below the inferior GTVp slice, whichever is lower. The levators should be included in the volume with the border being the outer wall of levator.

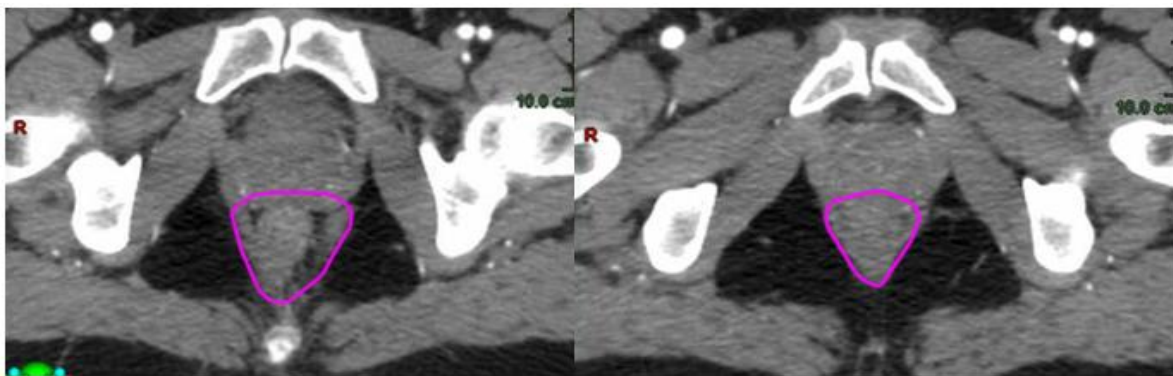


Figure 4: Delineation of the mesorectum

Ensure coverage of the obturator nodes by identifying the superior border of the obturator internus muscle. Use a 17mm rollerball to ensure the volume covers the medial aspect of this muscle until the obturator artery moves laterally to the muscle. Once the obturator artery is lateral to the obturator internus muscle contouring can stop.

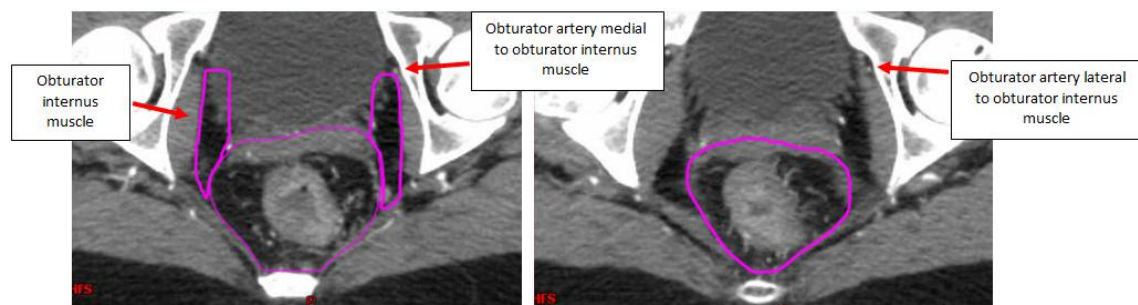


Figure 5: Contouring of ON and its inferior border

Borders of CTVe xxxx

	Superior	Inferior	Lateral	Medial	Anterior	Posterior
Internal Iliac Nodes	Anterior border of the S1/S2 junction, or 2cm above the highest superior involved node (including those present prior to neo-adjuvant chemo).	Superior border of the obturator nodes at the most superior part demonstrating the obturator internus.	Upper pelvis: iliopsoas muscle. Lower pelvis: medial edge of obturator internus.	Upper pelvis: 7mm medial to internal iliac vessels. Lower pelvis: mesorectum and presacral space.	Upper pelvis: 7mm anterior to the internal iliac vessels. Lower pelvis: obturator internus or bone.	The bony pelvis.
Obturator nodes	At the most superior slice demonstrating the obturator internus, the inferior border of the internal iliac nodes.	At the point the obturator artery exits the pelvis. This is identified by the obturator artery moving lateral to the obturator internus.	The obturator internus muscle (unless there are pelvic side-wall nodes where the bony sidewall should be used).	Anterior: 17mm from obturator internus muscle, include areas of bladder if present. Posterior: The mesorectal volume.	The anterior extent of the obturator internus muscle.	The sacroiliac joint or the pyriformis.
Mesorectal Nodes	Either the anterior border of the S2/3 junction or, if it can be identified, the bifurcation of the inferior mesorectal artery into the superior rectal and the sigmoid artery.	Insertion of the levator ani muscle into the external sphincter muscles (disappearing of the mesorectal fat around the rectum). The inferior border should be 2cm below the inferior GTVp slice.	Upper/mid: Mesorectal fascia if visible or medial border of the internal iliac nodes/obturator nodes. Lower: Lateral edge of levator ani muscle.	Superior: 7mm anterior to superior rectal artery or inferior mesorectal artery. This may match with 1 cm presacral anterior margin at S1/S2. Mid/inferior: 10mm anterior to the mesorectal fascia into the organs. (penile bulb / prostate and SV / bladder in males; bladder / vagina / cervix / uterus in females)	Anterior surface of the sacrum and coccyx to the level of ischio-rectal fossae (including the medial part of the presacral space).	
Pre-sacral Nodes	See superior border of internal iliac	Caudal border of the mesorectum	Sacro-iliac joints.		10mm anterior to the anterior vertebrae/sacral border or 7mm anterior to the SRA/IMA, whichever is more superior.	Anterior wall of the vertebrae, include sacral nerve root, exclude iliopsoas.

EofE RTN Rectum Protocol V4
Date Agreed: 05 2026
Date to be reviewed: 05 2027





PTVp_ xxxx is defined as the ICTV_Final + 5mm in all directions with daily online volumetric imaging.

If daily online imaging is not performed, then an ICTV_Final + 10mm in all directions should be used.

PTVe_ xxxx is CTVe_ xxxx plus 5mm margin.

4.2 Palliative radiotherapy

For palliative treatments, contour GTV and add margin to PTV according to centre set-up. Consider formal contouring as previous for 3D conformal treatment.

5.0 Organs at risk

Aim for the use of standard nomenclature as per Global Harmonization Group consensus guidelines:

<https://www.thegreenjournal.com/action/showPdf?pii=S0167-8140%2820%2930294-2>

Structure Name	Description
Bowel_Small Spc_Bowel	Contouring should include all individual small bowel loops to at least 20mm above the superior extent of both PTVs. Alternatively, a bowel cavity can be contoured. Contour abdominal contents inferiorly; from the most inferior small or large bowel loop (excluding the rectum), whichever is most inferior, and contour to 2cm superior to PTV. Ensure CTV, muscles, major vasculature (common, internal, and external iliac vessels), bladder and uterus are excluded.
Bladder	Inferiorly contour outer wall from its base to superiorly to its dome.
FemurHeadNeck_L and FemurHeadNeck_R	To be contoured separately on each side. The femoral ball, neck, greater and lesser trochanter, and proximal femoral shaft should be contoured as a single structure. Start superiorly at the cranial edge of femoral ball to the caudal aspect of the lesser trochanter inferiorly.
External genitalia	Male: delineation should include penis and scrotum. Female: delineation should include the clitoris, labia majora and minora. The lateral extent is the inguinal creases. Cranially this will extent to the level of the mid symphysis pubis. Optional for low rectal cancer





5.1 Dose Constraints (SCRT)

Structure name	Constraint	Optimal	Mandatory
Bowel_Small	D200cc	<20Gy	
	D150cc	<22Gy	
	D20cc	<25Gy	
Bladder	D45%	<21Gy	
Bowel_Cavity	D400cc	<10Gy	
	D250cc	<18Gy	
	D200cc	<23Gy	

5.2 Dose Constraints (LCRT)

Structure name	Constraint	Optimal	Mandatory
Bowel_Small	D180cc	<35Gy	
	D100cc	<40Gy	
	D65cc	<45Gy	
	D0.5cc	-	<52.5Gy
FemurHead_L/R	D50%	<30Gy	<45Gy
	D35%	<40Gy	<50Gy
	D5%	<50Gy	<52.5Gy
Bladder	D50%	<35Gy	<45Gy
	D35%	<40Gy	<50Gy
	D5%	<50Gy	<52.5Gy
Genitalia	D50%	<20Gy	<35Gy
	D35%	<30Gy	<40Gy
	D5%	<40Gy	<52.5Gy
Bowel_Cavity	D400cc	<20Gy	
	D250cc	<30Gy	
	D200cc	<43Gy	<47.5Gy

EofE RTN Rectum Protocol V4

Date Agreed: 05 2026

Date to be reviewed: 05 2027





6.0 Planning process/ technique

- IMRT, VMAT and TomoTherapy are acceptable treatment techniques
- Beam entry should avoid the stoma and should be moved outside the treatment fields, if possible, to minimise unintended bolus effects
- Conformal or simple field arrangements can be used for palliative treatments
- **Target objectives:**

Volume	OAR/Target	Optimal constraints
PTVp_xxxx	D99% D95% D50% D2%	>90% >95% =100%±2% <105%
PTVe_xxxx	D99% D95% D50%	>90% >95% =100%±2%
PTVe_xxxx_Eval (PTVe_xxxx cropped 5mm from PTVp_xxxx)	V107%	<15%

7.0 Peer Review/ Contour QA

- Radiology support for target volume definition would be recommended in keeping with national guidance
- All curative and adjuvant volumes should be prospectively peer reviewed before the start of treatment
- A description of the contouring (planning note) and of the peer review process including changes made should be saved in the patient record
- The peer review process and outcomes should be audited





8.0 Target verification

Modality	Frequency	Match point	Additional information
kV planar/ CBCT	Daily CBCT (mandatory for SCRT) kV if CBCT not possible	Automated bony match using a ROI/clipboxes placed around PTV.	

9.0 Side effects

Formally review and record side effects using relevant grading scale.

9.1 Possible early or short-term side effects	
Expected (50-100%)	Initial management (if appropriate)
Tiredness	Recommend light exercise as tolerated
Common (10-50%)	Initial management (if appropriate)
Bowel frequency	
Looser stools	WHO toxicity grade <ul style="list-style-type: none"> • Grade 1: Increase of 2-3 stools per a day over pre-treatment • Grade 2: Increase of 4-6 stools per day, or nocturnal stools with moderate cramping • Grade 3: Increase of 7-9 stools per a day, or incontinence or severe cramping • Grade 4: Increase of >10 stools per day, or bloody diarrhoea or need for parenteral support

EofE RTN Rectum Protocol V4
Date Agreed: 05 2026
Date to be reviewed: 05 2027





	<p>Dietary advice: advise to avoid high fibre, high fat foods, spices, caffeine, alcohol, fruit juices and lactulose containing products if appropriate. Recommend adequate oral hydration and consider smaller frequent meals.</p> <ul style="list-style-type: none"> • G2 diarrhoea: continue with loperamide and oral rehydration, send stool for culture and C. difficile toxins • G3 diarrhoea: Loperamide, codeine, IV hydration and inpatient management as indicated. Continue radiotherapy but do not treat if localised peritonism; consider suspending chemotherapy • Consider broad spectrum antibiotics and GCSF if neutropenic (likely Cephalosporin and Metronidazole) • If G3 diarrhoea not controlled after above within 48hrs: commence s/c octreotide, titrate according to response. Total Parenteral nutrition should be discussed with the nutrition team • G4 diarrhoea: interrupt treatment, admit and provide full supportive treatment until resolved to G2 and reassess daily
Pain in abdomen/ anus	<p>Analgesia as per WHO pain ladder for proctalgia Consider cinchocaine with prednisolone suppositories for proctitis</p>
Bleeding from rectum	
Tenesmus	
Urinary frequency	<p>RTOG acute urinary toxicity grade</p> <ul style="list-style-type: none"> • Grade 1: urination or nocturia frequency twice pre-treatment habit • Grade 2: urination or nocturia that is less frequent than every hour. Dysuria, urgency, bladder spasms may be reported • Grade 3: urination with nocturia hourly or more frequently; with dysuria, pelvic pain, and bladder spasm. Gross haematuria with/without clots may be reported. <ul style="list-style-type: none"> • Grade 4; haematuria requiring transfusion and acute bladder obstruction <p>Dietary advice: encourage good oral hydration.</p>



	Antispasmodics: consider antispasmodics for bladder spasms.
Cystitis	Analgesia: consider oral analgesia for dysuria. Infection screening: check urine dip +/- MSU, consider antibiotics if appropriate.
Skin soreness, itching, blistering and colour changes	<p>RTOG</p> <ul style="list-style-type: none"> • Grade 1: Faint or dull erythema; mild tightness and itching of the skin may occur • Grade 2a: Tender or bright erythema; skin may feel tighter/itchy/sore • Grade 2b: Patchy moist desquamation; yellow/pale green exudate may be visible on the surface. Soreness and oedema are evident • Grade 3: Confluent moist desquamation; more pronounced areas of broken skin, yellow/pale green exudate are visible. Soreness and oedema are evident • Grade 4: Ulceration of the skin; haemorrhage and or necrosis of the skin are evident <p>Moisturiser: patient to use preferred centre Emolient (aloe vera gel, E45 etc.) on intact skin. Hydrogel and non-adhesive/silicon-based dressings on areas of moist desquamation. Steroid creams: topical treatment may be required but should not be used on broken skin or if signs of infection are present. Analgesia: review oral analgesia regime. Consider protosedyl ointment, instillgel before bowel opening. Infection screening: take a swab if there are signs of infection and arrange antibiotic treatment if infection is indicated. Consider for admission or regular wound care review. G4 radiation dermatitis: interrupt treatment until G3</p>
Hair loss in treatment area	
Rare (Less than 1%)	Initial management (if appropriate)
Nausea and/ or vomiting	<p>CTCAE 4.03 grading for nausea:</p> <ul style="list-style-type: none"> • Grade 1: loss of appetite without alteration in eating habits • Grade 2: oral intake decreased without significant weight loss, dehydration, or malnutrition



	<ul style="list-style-type: none"> Grade 3: Inadequate oral caloric or fluid intake; tube feeding, total parenteral nutrition, or hospitalisation <p>Anti-emetics: 5HT3 antagonists are particularly effective in radiation induced nausea and vomiting. Regular antiemetics are more effective than PRN doses.</p> <p>Consider prophylaxis with a 5-HT3 receptor antagonist (ondansetron 8mg orally or intravenously or granisetron 2mg orally or 1mg IV as a single dose) at least 30 minutes prior to radiotherapy session if required.</p> <p>Consider for admission and assess need for IV fluids and nutritional support.</p>
--	--

9.1b Possible late or long-term side-effects	
Expected (50-100%)	Initial management (if appropriate)
Skin changes in treatment area	Consider referral to laser therapy for problematic radiation induced fibrosis or telangiectasia.
Long-term bowel symptoms including increased frequency	<ul style="list-style-type: none"> Consider steroid suppositories for proctitis Consider Loperamide/Codeine Phosphate for looser stool Pelvic floor exercise Consider referral to specialist surgical units/ local late effect team Please refer to the Practical management of the Gastrointestinal Symptoms of Pelvic Radiation Disease Consider investigation of conditions such as: <ol style="list-style-type: none"> Bile Acid malabsorption using SeHCAT test Small Intestinal Bacterial Overgrowth
Early menopause	Consider hormone replacement therapy if appropriate
Women: Infertility	Offer fertility preservation
Common (10-50%)	Initial management (if appropriate)
Long-term bowel	<ul style="list-style-type: none"> Consider steroid suppositories for proctitis
Incontinence Urgency	

EofE RTN Rectum Protocol V4
 Date Agreed: 05 2026
 Date to be reviewed: 05 2027



9.1b Possible late or long-term side-effects		
symptoms including:	Obstruction	<ul style="list-style-type: none"> • Consider Loperamide/Codeine Phosphate for looser stool • Pelvic floor exercise • Consider referral to specialist surgical units/ local late effect team • Please refer to the Practical management of the Gastrointestinal Symptoms of Pelvic Radiation Disease • Consider investigation of conditions such as: <ol style="list-style-type: none"> 1. Bile Acid malabsorption using SeHCAT test 2. Small Intestinal Bacterial Overgrowth
	Bleeding from rectum causing blood in stool	
Less Common (Less than 10%)		Initial management (if appropriate)
Bowel stricture		Requires discussion with the surgical team.
Long-term urinary symptoms including:	Incontinence	Consider tamsulosin/ anti-muscarinic agents as appropriate Pelvic floor exercise Inco pads for urinary incontinence
	Urgency	Consider tamsulosin/ anti-muscarinic agents as appropriate
	Obstruction	
More prone to fractures in the radiotherapy treatment area		Counsel on bone health including calcium rich diet and vitamin D supplementation
Women: change in sexual experience including narrowing and dryness of the vagina, which may cause pain and make sexual activity more difficult		Topical lubrication with additional use prior to sexual intercourse. Counsel on regular use of vaginal dilators

EofE RTN Rectum Protocol V4
 Date Agreed: 05 2026
 Date to be reviewed: 05 2027



9.1b Possible late or long-term side-effects		
Men: Infertility		
Men: change in sexual experience including:	Inability to ejaculate	Consider pharmacological (phosphodiesterase inhibitors) and non-pharmacological interventions for sexual dysfunction Consider referral to erectile dysfunction clinic.
	Dry ejaculate	
	Erectile dysfunction	
Rare (Less than 1%)		Initial management (if appropriate)
Bowel/ bladder damage	Perforation	
	Fistula	
A different cancer in the treatment area		




10.0 References

1. Bahdoer, R., Dijkstra, E., Etten, B. et al. Short-course radiotherapy followed by chemotherapy before total mesorectal excision (TME) versus preoperative chemoradiotherapy, TME, and optional adjuvant chemotherapy in locally advanced rectal cancer (RAPIDO): a randomized, open-label, phase 3 trial. *The Lancet*, 22(1), pp. 29-42.
2. Cancer Institute NSW. (2021). Management of radiation induced nausea and vomiting. Available at <https://www.eviq.org.au/clinical-resources/side-effect-and-toxicity-management/gastrointestinal/426-management-of-radiation-induced-nausea-and-vom#management> (Accessed: 27 September 2021).
3. London Cancer Alliance. (2016). LCA Acute Oncology Clinical Guidelines. Available at <https://rmpartners.nhs.uk/wp-content/uploads/2017/03/lca-revised-acute-oncology-clinical-guidelines-september-2013-updated-march-2016-.pdf> (Accessed: 27 September 2021).
4. Mao, Y., Hedgire, S., Prapruttam, D. and Harisinghani, M., 2014. Imaging of pelvic lymph nodes. *Current Radiology Reports*, 2(11), p.70.
5. Owens, R., Mukherjee, S., Padmanaban, S., Hawes, E., Jacobs, C., Weaver, A., Betts, M. and Muirhead, R. (2020). Intensity-modulated radiotherapy with a simultaneous integrated boost in rectal cancer. *Clinical Oncology*, 32(1), pp.35-42.
6. Hodapp N. The ICRU report 83: prescribing, recording, and reporting photon-beam intensity-modulated radiation therapy (IMRT). *Strahlenther Onkol* 2012; (1): 97-99.
7. The American Association of Physicists in Medicine. (2018). Standardizing Nomenclatures in Radiation Oncology. Available at https://www.aapm.org/pubs/reports/RPT_263.pdf (Accessed: 16th June 2021).
8. The Royal College of Radiologists. (2021). National rectal cancer; Intensity modulated radiotherapy (IMRT) guidance. Available at https://www.rcr.ac.uk/system/files/publication/field_publication_files/bfco211-rectal-imrt-guidance.pdf (Accessed: 27 September 2021).
9. The Royal College of Radiologists. (2019). Radiotherapy dose fractionation, third edition. Available at <https://www.rcr.ac.uk/publication/radiotherapy-dose-fractionation-third-edition> (Accessed: 27 September 2021).
10. The Royal College of Radiologists. (2017). Radiotherapy target volume definition and peer review, RCR guidance. Available at

EofE RTN Rectum Protocol V4

Date Agreed: 05 2026

Date to be reviewed: 05 2027



https://www.rcr.ac.uk/system/files/publication/field_publication_files/bfco172_peer_review_outlining.pdf (Accessed: 27 September 2021).

11. The Royal College of Radiologists. (2021). Radiotherapy consent form for rectal cancer. Available at <https://www.rcr.ac.uk/sites/default/files/radiotherapy-consent-form-for-rectal-cancer.pdf> (Accessed: 27 September 2021).

12. The Society & College of Radiographers. (2020). The society and College of Radiographers, practice guideline document; radiation dermatitis guidelines for radiotherapy healthcare professionals. Available at https://www.sor.org/getmedia/53bd52ff-679e-48de-82a0-dc8dae570896/2020_version_4_final_practice_guideline_radiotherapy_skin_care_llv1.pdf (Accessed: 27 September 2021).

13. Clinical Protocol, Rectal cancer, Colchester Hospital.

14. Clinical Protocol, Radiotherapy for Rectal Cancers, Norfolk and Norwich University Hospitals NHS Foundation Trust.

15. Clinical Protocol, Rectal Cancer- Radiotherapy Treatment, Peterborough City Hospital.

16. Clinical Protocol, Radiotherapy Treatment for Rectal Cancer, Cambridge University Hospital NHS Trust.

17. Colorectal Planning Summary, Southend University Hospital.

11.0 Members of the protocol drafting committee

- Cambridge University Hospital NHS Foundation Trust: Rashmi Jadon, Daniel Welford, Jennifer Mehrer, Anita Anthony, Hannah Chantler
- East Suffolk and North Essex NHS Foundation Trust (Colchester): Sadaf Usman, Jenny Collins, Nick Bretherton, Sandra Huff, Lousie Bradshaw
- East Suffolk and North Essex NHS Foundation Trust (Ipswich): Liz Sherwin, Nicola Ramsey, Lindsey Sorroll
- Mid and South Essex NHS Foundation Trust: Rafiqul Islam (Chair), Mahbuba Choudhury, Joe Hobson, Nicky Wilde
- Norfolk and Norwich University Hospital NHS Foundation Trust: Andrew Ho, Christopher Beck, Peter Anthony, Catherine Palmer, Sarah Betts, David Moodie
- North West Anglia NHS Foundation Trust: Catherine Jephcott, Abbie Hollingdale, Aileen Considine, Jaak Joe, Karen Lemoine, Aquila Sharif



12.0 Amendment History

A record of changes in this document:

Date	Updated version number	Previous version number	Page Number/Section (updated version)	Details
22.11.21	V1.0			New Document
14.11.22	V2.0	V1.0	Updated version	Updated document issued with changes as outlined below:
			1.1.2	Statement about trials added to exclusion criteria. Pelvic reirradiation added to exclusion criteria.
			5.1	Short course RT bowel cavity constraints included.
			6.0	PTV objectives included.
			9.1a & 9.1b	Updates to side effect information
20.11.22	V2.1	V2.0	Section 5 pg 13	OAR section updated to include reference to GHG consensus guidelines
11.06.25	V3	V2.1	Pg 13	Table of borders of CTV_Elec added
			Section 5	Dose constraints updated
			Section 9	Updated for RCR consent guidance
			Section 11	Membership updated
05 26	V4	V3	Section 2	CT acquisition updated for PA node involvement
			Section 3	Palliative dose/ fractionation added to px table
			Section 5	OARs updated
			Section 6	Removal of structure prioritisation guidance
				Removal of modern dose algorithm statement
				Target objective table updated
			Section 8	Target verification information updated

