

Nonsurgical Rapid Maxillary Expansion in Adults: Report on 47 Cases Using the Haas Expander

Chester S. Handelman, DMD^a; Lin Wang, DDS^b; Ellen A. BeGole, PhD^c;
Andrew J. Haas, DDS, MS^d

Abstract: Rapid maxillary expansion (RME) in the adult is thought to be an unreliable procedure with several adverse side effects and, consequently, surgically assisted RME is considered the preferred procedure. The purpose of this paper is to study the efficacy of nonsurgical RME, and to determine the incidence of complications such as relapse of the expansion, pain and tissue swelling, tipping of the molars, opening rotation of the mandible and gingival recession. Rapid maxillary expansion using a Haas expander was examined in 47 adults and 47 children. A control group of 52 adult orthodontic patients who did not require RME was also studied. Students' *t*-test, and the analysis of variance followed by the Scheffé test were used to determine if there were significant differences among time periods and among the 3 study groups. The mean transarch width increase was similar in adults and children who had RME; 4.6 ± 2.8 compared to 5.7 ± 2.4 mm for the molars and 5.5 ± 2.4 compared to 5.7 ± 2.5 mm for the second premolars. In the adults, transarch expansion and the correction of the posterior crossbites were stable following discontinuance of retainers (mean 5.9 years). If the expander was properly fabricated, and turned no more than once a day, the procedure was well-tolerated. Rapid maxillary expansion in adults flared the molars buccally only 3° per side. The mandibular plane and lower facial height were unchanged. The adults achieved 18% of their transmolar expansion at the height of the palate and the remainder with buccal displacement of the alveolus. The children achieved 56% of their expansion by an increase at the height of the palate with the remainder due to displacement of the alveolus. There was some buccal attachment loss (0.6 ± 0.5 mm) seen in the female subjects associated with RME, but the extent was clinically acceptable. This resulted in significantly longer clinical crowns, but rarely caused exposure of buccal root cementum. Complications were infrequently observed or of minimal consequence. The results indicate that nonsurgical RME in adults is a clinically successful and safe method for correcting transverse maxillary arch deficiency. (*Angle Orthod* 2000;70:129–144.)

Key Words: Maxillary expansion; Surgically assisted maxillary expansion; Haas expander; Posterior crossbite; Transverse dimension; Adult treatment; Mandibular rotation; Gingival recession

INTRODUCTION

Transverse malocclusions due to maxillary width deficiency have been uniquely responsive to rapid correction in children and adolescents since Haas¹⁻³ popularized the fixed palatal expander in the 1960s. In contrast, the use of expanders to widen the maxillary arch in mature patients

is often reported as not feasible in standard texts and review papers.⁴⁻⁷

This pessimistic view of rapid maxillary expansion (RME) in adults is based in part on anatomic studies of the maturing face which show the midpalatal suture and adjacent articulations to be more rigid and beginning to fuse by the late teens.⁸⁻¹¹ In order to overcome the fusion and resistance of the adult sutures to expansion, surgically assisted rapid maxillary expansion (SA-RME) has been advocated. Surgery ranging from a subtotal Le Fort I^{12,13} to more limited lateral and midline maxillary osteotomies,¹⁴⁻¹⁹ combined with fixed palatal expanders, has been successful in allowing the midpalatal suture to separate and the maxilla to be widened.

Surgery, however, is costly and requires either outpatient surgery or hospitalization with attendant morbidity and time loss from work. Patients and their orthodontists may feel that the malocclusion is not sufficiently disfiguring or functionally compromising to justify the risks and costs of

^a Clinical Associate Professor in Orthodontics, University of Illinois, Chicago, and in private practice, Chicago, Ill.

^b Director and Associate Professor of Orthodontics, Nanjing Medical University, Nanjing, China.

^c Associate Professor in Orthodontics, University of Illinois, Chicago.

^d Clinical Associate Professor of Biostatistics in Orthodontics, University of Illinois, Chicago and in private practice, Cuyahoga Falls, Ohio.

Corresponding author: Chester S. Handelman, DMD, 25 East Washington Street, Suite 1817, Chicago, IL 60602 (e-mail: cshortho@flash.net).

Accepted: December 1999. Submitted: August 1999.

© 2000 by The EH Angle Education and Research Foundation, Inc.

Table 1. Distribution of Sex, Age, Treatment Time, and Crossbite for the Study Groups

	Child-RME	Adult-RME	Adult-Control
Number	47	47	52
Male	18	19	21
Female	29	28	31
Age start of treatment, y			
Mean \pm SD	9.5 \pm 1.3	29.9 \pm 8.0	32.7 \pm 7.4
Range	7.2–12.8	18.8–49.3	20.9–46.3
Treatment time, y	—	2.0 \pm 0.6	2.1 \pm 0.7
Posterior occlusion			
Unilateral crossbite	25	21	0
Bilateral crossbite	10	18	0
Constriction, no crossbite	11	7	0
No constriction or crossbite	1	1	52
Anterior Crossbite			
Yes	17	13	4
No	30	34	48

RME indicates Rapid Maxillary Expansion; SD, standard deviation.

a surgical procedure. This leads us to re-examine the feasibility of nonsurgical RME as an alternative to the SA-RME.

The potential limitations and complications of nonsurgical RME in adults stated in the literature, may be summarized as follows:^{12–18,20,21}

1. Expansion is limited and is only appropriate for dental expansion.
2. The results are unstable and relapse is common.
3. Pain is experienced because of the anatomic resistance to expansion, and because of ischemia, ulceration, and swelling due to compression of the palatal tissue by the appliance.
4. The posterior teeth tip leading to poor occlusion and instability.
5. Tipping of the teeth or their subsequent relapse leads to clockwise mandibular rotation, opening the bite and increasing facial height.
6. The maxillary posterior teeth are displaced buccally through the alveolus leading to gingival recession, bone loss and root resorption.

Previous reports of adults who have undergone palatal expansion are limited. Both Haas³ and Wertz and Dreskin²¹ reported expansion in 1 male in his twenties. More recently, Capelozza and coworkers²² attempted expansion at the mid-palatal suture in 38 nongrowing subjects with mixed results. Failure to expand, pain, swelling, or ulceration were frequent complications. Handelman²³ reported 27 adults who had successful expansion. Northway and Meade²⁴ reported 15 adults with successful expansion but were concerned with the level of gingival recession that they observed.

In a previous report, Handelman²⁵ demonstrated successful palatal expansion in 5 adult subjects with severe maxillary transarch deficiencies. In commenting on that article, Vanarsdall²⁶ and Mew²⁷ noted that the 5 cases were selected

and might not represent a larger sample of treated cases. Vanarsdall²⁶ was specifically concerned with the potential for gingival recession.

This paper expands our previous reports^{23,25} by examining 47 adults who underwent nonsurgical RME. We evaluate the efficacy of nonsurgical RME for increasing transpalatal width in the adult. The incidence and severity of the 5 cited complications are addressed. Adults who had RME, as part of their treatment are compared to 2 control groups: adult orthodontic patients who did not undergo RME and children treated with RME in the mixed dentition. In addition to study models and cephalometric measurements, palatal contours of the models are traced to gain an understanding of the nature of the nonsurgical expansion achieved in adults.

MATERIALS AND METHODS

The groups

Adult rapid maxillary expansion (A-RME). A group of 47 adults who had undergone nonsurgical RME with a Haas-type palatal expander followed by edgewise appliance therapy were evaluated. The subjects were patients from the private practices of 2 of the authors (29 from CSH and 18 from AJH). All adults from 1 practice (CSH) treated from 1978 to 1995 were evaluated for inclusion in the study. Patients that had 5 years post-retention records taken between 1964 and 1994 were evaluated from the other office (AJH). All patients had some form of maxillary transarch deficiency that required expansion (Table 1). Inclusion in the study required that the subject be 18 years or older at the time of the pretreatment records and that records from before and after appliance therapy were available. All patients treated with the Haas expander were able to complete this phase of treatment. Subjects were excluded from the study for only the following reasons: incomplete records,

cleft of the lip or palate, or maxillary surgery if this jaw was segmented into 2 or more sections. We carefully reviewed the hospital reports on all subjects who had orthognathic surgery. Ten patients in this group had orthognathic surgery, 8 of which had maxillary surgery without segmentation.

Child rapid maxillary expansion (C-RME). A group of 47 consecutively treated children in the mixed dentition was selected from the practice of 1 of the authors (CSH). All were treated with the Haas expander as a first phase of treatment.

Adult control (A-C). Fifty-two adults who had completed comprehensive edgewise-orthodontic treatment through the practice of 1 of the authors (CSH) comprised the A-C group. All patients in this group were 18 years of age or older, did not have palatal expansion as part of their treatment, had comprehensive edgewise treatment of both arches for over 1 year and, demonstrated a pretreatment occlusion without obvious signs of maxillary constriction. Two of the patients had orthognathic surgery, but the surgery did not involve sectioning or widening of the maxilla. The A-C group was selected serially, however, an attempt was made to match the male-female ratio of the A-RME group.

Although there was no racial criterion for acceptance, the study sample was overwhelmingly Caucasian. The A-RME had 1 and the C-RME had 2 subjects of African-American descent, and the C-RME had 1 and the A-C had 3 subjects of Asian descent. One or 2 Hispanic subjects were present in all groups.

Timing of records

All pretreatment records (T_1) preceded the start of treatment and the post-treatment record (T_2) was taken at the time of retention following orthodontic treatment for the A-RME and the A-C groups. The post-treatment record for the C-RME group was taken at variable times before the start of the second stage of treatment and always followed the discontinuance of maxillary retainers. The post-retention record (T_3) was limited to a subgroup of 21 A-RME patients who had discontinued maxillary retainers for a minimum of 12 months. The record was generally taken about 5 years following the discontinuance of the maxillary retainer and 10 years following the T_2 records. The other 26 A-RME patients were excluded because they were still wearing maxillary retainers (18) or could not be recalled (8).

Appliance

All expanders were fixed tooth and tissue borne expanders, generally called Haas expanders.¹⁻³ The buccal bar was usually absent in the A-RME treated by 1 practitioner (CSH) but in place for the other (AJH). The C-RME group usually had the buccal bar in place. The adults and children followed the same protocol of expansion. Following ce-

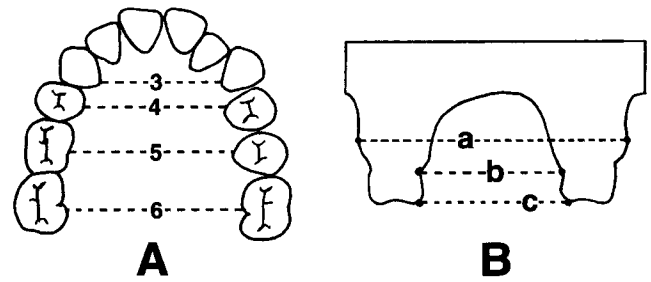


FIGURE 1A. Maxillary transarch widths, occlusal view.

FIGURE 1B. Maxillary first molar widths: (a) alveolar 6-6; (b) trans 6-6; (c) cusp 6-6.

mentation, the expander was turned 2 times on the first day. The patients were instructed to turn the expander 1 time per day on succeeding days and were seen at 2-week intervals. Patients were advised to discontinue expansion if they felt pain or tissue swelling. If a patient experienced pain or tissue swelling, the expander was turned back a few turns and, after a rest period of a week, expansion was resumed turning every other day. Expansion was discontinued when the palatal cusp of either of the maxillary molars was about to go into buccal crossbite. At that time, the expansion screw was fused with a dab of acrylic.

The expander was generally removed following 12 weeks of stabilization (range 8 weeks to 6 months). Following removal of the expander, a removable acrylic palatal retainer was placed on the same day. In children this retainer was worn for 3 to 6 months; in the adults the plate was worn for variable periods of time as short as 3 months or until retention. In the A-RME group, the acrylic plate was relieved to allow palatal adjustment of the overexpansion. Concurrent mandibular expansion was performed in 15 C-RME and 5 A-RME patients using a fixed lingual expansion arch²⁵ or a removable Schwartz-type expander with occlusal coverage as proposed by Hamula.²⁸ Data on pain or tissue swelling during RME in adults were obtained by reviewing the treatment charts. Linear measurements were made with an electronic caliper (Mitutoyo number 573, Tokyo, Japan) and recorded to the nearest 0.1 mm. Angular measurements were made with a protractor and recorded to the nearest 0.5°.

Model measurements

The maxillary and mandibular arch widths (Figure 1A) were recorded between the right and left antimeres of the following teeth; canines (trans 3-3), first premolars (trans 4-4), second premolars (trans 5-5) and permanent first molar (trans 6-6). Deciduous teeth were substituted when present. If teeth were absent or unerupted on either the T_1 or T_2 models, that measurement was deleted from the study for both time periods. The values were measured at the cervical margin of the tooth from the point of greatest convexity on 1 tooth to the contralateral tooth in the same arch

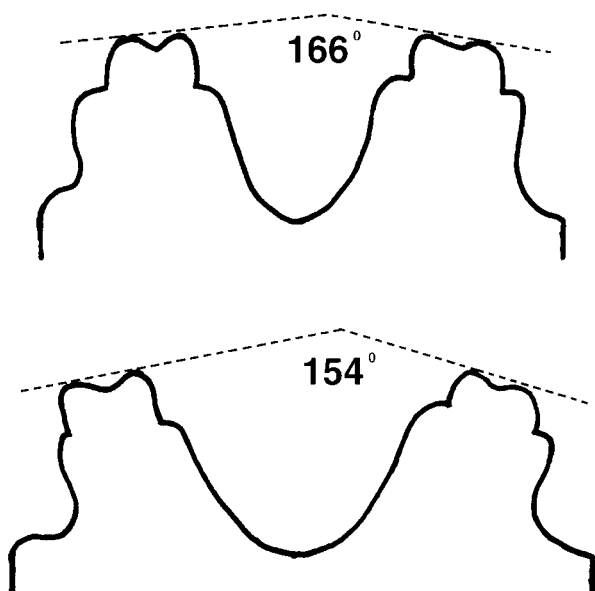


FIGURE 2. Maxillary first molar axial angulation measured on study models (after Burst³⁰). Top view has pretreatment measure of 166°. Bottom view has post-treatment measure of 154°. This decrease of 12° in molar angulation represents a 6° increase in buccal inclination per side.

as suggested by Howe and coworkers.²⁹ In the case of the permanent first molars and primary second molars, the point on the cervical margin adjacent to the lingual developmental groove was selected (Figure 1). Two other maxillary first molar measures were also recorded: from the mesial-palatal cusp of 1 first molar to its anitimerie (cusp 6-6) and from the most prominent buccal bulge on the alveolus superior to the maxillary first molar (alveolar 6-6). This measure was usually 3 to 5 mm superior to the gingival crest (Figure 1B).

Maxillary first molar axial angulation. The angle formed by the intersecting lines drawn across the mesial buccal and mesial lingual cusp tips of both the right and left first molars (Figure 2) was defined by Brust³⁰ and Brust and McNamara³¹ as the maxillary first molar angulation. The measure was recorded directly from the model using a Starett no. 1a protractor.

Clinical crown height. Clinical crown heights for premolars were measured from the tip of the buccal cusp to the height of contour of the buccal gingiva. The first molar record was taken from the most occlusal aspect of the buccal groove to the gingival point directly below the buccal groove, (Figure 3). The change in crown height from T₁-T₂ was used as an indirect measure of buccal attachment loss. Crown height for the child expansion group was not measured.

The maxillary model base was trimmed so that it was parallel to the occlusal plane of the posterior dentition. A contour gauge (General no. 837) made of 32 stainless steel pins per inch was placed at a right angle to the model base

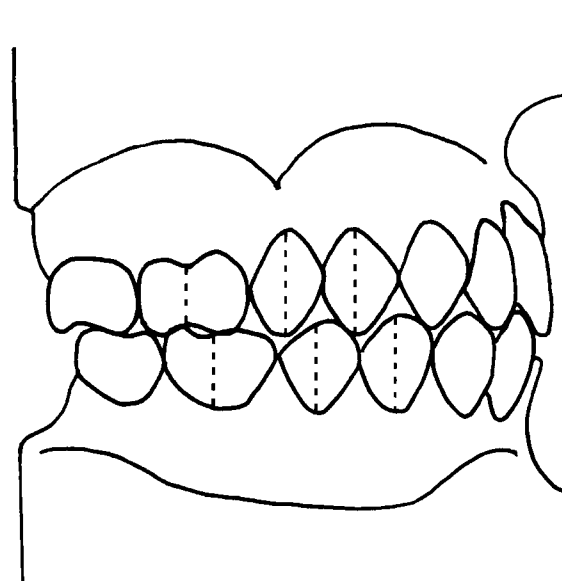


FIGURE 3. Clinical crown heights as measured on study models. An increase in clinical crown height from T₁ to T₂ is considered a reflection of "buccal attachment loss."

to transect the palatal grooves of the maxillary first molars. When the contour gauge was depressed, the stainless steel pins slid away from the model so that an outline of the palatal contour is registered (Figure 4). This contour was transferred to graph paper by carefully tracing the outline of the gauge.

The following measurements were derived from the contour drawings:

Palatal vault angle. A line was drawn tangent to the middle two-thirds of the right and left palatal surfaces. The angle formed by these 2 lines was recorded (Figure 5a).

Palatal depth from gingival height. A line was drawn connecting the point on the gingival crest adjacent the first molars. The shortest distance from the midpalatal raphé to this line was recorded (Figure 5b).

Palatal depth from molar cusp. A line was drawn connecting the occlusal surfaces of the first molars. The shortest distance from the midpalatal raphé point to this line was recorded (Figure 5c).

Palatal width at gingival height. A line was drawn from the first molar at the height of the palatal gingiva to its antimerie (Figure 5d). The length of this line was recorded.

Palatal width at mid-palate. A line was drawn perpendicular to the half way point between the height of the palatal vault and the gingival height line (Figure 5e). The length of this line was recorded.

Palatal width difference. This measure, adapted from Ladner and Muhl,³² represents the expansion at the height of the palatal vault. The palatal contour tracings from T₁ and T₂ were superimposed first on the right palatal outline and then the left while remaining parallel to the occlusal plane. The distance the midpalatal raphé was displaced rep-




FIGURE 4. Contour gauge in place, set perpendicular to the posterior occlusal plane and across the palatal grooves of the maxillary first molars. The displacement of the pins reflects the palatal contour of the study model. This contour is transferred to graph paper by tracing the outline of the pins.

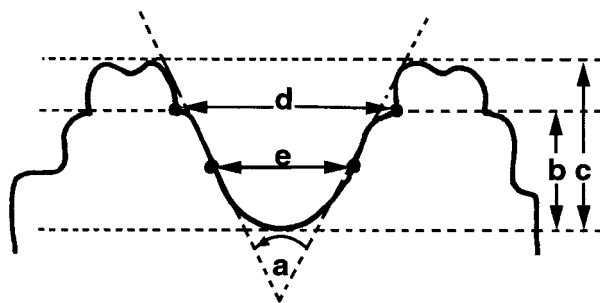


FIGURE 5. Measurements derived from contour tracings: (a) palatal vault angle; (b) palatal depth from gingival height; (c) palatal depth from molar cusp; (d) palatal width at gingival height; (e) palatal width at mid-palate.

resents the increase in palatal width per side, and their sum is the total palatal width difference (Figure 6).

Cephalometric measurements. (patient's teeth in occlusion)(orthognathic surgery patients excluded).

Mandibular plane. The angle formed by the Nasion Sella line and the mandibular plane.

Lower facial height. Anterior Nasal Spine to Menton in millimeters.

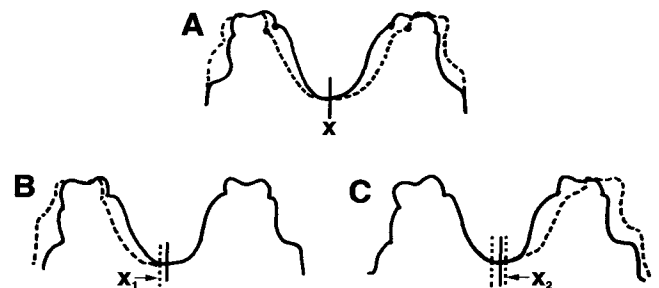


FIGURE 6. Palatal width difference. (A) The T_1 and T_2 contour tracings are superimposed on the midpalatal raphé with the occlusal planes parallel. (B) The T_2 tracing is moved to the left until the left T_1 and T_2 palatal walls merge. The displacement of the midpalatal raphé is marked. (C) This is repeated sliding the T_2 tracing to the right. The combined left and right displacements is the palatal width difference and reflects expansion at the height of the palate (after Ladner and Muhl).³²

Statistical analysis

The reliability of the measures was determined by comparing double assessments taken at least 2 weeks apart on 10 randomly selected adults. Both T_1 and T_2 measures were duplicated. Alpha was established at 0.01 because of the

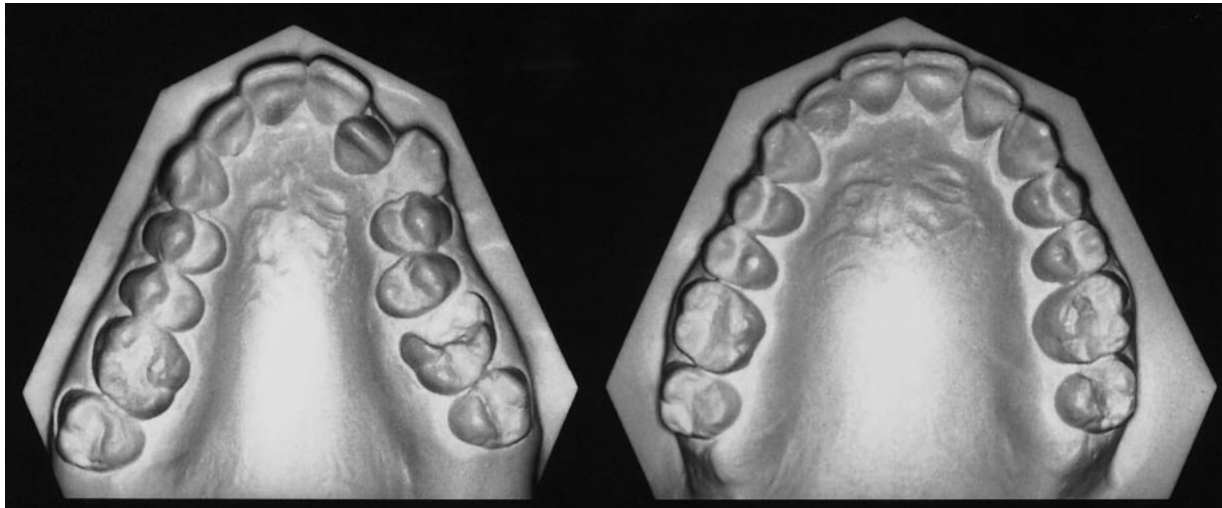


FIGURE 7. Study models of a 30 year old female, pretreatment on the left and post-treatment on the right. The central incisors did not separate during RME. Note the increase in transarch widths, arch perimeter and palatal volume.

large number of comparisons, in order to control type I error. The differences between the paired measurements were evaluated with *t*-tests. None were found significantly different.

The 3 study groups were compared using the analysis of variance, followed by the Scheffé test to isolate pairwise differences among the 3 groups. *t*-tests were used to compare males and females, and between successive time intervals. Alpha was set at 0.05 for all statistical tests.

In order to determine which variables were associated with an increase in clinical crown height, a correlation analysis was performed. Several variables were compared to the combined right and left first molar, second premolar, or first premolar measures for the T_1 - T_2 change in crown heights. The Pearson correlation coefficient was considered significant at the 0.05 level.

The data for males and females were combined since the ratio of males to females was the same for the 3 study groups and their responses to treatment (T_1 - T_2) were not significantly different ($P < 0.05$). The 1 exception was clinical crown height where the sexes responded differently to treatment and here the males and females were treated separately.

RESULTS

The sample

Table 1 lists the age, sex and treatment time for the 3 groups. The groups have a comparable distribution of males and females with a ratio of 40% males and 60% females. The C-RME is a mixed dentition sample. The A-RME group mean age of 29.9 was somewhat younger than the A-C group at 32.7 years, but this difference was not statistically significant. Both adult groups had members in their fifth decade of life and both had treatment times of about 2 years.

Pain and tissue swelling

Nine of the 47 A-RME subjects reported palatal swelling and pain, and 1 subject reported headaches.

Transarch widths, maxilla

Pretreatment transarch widths for both the C-RME and A-RME groups were significantly narrower than the A-C group (Table 2). For example, trans 6-6 width for the A-C group was 34.3 and only 30.6 and 31.4 mm for the C-RME and A-RME, respectively.

Rapid maxillary expansion increased the transarch widths in both expansion groups. At the level of the first molars, C-RME expanded 5.7 ± 2.4 and the A-RME expanded 4.6 ± 2.8 mm. At the level of the second premolar, C-RME expanded 5.7 ± 2.5 and the A-RME expanded 5.5 ± 2.4 mm. Both expansion groups at T_2 showed transarch widths that were significantly greater than observed in the A-C group.

Maxillary transmolar widths were measured on the models in 3 ways (Figure 1B). In the C-RME group the expansion realized from T_1 to T_2 was the same for all 3 measures of molar expansion (Table 2). In adults, the expansion of cusp 6-6 (5.7 mm) exceeded trans 6-6 (4.6 mm) and alveolar 6-6 (3.3 mm).

Transarch widths, mandibular

The 15 C-RME and 5 A-RME subjects had active mandibular expansion and were excluded from Table 3. At T_1 transmolar and first and second premolar widths were similar for the 3 groups, while transcuspid widths were larger in the C-RME group than for both adult groups. The C-RME group showed moderate mandibular transarch expansion from T_1 to T_2 ; generally 0.5 to 0.8 mm. The adults who underwent RME and edgewise orthodontic treatment

Table 2. Maxillary Transarch Widths and Analysis of Variance using Scheffé Method for Significant Group Difference at 0.05 Level

Tooth	Time	1—Child RME, mm			2—Adult RME, mm			3—Adult Control, mm			Scheffé Group Differences
		N	Mean	SD	N	Mean	SD	N	Mean	SD	
First Molar	T ₁	47	30.6	2.9	46	31.4	4.3	52	34.3	2.8	1-3, 2-3
	T ₂		36.4	2.7		36.0	3.7		34.1	3.0	
	T ₁ -T ₂		5.7	2.4		4.6	2.8		-0.2	1.1	
Second Premolar	T ₁	46	26.6	3.3	45	27.3	3.9	49	30.8	3.1	1-3, 2-3
	T ₂		32.4	2.7		23.8	3.5		30.3	3.0	
	T ₁ -T ₂		5.7	2.5		5.5	2.4		-0.6	1.5	
First Premolar	T ₁	39	23.6	2.8	39	23.2	2.9	27	26.8	2.3	1-3
	T ₂		28.5	2.8		27.9	2.9		26.8	2.3	
	T ₁ -T ₂		4.9	2.7		4.7	1.8		0.0	1.2	
Canine	T ₁	28	22.4	2.6	44	21.9	2.2	51	24.0	2.2	1-3, 2-3
	T ₂		26.6	2.2		24.7	2.2		23.9	1.6	
	T ₁ -T ₂		4.2	2.8		2.8	1.8		0.0	1.3	
First Molar Cusp	T ₁	47	35.8	3.2	46	36.0	5.2	50	38.2	3.5	1-3, 2-3
	T ₂		41.7	2.8		41.9	3.8		38.1	3.6	
	T ₁ -T ₂		5.9	2.5		5.9	3.6		0.0	1.4	
First Molar Alveolus	T ₁	46	52.7	4.8	46	55.0	4.0	50	57.8	3.6	1-3, 2-3
	T ₂		58.2	4.8		58.3	4.4		57.2	3.6	
	T ₁ -T ₂		5.5	1.9		3.3	2.1		0.5	1.2	

RME indicates rapid Maxillary expansion; SD, standard deviation.

Table 3. Mandibular Transarch Widths and Analysis of Variance using Scheffé Method for Significant Group Difference at 0.05 Level

Tooth	Time	1—Child RME, mm			2—Adult RME, mm			3—Adult Control, mm			Scheffé Group Differences
		N	Mean	SD	N	Mean	SD	N	Mean	SD	
First Molar	T ₁	32	33.6	2.3	42	33.9	3.6	51	32.4	2.9	2-3
	T ₂		34.0	2.2		34.9	3.3		32.5	2.7	
	T ₁ -T ₂		0.3	1.5		1.0	1.8		0.1	1.2	
Second Premolar	T ₁	29	29.5	2.3	37	29.3	3.4	50	28.4	2.9	2-3
	T ₂		30.1	1.9		30.2	3.2		28.7	2.3	
	T ₁ -T ₂		0.6	1.8		0.9	2.0		0.3	1.3	
First Premolar	T ₁	26	24.8	1.8	36	25.0	2.5	41	25.1	2.8	1-3, 2-3
	T ₂		25.6	1.8		25.8	1.8		24.8	2.0	
	T ₁ -T ₂		0.8	1.4		0.9	2.0		-0.3	1.6	
Canine	T ₁	27	21.1	1.5	37	19.0	2.1	48	19.0	1.9	1-2, 1-3
	T ₂		21.7	1.9		20.2	1.6		19.1	1.6	
	T ₁ -T ₂		0.6	1.9		1.2	1.4		0.1	1.3	

* Subjects with mandibular expansion appliances are excluded from the data.

RME indicates Rapid Maxillary Expansion; SD, standard deviation.

had mandibular transarch expansion of 0.9 to 1.2 mm. However, when comparing T₁ and T₂ values, neither the C-RME nor the A-RME mandibular expansions were significant. The modest mandibular transarch expansion in A-RME was significant (except for trans 5-5) when compared to the stable transarch measures of the A-C group (Table 3).

Stability of transarch expansion

The stability of palatal expansion was studied by examining A-RME patients who had discontinued all retention for a minimum of 1 year, however, the mean time out of retention was 5.9 ± 3.9 years. The comparison of T₂-T₃ transarch differences for 21 subjects is reported in Table 4. The decrease in transarch widths in subjects out of retention

was modest (0.5 to -0.6 mm), but statistically significant. None of the subjects relapsed into cross-bite. The mandibular arch, out of retention 5.3 ± 4.1 years, decreased on average 0.2 mm but this narrowing was not statistically significant.

Molar and palatal angle

The pretreatment axial inclinations of the molars were similar for both adult groups (Table 5). The increase in the maxillary transarch width for A-RME was accompanied by a decrease of 6.2 ± 11.5 degrees in the molar angle, indicating an increase in molar inclination to the buccal. Neither C-RME nor A-C groups showed a change from T₁ to T₂ in the axial inclination of the first molars.

The palatal angle (Table 5) was measured from the con-

Table 4. Change in Transarch Widths following Discontinuance of Retention (T_2-T_3) Using Paired *t*-test for Significance in Change from T_2 to T_3

Transarch Measure	N	Mean Difference, mm	SD, mm	P
Maxillary				
First Molar	21	0.0	0.9	NS
Second Premolar	19	-0.5	1.1	.04
First Premolar	16	-0.5	0.7	.01
Canine	21	-0.5	1.1	.05
First Molar, cusp	21	-0.6	1.0	.01
First Molar, alveolus	21	-0.6	1.3	.04
Mandular				
First Molar				
Second Premolar	21	-0.2	0.9	NS
First Premolar	18	-0.2	1.0	NS
First Premolar	17	0.0	1.0	NS
Canine	20	-0.3	0.7	NS

SD indicates standard deviation; NS, non significant.

four tracings (Figure 5). Following expansion there was a $7.9 \pm 7.8^\circ$ increase in the palatal angle in A-RME. In contrast, the C-RME showed no change in the palatal angle in association with its transmolar expansion. The adult control group also showed no change in palatal angle.

Palatal depth

These measures document if the molars were extruded by RME. Treatment had no effect on both depth measures for each of the adult groups (Table 5). The palatal depth

increased 1.5 mm from the occlusal plane of the molars in the C-RME group.

Palatal width at gingival height, at midpalate and palatal width difference

The palatal widths were measured at 3 different heights on the palatal contour tracings (Figures 5 and 6). These measures define expansion at the dental-gingival junction, the midpalate and at the apex of the palate (Table 5).

The adult control group showed no change in the palatal widths at all levels following standard edgewise treatment. The 2 expansion groups showed significant increases in palatal widths at all levels associated with RME treatment. Expansion at the crest of the gingiva was statistically similar for A-RME (5.1 ± 2.9 mm) and C-RME (5.5 ± 2.4 mm). Expansion at the mid-palate was 3.0 ± 2.0 mm for the adults and 4.4 ± 2.2 mm for the children, demonstrating significantly greater midpalatal expansion in children. The palatal width change at the apex of the palate was only 0.9 ± 1.3 mm for A-RME but was 3.1 ± 1.6 for C-RME, a difference that was statistically significant.

Mandibular plane and lower anterior face height

Before treatment, both the C-RME and the A-RME groups had greater mandibular divergence than the A-C group (Table 6). Rapid maxillary expansion and standard edgewise treatment did not change SN-MP measurements in the 3 groups. A-RME initially had longer lower anterior face height (+3.7 mm) than the A-C group. ANS-Me was unchanged by RME and edgewise treatment in the 2 adult

Table 5. Palatal and Molar Angles, Palatal Depth at Molar Cusp and Gingival Height, Palatal Width at Gingival Height and Mid-palate, Palatal Width Difference and Analysis of Variance Using Scheffé Method for Significant Group Difference at 0.05 Level

Measure	Time	1—Child RME			2—Adult RME			3—Adult Control			Scheffé Group Differences
		N	Mean	SD	N	Mean	SD	N	Mean	SD	
Molar angle, degrees	T_1	47	154.2	8.9	46	164.5	9.8	50	168.7	8.5	1-2, 1-3
	T_2		154.9	9.0		158.3	11.3		167.6	8.0	1-3, 2-3
	T_1-T_2		0.6	5.8		-6.2	11.5		-1.1	4.7	1-2, 2-3
Palatal angle, degrees	T_1	47	81.4	11.2	46	52.8	11.5	49	58.5	11.11	1-2, 1-3, 2-3
	T_2		82.4	15.1		60.7	11.2		57.9	11.03	1-2, 1-3
	T_1-T_2		1.0	9.0		7.9	7.8		-0.6	5.5	1-2, 2-3
Palatal depth at molar cusp, mm	T_1	47	14.3	2.2	46	20.3	2.6	49	19.6	2.4	1-2, 1-3
	T_2		15.8	2.6		20.2	2.6		19.5	2.3	1-2, 1-3
	T_1-T_2		1.5	1.3		0.0	1.2		-0.1	0.6	1-2, 1-3
Palatal depth at gingival height, mm	T_1	47	10.8	2.0	45	15.2	2.6	49	14.1	2.6	1-2, 1-3
	T_2		11.9	2.6		15.4	2.9		14.1	2.6	1-2, 1-3
	T_1-T_2		1.1	1.7		-0.0	1.2		0.0	0.7	1-2, 1-3
Palatal width gingival height, mm	T_1	47	28.4	3.0	45	29.6	4.3	50	31.6	3.0	1-3, 2-3
	T_2		33.9	2.7		34.7	3.7		31.4	3.2	1-3, 2-3
	T_1-T_2		5.5	2.4		5.1	2.9		-0.2	1.5	1-3, 2-3
Palatal width mid-palate, mm	T_1	47	17.9	3.5	45	19.7	4.1	49	22.2	2.9	
	T_2		22.3	3.2		22.8	4.1		21.9	3.1	
	T_1-T_2		4.4	2.2		3.0	2.0		-0.3	1.0	1-2, 1-3, 2-3
Palatal width Δ , mm		47	3.1	1.6	46	0.9	1.3	49	-0.1	0.4	1-2, 1-3, 2-3

RME indicates Rapid Maxillary Expansion; SD, standard deviation.

Table 6. Mandibular Plane Angle (SN/MP), Lower Facial Height (ANS-Me) and Analysis of Variance Using Scheffé Method for Significant Group Difference at 0.05 Level

Measure	Time	1—Child RME			2—Adult RME			3—Adult Control			Scheffé Group Differences
		N	Mean	SD	N	Mean	SD	N	Mean	SD	
Mandibular Plane Angle, degrees	T ₁	42	36.9	6.1	35	37.3	8.2	48	32.7	5.0	1-3, 2-3
	T ₂		36.8	6.2		37.3	7.9		32.7	5.7	1-3, 2-3
	T ₂ -T ₁		-0.2	2.5		0.0	1.9		0.0	1.5	
Lower Facial Height, mm	T ₁	42	62.8	5.8	35	75.4	6.7	48	71.7	6.3	1-2, 1-3, 2-3
	T ₂		65.3	5.7		75.7	6.5		72.2	6.7	1-2, 1-3
	T ₂ -T ₁		2.5	3.1		0.3	1.7		0.6	2.0	1-2, 1-3

RME indicates Rapid Maxillary Expansion; SD, standard deviation.

Table 7. t-test for Buccal Attachment Loss as Measured by Change in Crown Heights (T₁-T₂)*

Tooth	A-RME Group (mm)							A-C Group (mm)							Comparison between A-RME and A-C			
	Males			Females				p ₁	Males			Females				p ₁	p ₂	p ₂
	N	Mean	SD	N	Mean	SD	N		Mean	Sd	N	Mean	SD	N	Mean			
Maxillary																		
First Molar	32	-0.3	0.4	48	-0.6	0.5	NS	40	-0.1	0.4	62	-0.1	0.5	NS	NS	**		
Second Premolar	34	-0.3	0.5	52	-0.6	0.5	NS	42	0.0	0.5	60	-0.3	0.5	**	NS	NS		
First Premolar	28	-0.4	0.4	46	-0.6	0.6	NS	24	-0.1	0.5	30	-0.1	0.4	NS	NS	**		
Mandibular																		
First Molar	30	-0.1	0.3	50	-0.1	0.4	NS	40	0.0	0.3	62	-0.1	0.4	NS	NS	NS		
Second Premolar	28	0.0	0.4	50	-0.1	0.4	NS	42	-0.2	0.3	58	-0.1	0.5	NS	NS	NS		
First Premolar	28	-0.3	0.3	44	-0.2	0.5	NS	40	0.0	0.4	42	-0.1	0.3	NS	**	NS		

* The left and right measures were combined. A-RME indicates Adult Rapid Maxillary Expansion; N, number of pairs of teeth measured; SD, standard deviation; P₁, probability of significant difference comparing males and females in the same group; P₂, probability of significant difference compares A-RME and A-C subjects of the same sex; NS, nonsignificant.

** Significant at < 0.05 level.

groups. The ANS-Me lengthened by 2.5 mm in the C-RME group and this difference was significant.

Clinical crown height

The measurements for the left and right clinical crown heights of each tooth class were not significantly different (*P* < 0.05) and were pooled. We then examined if we could combine male and females. Males generally had longer crowns than females at T₁ (data not in tables), but females demonstrated a greater increase in their crown heights following orthodontic treatment. The males and females are therefore recorded separately.

Table 7 records the change in crown heights from T₁ to T₂, which is defined as buccal attachment loss. We first compared males and females in the A-RME group to each other. These within group comparisons did not achieve significance. We then compared the A-RME and AC subgroups of the same sex to each other. Comparison of males in the A-RME to the A-C groups generally was not significantly different. Comparison of the female A-RME to the A-C group revealed a different response to maxillary expansion treatment. For example, A-RME females had buc-

cal attachment loss of 0.6 mm for the maxillary first molars and first premolars, and this was significantly more loss than the 0.1 mm seen in the A-C group. There were no differences for mandibular measures of buccal attachment loss between the female A-RME and A-C groups.

We were interested in the maximal increase in crown height, because this might reflect cases with clinically relevant gingival recession. In the maxilla the A-RME group showed maximal buccal attachment loss of 2.0, 1.9 and 2.1 mm for the first molar, second premolar and first premolar, respectively. The A-C group showed maximal attachment loss of 2.1, 2.1, and 1.3 mm for the same teeth following orthodontic treatment. Maximal recession appeared to be similar for the 2 adult groups.

Does RME potentiate gingival recession beyond the period of active treatment? Since T₃ records for the adult control group were not available, we compared buccal attachment loss in the maxilla to the mandible for the 21 A-RME patients with T₃ records (Table 8). The time between T₂ and T₃ generally exceeded 10 years. The maxillary teeth showed an increase in crown height 0.5 to 0.6 mm, while the mandibular teeth showed an increase of 0.4 to 0.5 mm.

Table 8. Longterm Buccal Attachment Loss as Measured by Change in Crown Heights (T_2-T_3) in the Adult Rapid Maxillary Expansion Group (21 subjects)

	N	Mean, mm	SD, mm
Maxillary			
First Molar	39	0.6	0.8
Second Premolar	39	0.6	0.7
First Premolar	30	0.5	0.6
Mandibular			
First Molar	34	0.4	0.6
Second Premolar	35	0.5	0.7
First Premolar	29	0.4	0.9

N indicates number of teeth measured.

These comparative measures were not statistically significant.

What cofactors may cause an increase in crown height? We examined the influence of the following variables: age, pretreatment transarch width (T_1), change in transarch width (T_1-T_2), mandibular divergence, lower facial height, molar angle and pretreatment crown height. The different variables were correlated to changes in crown heights of the maxillary first molars, second premolars and first premolars, respectively. Using Pearson correlation coefficients, none of the above variables reached the level of significance, with the exception of the first molar angulation as related to first molar crown height ($P < 0.05$).

DISCUSSION

Retrospective studies are often flawed because the groups are not homogeneous, a biased selection of subjects may have occurred or variability in the treatment protocol may have been necessary due to clinical contingencies. While we attempted to minimize these problems, the subjects were not randomly selected which limits the ability to generalize the results and could introduce bias. The T_3 records may especially be subject to bias since patients with poor results may not respond to recall 10 years post-treatment.

The A-C group was in the mixed dentition and reasonably homogeneous for age (9.4 ± 1.2 years). The 2 adult groups clustered about age 30 and very few were in the 18- to early 20-year range. The ratio of males to females was balanced to minimize differences associated with sex.

The A-RME group was limited to subjects that, in the authors' judgment, would benefit from RME. For example, the patients included those with an absolute or relative transverse maxillary deficiency expressed as unilateral or bilateral crossbites, constricted arches, or maxillary constriction that was apparent during orthognathic surgical planning. These transverse problems were superimposed on variable horizontal and vertical malocclusions. Despite the variety of malocclusions, the maxillary transarch deficiency of the A-RME group was confirmed by a maxillary trans 6-6 width 3 mm deficient compared to the adult controls

($P < 0.05$) and deficient when compared to a group of older adolescents selected for ideal occlusion.²⁹

The treatment protocol for maxillary expansion was generally consistent because the Haas RME was fabricated in the same laboratory and was used in the same manner for the C-RME and A-RME groups. We attempted to include every available A-RME subject that met the criteria in order to maximize the size of the samples. Several subjects with malocclusions associated with transarch deficiency were not in the study because we did not elect to use RME. For example moderate deficiencies were often treated with edgewise appliance expansion, and some subjects with difficult problems or advanced gingival recession were treated with SA-RME. In a few cases, posterior crossbites were left untreated if a satisfactory correction of the patient's chief concerns was still achievable.

Efficacy of expansion

The A-RME group showed between 4.6 and 5.5 mm of expansion for the maxillary molars and premolars (Table 2). This was sufficient to correct all of the posterior crossbites. The molars were initially overexpanded. However, the records at this immediate post-expansion stage were not available, and the T_2 measurements for both expansion groups reflect the post-expansion lingual adjustment of the posterior teeth as they settled into proper occlusion. Studies of mixed dentition patients indicate that there is considerable palatal adjustment or recovery of the molar, usually about 20% of the original expansion.^{33,34} This lingual adjustment is sometimes referred to as relapse, but this is a misnomer since relapse should be reserved for the reoccurrence of the malocclusion (ie, the crossbite).

The expansion in the A-RME group was statistically similar to the C-RME group (Table 2). The molar expansion in the A-RME is also similar to studies of mixed dentition subjects with large sample size. For example, Spillane and McNamara³⁴ and Chang et al³⁵ reported 4.8 and 4.6 mm of retention of arch expansion in children. The expansion attained in the A-RME group contrasts to the unchanged transarch width in the A-C group. Individual cases showed more than 8 mm of expansion at T_2 (Figures 7 and 9). The amount of expansion observed in this study was related to the demands of the severity of the original malocclusion. No upper limit could be established either clinically or from examination of the data, though some limitation of nonsurgical RME undoubtedly exists.

Mandibular expansion appliances were used in conjunction with RME in 5 adults and 15 children. These patients were excluded from the data in Table 3. The expansion achieved in the remaining 32 C-RME and 42 A-RME subjects would be spontaneous in the case of the children and the result of edgewise appliance treatment for the adults. The C-RME group generally had 0.5 mm transarch mandibular expansion and the A-RME group about 1.0 mm of

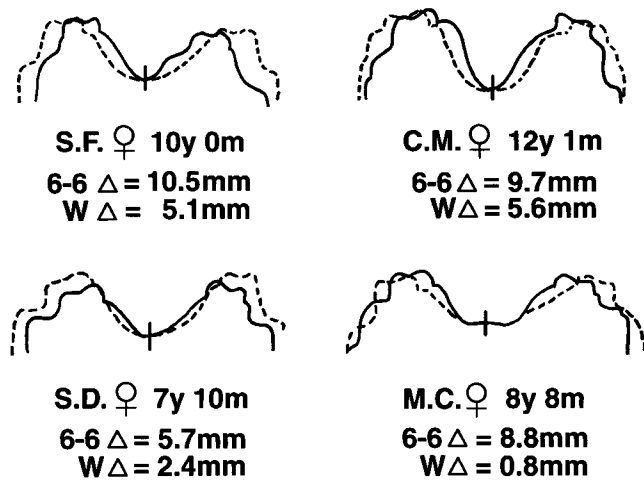


FIGURE 8. Palatal contours of 4 C-RME subjects. The T_1 and T_2 tracings are superimposed on the midpalatal raphe with the occlusal planes parallel. The T_1 - T_2 difference in the trans 6-6 ($6-6\Delta$) and the palatal width difference ($w\Delta$) are recorded. Note the first 3 subjects demonstrated about 50% of their width increase starting at the height of the palate. Patient MC female (lower right) was unusual for a child in that there was little increase in her palatal width difference.

expansion. These mandibular width changes are small, suggesting that maxillary expansion did not encourage clinically significant mandibular expansion if active mandibular expansion appliances were not used.

Data on the small subgroups who had active mandibular expansion are not recorded in Table 3 because of the small sample size. The mandibular expansion subgroups were expanded in the 3 to 4 mm range, which was significantly greater than the modest increase observed without active mandibular expansion. Concurrent mandibular expansion allows for greater maxillary expansion and also increases mandibular arch perimeter which provides space to correct the crowding of the dentition.^{7,30,31}

Relapse of expansion

The stability of palatal expansion in adults without surgical assistance has been questioned.^{12-18,21} The permanence of the expansion in the A-RME group can be evaluated by comparing the T_2 and T_3 transarch measures (Table 4). The maxillary transarch widths generally narrowed about 0.5 mm. Although trans 6-6 was unchanged, cusp 6-6 and alveolar narrowed 0.6 mm. The 8 to 9% decrease in transarch widths in no case resulted in a reoccurrence of the crossbites. The lack of crossbite relapse following discontinuance of retention may be explained as follows: maxillary retention was maintained for an average of 5 years, the change is only 0.5 mm, the lower arch also narrowed by 0.2 mm, and there may have been some overexpansion at T_2 that was maintained by the maxillary retainer. Carter and McNamara³⁶ have demonstrated normally occurring decrements in arch dimensions with age in subjects whether or-

thodontic treatment was undertaken or not, and this could explain some of the decrease in transarch widths.

The 90% retention of maxillary arch width at T_3 demonstrated by the present adult sample compares favorably with both Herberger's³⁷ child sample (with a residual expansion of 90% percent;) and Spillane³³ and Spillane and McNamara's³⁴ mixed dentition samples (with a residual expansion of 85%).

Pain and tissue swelling

Haas¹⁻³ has pointed out that the acrylic bodies of the RME must be rounded, clear of the gingival margins of the teeth and not extend to the second molar region. Capelozza and coworkers²² performed RME on a large group of non-growing patients. They used the Haas appliance and activated the screw 4 quarter-turns a day in an attempt to split the palate. Eighteen percent of the sample failed to demonstrate a midline separation and they were referred for SA-RME. Undesired side effects such as pain, edema, and ulceration were frequent. Only 32% of the sample was free of complications.

Nine of 47 A-RME subjects experienced pain or tissue swelling. All were able to complete the expansion phase of treatment following turning back of the expander a few turns, a rest period of a week, and resumption of expansion at a slower schedule of every other day. In order to reduce this morbidity we are now turning 1 turn every other day and 1 turn every third day for the adults over 50 years of age or patients with signs of gingival recession. The morbidity experienced in this study is less than the 100% morbidity of surgically assisted expansion with its associated facial swelling, discomfort and work days lost for postoperative recuperation.

The molars tip buccally

Pretreatment, there was no significant difference in first molar angulation between the A-RME and the A-C groups (Table 5). This indicates that transarch deficiency in adults is not associated with either buccal or palatal inclination of the molars, though individuals may show these tendencies. Palate expansion decreased the molar angle (an increase in buccal flare), which averaged only 3.1° change per side. Coordination of the maxillary posterior dentition with its mandibular counterpart for proper occlusion was not difficult in the treatment phase following RME.

The C-RME group showed no change in molar angulation despite the considerable increase in trans 6-6 width. The difference between the adults and children relative to molar angulation may be explained because in the C-RME group there is parallel translation of the palatal shelves due to of the disjunction of the palate. In children, there was also no change associated with RME treatment in the palatal angle (Table 5). In the A-RME group following RME, the palatal shelves were angulated to the buccal (4° per

side) so that both the palatal shelves and the molars showed a modest buccal tilt.

The mandible will rotate and cause bite opening

The literature is replete with statements that children who undergo RME will, as a side effect, demonstrate mandibular rotation and bite opening.^{7,38} Extrusion of the maxillary posterior teeth or downward displacement of the maxilla have been suggested as possible mechanisms that lead to mandibular displacement.⁷ Bonded expansion appliances with occlusal coverage have been advocated to prevent the bite opening that has been thought to accompany palatal expansion.^{5,39}

Chang et al³⁵ noted that most of the previous investigations considered only short-term changes and lacked untreated controls for comparison. In their study, they examined children at the completion of comprehensive orthodontic treatment (3 years following RME), and at long term follow up (10 years post-RME). At both time intervals, there was no increase in the mandibular plane, and lower facial height increased as compared to the controls. The data from the present study confirm their results. The C-RME group had no change in SN-MP angles when measured between 1 and 2.5 years following RME (Table 6).

Will the mandibular plane open and will the molars extrude when adults undergo RME? These negative side effects have been suggested because failure of the midpalatal suture to separate would lead to tipping as well as extrusive forces on the anchor maxillary teeth.⁷ The palatal depth at the molar cusp and at the gingival height (Table 5) would increase if the molars extruded, however, these measurements were stable. Consistent with this finding the mandibular plane and lower face height were also unchanged. The absence of bite opening is remarkable since both child and adult expansion groups have a large number of subjects with extremely divergent mandibles as each groups averaged 4 to 5° more divergent than the norm. At the beginning of the expansion process, the mandible will rotate away from the cranium due to cuspal interferences. However, following the removal of the expander, the bite will close as occlusal forces and orthodontic treatment improve the inter-cuspatation of the posterior teeth.

The buccal gingiva will recede

The literature suggests a frequent association of gingival recession with labially positioned incisors and canines.^{40,41} Proclination of the mandibular incisors in class III patients, prior to orthognatic surgery has been shown to be associated with gingival recession.⁴² Labial expansion of incisors in experimental animals will cause the gingiva to recede.⁴³ Vanarsdall^{20,26,44} states that RME in adults will cause the teeth to perforate their thin plate of buccal bone, and consequently the gingiva will recede. This scenario presumes dental expansion through a static adult alveolus. However,

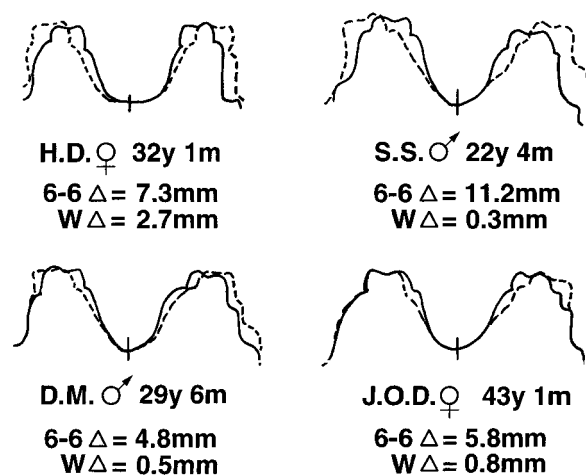


FIGURE 9. Palatal contours of 4 A-RME subjects superimposed as in Figure 8. The increases in trans 6-6 while large are due to displacements of the palatal alveolus with variable, but generally minimal expansion at the height of the vault.

the evidence from our contour tracings (Figures 8 and 9) and palatal measures indicate that the posterior dentition is translated *with* rather than *through* the alveolus.

Buccal attachment loss for adults who underwent RME when compared to the controls showed no significant difference between male subjects, but there were small but significant differences in the females for the maxillary first premolars, and first molars (Table 7). It is important to consider that the extent of the attachment loss was not clinically significant, averaging 0.6 mm for female and 0.3 mm for the male A-RME subjects compared to 0.1 mm in the adult controls. This expansion induced recession of 0.5 mm was not apparent to the patients and must be viewed in context; attachment loss is a common finding in adults with high standards of oral hygiene.⁴⁵⁻⁴⁸ For example, Serino et al⁴⁸ has shown that adults 30 to 41 years of age demonstrate 1 mm or more of attachment loss in over 30% of their buccal sites and half of these loss sites have 2 mm or more of recession.

Gingival recession has been defined by periodontal investigators as the loss of gingival attachment to the extent that the root cementum is exposed.^{40,48} This often is associated with cemental hypersensitivity.⁴⁹ Serino et al⁴⁸ stated that recession in his longitudinal adult study was a rare finding at buccal sites, unless at least 3 mm of buccal attachment loss was evident. We reexamined the study models for signs of post-treatment root exposure that was not present pretreatment. We noted 11 new sites out of 480 possible sites. These sites of root exposure were moderate, less than 1 mm in length, and usually associated with pretreatment buccal attachment loss. The average increase in crown length of 0.5 mm observed in the female RME patients above that of the controls is best defined as buccal attachment loss rather than gingival recession. Root expo-

sure was only occasionally observed and, when seen, it was not extensive.

Some level of iatrogenic response is inevitable in orthodontic treatment; the question is what is the frequency of extreme loss that may jeopardize the health of the dentition. Lupi et al⁵⁰ have reported that most adults undergoing orthodontic treatment will demonstrate some level of bone loss and root resorption. These authors suggest that adult treatment was generally safe because these changes were moderate and extreme loss was infrequent. In the present study, maximal recession of about 2 mm was infrequent and was also observed in the control sample.

Studies of adults have shown buccal gingival attachment loss increasing with age.⁴⁵⁻⁴⁸ Will RME promote an increase in this naturally occurring recession? Apparently not. During the 10 years following completion of RME treatment at T₃ the increase in crown heights for the maxillary teeth was similar to that for the mandibular dentition (Table 8), and similar to recession observed in the third and fourth decade of life in otherwise healthy adults.⁴⁸

We had assumed that patients who demonstrated the largest increase in gingival recession following RME would be the oldest, those who had the greatest maxillary transarch deficiency, those with the greatest amount of transarch expansion, and those who initially had the longest crown heights. Surprisingly, none of these variables proved to be significantly correlated to the degree of recession observed.

Are patients with advanced pre-existing gingival recession candidates for nonsurgical RME? There is insufficient evidence from this paper to know whether RME would seriously accelerate the recession of the already compromised buccal periodontium, but caution is advised. Adults with pre-existing recession tend to show the greatest number of sites with new or further recession over time.^{47,48} In mild cases of recession we turn the expansion screw less frequently (ie, every third day). In cases with advanced recession, however, SA-RME is indicated. Northway and Meade²⁴ have demonstrated significantly less crown lengthening in SA-RME groups compared to a group of adults expanded with the Haas expander as in the present study.

The measure of clinical crown height is an indirect quantification of buccal attachment loss. This measurement is not ideal since it is influenced by attrition of the crown or gingival hyperplasia, does not consider pocket depth, and does not measure bony dehiscence. It is possible for the gingival tissue to be intact while masking the underlying dehiscence of bone.⁵¹ Nevertheless, gingival recession of a significant nature is not obligatory following RME and only modest crown lengthening is observed.

Expansion of the alveolus

In a previous publication we examined the contour tracings of 5 adults who underwent RME and concluded that the expansion was achieved through displacement of the

alveolar process that starts at the apical third to midlevel of the palatal vault.²⁵ We termed this expansion "rapid maxillary alveolar expansion."

The palate width difference measures expansion at the height of the palate.³² This measure was 3.1 mm in the C-RME group, while the palatal width expanded 5.5 mm at the level of the palatal gingiva (Table 5). Thus, 56% of the expansion in children is likely to be due to skeletal distraction between the left and right maxillae (Figure 8). This is consistent with the findings of Krebs.^{52,52} Using metallic implants, he demonstrated that approximately 50% of the expansion achieved by RME in children was skeletal, and the remainder was dental-alveolar. In children there were 4.4 mm of expansion at the level of the midpalate; this represents 80% of the total transarch expansion.

Rapid maxillary expansion in adults, while equally effective in correction of transarch deficiency, was somewhat different in nature. The expansion across the top of the vault (the palate width difference) measured 0.9 mm while expansion at the level of the palatal gingiva was 5.1 mm (Table 5). This represents an 18% expansion compared to 56% in C-RME at the height of the palate (Figure 9). However, the mechanism is unlikely to be distraction between the right and left maxillae, since separation between the central incisors rarely occurred. At the midpalatal level, the expansion was 4.1 mm or 80% of the total transarch expansion achieved. Thus, at the level of the midpalate, the expansion observed in children and adults was similar in terms of percent of the total transarch expansion.

Is the alveolar expansion also noted on the buccal surface of the maxilla? We determined this using the most prominent buccal point superior to the maxillary first molars. This is similar to the maxillary point used by Betts et al^{13,54} in their analysis of maxillary deficiency using frontal radiographs. In C-RME, the alveolar 6-6 expanded 5.5 out of 5.7 mm of transarch expansion, or 96% of the total. In A-RME, the alveolar 6-6 expanded 3.3 out of 4.6 mm of transarch expansion, or 72% of the total expansion. These data indicate that the adult alveolar housing is translated buccally by the Haas expander but not as fully as in children. The outcome of nonsurgical RME probably represents a continuum; from young children who experience about half their expansion in the base of the maxilla and half in the dentoalveolar complex, to older adolescents who experience a greater percentage in the alveolus, to adults whose expansions occur largely in the alveolus. The qualitative difference in the palate expansion in children and adults can be visualized by comparing the T1 and T2 contour tracings of their palates (Figures 8 and 9).

How can we explain this orthopedic translation of the alveolus with nonsurgical RME? The forces generated by the Haas expander, with its rigid acrylic bodies pressing against the lateral walls of the palate, are quite high and would be sufficient to bend bone.⁵⁵ Frost⁵⁶ and Epker and Frost⁵⁷ have studied the remodeling of bone under various

forces and they theorize that when a bone surface bends so that it becomes more concave, bone apposition occurs on that surface. On the other hand, when a bone surface bends so that it becomes less concave, bone resorption will occur on that surface. The bending of the palatal walls in the buccal direction away from their superior articulations causes a concavity on the buccal wall of the maxilla, and thus would induce bone formation. The palatal surface would become convex and induce bone resorption. Additionally, the occlusal forces acting during prolonged retention would reinforce this tendency, as illustrated by Epker and O'Ryan.⁵⁸

Surgically assisted versus nonsurgical RME

The literature on SA-RME concentrates on descriptions of surgical technique but suffers from small sample size, minimal quantification of results, absence of control groups, and lack of long-term data. The recent paper by Northway and Meade²⁴ largely corrects these deficiencies. Specifically, they compared 2 SA-RME groups to an adult nonsurgical RME group that was similar to our study group. Each group had up to 15 subjects. The authors state, "maxillary expansion in adults, both orthopedic as advocated by Haas and surgically assisted, is predictable and stable." The benefit of the surgical assist was a greater increase in palatal volume and a smaller increase in crown length.

Surgical procedures, however, are associated with morbidity such as pain, facial swelling, sinus infection, and work loss. Following expansion there is an awkward stage of a large and unsightly midline diastema. Cureton and Cuenin⁵⁹ have recently documented the possibility of asymmetric separation between the maxillary central incisors resulting in osseous defects, tooth mobility, gingival recession and external root resorption. The subtotal Le Fort I procedures in particular expose the patient to grave, though rare, complications. Lanigan⁶⁰ stated that separation of the pterygoid plates may infrequently cause excessive hemorrhage, thrombosis (which can lead to stroke), and arteriovenous fistulae between the carotid sinus and carotid artery.

Ultimately the clinician must decide for each individual adult patient whether it is best to expand the maxilla with nonsurgical RME or SA-RME. Having these 2 viable options greatly enhances our ability to treat cases of maxillary arch deficiency. However, in view of the costs, morbidity, and surgical risks of SA-RME and the infrequently observed or minimal consequences of RME, each case should be evaluated to determine if a nonsurgical approach would provide an acceptable correction of maxillary transarch deficiency.

CONCLUSIONS

We examined 47 adults whose transarch widths were increased using a Haas appliance that expanded the palatal alveolus rather than split the palate. To achieve alveolar

expansion, a properly fitted appliance turned 1 time per day or preferably every other day is advocated. This protocol reduces the incidence of pain and tissue swelling that occurs from more frequent turning schedules in the vain attempt to split the adult palate.

The increase in transarch width of 4.5 mm for first molars and 5.5 mm for second premolars was similar to that achieved in the children's expansion group and in every case, the expansion was sufficient to correct the transverse malocclusions. The corrections were stable over time even after discontinuance of maxillary retention.

Over-expansion allows the molars to return to an upright position; as a result, there was minimal buccal flare of the molars. The modest increase in buccal angulation of 3° per side was consistent with similar tipping of the palatal shelves.

Rapid maxillary expansion did not rotate the mandible or cause the bite to open despite the presence of many high angle subjects in the sample.

Buccal attachment loss was not statistically significant for males when the adult expansion group was compared to the adult control group. However, females had significantly more loss (0.5 mm) than the control adults did. This modest recession was not noted by the patients and did not compromise the health of the dentition.

Surgically assisted expansion is associated with high cost, morbidity, and surgical risks. Orthodontists now have a nonsurgical option with a high level of efficacy and stability that is safe and applicable for most cases requiring maxillary transarch expansion.

ACKNOWLEDGMENTS

The authors thank Drs Charles Green and Zane Muhl for their critical reading of the manuscript.

REFERENCES

1. Haas AJ. Rapid expansion of the maxillary dental arch and nasal cavity by opening the mid-palatal suture. *Angle Orthod.* 1961;31:73-90.
2. Haas AJ. The treatment of maxillary deficiency by opening the mid-palatal suture. *Angle Orthod.* 1965;65:200-217.
3. Haas AJ. Palatal expansion: just the beginning of dentofacial orthopedics. *Am J Orthod.* 1970;57:219-255.
4. Proffit WR. *Contemporary Orthodontics*. St. Louis, Mo: Mosby; 1986: 239,619.
5. McNamara JA Jr, Brudon WL. *Orthodontic and Orthopedic Treatment in the Mixed Dentition*. Ann Arbor, Mich: Needham Press; 1993.
6. Bishara SE, Staley RN. Maxillary expansion: clinical implications. *Am J Orthod Dentofacial Orthop.* 1987;91:3-14.
7. McNamara JA Jr. *The role of the transverse dimension in orthodontic diagnosis and treatment planning*. In: Craniofacial Growth Series, Monograph 36. Ann Arbor, Mich: University of Michigan Center for Human Growth and Development; 1999.
8. Melsen B. A histological study of the influence of sutural morphology and skeletal maturation of rapid palatal expansion in children. *Trans Eur Orthod Soc.* 1972;48:499-507.

9. Melsen B. Palatal growth studied on human autopsy material. A histologic microradiographic study. *Am J Orthod.* 1975;68:42–54.
10. Melsen B, Melsen F. The postnatal development of the palato-maxillary region studied on human autopsy material. *Am J Orthod.* 1982;82:329–342.
11. Persson M, Thilander B. Palatal suture closure in man from 15 to 35 years of age. *Am J Orthod.* 1977;72:42–52.
12. Bell WH, Epker BN. Surgical-orthodontic expansion of the maxilla. *Am J Orthod.* 1976;70:517–528.
13. Betts NJ, Vanarsdall RL, Barber HD, Higgins-Barber K, Fonseca RJ. Diagnosis and treatment of transverse maxillary deficiency. *Int J Adult Orthodon Orthognath Surg.* 1995;10:75–96.
14. Lines PA. Adult rapid maxillary expansion with corticotomy. *Am J Orthod.* 1975;67:44–56.
15. Kennedy JW, Bell WH, Kimbrough OL, James WB. Osteotomy as an adjunct to rapid maxillary expansion. *Am J Orthod.* 1976;70:123–137.
16. Bays RA, Greco JM. Surgically assisted rapid palatal expansion: an outpatient technique with long-term stability. *J Oral Maxillofac Surg.* 1992;50:110–113.
17. Pogrel MA, Kaban LB, Vargarik K, Baumrind S. Surgically assisted rapid maxillary expansion in adults. *Int J Adult Orthodon Orthognath Surg.* 1992;7:37–41.
18. Mossaz CF, Byloff FK, Richter M. Unilateral and bilateral corticotomies for correction of maxillary transverse discrepancies. *Eur J Orthod.* 1992;14:100–116.
19. Lehman JA, Haas AJ, Haas DG. Surgical orthodontic correction of transverse maxillary deficiency: a simplified approach. *Plast Reconstr Surg.* 1984;73:62–68.
20. Vanarsdall RL. Periodontal/orthodontic interrelationships. In: Graber TM, Vanarsdall RL, eds. *Orthodontics: Current Principles and Techniques, 2d ed.* St. Louis, Mo: Mosby; 1994:712–749.
21. Wertz R, Dreskin M. Midpalatal suture opening: a normative study. *Am J Orthod.* 1977;71:367–381.
22. Capelozza Filho L, Cardoso Neto J, da Silva Filho OG, Ursi WJ. Non-surgically assisted rapid maxillary expansion in adults. *Int J Adult Orthodon Orthognath Surg.* 1996;11:57–66.
23. Handelman CS. Limitations of orthodontic treatment in adults: Part 2, The significance of alveolar width in orthodontic diagnosis and treatment planning. In: McNamara JA Jr, Trotman CA, eds. *Orthodontic Treatment: The Management of Unfavorable Sequela.* Craniofacial Growth Series, Monograph 31. Ann Arbor, Mich: University of Michigan Center for Human Growth and Development; 1996:232–240.
24. Northway WM, Meade JB Jr. Surgically assisted rapid maxillary expansion: a comparison of technique, response and stability. *Angle Orthod.* 1997;67:309–320.
25. Handelman CS. Nonsurgical rapid maxillary alveolar expansion in adults: a clinical evaluation. *Angle Orthod.* 1997;67:291–305.
26. Vanarsdall RL Jr. Commentary: nonsurgical rapid maxillary alveolar expansion in adults: a clinical evaluation. *Angle Orthod.* 1997;67:306–307.
27. Mew J. Letters: rapid maxillary expansion. *Angle Orthod.* 1997;67:404.
28. Hamula W. Modified mandibular Schwarz appliance. *J Clin Orthod.* 1993;27:89–93.
29. Howe RP, McNamara JA Jr, O'Connor KA. An examination of dental crowding and its relationship to tooth size and arch dimension. *Am J Orthod.* 1983;83:363–373.
30. Brust EW. *Arch Dimensional Changes Concurrent with Expansion in the Mixed Dentition* [master's thesis]. Ann Arbor, Mich: University of Michigan; 1992.
31. Brust EW, McNamara JA Jr. Arch dimensional changes concurrent with expansion in mixed dentition patients. In: Trotman CA, McNamara JA Jr, eds. *Orthodontic Treatment: Outcome and Effectiveness.* Craniofacial Growth Series, Vol. 30. Ann Arbor, Mich: University of Michigan Center for Human Growth and Development; 1995.
32. Ladner PT, Muhl ZF. Changes concurrent with orthodontic treatment when maxillary expansion is a primary goal. *Am J Orthod Dentofacial Orthop.* 1995;108:184–193.
33. Spillane LM. *Arch Dimensional Changes in Patients Treated with Maxillary Expansion During the Mixed Dentition* [master's thesis]. Ann Arbor, Mich: University of Michigan; 1990.
34. Spillane LM, McNamara JA Jr. Maxillary adaptations following expansion in the mixed dentition. *Semin Orthod.* 1995;1:176–187.
35. Chang JY, McNamara JA Jr, Herberger TA. A longitudinal study of skeletal side effects induced by rapid maxillary expansion. *Am J Orthod Dentofacial Orthop.* 1997;112:330–337.
36. Carter GA, McNamara JA Jr. Longitudinal dental arch changes in adults. *Am J Orthod Dentofacial Orthop.* 1998;114:88–99.
37. Herberger TA. *Rapid Palatal Expansion: Long Term Stability and Periodontal Implications* [master's thesis]. Philadelphia, Penn: University of Pennsylvania; 1987.
38. Thörne N. Experiences on widening the median maxillary suture. *Trans Eur Orthod Soc.* 1956:279–290.
39. Sarver DM, Johnston MW. Skeletal changes in vertical and anterior displacement of the maxilla with bonded rapid palatal expansion appliances. *Am J Orthod Dentofacial Orthop.* 1989;95:462–466.
40. Källestål C, Uhlin S. Buccal attachment loss in Swedish adolescents. *J Clin Periodontol.* 1992;19:485–491.
41. Modéer T, Odenrick L. Post-treatment periodontal status of labially erupted maxillary canines. *Acta Odontol Scand.* 1980;38:253–256.
42. Årtun J, Krogstad O. Periodontal status of mandibular incisors following excessive proclinations. A study in adults with surgically treated mandibular prognathism. *Am J Orthod Dentofacial Orthop.* 1987;91:225–232.
43. Steiner CG, Pearson JK, Ainamo J. Changes of the marginal periodontium as a result of labial tooth movement in monkeys. *J Periodontol.* 1981;52:314–320.
44. Vanarsdall RL Jr. Transverse dimension and long-term stability. *Semin Orthod.* 1999;5:177–180.
45. Gorman WG. Prevalence and etiology of gingival recession. *J Periodontol.* 1967;38:316–322.
46. Sangnes G, Gjermo P. Prevalence of oral soft and hard tissue lesions related to mechanical toothcleaning procedures. *Community Dent Oral Epidemiol.* 1976;4:77–83.
47. Løe H, Ånerud Å, Boysen H. The natural history of periodontal disease in man; prevalence, severity, and extent of gingival recession. *J Periodontol.* 1992;63:489–495.
48. Serino G, Wennström JL, Lindhe J, Eneroth L. The prevalence and distribution of gingival recession in subjects with a high standard of oral hygiene. *J Clin Periodontol.* 1994;21:57–63.
49. Addy M, Mostafa P, Newcombe RG. Dentine hypersensitivity: the distribution of recession, sensitivity and plaque. *J Dent.* 1987;15:242–248.
50. Lupi JE, Handelman CS, Sadowsky C. Prevalence and severity of apical root resorption and alveolar bone loss in orthodontically treated adults. *Am J Orthod Dentofacial Orthop.* 1996;109:28–37.
51. Karring T, Nyman S, Thilander B, Magnusson I. Bone regeneration in orthodontically produced alveolar bone dehiscences. *J Periodontol Res.* 1982;7:309–315.
52. Krebs A. Expansion of the midpalatal suture studies by means of metallic implants. *Trans Eur Orthod Soc.* 1958;34:163–171.
53. Krebs A. Midpalatal suture expansion studies by the implant method over a seven year period. *Trans Eur Orthod Soc.* 1964;40:131–142.
54. Betts NJ, Lisenby CW. Normal adult transverse jaw values ob-

- tained using standardized posteroanterior cephalometrics [abstract 1567]. *J Dent Res.* 1994;73:298.
55. Zimring JF, Isaacson RJ. Forces produced by rapid maxillary expansion. *Angle Orthod.* 1965;35:178–186.
 56. Frost HM. *The Laws of Bone Structure.* Springfield, Ill: CC Thomas; 1964.
 57. Epker BN, Frost HM. Correlation of patterns of bone resorption and formation with physical behavior of loaded bone. *J Dent Res.* 1965;44:33–42.
 58. Epker BN, O’Ryan F. Determinants of Class II morphology: I. A biomechanical theory. In: McNamara JA Jr, Carlson DS, Ribbens K, eds. *The Effects of Surgical Intervention on Craniofacial Growth. Craniofacial Growth Series, Monograph 12.* Ann Arbor, Mich: University of Michigan Center for Human Growth and Development; 1982.
 59. Cureton SL, Cuenin M. Surgically assisted rapid palatal expansion: orthodontic preparation for clinical success. *Am J Orthod Dentofacial Orthop.* 1999;116:46–59.
 60. Lanigan DT. Injuries to the internal carotid artery following orthognathic surgery. *Int J Adult Orthodon Orthognath Surg.* 1988; 4:215–220.