

# The negative effect of mouth breathing on the body and development of the child.



Dr John Flutter BDS (London) Dental Surgeon.

Brisbane Queensland

I started my first orthodontic case in 1972 when I started in general practice in London. My practice is now limited to orthodontics and dentofacial orthopaedics and I have comprehensive records of all my orthodontic cases for the last twenty five years.

Over the years I have noticed an increasing tendency for children to show evidence of chronic or habitual mouth breathing. This has a negative effect not only on the development of the jaws the shape of the developing cranium and the occlusion but also on the general health of the child.

I have been trying to help children develop nasal breathing for over twenty years. I have discovered more ways that don't work than ways that do! I use several different techniques either separately or together.

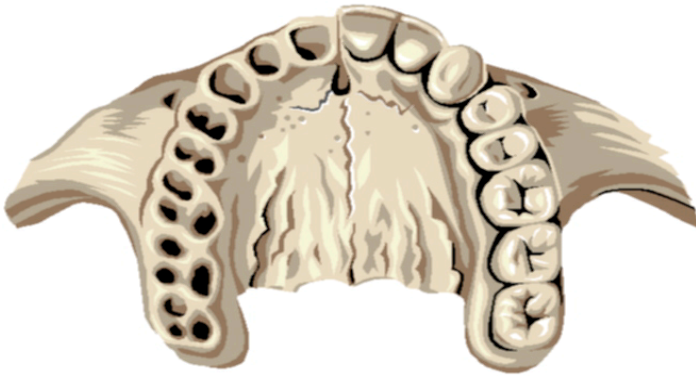There is plenty of evidence in the literature that mouth-breathing has an adverse effect on the growth and development of the face and jaws. All children who are habitual mouth-breathers will have a malocclusion.

*The mouth breathers' maxillas and mandibles were more retrognathic. Palatal height was higher, overjet was greater in mouth breathers. Overall, mouth breathers had longer faces, with narrower maxillae and retrognathic jaws. (1)*


The tongue plays a large part in influencing cranial and maxillary growth. When a child is new born the forward thrusting of the tongue to express milk from the mothers breast is the force that drives the horizontal or forward growth of the maxillae.

The tongue is ideally in contact with the roof of the mouth at rest and during the sub-conscious swallow. In this position, the tongue exerts a lateral force which counterbalances the inward force exerted by the buccinator muscles. This is what maintains the integrity of the developing maxilla. When the tongue rests and functions in the palate the teeth erupt around the tongue producing the normal or healthy arch form. The moment the child is a mouth breather, and the tongue drops to the floor of the mouth, the buccinators continue to push inwards and cause the upper arch to collapse.

It is not possible to have the tongue rest and function in the palate and breathe through the mouth. In the chronic mouth breathing child the tongue falls from the roof of the mouth and no longer provides support for the upper arch. This results in a reduced size and retrognathic upper arch.

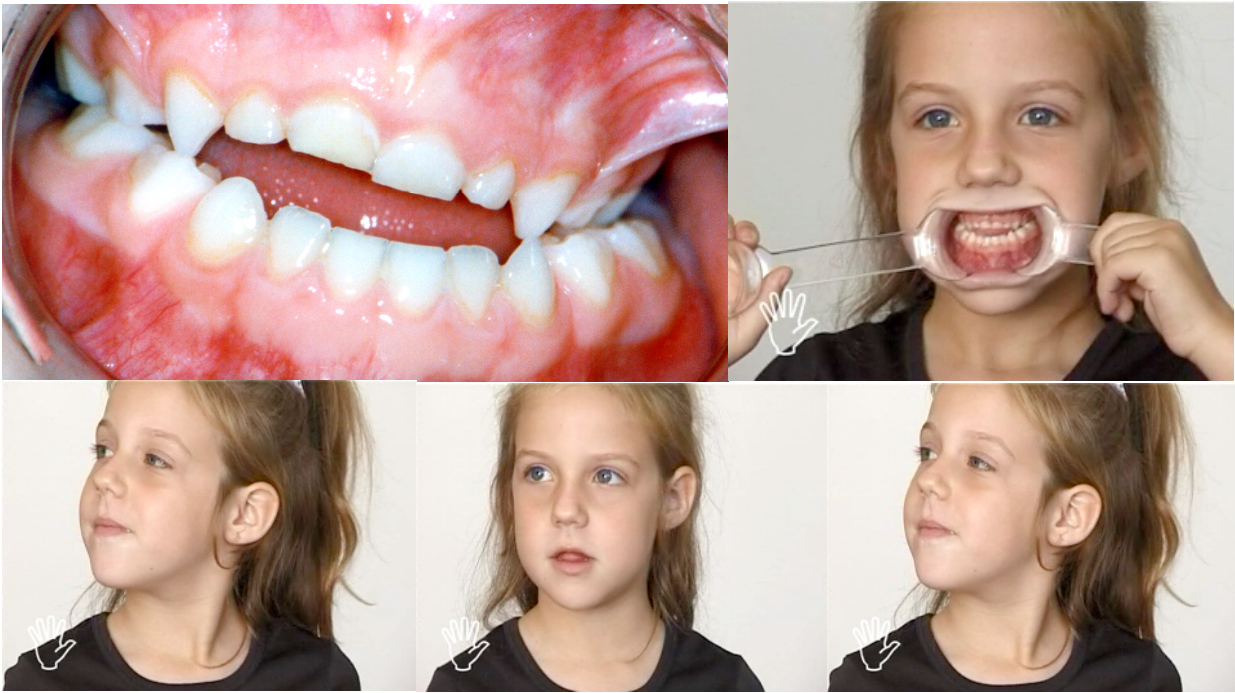

The normal arch form is rounded with the widest part of the maxillae at the mesio-buccal cusps of the upper second molars. This shape is produced when the tongue rests and functions in the palate. In most malocclusions the upper molars are mesially rotated leaving the widest part of the arch at the distal cusps of the upper molars.

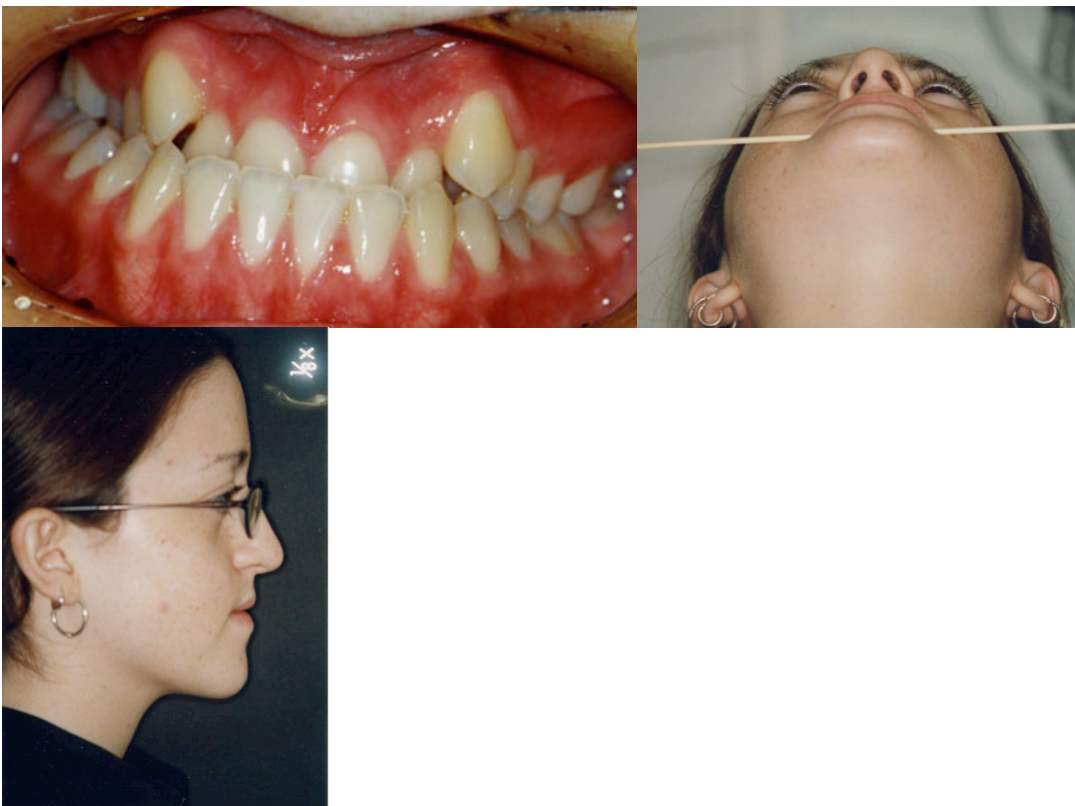

When Harvold et al surgically blocked the noses of young monkeys they all developed malocclusions.

All experimental animals gradually acquired a facial appearance and dental occlusion different from those of the control animals. (2)



These are stills from a video of a child displaying a typical mouth breathing pattern. The upper arch is under-developed with a uni-lateral crossbite and an anterior open bite. The posterior cross bite reflects the narrow upper arch unsupported by the tongue and the anterior open bite is a result of the anterior tongue thrust. The upper and lower arches are both retrognathic; the upper arch is more retrognathic leading to the anterior cross bite.

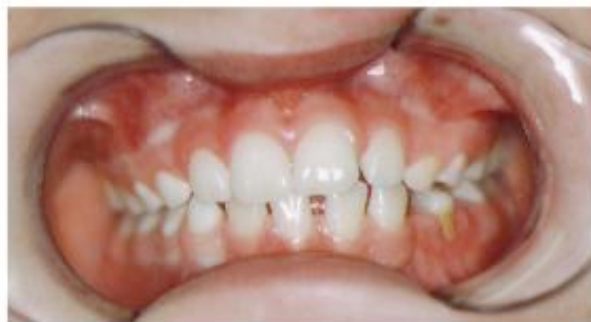
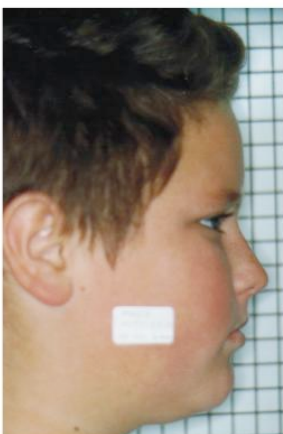
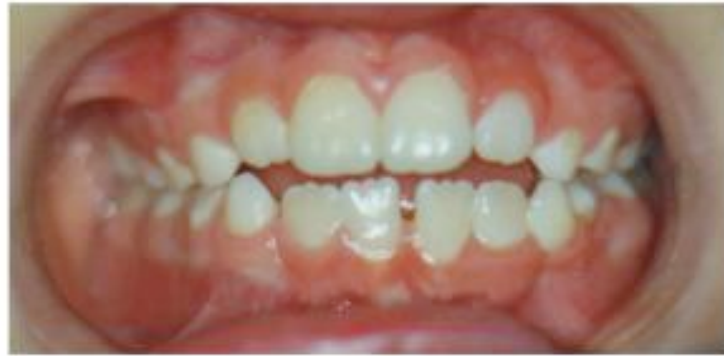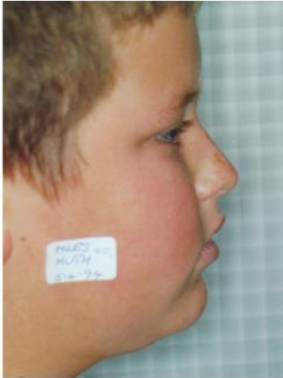When assessing a new patient salutary lessons can be learned by looking at the face from a sub-mental view. Chronic mouth breathing has left this young adult with a severely retrognathic maxillae. When viewed from this direction, the underside of the orbit should not be visible. Two thirds of

the floor of the orbit is the maxillae and when the maxillae is retrognathic the eye support is compromised. The lateral photograph would have been better if I had asked the patient to take her spectacles off before taking the photograph! Even so it is possible to recognise the retrognathic maxillae.

### Postural Implications of Chronic Mouth-breathing

Children who are chronic mouth breathers will tend to have a head tilted or pitched backwards. Any head posture where the head is not held level will have an influence on the shape, size and position of all the bones in the cranium.



Change in head posture and dentition in a boy treated only with a Trainer for one year to establish nasal breathing and improved myofunctional patterns. Note the head is no longer tipped or pitched backwards when nasal breathing is established.

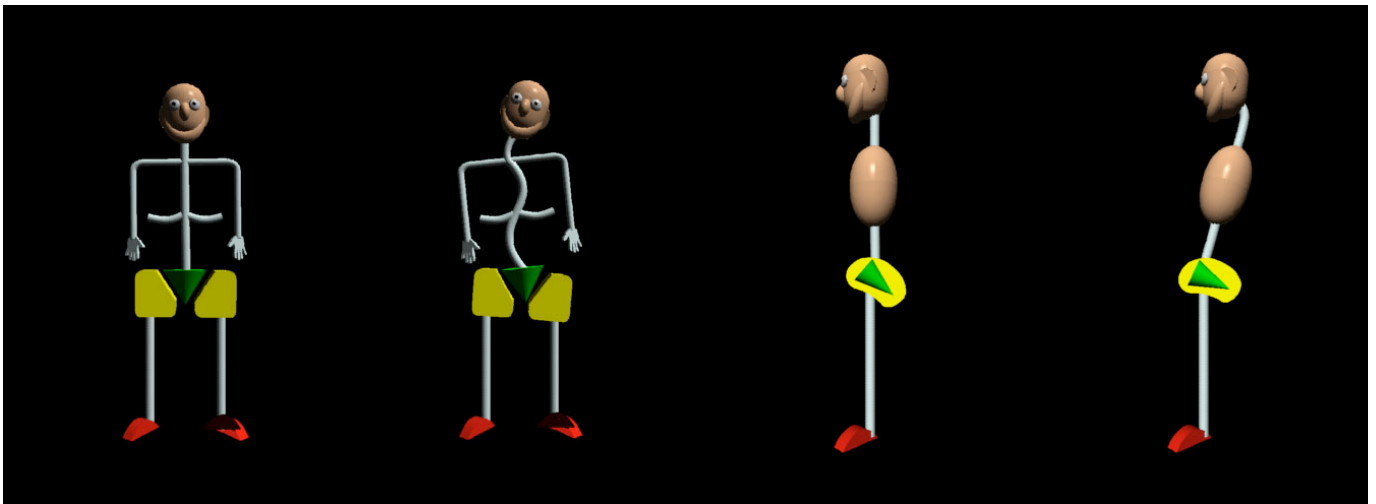
The shape of the cranium in the growing child will be distorted when the cranium is not held level. The adult cranium weighs between 4-5 Kg, the child's cranium a little less, and it contains largely water. If the head is not held level then there will be an increased mass of cranial contents on the downhill side leading to cranial distortion. The cranium consists of twenty nine different bones separated by sutures. If there is distortion in any bone in the cranium it will be reflected in all bones in the cranium including the upper and lower jaws.

In the mouth breathing child the head is pitched or tilted backwards increasing the mass of cranial contents in the posterior part of the cranium. If the child is able to improve the cranial posture by establishing nasal breathing then the cranium will have the opportunity to grow with a more favourable pattern. This improved pattern will be reflected throughout the cranium including the dental arches.

There is no distortion in one part of the body that is not reflected throughout the body. For a level cranium we need level shoulders, a level pelvis and this requires good foot support.

Sometimes the poor head posture is a result of a pattern that arises lower in the body, for example, a tilted pelvis or pronated feet as the body's proprioceptors constantly try to rebalance the body. This is called an ascending pattern. Sometimes the poor head posture arises in the cranium, as in chronic mouthbreathing. This is called a descending pattern.

I do not treat the postural patterns but I have learned to recognise them. I work with other health workers who help the patient to improve the posture and foot support.



There is no distortion on one part of the body that is not reflected throughout the body. Body distortions can be either ascending or descending problems. When we establish nasal breathing we see an improvement in the entire body posture and the head levels. If after correcting mouth breathing I still observe body distortions I refer other health workers.

### Establishing nasal breathing

When I see a child for the first time seeking orthodontic treatment the first thing I assess is the breathing pattern. Children who are chronic mouth breathers will all hyperventilate. In normal nasal breathing the child will inhale/exhale about every six seconds. Children who are chronic mouth-breathers will inhale/exhale about every three seconds. It is often possible to note this by looking at the rise and fall of the shoulders in time with the breathing.

When I see the shoulders and chest moving during relaxed breathing I see it as a clear indication that all is not well. Breathing should always be controlled from the diaphragm with no visible outward signs of the breathing.

In addition, breathing should be silent. So when I can hear the child breathe it is a strong indication the breathing is dysfunctional.

Children who are chronic mouth breathers as a result of an allergic rhinitis will only manage to breathe through the nose if it is possible identify and eliminate the allergens. Allergens may be airborne and inhaled or food allergies that are consumed.


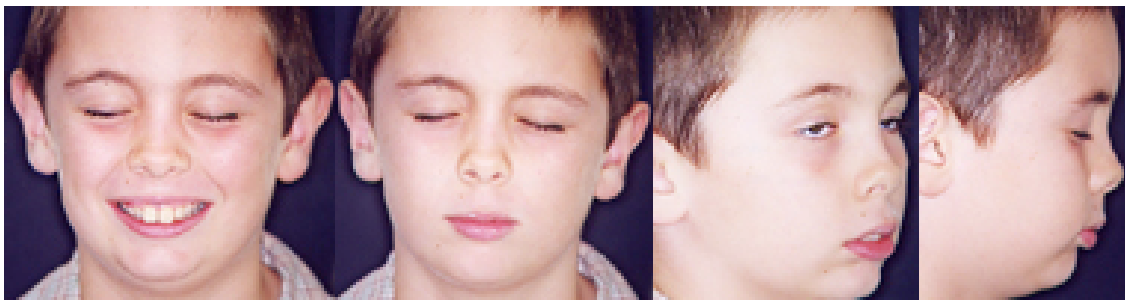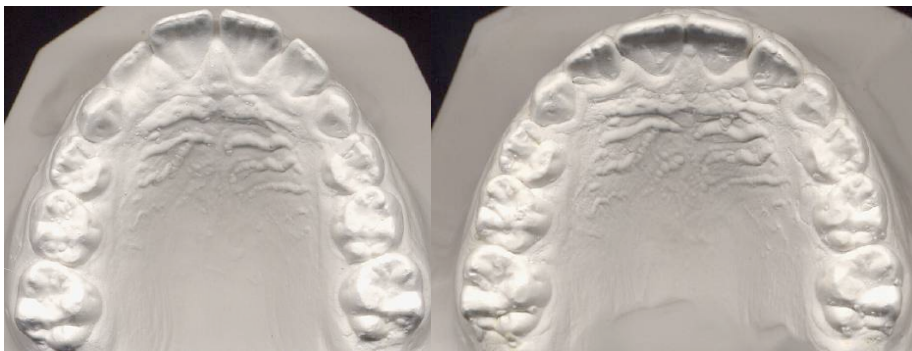
For the children who do not display allergic rhinitis then establishing nasal breathing is often a matter of breaking the mouth-breathing pattern. Sometimes it is necessary to reduce the hyperventilation in these children before the pattern can be changed.

Generally the younger the patient the easier it is to change the breathing pattern. The techniques I use to help children to establish nasal breathing include:

The Pre-Orthodontic Trainer<sup>®</sup> worn for a minimum of one year.  
Arch expansion followed by the Trainer or Biobloc therapy or fixed appliance  
The Breathing Well Programme  
A Home Audit

**The Pre-Orthodontic Trainer<sup>®</sup> worn for a minimum of one year.**

To establish nasal breathing in the younger child in the early mixed dentition I encourage the child to wear a Pre-Orthodontic Trainer<sup>®</sup>. This is a prefabricated removable appliance that is worn all night while the child is asleep and one hour during the day while the child is awake. With the Trainer in the mouth during the day the child will have the lips together and will breath through the nose. In this first example the child breaks the mouth-breathing pattern over a period of one year and normal growth of the face and jaws then follows. About thirty percent of the children, that I treat in the mixed dentition with a Trainer alone, require a second year of treatment.



Pre-Orthodontic Trainer<sup>®</sup>

If nasal breathing is established in the growing child then normal growth can be established. This child wore only a Pre-Orthodontic Trainer<sup>®</sup> for one year and established nasal breathing. Note the change in arch form as a result. The rounded or Roman arch replaces the narrow tapering Gothic arch form. The molar on the patient's left rotated well the right molar less well. Note the improvement in the child's facial appearance once lip seal and nasal breathing is established.

*Thus we found that a change from mouth-open to mouth-closed breathing was associated with (1) greater mandibular growth expressed at the chin in both sexes, (2) greater facial growth expressed at the midface in males. (3)*

### **Arch expansion followed by the Trainer or Biobloc therapy or fixed appliance**

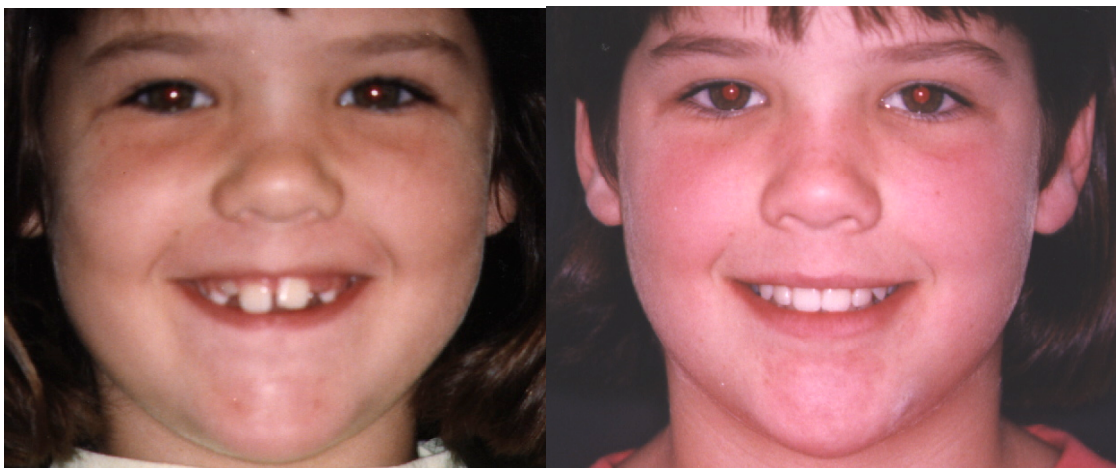
When the upper dental arch is expanded it will inevitably result in an increase in the width of the nasal passages. It also provides room for the tongue to rest and function in the palate. Often, especially in the younger child, arch expansion will result in the vault of the upper arch falling also increasing the height of the nasal passages.

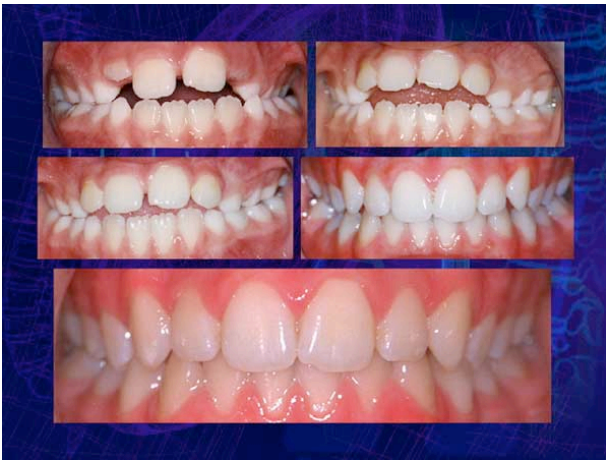Research has shown that arch expansion usually relapses but not always.

*Very soon it became clear, that Orthodontically induced transverse sizes of dental arches are very unstable.(4)*

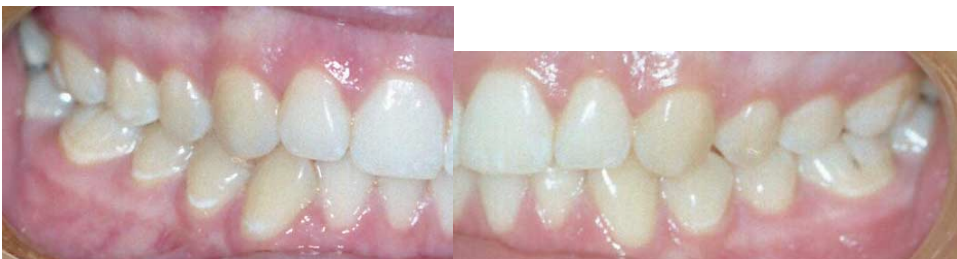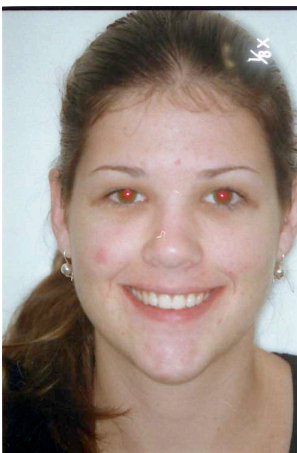
We need a well developed upper arch to train the tongue to rest and function there. More importantly we need the tongue to rest and function in the palate to maintain the expanded arch form. We all see relapse after arch expansion but I hope we all see arches that remain stable long term after expansion. In my experience the arches that remain stable after expansion are those where the tongue retains the changes. A few children make this functional change themselves without help, but most children need myofunctional training to help establish a good tongue in palate posture. For this reason I always follow arch expansion with either a Trainer or Biobloc appliances or both.

If there is a posterior cross bite, which there usually is in mouth breathing children, I will start by correcting the crossbite with a Biobloc expansion appliance. In the child in the early mixed dentition I will use a palatal arch retainer to maintain arch form while I establish nasal breathing and improved muscle function. For this I use a Trainer often with the Breathing Well Programme I will describe later. In the late mixed dentition and permanent dentition I tend to use a Biobloc 3 or postural appliance after arch expansion, again often with the Breathing Well Programme.





Before treatment, stages during treatment and one year after treatment.



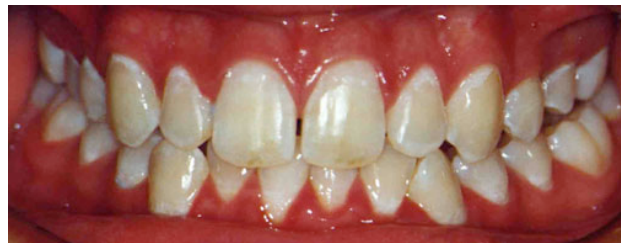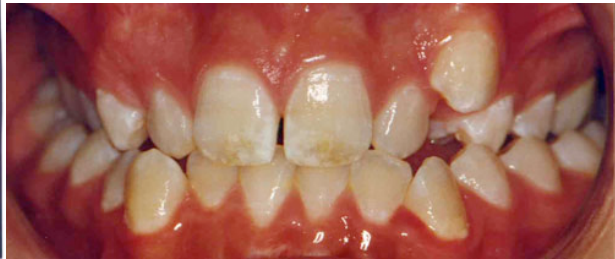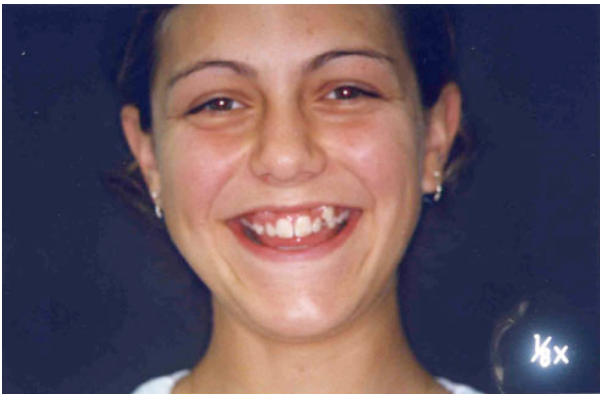
Seven years after treatment with no retention or fixed appliances used.

This girl presented with a chronic mouth-breathing pattern in the early mixed dentition. The posterior cross bite and the anterior open bite are typical of the mouth-breathing pattern. Using Orthotropic therapy using a series of Biobloc appliances the upper arch was expanded and the upper incisors advanced. The mandibular posture was then corrected with a lip seal and nasal breathing. The pattern remained stable long term as the patient maintained the nasal breathing pattern, a lip seal and the teeth in or near contact at rest.

### The Breathing Well Programme

For some children in addition to appliance therapy in order to establish a lip seal we need to reduce the hyperventilation. In much the same way as when we go running it may not be possible to take that much air in and out of the nose. In these cases we need to reduce the hyperventilation. To understand the mechanism here we need to understand a little of the biochemistry and the physiology of breathing.





This girl presented in the permanent dentition with a chronic mouth breathing pattern. By the time the second molars have erupted over 90% of the growth of the head and neck is completed. Modifying growth patterns was not an option. I developed the upper arch using a Biobloc expansion appliance and aligned the upper teeth with a fixed appliance. I fitted no lower appliance leaving the lower teeth largely unchanged. An important part of the treatment was to establish nasal breathing. While in the fixed appliance the patient wore a Trainer for Braces and completed the Breathing Well Programme. When nasal breathing is established the tongue can rest and function in the palate. If the tongue is not able to support the upper arch then relapse of the upper arch expansion is to be expected without permanent retention.

### The Biochemistry and Physiology of Breathing

#### Why do we breathe?

To deliver oxygen to body cells

To remove excess CO<sub>2</sub>

#### Oxygen

Body cell requirement 2-3%

Atmospheric content 21%

Oxygen does not have to be stored. It is always available

Its purpose is to provide energy and to regenerate cells

### **Carbon Dioxide**

Body requirement 6.5% or 40mm Hg

Atmospheric content 0.03%

It has to be produced by the body and stored

It is stored in the lungs at 6.5%

It is stored in arterial blood at 40mm Hg pressure

It is produced as a by product of exercise and digestion

When the child breathes through the mouth the stored carbon dioxide in the lungs escapes. This results in reduced levels of carbon dioxide in the lungs and reduced levels of carboxy-haemoglobin in the blood.

Many of the problems associated with chronic mouth breathing are as a result of this lowered level of carboxy-haemoglobin in the body.

### **Carbon Dioxide**

Has 4 major functions in the body

It facilitates release of oxygen from haemoglobin

It triggers breathing by activating the medullary sensor

It maintains pH by buffering with bicarbonate or carbonic acid

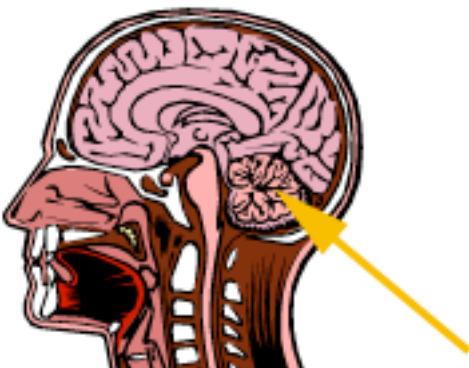
It prevents smooth muscle from going into spasm

All these functions are reduced or impaired in children who are chronic mouth-breathers.

### **What makes us breathe?**

Although we breathe subconsciously the point that we inhale is determined chemically.

As carbon dioxide builds up in the body it changes the pH of the blood and this pH shift triggers the brain to tell us to take a new breath.



### **The Medullary Trigger**

reacts to levels of CO<sub>2</sub> in the body of approximately 40mm Hg, producing a normal breathing pattern

## What is normal breathing ?

- Gentle wave pattern
- 4-5 litres of air per minute
- 8-10 breaths per minute
- Breathing in and out through the nose

This is about one breath every six seconds

## What goes wrong ?

The Medullary Trigger resets itself

Through constant exposure to CO<sub>2</sub> levels lower than 40mm Hg, mainly as a result of mouth breathing, the trigger is activated far earlier, causing over breathing or hyperventilation.

This is often results in an inhale every three seconds

## The Problem with Mouth Breathing

The tongue no longer provides support for the upper jaw with resulting reduced upper arch size.

The vault rises leading to reduction in the size of the nasal passages contributing to congestion of nose

The pH of saliva elevates leading to increased rate of caries

A tendency to URT infections often resulting in tonsillitis and enlarged adenoids

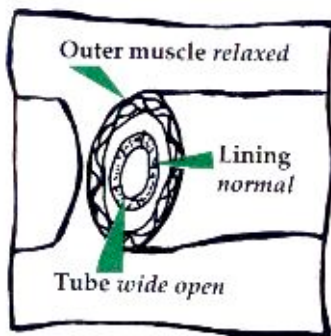
The medullary trigger resets at lower level leading to hyperventilation

The alkalinity of blood increases so less oxygen released from the blood. This is known as the Bohr Effect. Oxygen circulates the blood in the form of oxy-haemoglobin but reduced levels of carboxy-haemoglobin mean that less oxygen is released from the oxy-haemoglobin to enter the tissues so cells die

Smooth muscle spasm. Gastric reflux, asthma and bed wetting are commonly associated with chronic mouth-breathing

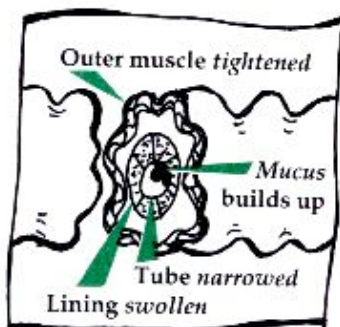
## Smooth muscle is found throughout the body

- Respiratory system
- Digestive system
- Circulatory system
- All hollow organs
- All tubes and ducts



### Smooth muscle goes into spasm causing

- Respiratory problems such as asthma
- Digestive disorders
- Circulatory problems
- Disturbed sleep
- Ear nose & throat issues



### The Solution to Mouth Breathing

Train the child to become a natural nose breather again

Address the issues that caused the initial problem

Institute a strategy to ensure this does not recur

### Fixing the problem

The Medullary trigger can be reset, by reversing the process and sending messages of increasing CO2 levels it is possible to reset the trigger and return the breathing pattern to normal

### The Breathing Well Program



designed to restore Nasal Breathing as the norm

This is a twelve week programme that involves both the child and parent. It takes about 20 minutes a day for twelve weeks. If more than one week is missed the child has to start again. The programme is a series of breathing training exercises done in a structured, regular pattern. The object of the programme is to reset the medullary trigger to respond to increased levels of carbon dioxide (carboxy-haemoglobin) and establish a

lip seal. It requires commitment on the part of parent and child but is very effective in reducing hyperventilation and establishing nasal breathing.

The programme is normally done in conjunction with the Trainer system to improve myofunctional patterns at the same time.

For more information on The Breathing Well Programme contact [john@jfdcourses.com](mailto:john@jfdcourses.com).

### **The Home Audit.**

To establish nasal breathing the child needs to be able to breathe clean air with a minimum of airborne particles.

I ask the child and parents to review the child's home environment.

I try and discourage fitted carpets in the child's bedroom. Fitted carpets trap particles that are released into the air when the carpet is walked on.

I encourage the parents to leave the bedroom window open at night to provide fresh air for the child during sleep.

I discourage pets in the house. This is often not possible to achieve but at least discourage pets in the child's bedroom.

Finally it is easier to establish nasal breathing when the child lives in a smoke free environment.

Electric air humidifiers can help to settle airborne particles in the child's bedroom at night.

### **Conclusion**

All children who are chronic mouth-breathers will develop a malocclusion.

It is possible to help many children establish nasal breathing. For many children mouth breathing is a habit that can be broken.

Often before establishing nasal breathing we need to expand the upper arch to make room for the tongue to rest and function there. After expansion, unless the tongue learns to rest and function in the palate the arch form will relapse.

Often we need to reduce hyperventilation before the child can establish nasal breathing. The Breathing Well Programme requires commitment by both the parent and child for it to be successful.

To establish nasal breathing in growing children requires very few technical skills on the part of the practitioner. The dentists and orthodontists who are most successful at helping children change any pattern are those practitioners who relate well and communicate well with children.

## References

- 1 Mouth Breathing in Allergic Children: It's Relationship to Dentofacial Development  
Bresolin, Shapiro E.T. Al. American Journal of Orthodontics 1983.

The mouth breathers' maxillas and mandibles were more retrognathic. Palatal height was higher, overjet was greater in mouth breathers. Overall, mouth breathers had longer faces, with narrower maxillae and retrognathic jaws.

This supports previous claims that nasal airway obstruction is associated with aberrant facial growth.

- 2 Egil P. Harvold, DDS Ph.D.,L.L.D.Brittta S. Tamer, DDS, Kevin Varervik, DDS., and George Chierici, DDS - American Journal of Orthodontics Vol 79. No. 4 April, 1981.

"All experimental animals gradually acquired a facial appearance and dental occlusion different from those of the control animals.

- 3 Donald G. Woodside, Sten Linder-Aronson, Anders Lundstrom, John William. American Journal of Orthodontics July 1991.

The amount of maxillary and mandibular growth and the direction of maxillary growth were studied in 38 children during the 5 years after adenoidectomy for correction of severe nasopharyngeal obstruction.

Thus we found that a change from mouth-open to mouth-closed breathing was associated with (1) greater mandibular growth expressed at the chin in both sexes, (2) greater facial growth expressed at the midface in males.

- 4 Expansion and Relapse in Long Follow up Studies. Orthodontic Dept. of the University Dental Hospital in Cologne - A Study of 500 patients from 1964. Schwarze C.

Very soon it became clear, that Orthodontically induced transverse sizes of dental arches are very unstable.

## Further reading

Biobloc Therapy by JRC Mew.

<http://jfdcourses.com>

<http://orthotropics.com/>

<http://www.myoresearch.com/>

<http://www.buteykoabc.com/>



**John Flutter Dental**  
Pty Ltd

Dr John Flutter graduated in London and worked in general practice in London before moving to Australia.

He is now in practice in Brisbane with the practice limited to orthodontics and dentofacial orthopaedics.

He is Board Eligible with the International Association for Orthodontics (IAO) Hawaii 1994

He is a former federal president of The Australian Association of Orofacial Orthopaedics (AAOO)

He has lectured to dentists and orthodontists on Myofunctional Therapy in over 60 countries in the world in association with Myofunctional Research Company.

Has produced a DVD entitled : "Myofunctional Effects on Facial Growth and The Dentition"