

**PennHIP Report**

Referring Veterinarian: Dr Timothy Bostley  
 Email: hiltonvet@gmail.com

Clinic Name: Hilton Veterinary Hospital  
 Clinic Address: 251 East Avenue  
 Hilton, NY 14468  
 Phone: (585) 392-2937  
 Fax: (585) 392-5417

**Patient Information**

Client: Licata, Karina  
 Patient Name: Lana  
 Reg. Name:  
 PennHIP Num: 154989  
 Species: Canine  
 Date of Birth: 28 Feb 2020  
 Sex: Female  
 Date of Study: 15 Mar 2021  
 Date of Report: 04 Apr 2021

Tattoo Num:  
 Patient ID: 14083-8  
 Registration Num:  
 Microchip Num: 956000012565754  
 Breed: MIXED BREED  
 Age: 13 months  
 Weight: 35 lbs/15.9 kgs  
 Date Submitted: 02 Apr 2021

**Findings**

Distraction Index (DI): Right DI = 0.50, Left DI = 0.46.  
 Osteoarthritis (OA): **No radiographic evidence of OA for either hip.**  
 Cavitation/Other Findings: No cavitation present.

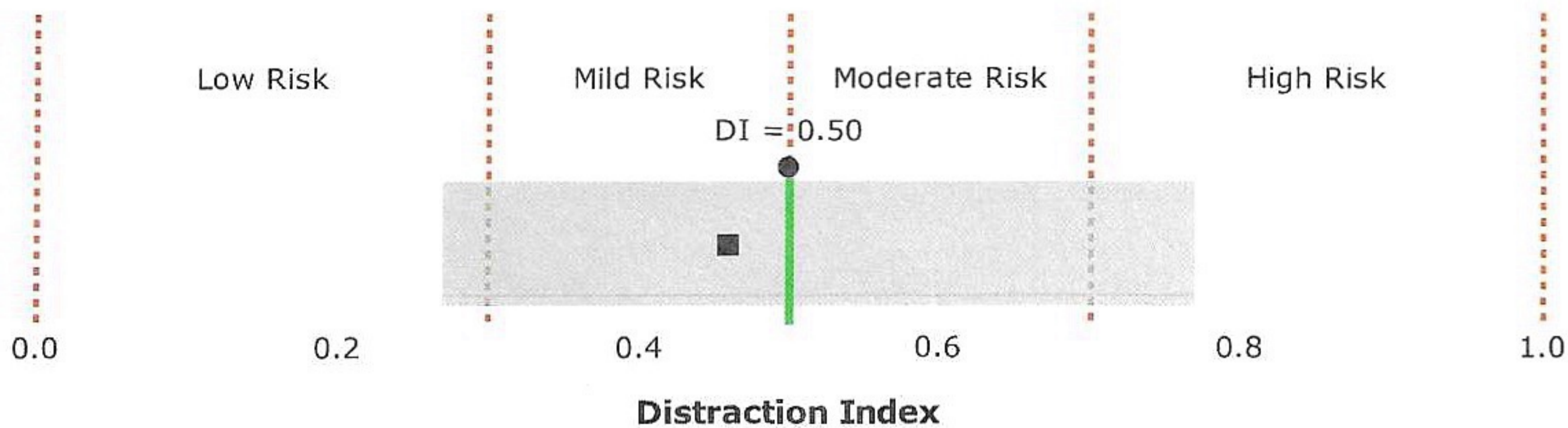
**Interpretation**

Distraction Index (DI): The laxity ranking is based on the hip with the greater laxity (larger DI). In this case the DI used is 0.50.

OA Risk Category: The DI is between 0.50 and 0.69. This patient is at moderate risk for hip OA.

Distraction Index Chart:

**MIXED BREED**



**BREED STATISTICS:** This interpretation is based on a cross-section of 10834 canine patients of the MIXED BREED breed in the AIS PennHIP database. The gray strip represents the central 90% range of DIs (0.27 - 0.77) for the breed. The breed average DI is 0.46 (solid square). The patient DI is the solid circle (0.50).