

# ENT Dilemmas for the Hospitalist

Nathan Page, MD, FAAP  
Division of Otolaryngology  
Phoenix Children's Hospital  
July 22, 2023

- Post-tonsillectomy hemorrhage
- Steroids in head/neck infections
- NSAIDs after ENT surgery
- Appropriate use of CT
- Acute mastoiditis
- Orbital cellulitis
- Cochlear implant issues
- Other topics?

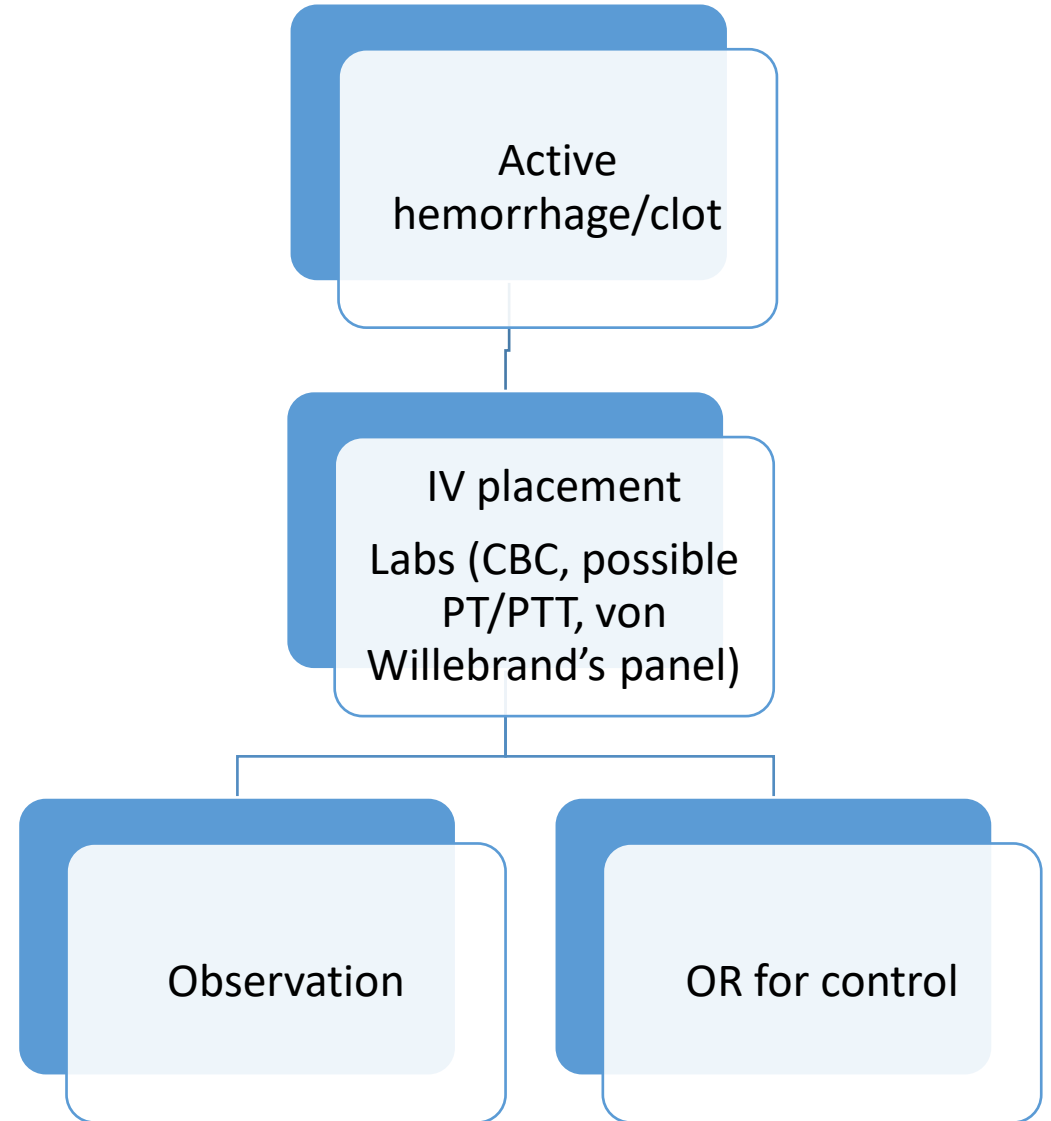
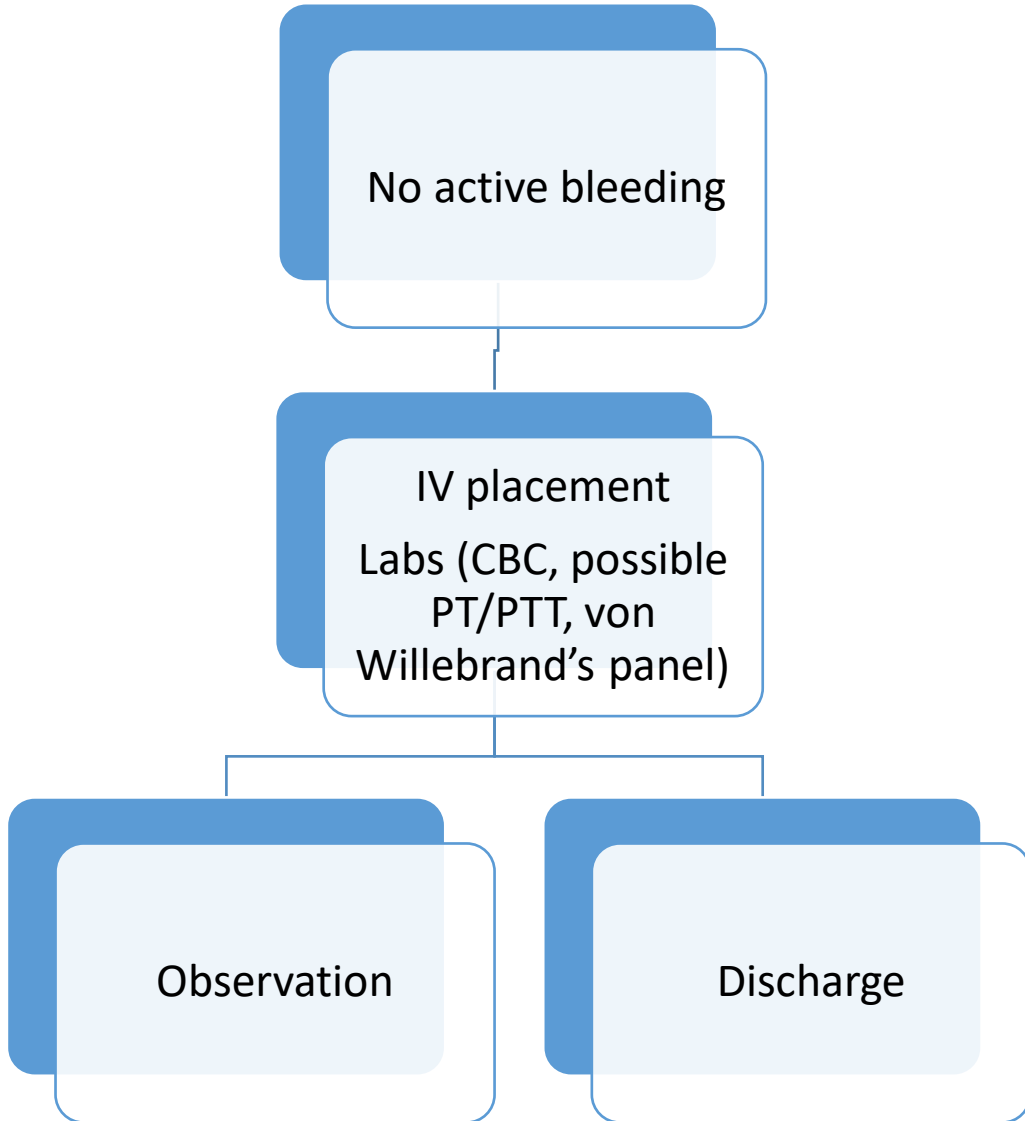
# Post-tonsillectomy hemorrhage

- Expected rate of 1-5%
- Highest in teens (and adults)
- Biphasic –
  - Primary (POD #0-1)
    1. Secondary ( $\geq$ POD #2)
- Peak POD#5-10

## Risk factors:

- Age
- Indication for surgery
  - Chronic tonsillitis
  - Peritonsillar abscess
- Medications?
  - NSAIDs
  - Dexamethasone
- Technique?

# Treatment



# Steroids in head/neck infections



## Reduction in edema vs immunosuppression

Steroids for peritonsillar abscess – placebo controlled trials

[Laryngoscope](#). 2018 Jan;128(1):72-77. doi: 10.1002/lary.26672. Epub 2017 May 31.

Overall – improved fever; some improvement in speed of recovery (mouth opening, oral intake, etc.)

# Steroid benefit?

## **Definitely**

- Acute sinusitis
  - Orbital cellulitis
  - Brain abscess
- Peritonsillar abscess
- Retropharyngeal abscess
- Facial paralysis (Bell's palsy)
- Airway compromise

## **No clear benefit**

- Neck abscess
- Mastoiditis

# NSAIDs post-ENT surgery

- Tonsillectomy/Adenoidectomy
- Head/neck surgery
- Tympanoplasty/mastoidectomy
- Sinus surgery



Guideline

# Clinical Practice Guideline: Tonsillectomy in Children

**Reginald F. Baugh, MD<sup>1</sup>, Sanford M. Archer, MD<sup>2</sup>,  
Ron B. Mitchell, MD<sup>3</sup>, Richard M. Rosenfeld, MD, MPH<sup>4</sup>,  
Raouf Amin, MD<sup>5</sup>, James J. Burns, MD<sup>6</sup>, David H. Darrow, MD, DDS<sup>7</sup>,  
Terri Giordano, MSN, CRNP, CORLN<sup>8</sup>, Ronald S. Litman, DO<sup>9</sup>,  
Kasey K. Li, MD, DDS<sup>10</sup>, Mary Ellen Mannix, MRPE<sup>11</sup>,  
Richard H. Schwartz, MD<sup>12</sup>, Gavin Setzen, MD<sup>13</sup>,  
Ellen R. Wald, MD<sup>14</sup>, Eric Wall, MD, MPH<sup>15</sup>,  
Gemma Sandberg, MA<sup>16</sup>, and Miles M. Patel, MS<sup>17</sup>**

Otolaryngology—  
Head and Neck Surgery  
144(1S) S1–S30  
© American Academy of  
Otolaryngology—Head and Neck  
Surgery Foundation 2011  
Reprints and permission:  
[sagepub.com/journalsPermissions.nav](http://sagepub.com/journalsPermissions.nav)  
DOI: 10.1177/0194599810389949  
<http://otojournal.org>

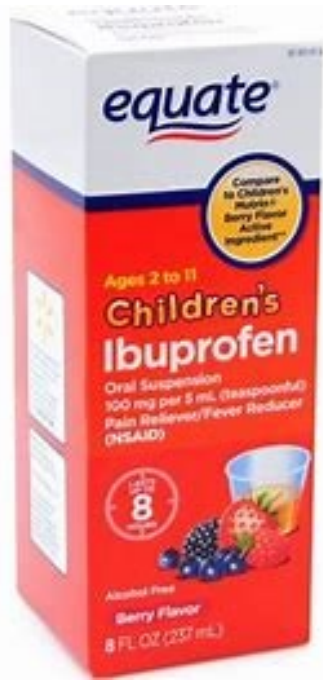

# Postoperative Care

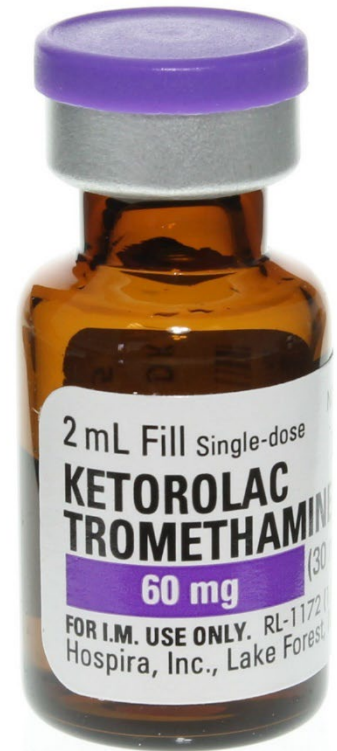**9. The clinician should advocate for pain management after tonsillectomy and educate caregivers about the importance of managing and reassessing pain.**

**Table 8.** Posttonsillectomy Pain Management Education for Caregivers

1. Throat pain is greatest the first few days following surgery and may last up to 2 wk.
2. Encourage your child to communicate with you if he or she experiences significant throat pain, since pain may not always be expressed and therefore not recognized promptly.
3. Discuss strategies for pain control with your health care provider before and after surgery; realize that antibiotics after surgery do not reduce pain and should not be given routinely for this purpose.
4. Make sure your child drinks plenty of fluids after surgery. Staying well hydrated is associated with less pain.
5. Ibuprofen can be used safely for pain control after surgery.
6. Pain medicine should be given as directed by your health care provider. Especially for the first few days following surgery, it should be given often.
7. Many clinicians recommend not waiting until your child complains of pain. Instead, the pain medication should be given on a regular schedule.
8. Expect your child to complain more about pain in the mornings—this is normal.
9. Rectal administration may be given if your child refuses to take pain medication orally. Call your health care provider if you are unable to adequately control your child's pain.



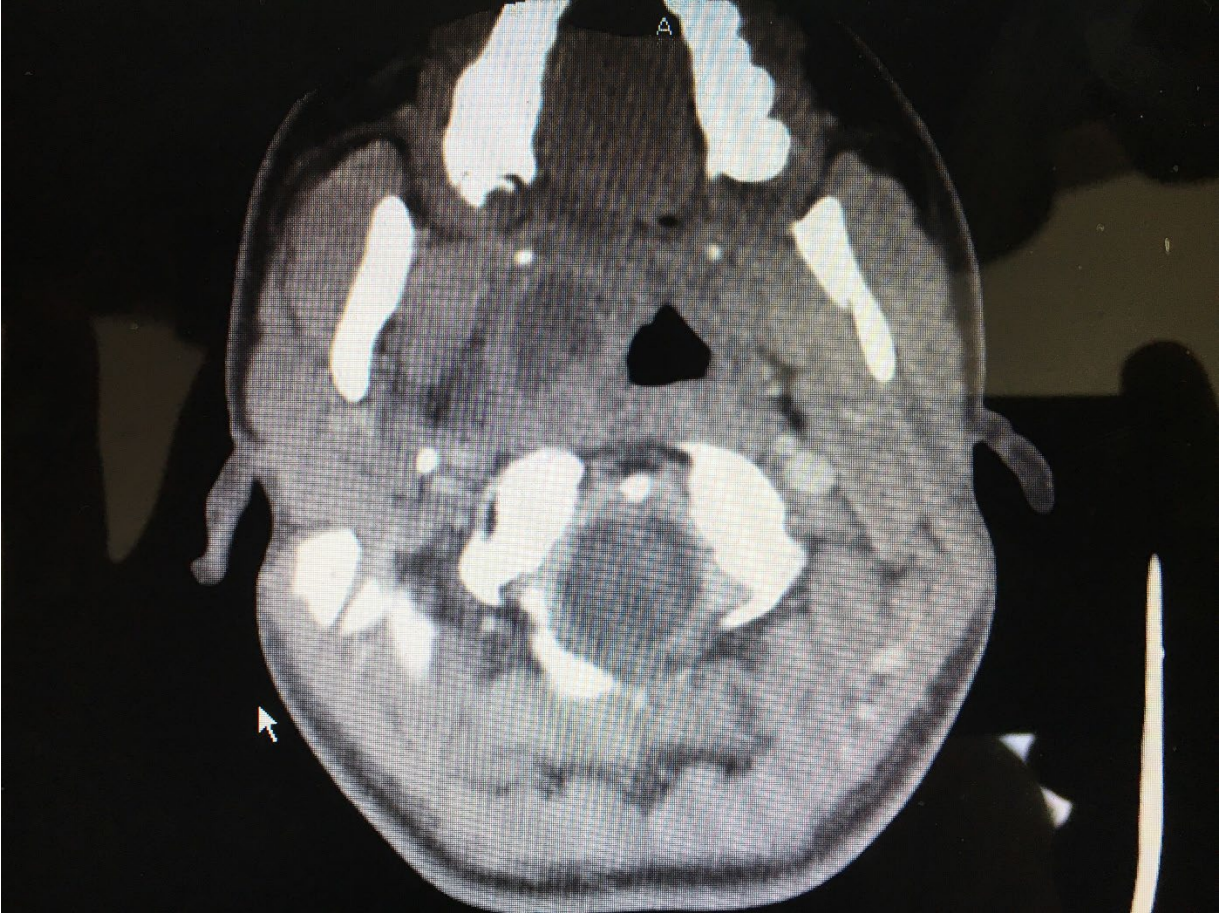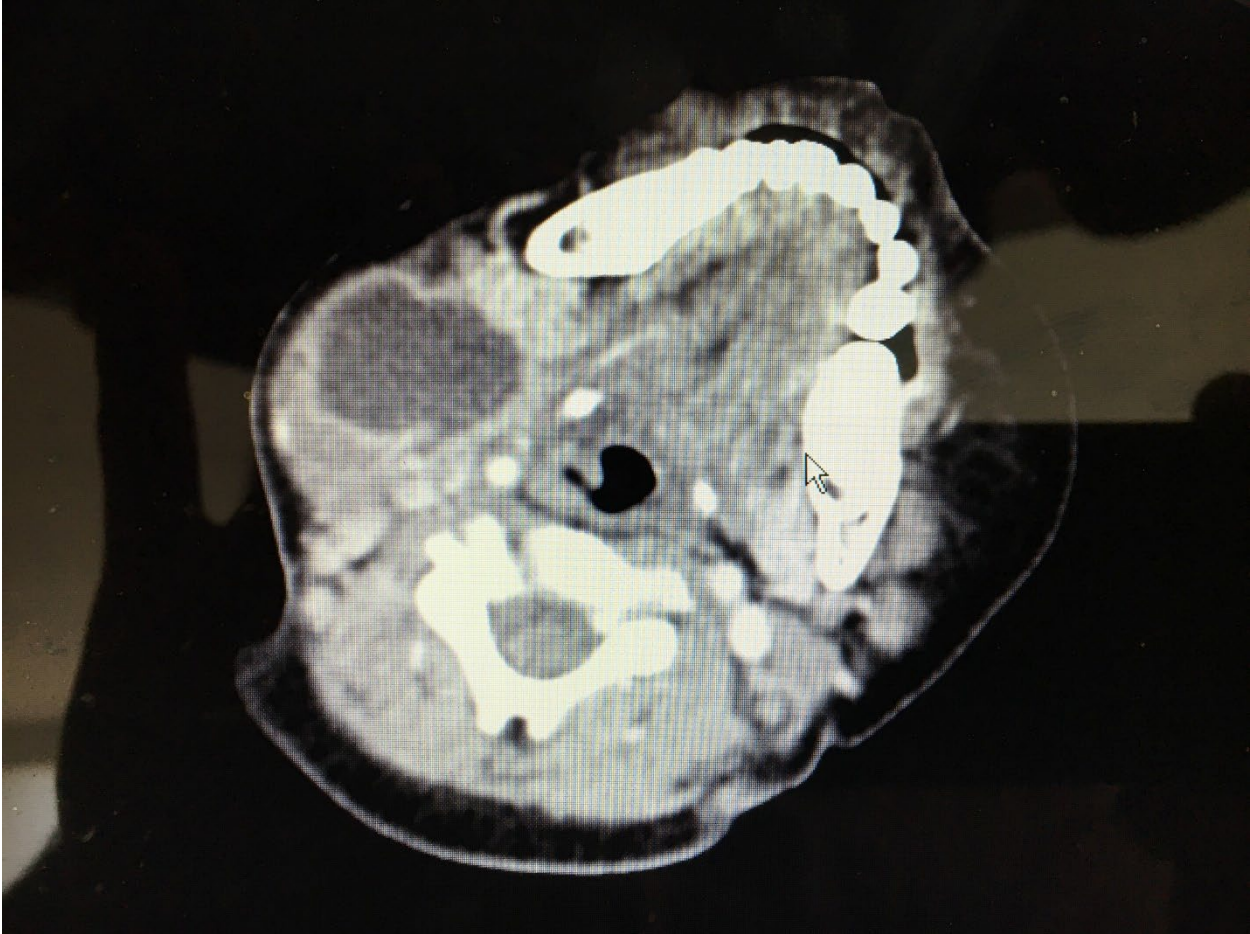
VS



- No clear guidelines for other surgeries – surgeon’s prerogative
- Particular caution for:
  - Sinus surgery
  - Thyroidectomy
  - Tonsillectomy



# Appropriate use of CT




A monarch butterfly with orange and black wings is perched on the tip of a child's hand. The background is a light blue square.

image  
gently®

## The Image Gently Alliance

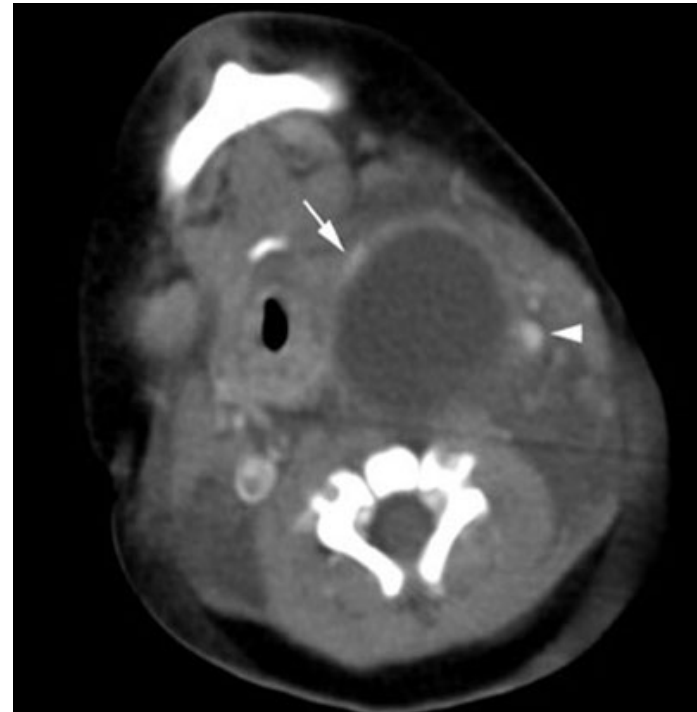
- Children are more sensitive to radiation.
- What we do now lasts their lifetimes.
- So when we image, let's image gently: more is often not better.

([imagegently.org](http://imagegently.org))

# When CT is the right thing to do:

- Child size the dose
- One scan (single phase) is often enough
- Scan only the indicated area.

(imagegently.org)



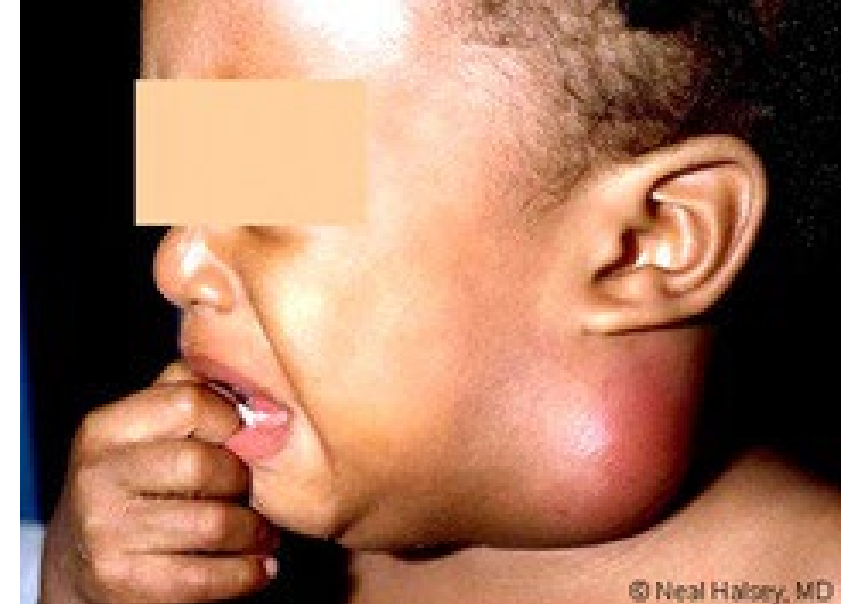# When is it the right thing to do?

- Evaluate complications of acute otitis media:
  - Mastoiditis
  - Sigmoid sinus thrombosis
  - Subperiosteal abscess
- Evaluate complications of sinusitis:
  - Orbital cellulitis/abscess
- Suspicion for retropharyngeal abscess
- Neck abscess (if diagnosis is unclear or anatomic localization needed)



# When is CT usually not indicated?

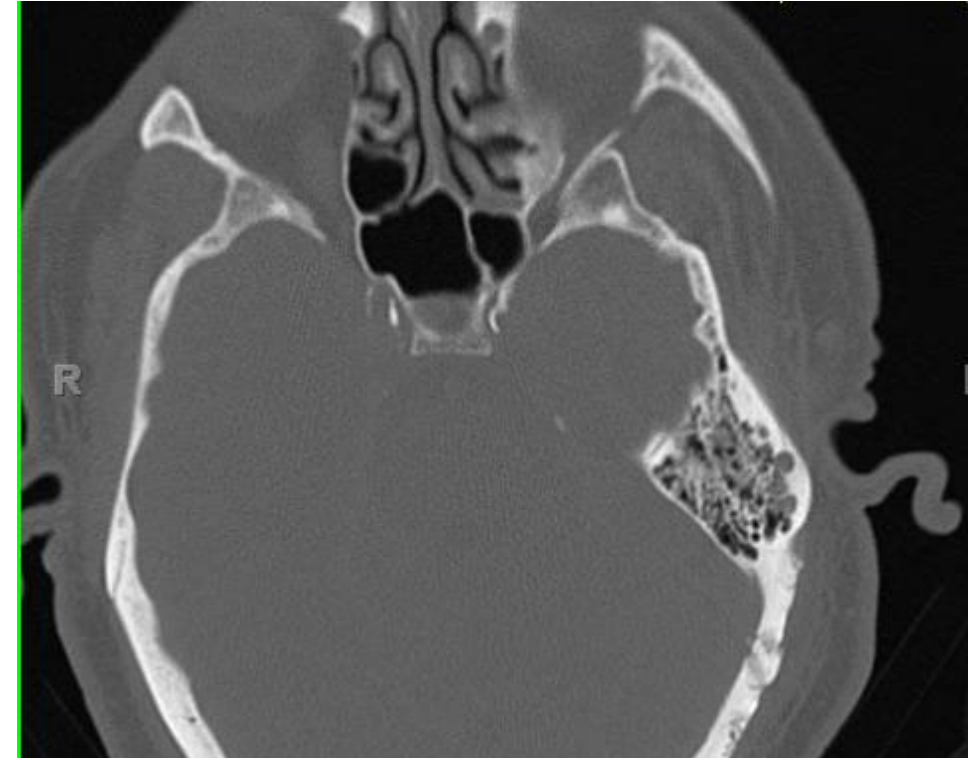- Peritonsillar abscess
- Acute sinusitis without complications
- Acute otitis media (or even mastoiditis) without complications
- Pointing neck abscess



© Neal Halsey, MD

# Acute Mastoiditis

- The most common complication of AOM
- Typically develops less than 10 days after onset of AOM
- 50% of patients <2yo
- 50-75% without antecedent AOM
- Higher rate in countries where abx are not prescribed for AOM



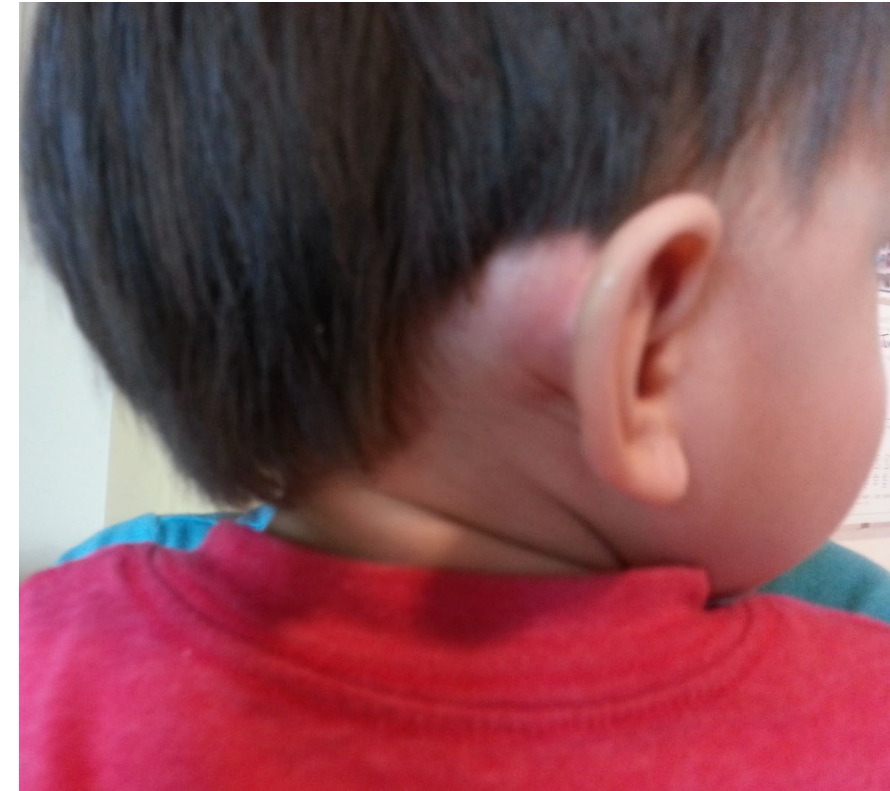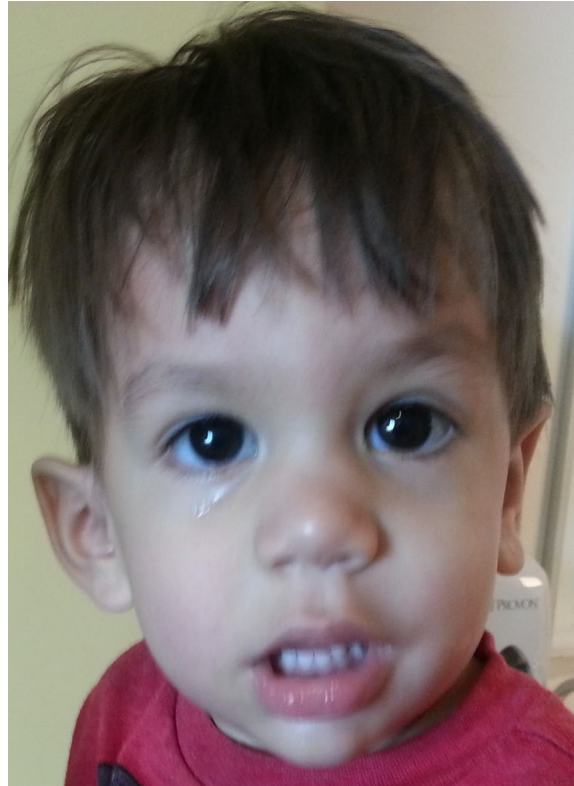Acute mastoiditis vs acute coalescent mastoiditis with or without subperiosteal abscess

# DIAGNOSIS



# Diagnosis – clinical features

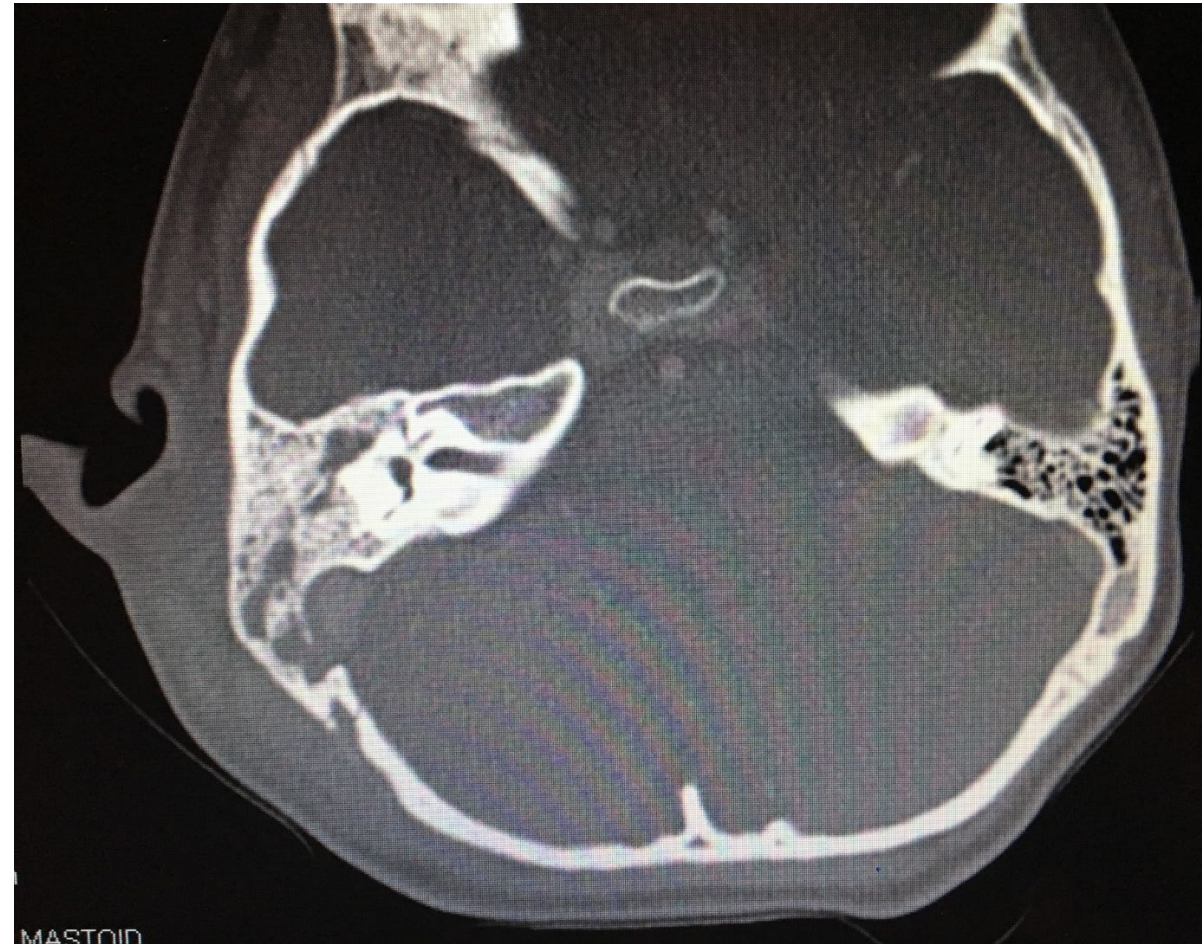- Fever, irritability,
- Protrusion of the pinna – “down and out”
- Postauricular edema/erythema
- Tenderness to palpation
- Sagging of posterosuperior canal skin
- AOM if TM is visible





# Diagnosis - radiology

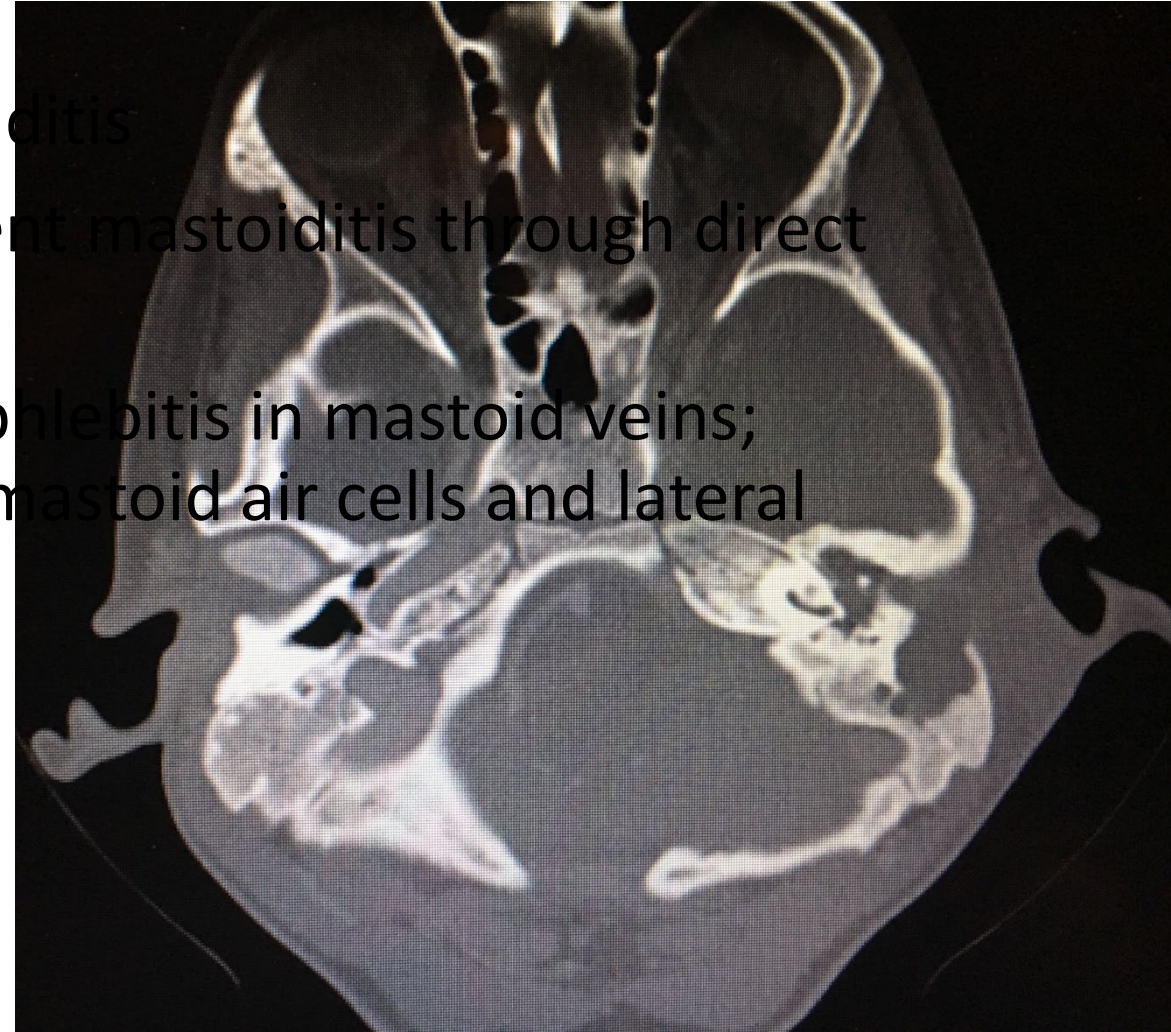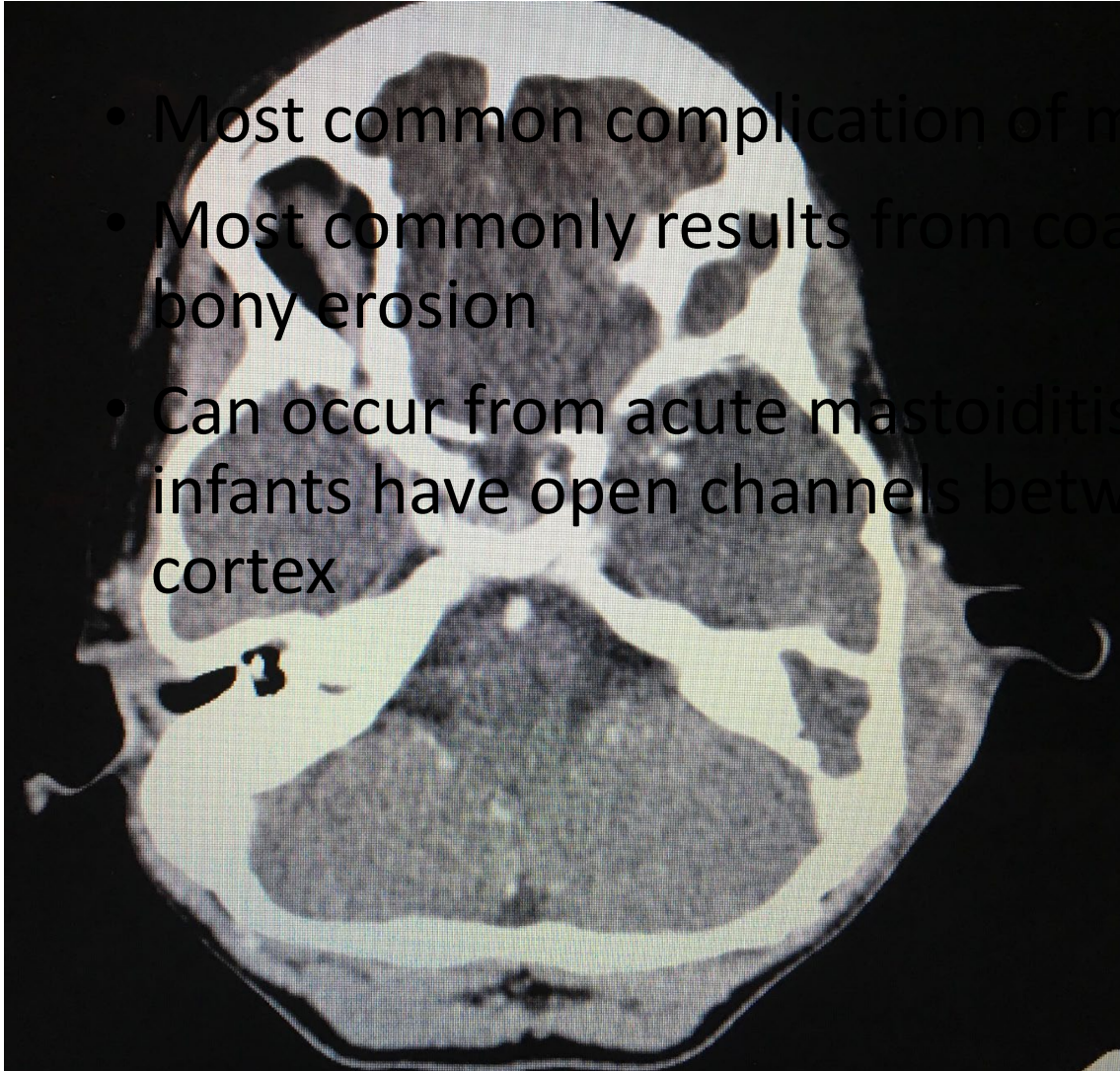
- NOT JUST OPACIFIED AIR CELLS!



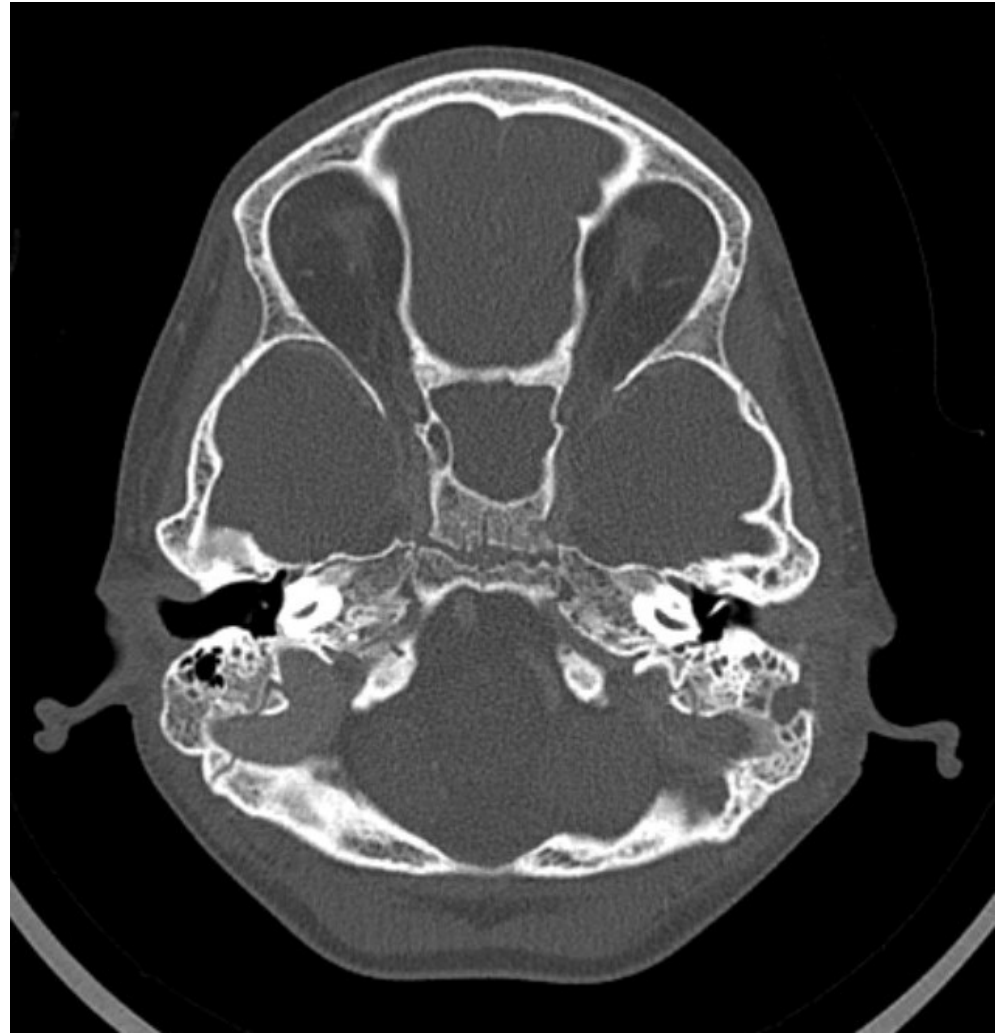
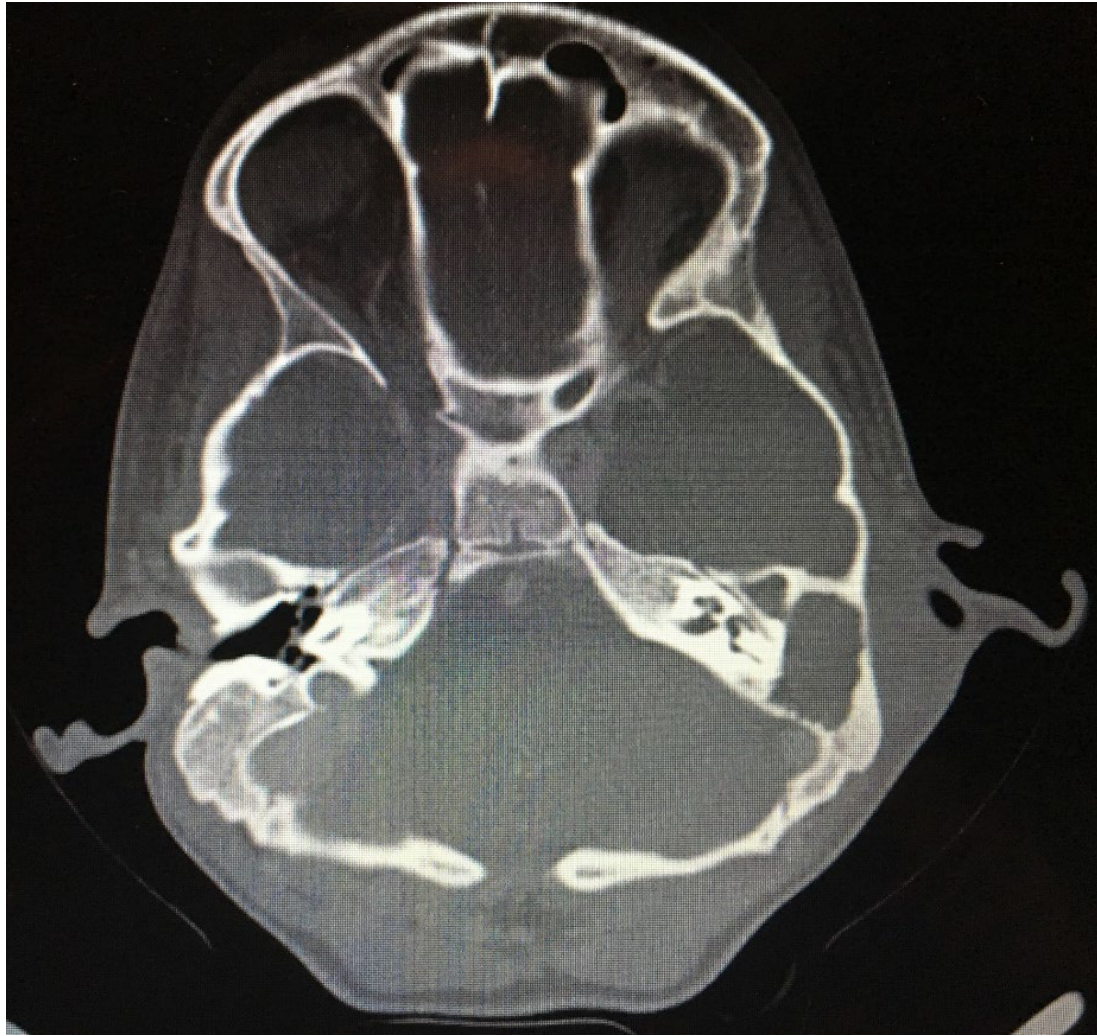

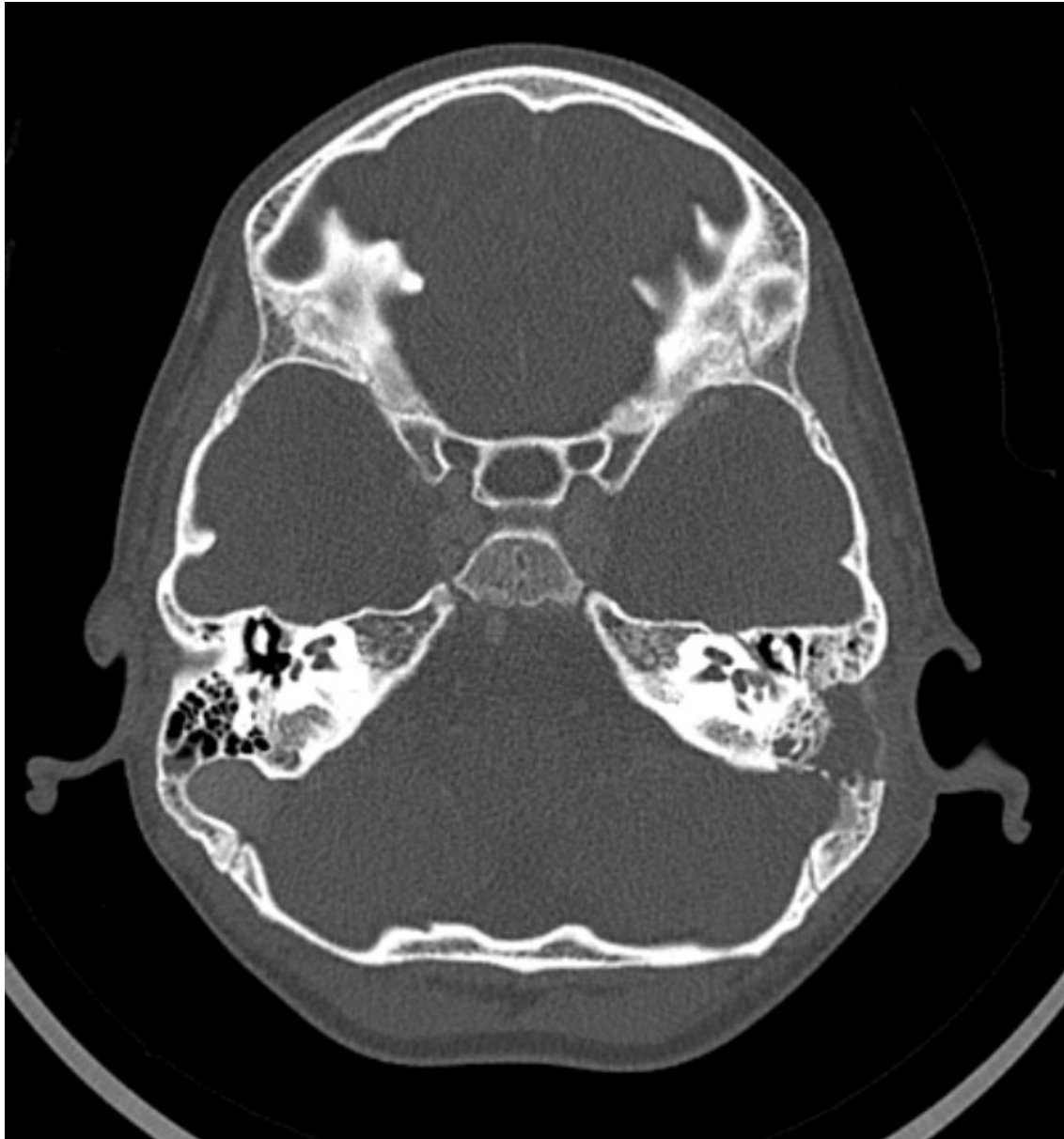
# Acute Coalescent mastoiditis with subperiosteal abscess

- Most common complication of mastoiditis
- Most commonly results from coalescent mastoiditis through direct bony erosion
- Can occur from acute mastoiditis via phlebitis in mastoid veins; infants have open channels between mastoid air cells and lateral cortex











# Treatment

- IV abx – Typical flora of AOM
- Surgery – tube placement, I&D, possible mastoidectomy

“The most important of these natural remedies can be had free of cost in any home. They are Air, Fasting, Water and the right Mental Attitude.”

Henry Lindlahr, Nature Cure: Philosophy and Practice Based on the Unity of Disease and Cure,  
1913

# Orbital cellulitis/Abscess

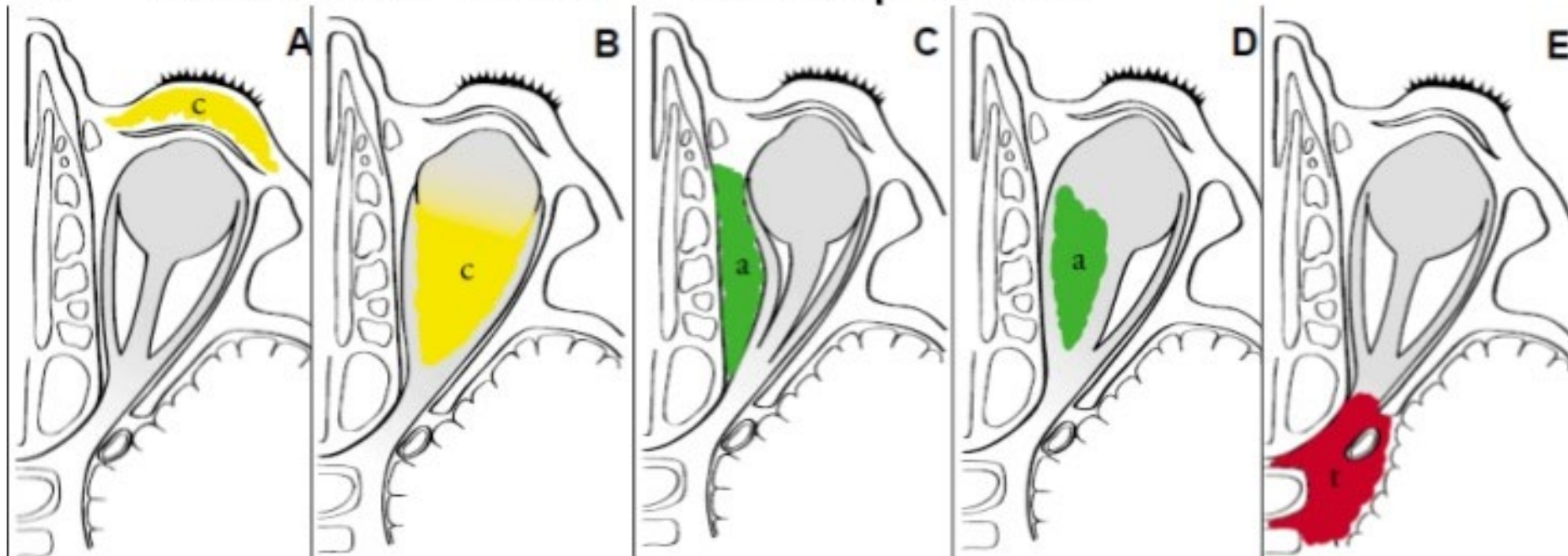
- Chandler classification – based on imaging
  - Type 1 – Preseptal cellulitis
  - Type 2 – Postseptal cellulitis
  - Type 3 – Subperiosteal abscess
  - Type 4 – Orbital abscess
  - Type 5 – Cavernous sinus thrombophlebitis

# Orbital Complications Of Sinusitis

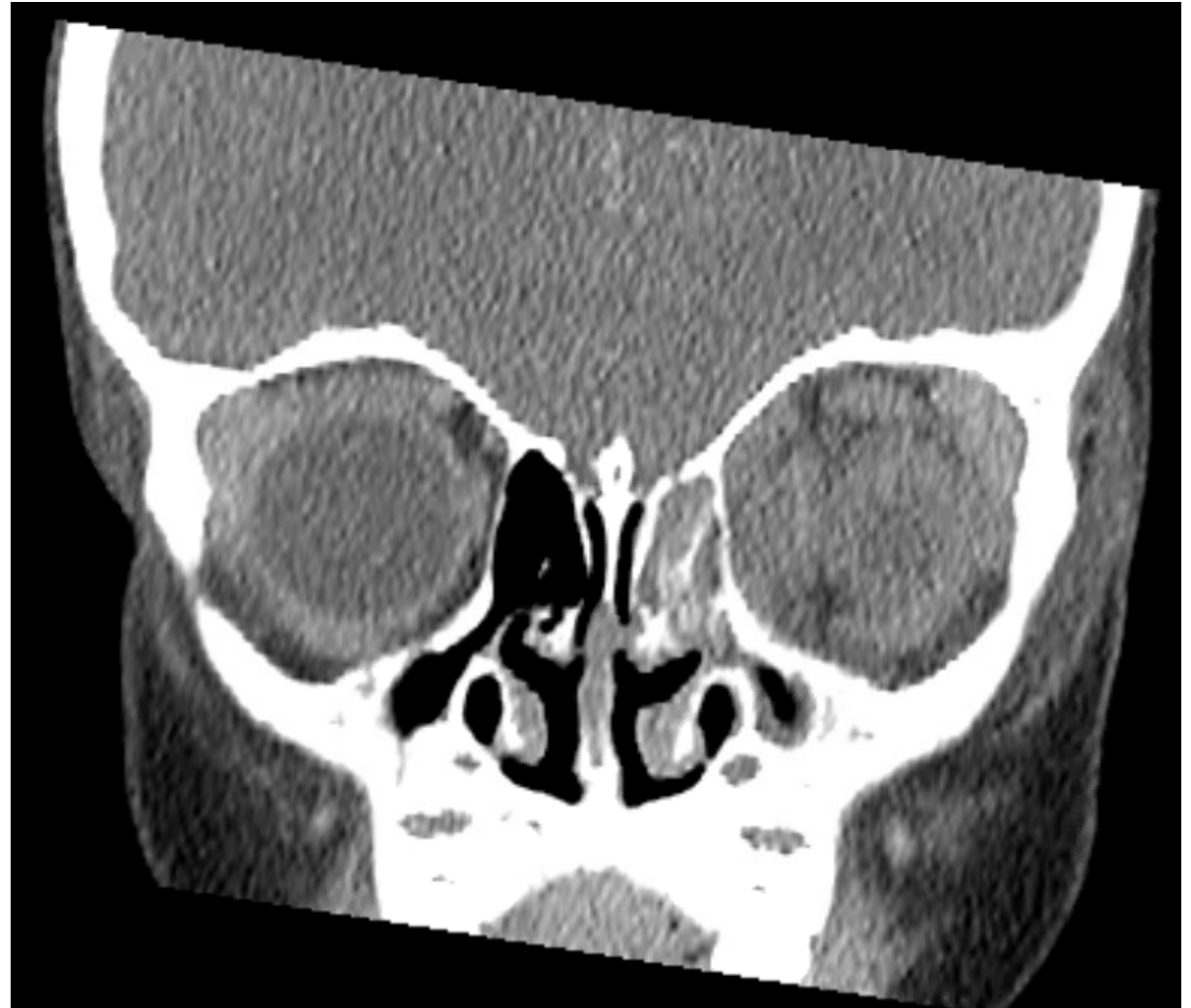## Classification



1. Periorbital (Pre-Septal) cellulitis
2. Orbital (Post-Septal) cellulitis
3. Subperiosteal Abscess
4. Orbital abscess
5. Cavernous Sinus Thrombophlebitis



- ENT
- Ophthalmology
- Infectious Disease
- Hospitalist

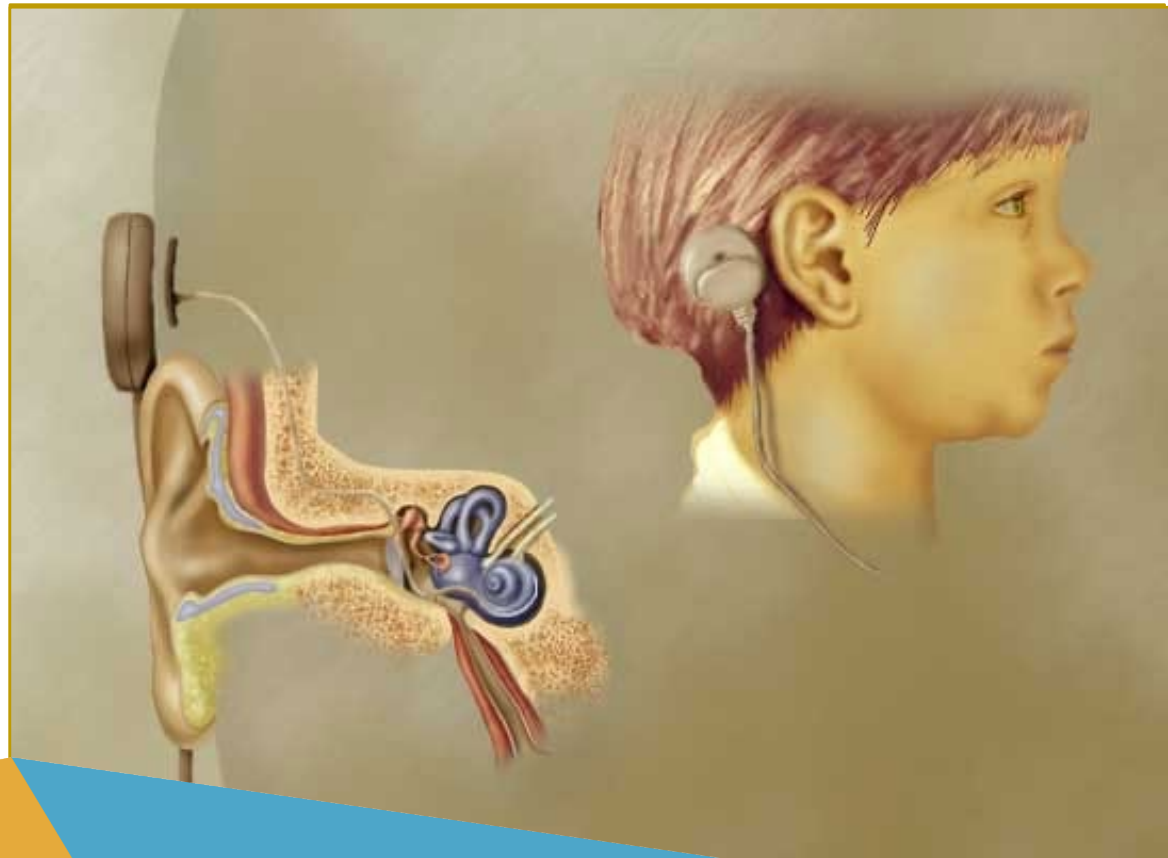

# Cochlear Implant Concerns

- Imaging
- Infection
- Using processors

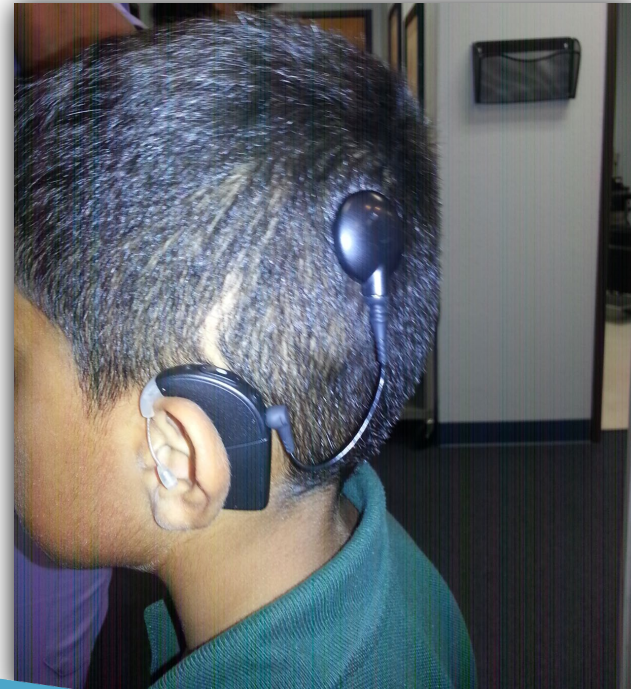# Cochlear Implants

- Transmits sound directly to the auditory nerve through electrical stimulation of the cochlea



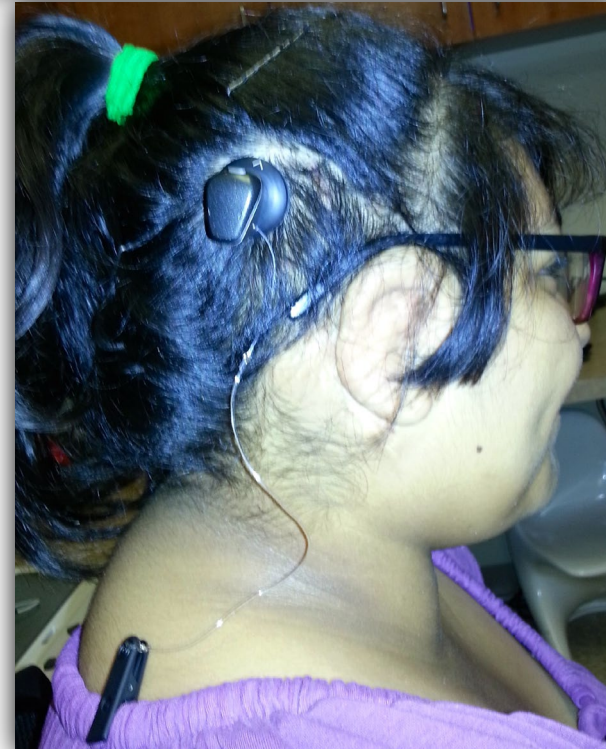
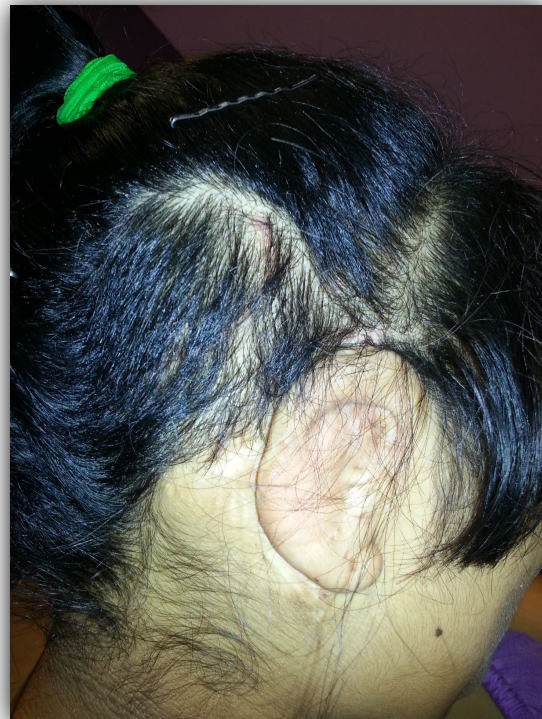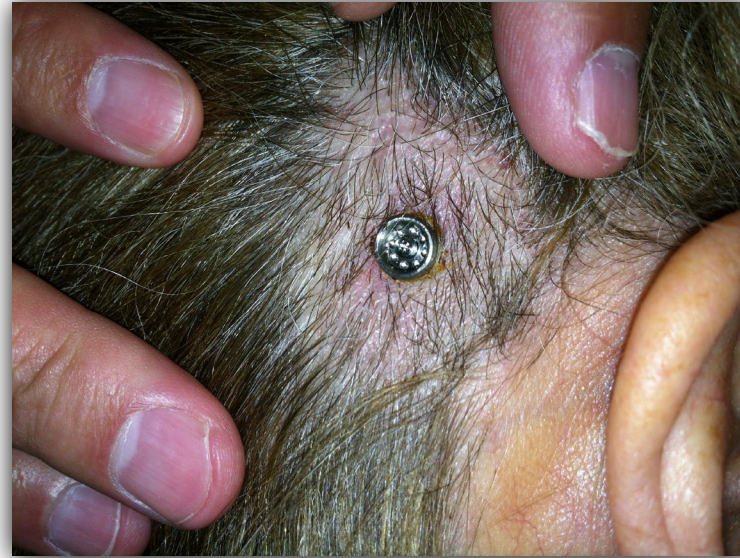# Cochlear Implants

- FDA: > 1yo
- Hearing aid trial: Minimum of 3-6 months
- Candidates are evaluated by a cochlear implant team
- Long-term speech/audiological therapy and mapping
- Potential for oral communication





# Bone anchored hearing aid vs cochlear implant





# MRI with Cochlear Implants

Safety – displacement of magnet, soft tissue injury

Image Quality – artifact 5-8cm around magnet

Patient discomfort – pain during MRI

MRIs can range in strength from 0.2 T to 7.0 T, with 1.5 T being the most common.



Only 1 in 10 Americans has had an MRI.<sup>2</sup>



97% of radiology professionals surveyed do not recommend conducting MRI scans on patients with magnets in their bodies.<sup>5</sup>



92% of radiologists surveyed would prefer to have magnets removed before an MRI.<sup>5</sup>



# MRI

## Cochlear

New generation

- Safe up to 3T

Last generation

- Safe for 1.5T MRI with bandaging
- Safe for 3T with magnet removed

## Advanced Bionics

New generation

- Safe up to 3T

Last generation

- Safe for 1.5T MRI with bandaging
- Safe for 3T with magnet removed

## Med El

Last two generations

- Compatible with 3T MRI without removal of magnet (Self-aligning magnet)

# MRI

- Magnet removal is very rare
- Other imaging modalities can often be used

# Infections with cochlear implants

- Surgical site infection
  - Rare
  - Within 1-2 weeks of surgery
  - Contact surgeon immediately
  - Likely admission for IV abx, possible I&D
- Acute otitis media
  - Most common age group overlaps heavily with CI patients
  - Oral abx – usual coverage