APPROACH TO PENETRATING CHEST TRAUMA

EMET

Foundations of Respiratory Management

INTERACTIVE SESSION

Learning Outcome

- You will be able to explain an approach to penetrating chest trauma

Resuscitative Thoracotomy

When to do it
Why to do it
How to do it
Is it the first stage of an autopsy?

Background

Thoracic trauma accounts for 25-50% of all traumatic injuries

90% of thoracic trauma can be managed non operatively (+/- chest tube insertion)

10% of thoracic trauma victims will require thoracotomy

- Injuries sustained from chest trauma result in:
- Hypoxia
- Reduced Cardiac Output

Definition

- ED Thoracotomy
- Emergent Thoracotomy
- Early Thoracotomy
- Resuscitative Thoracotomy
  - Undertaken at any stage of the resuscitative process and so can be defined in terms of the urgency of the procedure in relation to the patients physiological status
  - i.e. Occurring at the site of injury, in the ED or in the OT as an integral part of the initial resus

- Urgent Thoracotomy
  - Takes place in the context of physiological stability and hitherto successful resuscitation.
- Elective Thoracotomy
  - E.g. For CABG

- Controversy still surrounds the indications for the procedure – esp in blunt trauma.

- Survival rates after emergency thoracotomy
  - Penetrating trauma :9-12% (some say as high as 38%!!!)
  - Blunt trauma :1-2%

PATIENT PRESENTATION IN EXTREMIS FOLLOWING THORACIC TRAUMA

SIGNS OF LIFE ?

NO

PREDICTORS OF POOR OUTCOME

Blunt trauma mechanism e.g. RTA

Pre-hospital CPR longer than 5 min

Associated severe head injury +/- multisystem trauma

INDICATION FOR EMERGENCY THORACOTOMY

Penetrating thoracic trauma with definite signs of life at scene

YES

INDICATIONS FOR EMERGENCY THORACOTOMY

Severe hypotension (Class II/ III shock*) with evidence of:

Intrathoracic haemorrhage
Pericardial tamponade
Systemic air embolism
Severe extrathoracic haemorrhage

SIGNS OF LIFE:

Electrical activity on ECG (with or without pulse)

Evidence of pupillary, corneal or gag reflexes

GCS > 3

Consider urgent thoracotomy in theatre if patient stable following resuscitation (Class IV shock*)

** Table 5. Classification of physiological status. Note: absence of signs of life = Class I*

Class II	Class III	Class IV
Any ECG electrical activity without palpable pulse or measurable blood pressure	SBP < 60 mmHg Transient response or unresponsive to fluid resuscitation	SBP 60 - 90 mmHg Stable response to fluid resuscitation

When to do it

- Penetrating Trauma
  - Signs of life
    - Reacting pupils
    - Gag reflex
    - ECG rhythm (i.e. PEA)
    - Echo showing some heart motion
- Blunt Trauma (controversial)
  - Patient dies right in front of you
  - (Ultrasound may aid your decision)

When NOT to do it

- Definite loss of cardiac output for greater than 10 mins (this time frame is variable)
- Any patient who has a cardiac output including hypotensive patients
- Blunt trauma with no output
- Obvious Non - survivable injuries
- No knowledge of procedure
- No way of getting patient to definitive care

Why to do it

- Decompression of Cardiac Tamponade
- Control of haemorrhage
- Internal CPR

Why to do it

- Decompression of Cardiac Tamponade
- Control of Haemorrhage
- CPR

- Opportunity for practice is extremely unlikely
- The fist time you do this will be for real!!

How to do it

- Emergency Clam Shell Technique
  - Straight forward for emergency physicians
  - Exposes thoracic structures in a way that is easy to recognise
  - Intuitive approach in setting of chest trauma
  - Not the only way.....



Area / Staff / Equipment

In Resus of ED or operating theatre

Staff must include someone who is willing to do procedure

Thoracotomy Tray

- Split staff into 2 teams – one to do procedure and one to continue all other aspects of the resuscitation of the patient (i.e. Intubation, ventilation, iv access – do not delay thorocotomy)

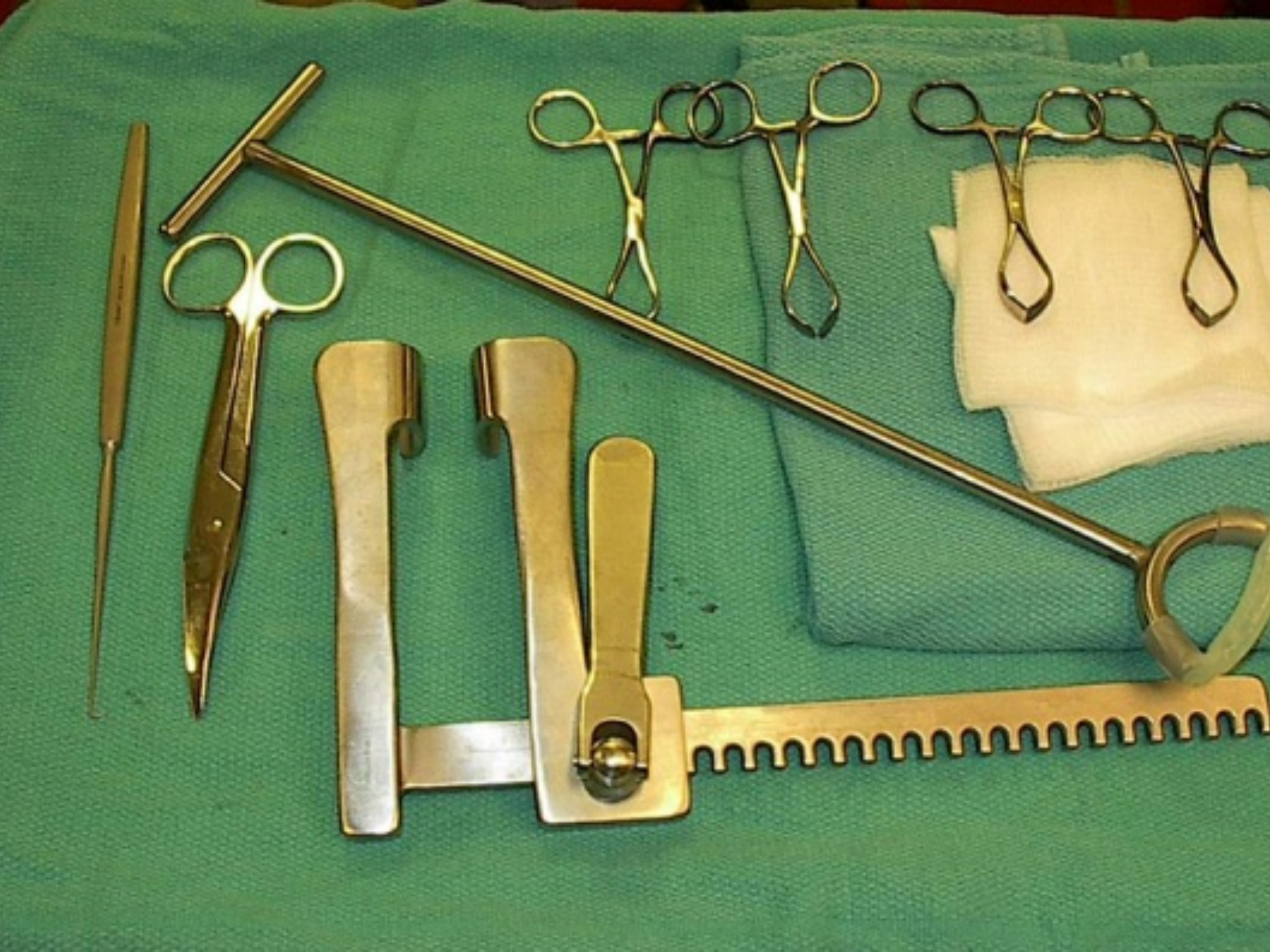

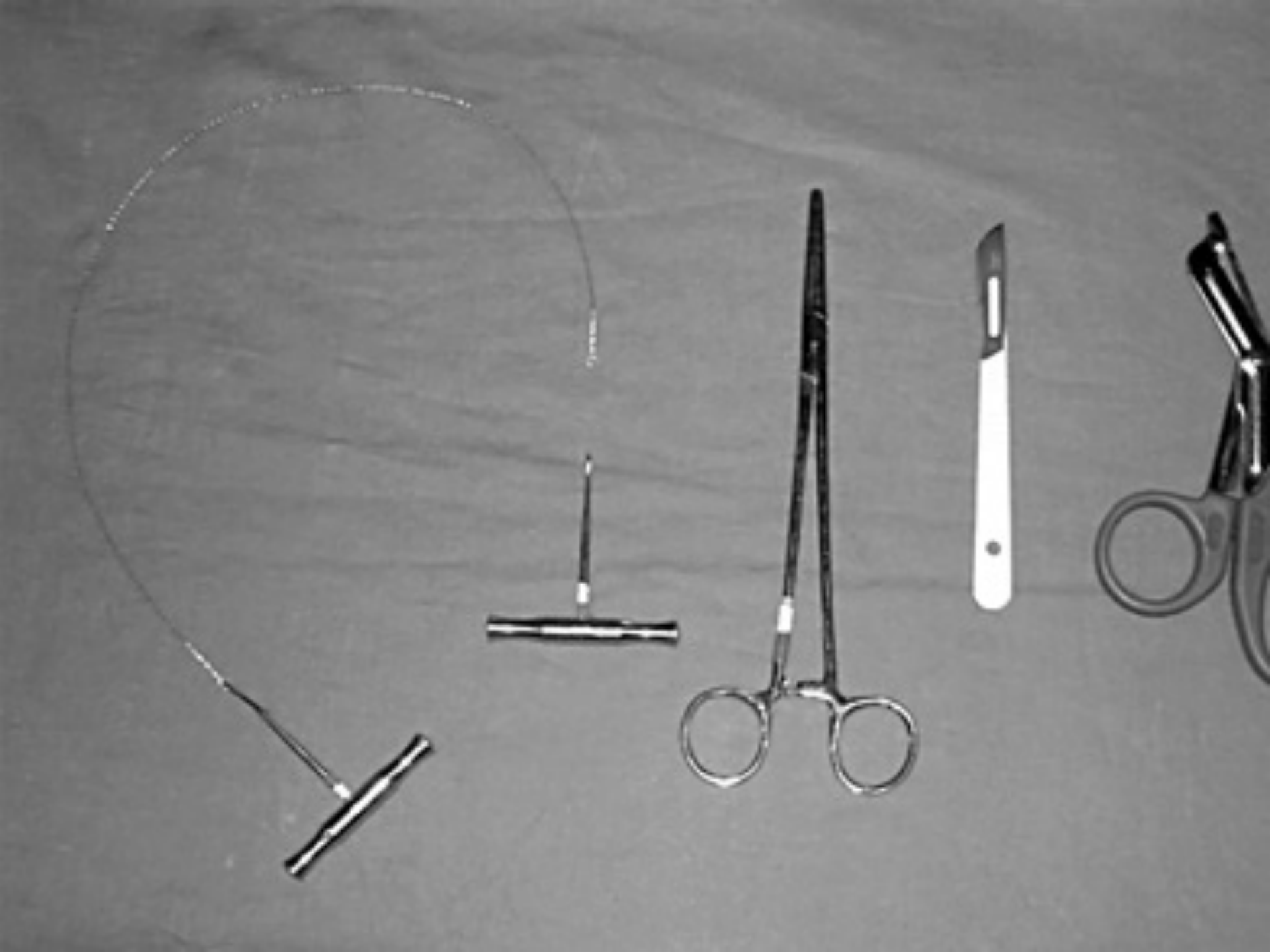

- “Baptise in Betadine”
  - Do not waste time with prep and drapes, this is not a sterile procedure

- Fist step is to make bilateral 4cm thoracostomies
  - Same position and technique as chest drain insertion
  - (At this stage if you happen to decompress a tension pneumothorax and get ROSC then procedure can be stopped



- Connect the two thorocostomies with a deep skin inscision following the 5th interconstal space.



- Insert two fingers into one of the thorocostomies to hold the lung away whist cutting through all layers of the intercostal muscles and pleura towards the sternum using the heavy scissors. Do this on both sides

- Then cut through the sternum or xiphoid process using this scissors. If this is not possible use the Gigli saw

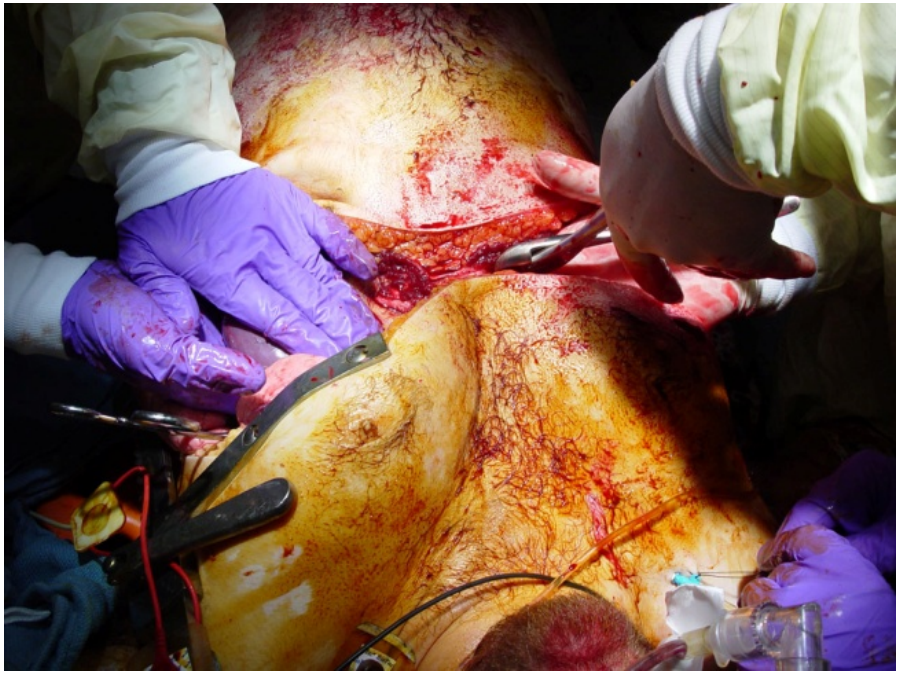

- Open the “calm shell”using retractors or rib spreaders. If not available x2 gloved assistants can hold the incision open manually

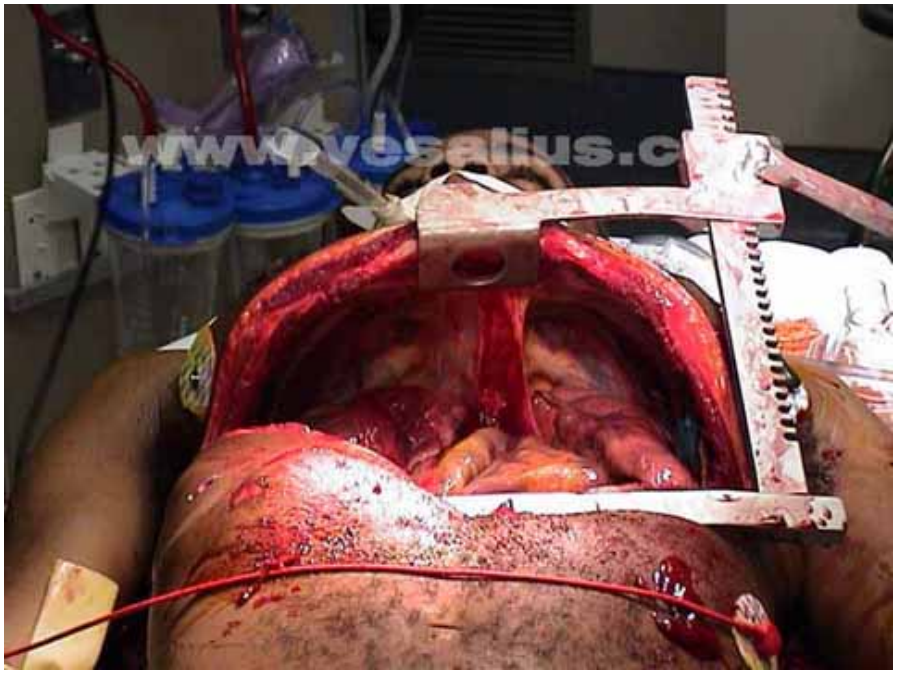

- If exposure is inadequate extend the incision posteriorly on both sides

- Lift the pericardium with clamp or forceps and make a large longitudinal midline incision using the scissors.

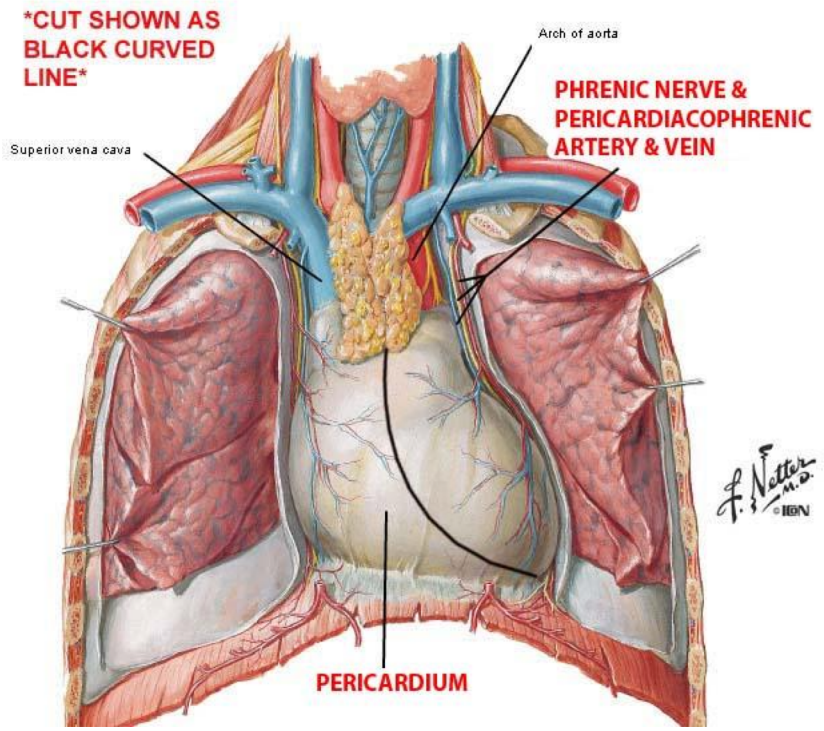

- Remember the phrenic nerves run in the lateral walls of the pericardium

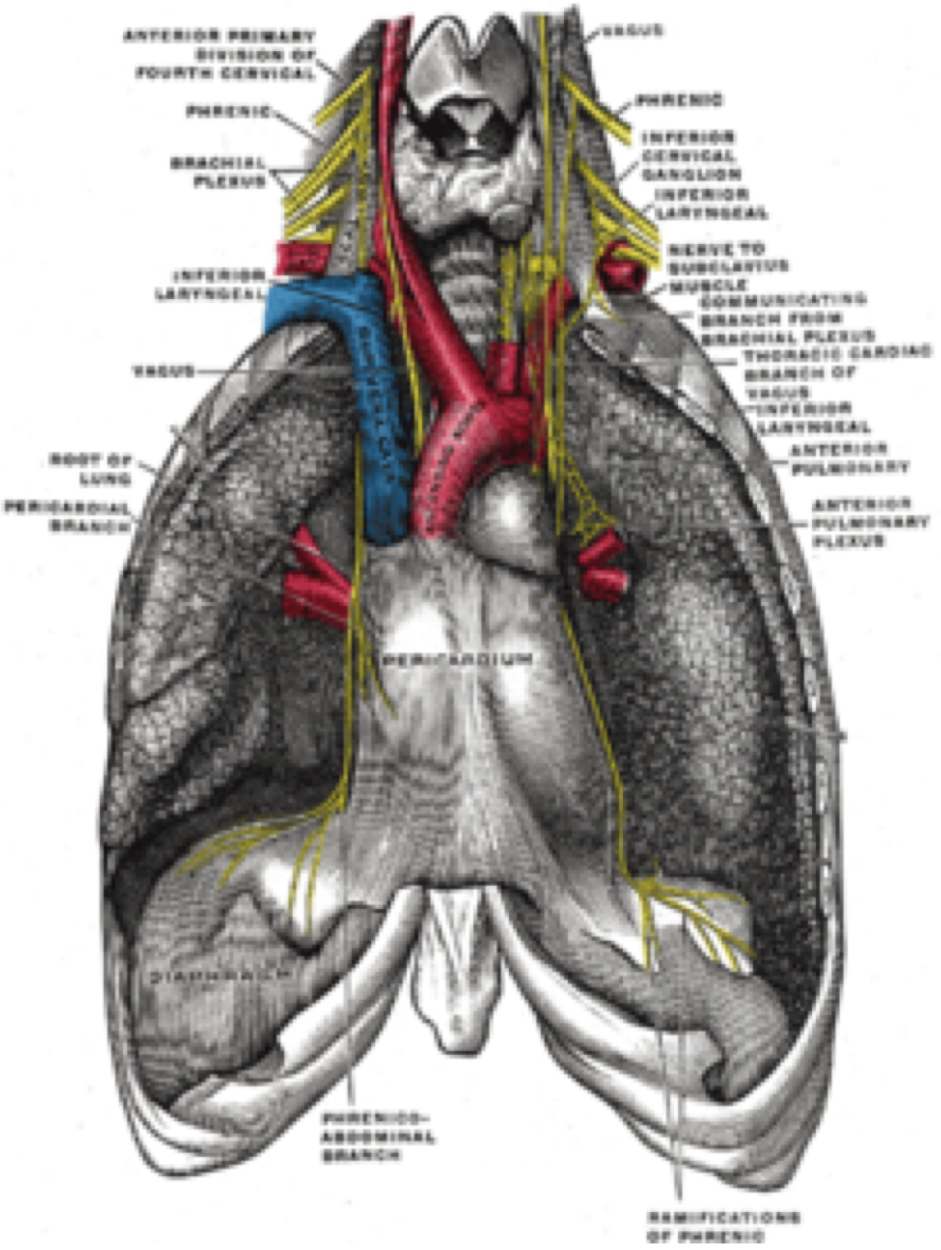

- Evacuate all blood and clot present and then inspect the heart for site(s) of bleeding

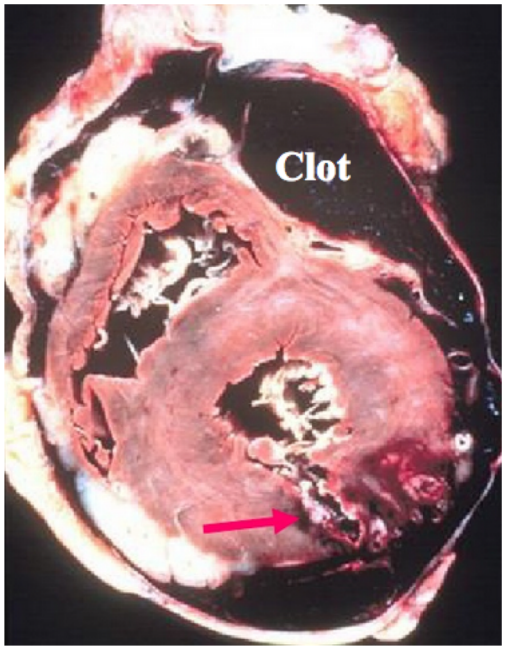

- Remember there may be more than one site of bleeding



- At this point either....
- The heart will start beating with a normal cardiac output



- The heart will start beating with a reduced cardiac output



- The heart will not start beating



- Control of bleeding sites
  - Small defects – use finger or gauze swab
  - Large defects – a urinary catheter can be passed through the defect, inflated and the gently pulled back
  - ONLY if above methods fail should suturing defects be attempted. High chance of occluding a coronary artery. Large suture, take big bites.

- CPR
  - Two handed technique
  - One hand applied to the posterior aspect straight fingers, apex in the palm.
  - Second hand milks blood from the apex upwards at 80bpm.
  - Assistant could be used to press descending aorta against the spinal column with finger or thumb improving coronary artery perfusion
  - Keep heart horizontal so as not to impair venous filling

- Internal cardiac defibrillation – 10j
- Close over incision and perform external defibrillation

Why not do a pericardiocentesis?

- Needle pericardiocentesis shown to be ineffective due to presence of extensive clot in the pericardial sac

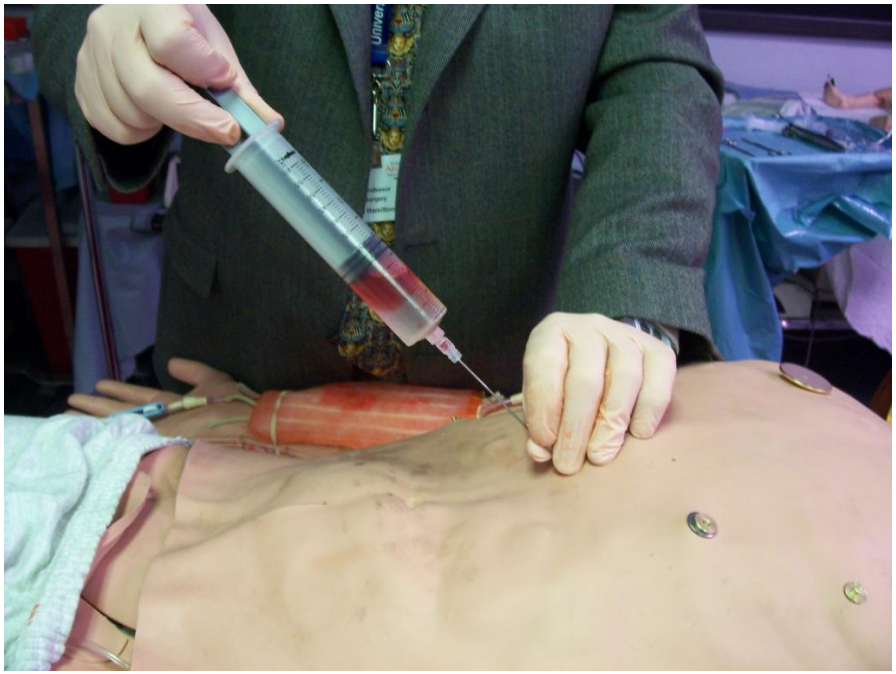

- Delays definitive intervention

- There is little evidence to support one technique of emergency thoracotomy over another

- Median sternotomy is the prefered approach by cardiothoracic surgeons
  - Can be performed rapidly (<2mins)
  - Complete access to the mediastinum and thoracic cavity
  - Requires the use of complex, unfamiliar equipment that is not available in the ED
  - Access to upper thoracic structures not relevant in the ED thoracotomy setting.



- Traditional left anterolateral thoracotomy has a number of disadvantages for the non-surgical doctor
  - Exposure of the heart is limited to the left side and with a side on view
  - Identification of structures is difficult
  - Identification of the site of bleeding more difficult



- Clam shell advantages
  - Provides excellent exposure of the heart and lower mediastinum
  - Provides access to both pleural cavities
  - Anatomy can be viewed from the front making orientation and identification easy.
  - Realistic way to access the pericardium in 2-3 mins
  - It is an extension of a familiar technique

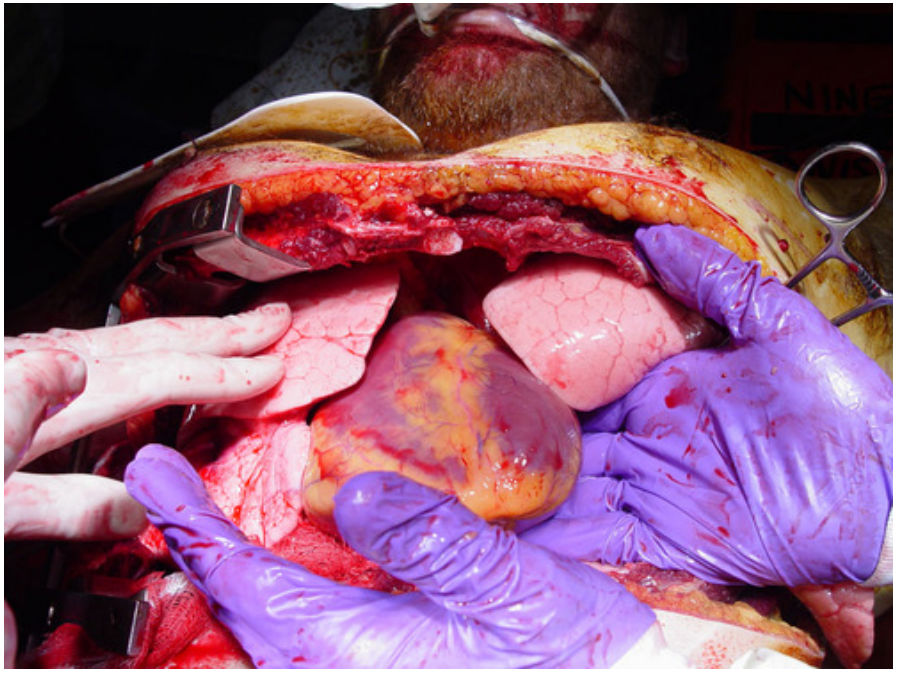



Vs

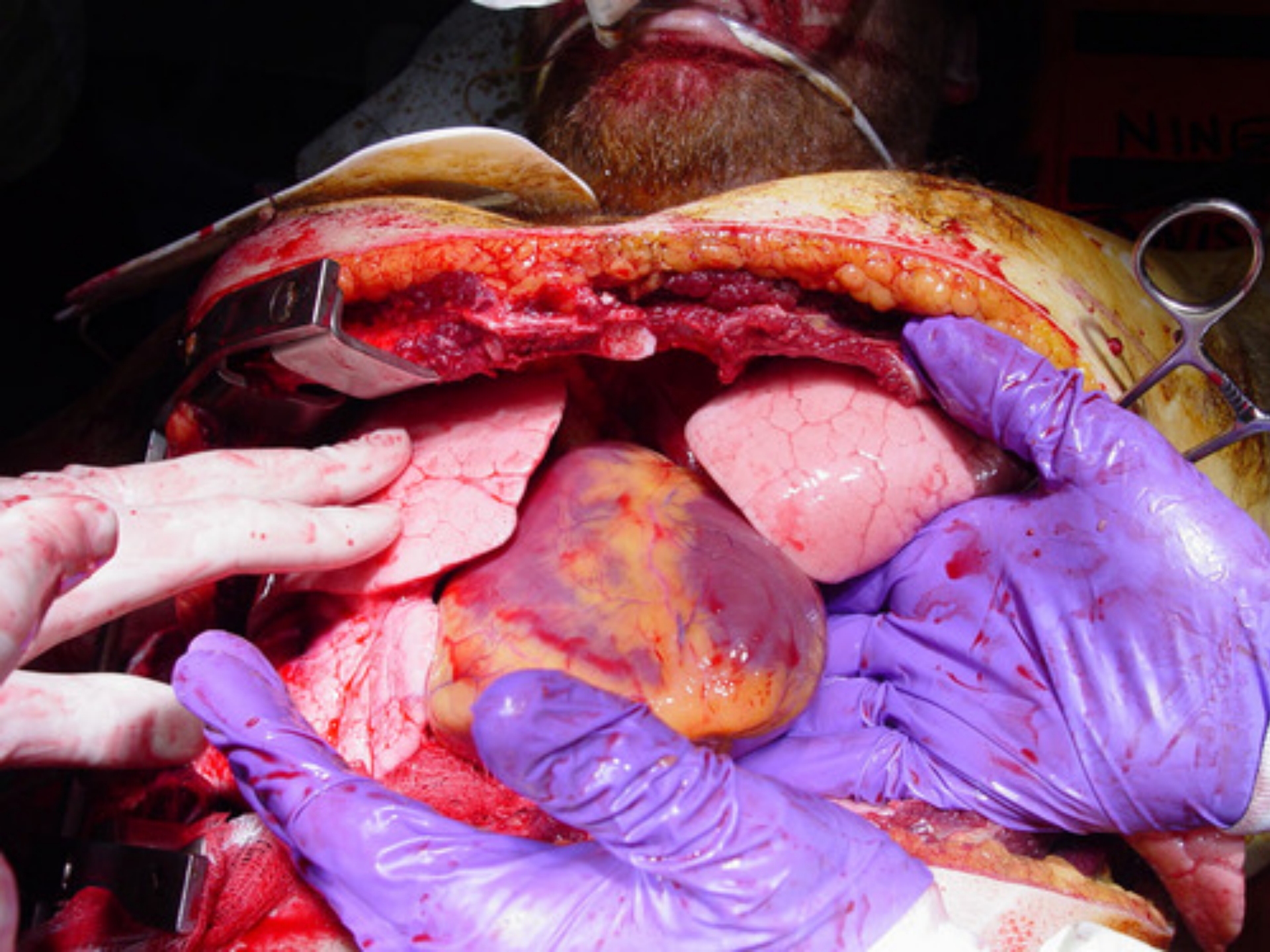

Summary

- Emergency Thoracotomy is very rare
- Blunt trauma poor
  - Controversial indication
  - Extremely poor survival rate
  - Only consider if cardiac arrest in front of you
- Penetrating Trauma
  - Signs of life and loss of output for no greater that 10 minutes

Summary (cont.)

- Emergency Clam Shell Technique
  - Finger thorocostomies will decompress a tension pneumothorax that has not been adequately treated
  - Familiarity with initial steps of this procedure
  - Maximum exposure in order to orientate yourself and identify sites of bleeding

END

References

- Weingart S – Emcrit podcast 36 and 83

- P A Hunt et al Emergency thoracotomy in thoracic trauma – a review Injury, Int. J. Care Injured (2006) 37, 1-19

- D Wise et al Emergency thoracotomy: how to do it Emerg Med J (2005) 22, 22-24

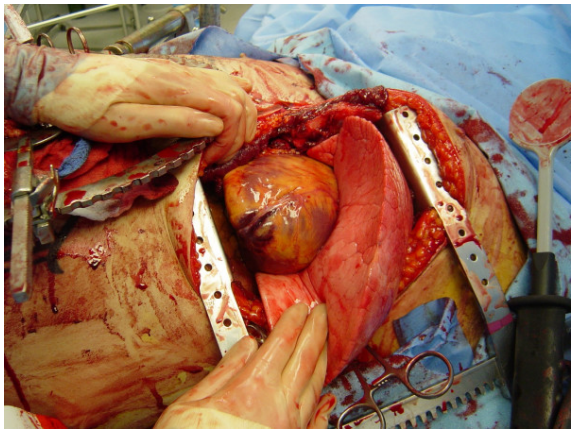

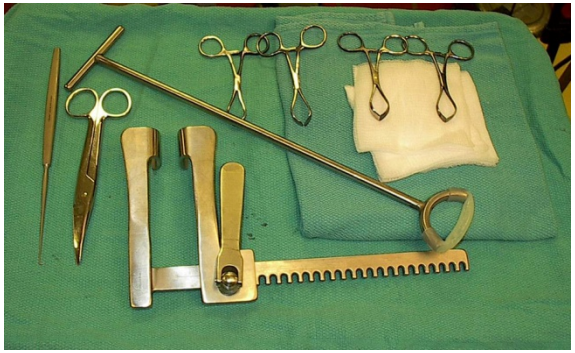

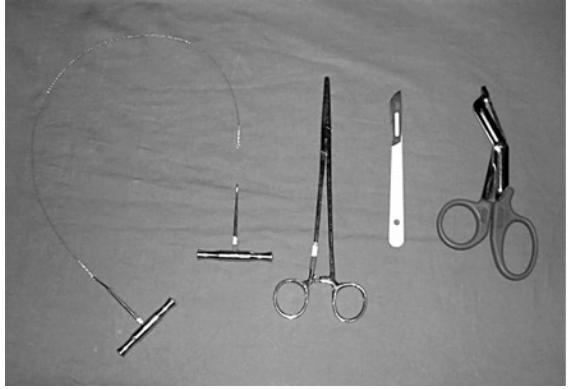

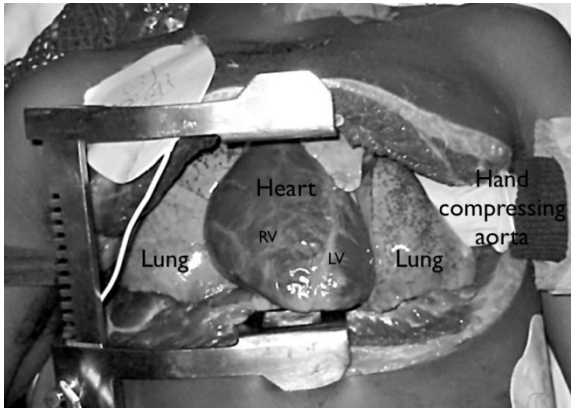

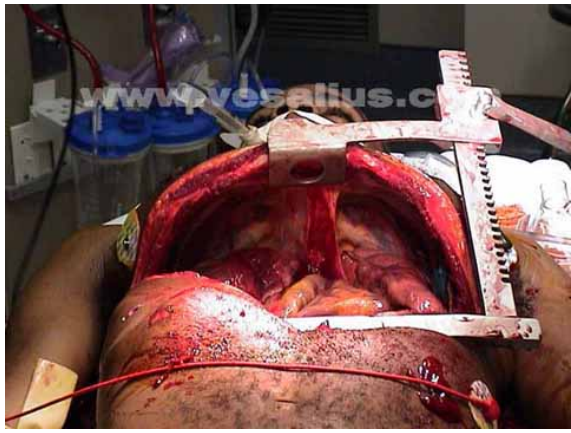

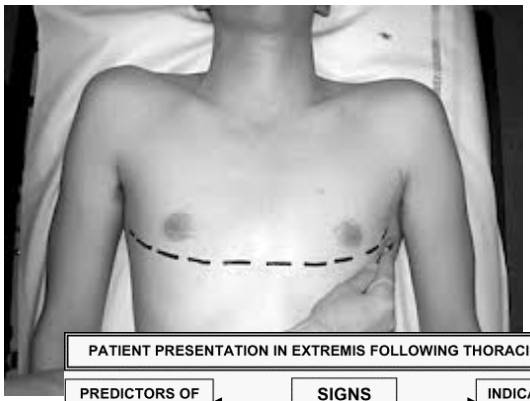





PATIENT PRESENTATION IN EXTREMIS FOLLOWING THORACIC TRAUMA

PREDICTORS OF POOR OUTCOME

Blunt trauma mechanism e.g. RTA

Pre-hospital CPR longer than 5 min

Associated severe head injury +/- multisystem trauma

INDICATION FOR EMERGENCY THORACOTOMY

Penetrating thoracic trauma with definite signs of life at scene

NO

SIGNS OF LIFE ?

YES

SIGNS OF LIFE:

Electrical activity on ECG (with or without pulse)

Evidence of pupillary, corneal or gag reflexes

GCS > 3

INDICATIONS FOR EMERGENCY THORACOTOMY

Severe hypotension (Class II/ III shock*) with evidence of:

Intrathoracic haemorrhage
Pericardial tamponade
Systemic air embolism
Severe extrathoracic haemorrhage

Consider urgent thoracotomy in theatre if patient stable following resuscitation (Class IV shock*)

** Table 5. Classification of physiological status. Note: absence of signs of life = Class I*

Class II	Class III	Class IV
Any ECG electrical activity without palpable pulse or measurable blood pressure	SBP < 60 mmHg Transient response or unresponsive to fluid resuscitation	SBP 60 - 90 mmHg Stable response to fluid resuscitation