Management of Pneumothorax

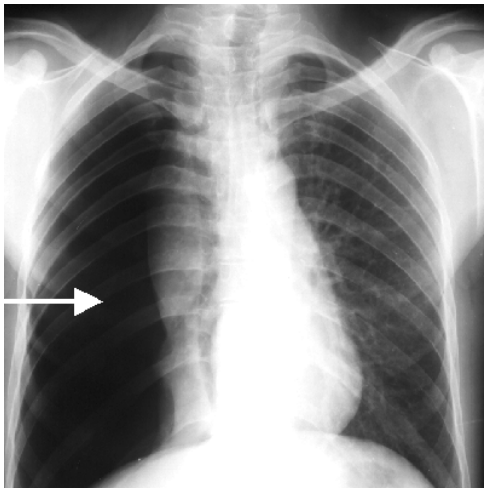

Calvary Hospital EMET

Foundations of Respiratory Management Lecture 2

Learning Outcomes

1. You will be able to list the different **classifications** of pneumothorax

2. You will be able to explain different **management options** of pneumothorax

3. You will be able to evaluate different **methods** of **chest drain insertion**

4. You will be able to evaluate different **methods** for **decompressive thoracostomy**

Classification of PTX

- Traumatic PTX
- Primary Spontaneous PTX (PSP)
  - Occurs in otherwise healthy individuals
  - Young men
  - No precipitating event
- Secondary Spontaneous PTX (SSP)
  - Underlying lung disease, eg. COPD, connective tissue disorder
  - No precipitating event

Resuscitation

- Apply high flow O2
  - 1. maintain/improve oxygen saturations
  - 2. increase the rate of PTX resolution
- Rule out tension
  - Significant SOB
  - Hypotension
  - Tachycardia
  - Confusion

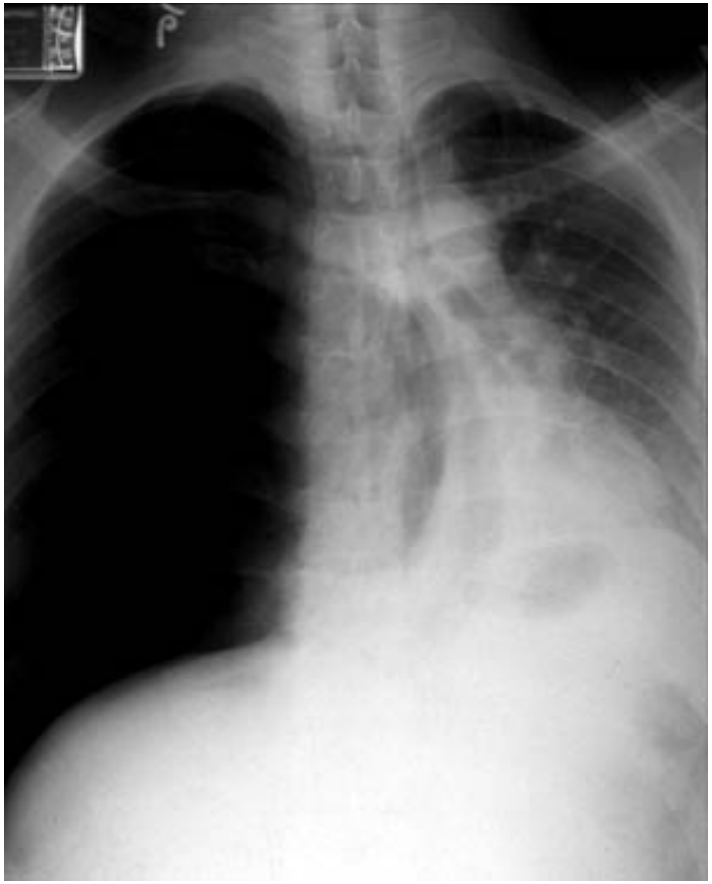

Measuring a PTX

- Size does not correlate well with symptoms
- Clinical picture more important when deciding management strategy
- CT scanning most accurate method not practical for all patients
- Erect PA CXR
  - USA guidelines (a) measures distance lung apex to cupola – may overestimate localised apical PTX
  - BTS guidelines (b)
  - 2cm rim at the level of the hilum indicates 50% PTX
  - <2cm = small
  - >2cm =large

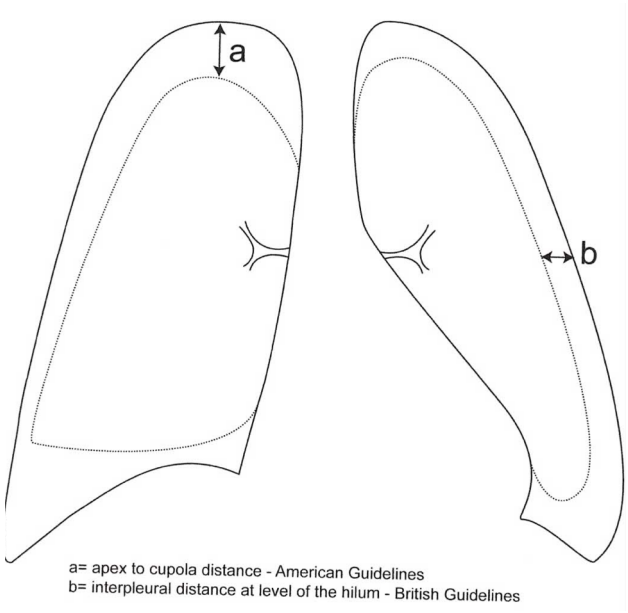

Ultrasound

- Most useful in the management of supine trauma patients
- Helpful in needle aspiration

Treatment Options

- Conservative – observation / watch and wait
- Needle Aspiration
- Seldinger (catheter over guide-wire) / Fine Bore Catheter
- Traditional / Large Bore ICC

Conservative

- Small PSPs where patients are not breathless can be managed safely as outpatients
- 80% small PSPs have no persistent air leak and observation in these patients results in less recurrence than those treated with chest drains
- Patient needs to be able to seek medical attention if there is any deterioration, should be followed up in respiratory outpatients, and should be given written advice eg. symptom management, concerning symptoms
- Appropriate oral analgesia for pain
- Observation is inappropriate for a patient who is breathless

The NEW ENGLAND JOURNAL of MEDICINE

ESTABLISHED IN 1812 JANUARY 30, 2020 VOL. 382 NO. 5

Conservative versus Interventional Treatment for Spontaneous Pneumothorax

S.G.A. Brown, E.L. Ball, K. Perrin, S.E. Asha, I. Braithwaite, D. Egerton-Warburton, P.G. Jones, G. Keijzers, F.B. Kinnear, B.C.H. Kwan, K.V. Lam, Y.C.G. Lee, M. Nowitz, C.A. Read, G. Simpson, J.A. Smith, Q.A. Summers, M. Weatherall, and R. Beasley, for the PSP Investigators*

CONCLUSIONS

Although the primary outcome was not statistically robust to conservative assumptions about missing data, the trial provides modest evidence that conservative management of primary spontaneous pneumothorax was noninferior to interventional management, with a lower risk of serious adverse events. (Funded by the Emergency Medicine Foundation and others; PSP Australian New Zealand Clinical Trials Registry number, ACTRN12611000184976.)

Needle Aspiration



- In PSP NA has been shown to have equivalent success to ICC insertion (although this is disputed – BTS vs ACCP)
- Less painful than ICC
- Decease rate of hospital admission
- Failure rate in around 1/3 of patients will require a second procedure. Repeat NA is not recommended
- May be unsafe to use sharp needle aspiration on PTX <1cm
- The choice of initial intervention should take into account operator experience and patient choice

Intercostal Catheter
Seldinger / Fine Bore Catheter



- Small bore, wire-guided ICC (10-14 French)
- Ease of insertion (easier than needle aspiration?)
- Attachment of a Heimlich valve allows patient mobilisation and potentially outpatient care:

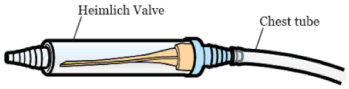

- More painful than NA but less painful than tradition large bore ICC
- Factors that predispose to small tube failure include presence of pleural fluid and/or presence of a large air leak
- Chemical pleurodesis is still possible through small chest drains
- Although Seldinger intercostal catheters come in a range of sizes the latest realization is the 3 way tap (9 French) is the rate limiting step in air evacuation



Traditional ICC



- Large bore ICC (>24 French) are not recommended for initial treatment of PTX (although it may become necessary to replace a small ICC with a large one if there is a persistent air leak)
- First line for trauma patients?
- Very painful often requiring IV sedation and analgesia
- Complications:
    - Penetration of a major organ (lung, liver, spleen, stomach, heart, great vessels). Usually a result of inappropriate trocar use
    - Incorrect tube placement (increasing rate of pick up from CT scanning)
    - Pleural infection and empyema (1% of ICC placement – up to 6% in trauma)

Triangle of Safety

- Pectoralis Major
- Anterior to the Mid-Axillary Line
- Above the 5th intercostal space

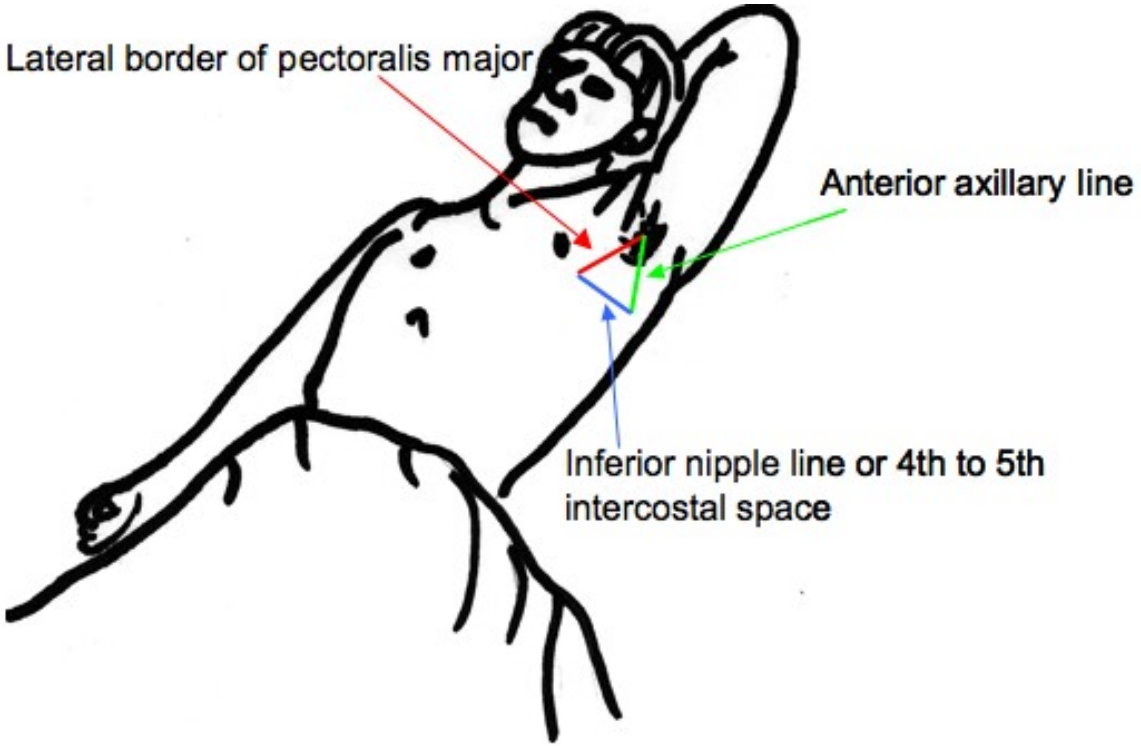




Excel innovative



Chest drain system

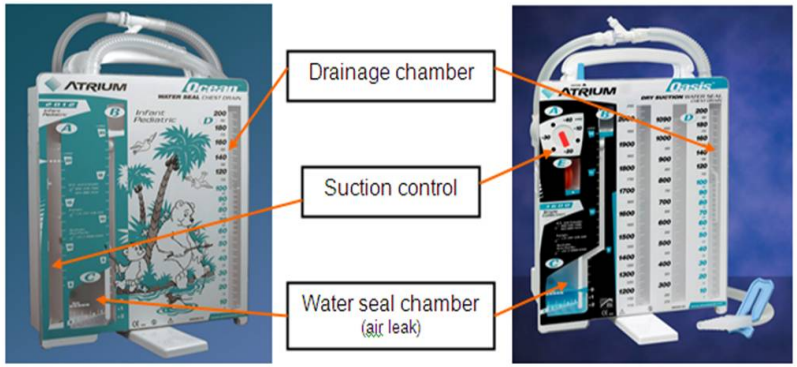

Suction?

- No evidence for routine use
- Indicated if persistent air leak after 48 hrs (therefore no role for suction in the ED)
- The addition of suction too early after chest drain insertion may precipitate re-expansion pulmonary oedema (esp in PSP that may have been present for several days)

Disposition

- PSP - Observation in ED after conservative management or NA, and home with written advice
  - Follow up in respiratory OP in 7-10 days
  - Re-expansion rate of 2.2% a day with wild variations
- SSP - Admission for observation after conservative management or NA
- Admission after ICC

Pneumothorax Guideline

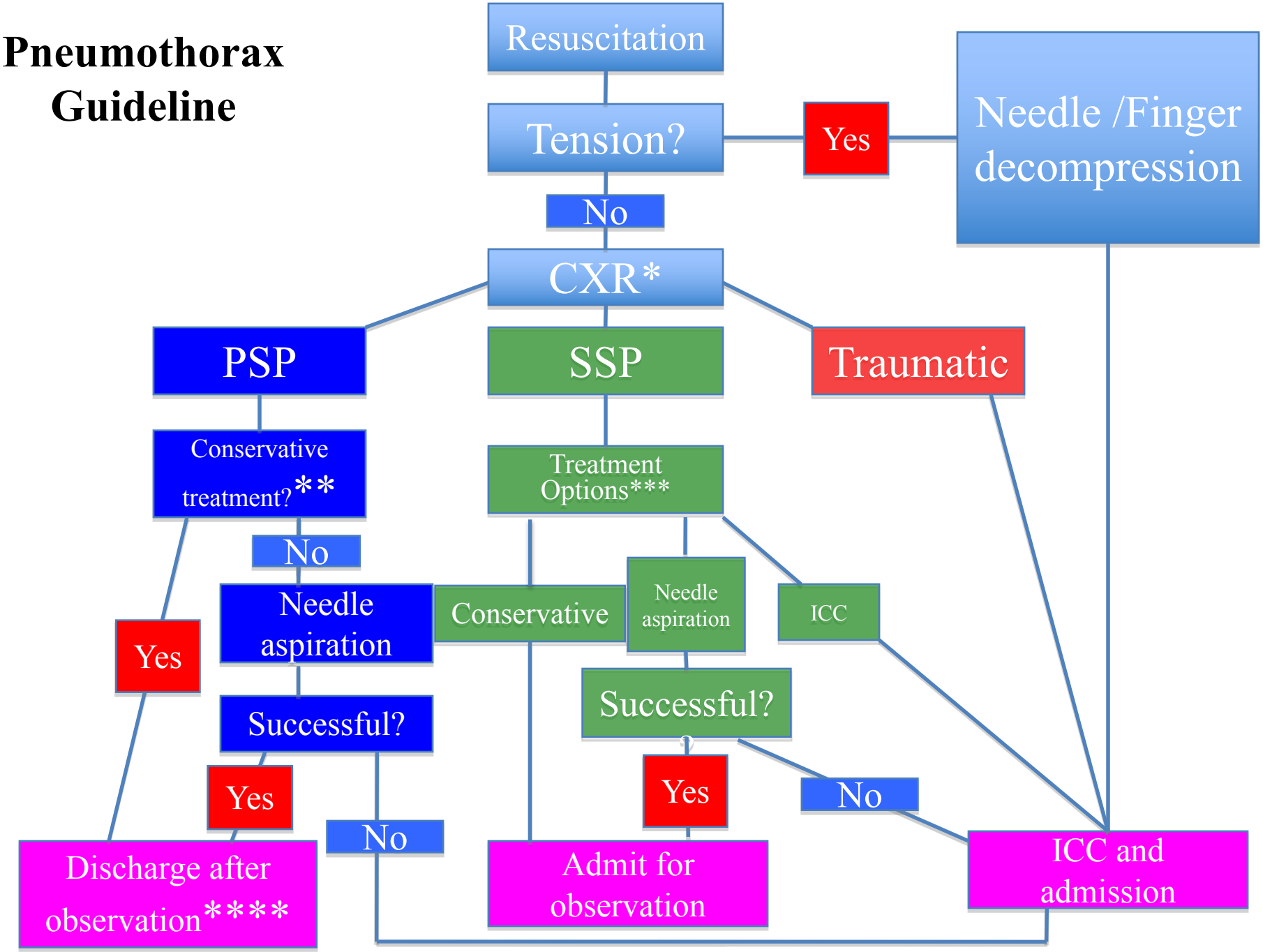

Pneumothorax Guideline

Appendix

*Measuring PTX
Erect PA CXR
Length "b" –
<2cm = small
>/= 2cm = large (50%)

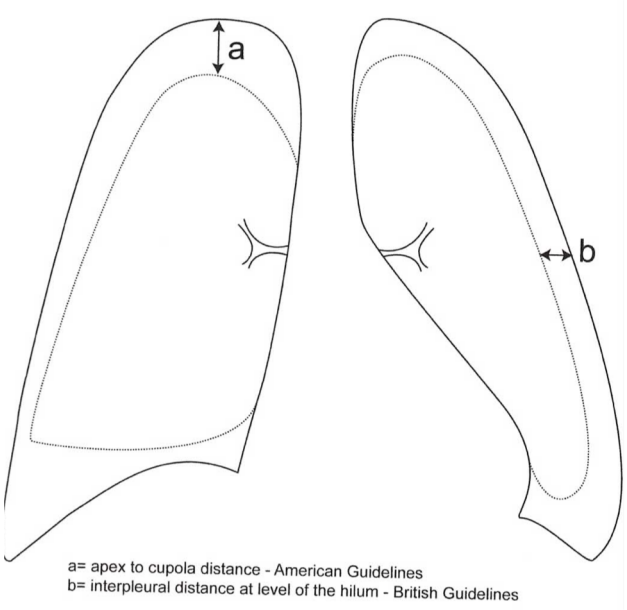

a= apex to cupola distance - American Guidelines
b= interpleural distance at level of the hilum - British Guidelines

**PSP conservative treatment criteria: no significant SOB, <2cm PTX

***SSP treatment options:

CONSERVATIVE: no significant SOB, <1cm PTX or isolated apical PTX, <50 years

NEEDLE ASPIRATION: <50 years <2cmPTX

ICC: >50 years >2cm PTX

****Discharge criteria and written advice:

4 hours observations with no deterioration
Must live close to hospital
Return immediately to ED if increasing SOB
Follow up in Respiratory OP 7-10 days
No air travel
No SCUBA diving

Needle Vs Finger Decompression

- Conventional Teaching:
  - Anterior approach
  - 2nd intercostal space, midclavicular line
  - Most attempts go medial to this!
  - Several vital structures medial to mid clavicular line that you should not hit !

25 ED Physicians asked to point out the site to do a "thoracocentesis"

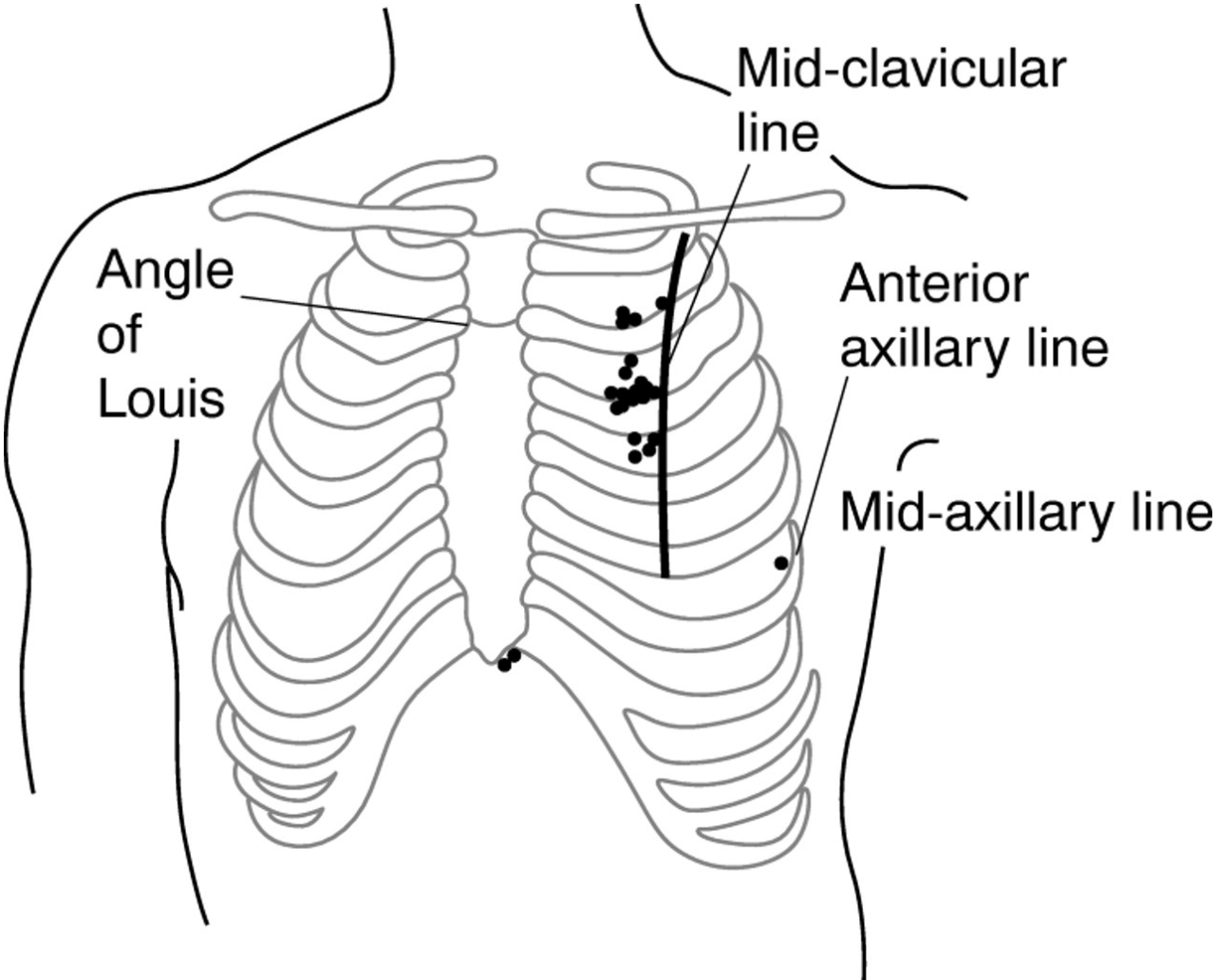

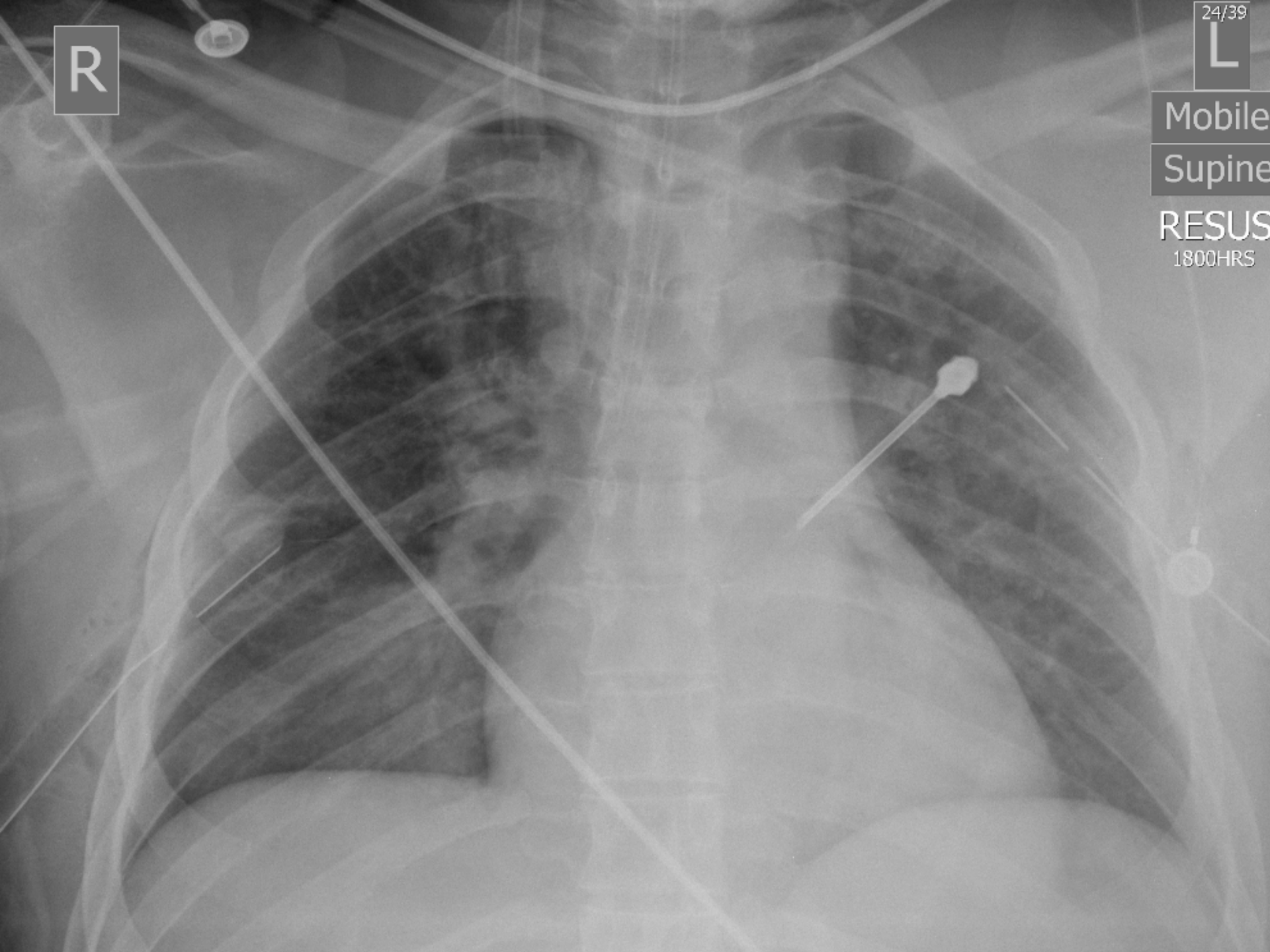
R
24/39
L
Mobile
Supine
RESUS
1800HRS

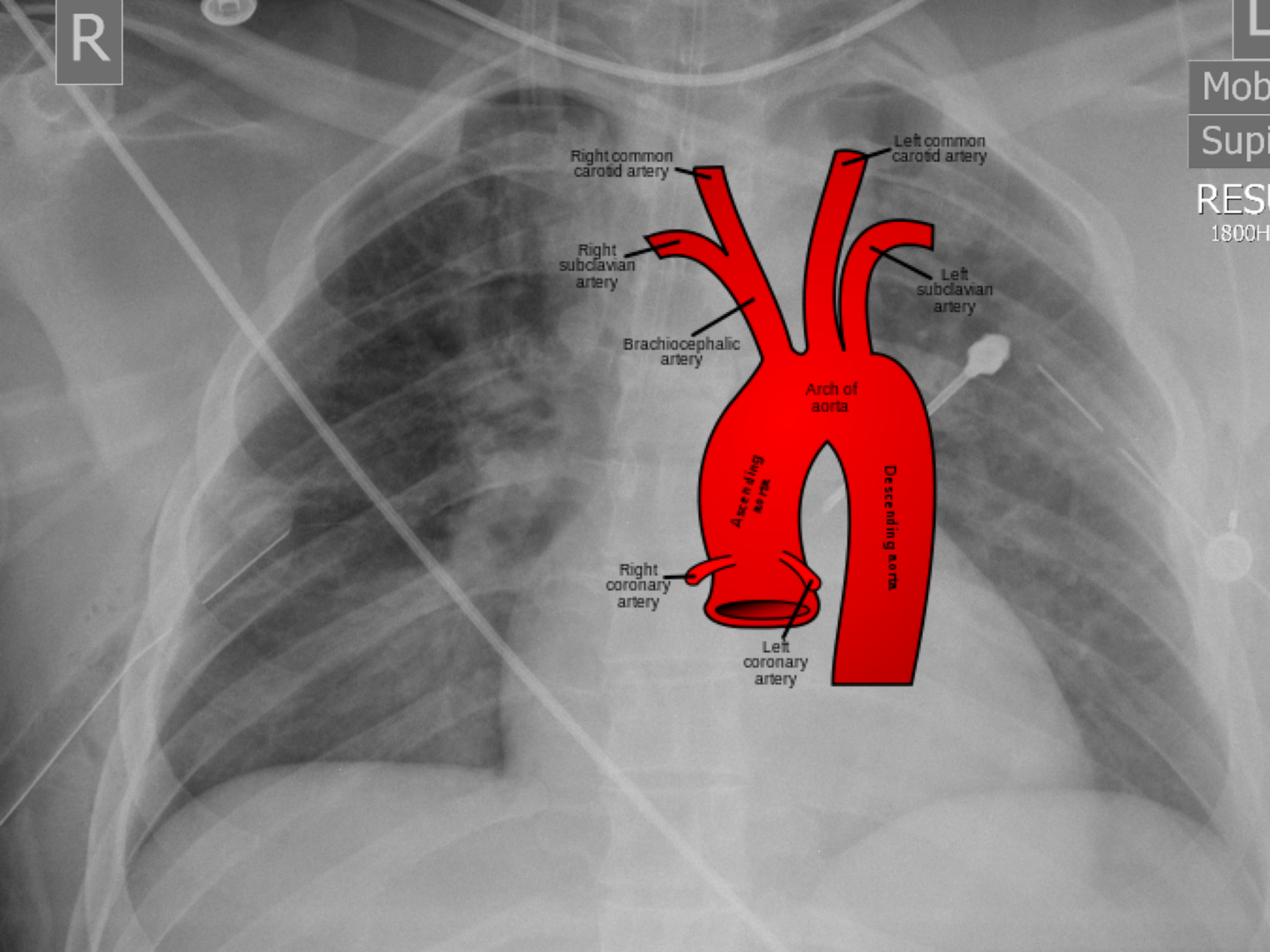
R
Right common carotid artery
Left common carotid artery
Right subclavian artery
Left subclavian artery
Brachiocephalic artery
Arch of aorta
Ascending aorta
Descending aorta
Right coronary artery
Left coronary artery
Mob
Supi
RES
1800H

- Mid clavicular line is almost on the nipple line
- Going lateral to the nipple is probably safest
- Or.....

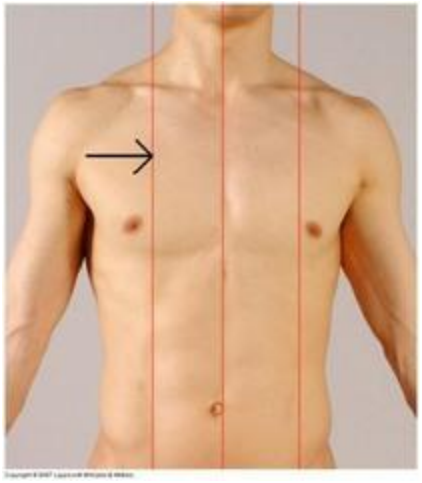

- ....do the needle decompression in the same site you would do a chest drain

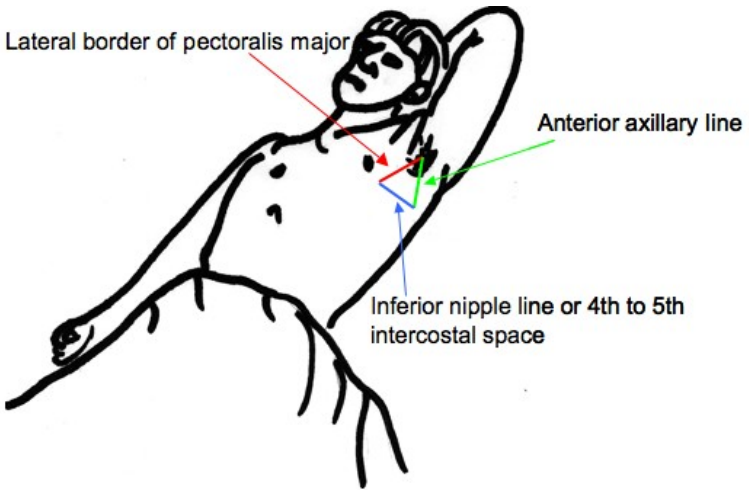

- Normal IV cannula is not long enough is 65% of cases
- The cannula that comes in the central line kit may be more appropriate
- Even if you get cannula in the correct place it may kink, occlude, compress or dislodge

- Finger Thoracostomy
  - Essentially the first step of a large bore ICC insertion
  - Provides definitive decompression of the pleural space
  - Can be followed up by insertion of an ICC or the wound can simply be sutured closed

- Much more appropriate procedure in trauma patients

- Bilateral finger thoracostomies can be converted into a clamshell thoracotomy

