AIS PennHIP

(877) 727-6800 www.antechimagingservices.com

Owner's Copy

PennHIP Report

Referring Veterinarian: Dr Tracy Godfrey	Clinic Name: Kemptville Animal Hospital
Email: tgodfrey@kahvet.com	Clinic Address: 4 Industrial Dr. Unit 5 Kemptville, ON K0G 1J0
	Phone: (613) 258-2030
	Fax:(613) 258-0027

Patient Information

Client: Osgoode, Osgoode	Tattoo Num:
Patient Name: Chewy	Patient ID: 991
Reg. Name: Northernpaws Chewbacca of Knighterrant	Registration Num: HL4004364
PennHIP Num: 158729	Microchip Num: 956000012299007
Species: Canine	Breed: ENGLISH MASTIFF
Date of Birth: 02 Jun 2020	Age: 12 months
Sex: Male	Weight: 160 lbs/72.6 kgs
Date of Study: 21 Jun 2021	Date Submitted: 21 Jun 2021
Date of Report: 24 Jun 2021	

Findings

Distraction Index (DI): Right DI = 0.47, Left DI = 0.35.

Osteoarthritis (OA): **No radiographic evidence of OA for either hip.**

Cavitation/Other Findings: No cavitation present.

Interpretation

Distraction Index (DI): The laxity ranking is based on the hip with the greater laxity (larger DI). In this case the DI used is 0.47.

OA Risk Category: The DI is between 0.31 and 0.49. This patient is at mild risk for hip OA.

Distraction Index Chart:

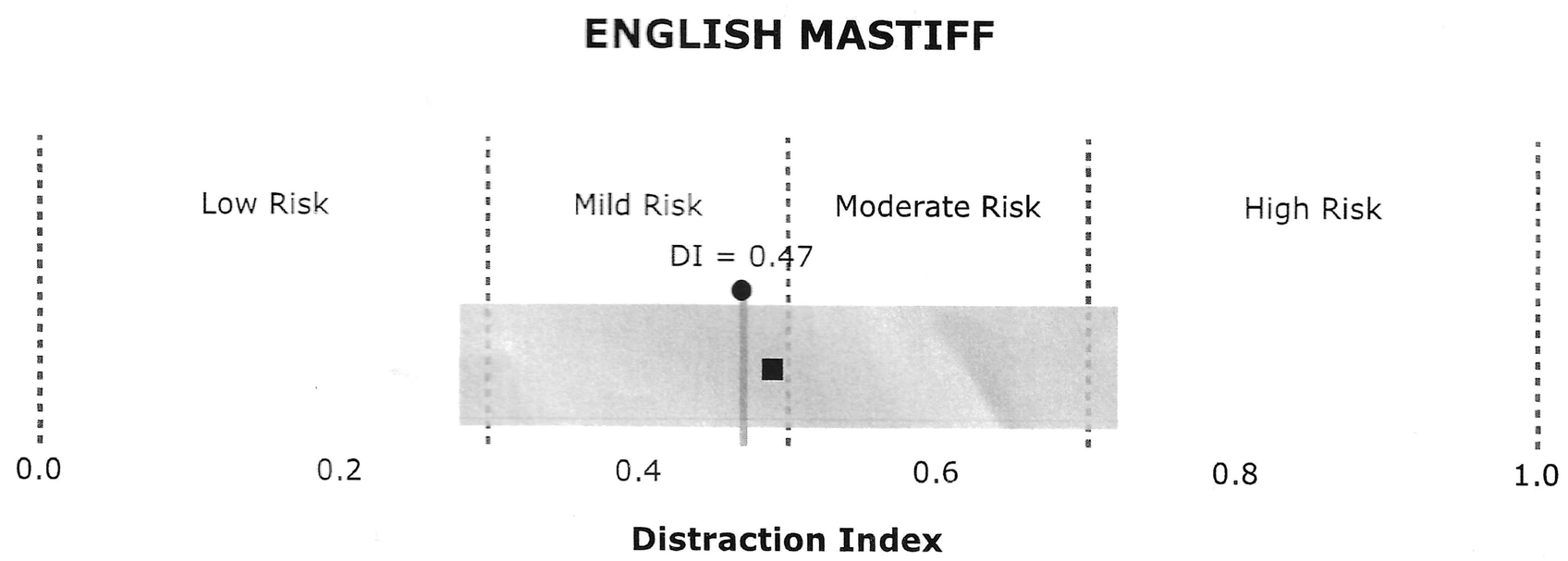

BREED STATISTICS: This interpretation is based on a cross-section of 1091 canine patients of the ENGLISH MASTIFF breed in the AIS PennHIP database. The gray strip represents the central 90% range of DIs (0.28 - 0.72) for the breed. The breed average DI is 0.49 (solid square). The patient DI is the solid circle (0.47).

SUMMARY: The degree of laxity (DI = 0.47) falls within the central 90% range of DIs for the breed. This amount of hip laxity places the hip at a mild risk to develop hip OA. **No radiographic evidence of OA for either hip.**