

COOL RENEWAL[®] CASE STUDY

DISTICHIA

Veterinarian Name: Sharon Minninger, DVM

Practice Name: Telford Veterinary Hospital

Date of Treatment: July 1, 2020

Patient Signalment

Ramsey- 2 Yrd Old MN Mix, 60 lbs.

Chief Complaint

Chronic blepharospasm and tearing, especially right eye.

Also increased inter-dog aggression at home.

Distichia present bilateral eyes, both upper and lower lids, lining the entire eyelids.

Too numerous to count.

Solution

Cryosurgery with Cool Renewal to freeze Distichia bilateral eyelids, both eyes.

Results/ Opinion

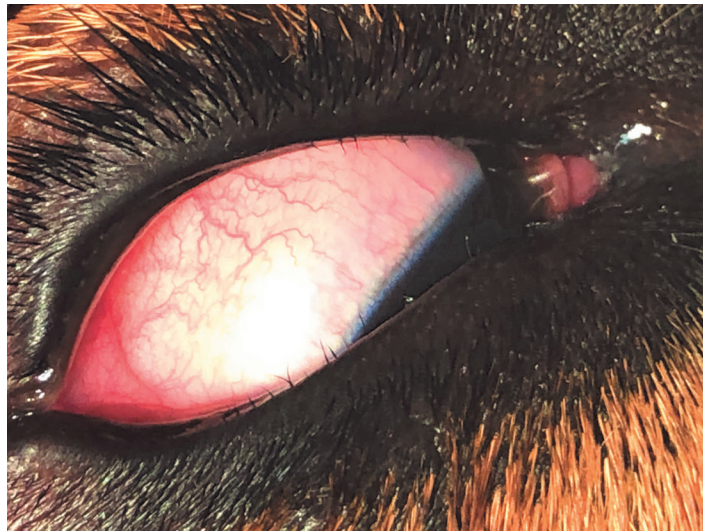
1 week later, decrease in tearing and rubbing at eyes.

Overall improved comfort.

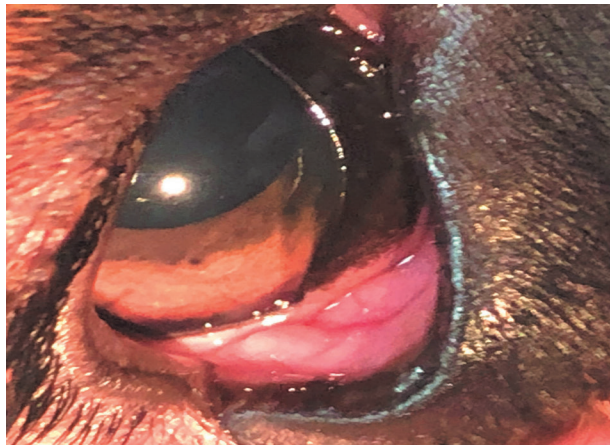
COOL RENEWAL[®] CASE STUDY

Images (before/during/after treatment)

BEFORE



AFTER



Links to Treatment Video(s)

Available upon request- info@cool-renewal.com