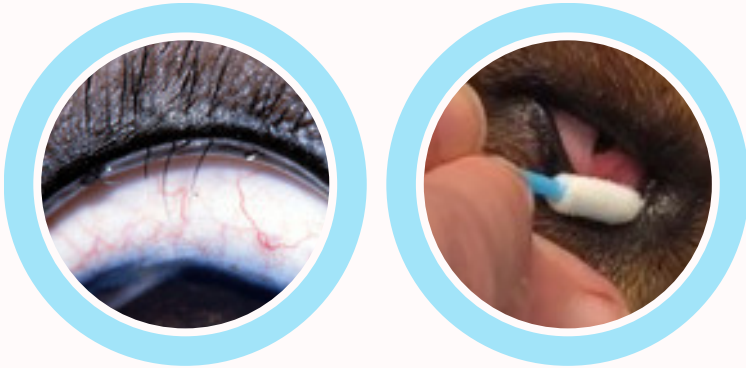


VETERINARY LESION FOCUS

DISTICHIA

FREEZE THAT FOLLICLE!



Distichia are extra, abnormally positioned hairs (cilia) along the eyelid margin. These cilia can cause irritation to the eye because they are directed toward, instead of away from the eye surface.

Eyes irritated by distichia usually have intermittent or persistent redness, squinting, and increased tearing and are prone to corneal ulceration and scarring.

When distichia are identified to be causing ocular irritation, the hairs should be removed so they do not cause permanent damage to the cornea.

.....

COOL RENEWAL USES EXTREME COLD TO DESTROY TISSUE/ LASH FOLLICLE

NO CUTTING, NO SUTURING, NO RECONSTRUCTION OF LID


HEALS NATURALLY IN 7-10 DAYS

MINIMAL PATIENT DISCOMFORT

CLINIC COST: ~\$3 PER TREATMENT


PROCEDURE CHARGE: ~ \$250 W/ ANESTHESIA or SEDATION

FACTS ABOUT DISTICHIASIS



- Distichiasis is a common condition in dogs, but it is more prevalent in the American Cocker Spaniel, English Cocker Spaniel, Miniature Dachshund, Longhair Dachshund, Bulldog, and Weimaraner breeds.
- Distichiasis, or the presence of extra eyelashes, in dogs is a condition where hairs grow in an unusual area on the eyelid. The hairs will generally grow out of the meibomian glands at the lid of the eyelid. Depending on the number of hairs, the rigidity of the hairs, and the direction of the hairs, this can cause problems to the eye itself.
- The presence of extra hairs, or eyelashes, does not cause a problem in many dogs. The hairs are not bothersome and many pet owners do not even realize that their dog has extra hairs on the eyelid. However, there are symptoms to watch for:
 - Rubbing the eye
 - Increased blinking
 - Squinting of the eye
 - Increased watering
 - Redness of the eye
 - Ulcerations in the eye
- Distichiasis is a fairly common condition and it is not known why extra hairs emerge from the ducts of the meibomian gland. It can occur in any dog with varying degrees of severity.

COMMON TREATMENT OPTIONS DISTICHIASIS



OCCULAR LUBRICANTS



A lubricating gel may be the only necessary treatment if the case of distichiasis is mild. The lubricating gel will soften the hairs and therefore reduce the irritation. However, the dog will need to remain on a lubricating gel for the rest of its life.

PLUCKING



In some cases, the extra eyelashes are able to be plucked. This may be the treatment if there are only a few long hairs that need to be removed. HAIRS DO GROW BACK; therefore regular plucking will need to occur throughout the dog's lifetime.

SURGICAL REMOVAL & LID RECONSTRUCTION



Complications from V-plasty can be minor or severe and may include corneal ulceration, infection, suture reaction, eyelid margin misalignment, or eyelid tumor regrowth if tumor cells are left behind

CRYOSURGERY

For small tumors, cryosurgery can be very effective. It is a suture-less procedure that may require a brief general anesthesia or sedation. the affected eyelid is treated with two rounds of freezing with a foam tipped applicator saturated with cryogen, about 20 seconds each treatment.

Skin ulceration is expected with cryosurgery and can last up to 7-10 days peaking about 3-5 days post surgery on average. Some local skin ulceration may also occur and resolves in the first 1-2 weeks. The goal of care is to destroy any residual tumor cells and allow the eyelid to heal without any incisions or suture placement. Infection is rare but topical antibiotics and systemic anti-inflammatories and pain medication is typically used postoperatively.

TIPS FOR TREATING DISTICHIA

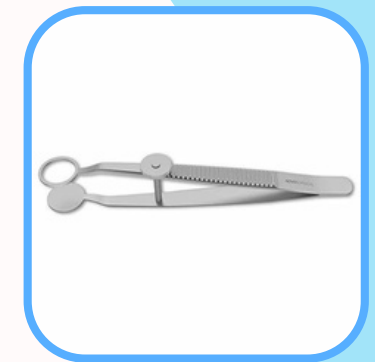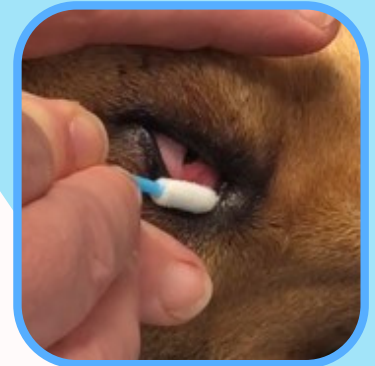with

COOL RENEWAL

CRYOSURGERY SYSTEM

DISTICHIA CASE STUDY

1. If needed, use a chalazion clamp to hold open the lid
2. The hair/ lash can be plucked prior to the freeze but isn't required
3. Choose an appropriately sized Foam Tipped Applicator (usually the small, pointed tip)
4. Apply the frozen applicator to the skin for approximately 20-30 seconds
5. Once the applicator is removed from the skin, an ice ball should appear and take approximately 1minute to thaw naturally. DO NOT TOUCH the skin during the thaw phase.
6. Once the ice ball has thawed, the clamp can be removed.
7. Some veterinarians like to perform 2 consecutive freezes. It's personal preference, depending on thickness and size of the treatment area.
8. Post Treatment- since the eyes are very vascular, they generally heal faster than other body locations, so it should heal within 7-10 days.
9. Follow up within 14 days to assess the healing and to determine if an additional freeze is required.



-
- **SINCE THE EYELID IS A SENSITIVE AREA, IT USUALLY REQUIRES A SHORTER FREEZE APPLICATION TIME THAN THICKER SKIN AREAS. TARGET FREEZE TIME APPROXIMATELY 20-30 SECONDS**
 - **IT IS ALWAYS RECOMMEND TO USE THE FOAM TIPPED APPLICATORS FOR DISTICHIA TREATMENT.**
 - **NEVER USE ONE OF THE ISOLATION FUNNELS ON OR AROUND THE EYE, AS THE EYEBALL COULD BE DAMAGED IF THERE WAS ANY LEAKAGE OF CRYOGEN DURING THE PROCEDURE.**

PLEASE WATCH THE [INSTRUCTIONAL VIDEO](#) PRIOR TO PERFORMING PROCEDURES