



Owner's Copy

**PennHIP Report**

Referring Veterinarian: Dr Brian Welborn  
 Email: atkinsonvetclinic@telebeep.com

Clinic Name: Atkinson Veterinary Clinic, PC  
 Clinic Address: 620 S. State Hwy 11  
 Atkinson, NE 68713  
 Phone: (402) 925-5110  
 Fax: (402) 925-5061

**Patient Information**

Client: Lemmer, Bonnie  
 Patient Name: Charlie  
 Reg. Name:  
 PennHIP Num:   
 Species: Canine  
 Date of Birth: 07 Dec 2021  
 Sex: Male  
 Date of Study: 27 Apr 2022  
 Date of Report: 29 Apr 2022

Tattoo Num:  
 Patient ID: Charlie  
 Registration Num:   
 Microchip Num: 956000011947829  
 Breed: BERNESE MOUNTAIN DOG  
 Age: 20 weeks  
 Weight: 56 lbs/25.4 kgs  
 Date Submitted: 27 Apr 2022

**Findings**

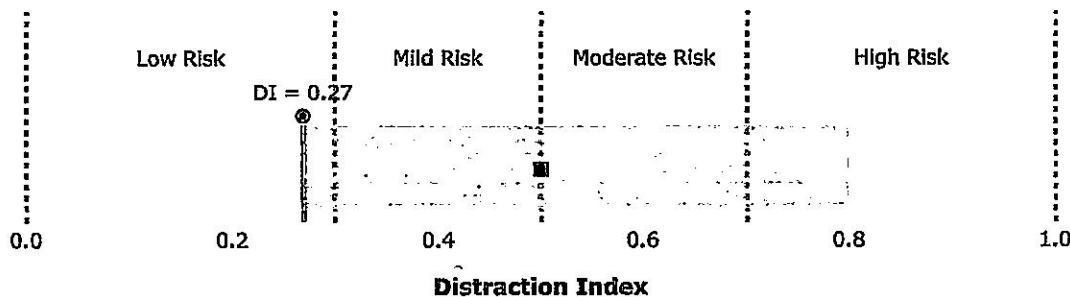
Distraction Index (DI): Right DI = 0.27, Left DI = 0.27.  
 Osteoarthritis (OA): No radiographic evidence of OA for either hip.  
 Cavitation/Other Findings: No cavitation present.

**Interpretation**

Distraction Index (DI): The laxity ranking is based on the hip with the greater laxity (larger DI). In this case the DI used is 0.27.

OA Risk Category: The DI is less than or equal to 0.30. This patient is at minimal risk for hip OA.

Distraction Index Chart:

**BERNESE MOUNTAIN DOG**

**BREED STATISTICS:** This interpretation is based on a cross-section of 3689 canine patients of the BERNESE MOUNTAIN DOG breed in the AIS PennHIP database. The gray strip represents the central 90% range of DIs (0.27 - 0.80) for the breed. The breed average DI is 0.50 (solid square). The patient DI is the solid circle (0.27).