



(877) 727-6800

www.antechimagingervices.com

Owner's Copy

PennHIP Report

Referring Veterinarian: Dr Brian Welborn
Email: atkinsonvetclinic@telebeep.com

Clinic Name: Atkinson Veterinary Clinic, PC
Clinic Address: 620 S. State Hwy 11
Atkinson, NE 68713
Phone: (402) 925-5110
Fax: (402) 925-5061

Patient Information

Client: Lemmer, Bonnie
Patient Name: Fonzie
Reg. Name:
PennHIP Num:
Species: Canine
Date of Birth: 05 May 2018
Sex: Male
Date of Study: 19 Nov 2018
Date of Report: 20 Nov 2018

Tattoo Num:
Patient ID: Fonzie
Registration Num:
Microchip Num: 968000010895045
Breed: BERNESE MOUNTAIN DOG
Age: 6 months
Weight: 79 lbs/35.8 kgs
Date Submitted: 19 Nov 2018

Findings

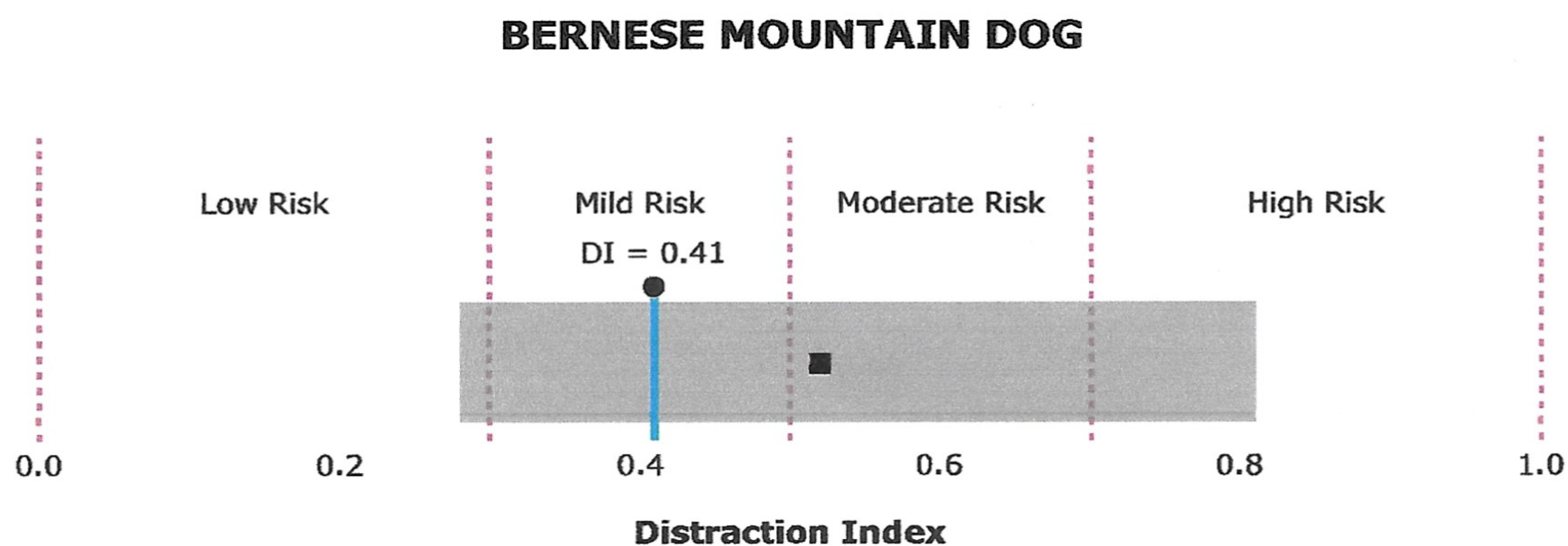
Distraction Index (DI): Right DI = 0.40, Left DI = 0.41.
Osteoarthritis (OA): No radiographic evidence of OA for either hip.
Cavitation/Other Findings: No cavitation present.

Interpretation

Distraction Index (DI): The laxity ranking is based on the hip with the greater laxity (larger DI). In this case the DI used is 0.41.

OA Risk Category: The DI is between 0.31 and 0.49. This patient is at mild risk for hip OA.

Distraction Index Chart:



BREED STATISTICS: This interpretation is based on a cross-section of 2765 canine patients of the BERNESE MOUNTAIN DOG breed in the AIS PennHIP database. The gray strip represents the central 90% range of DIs (0.28 - 0.81) for the breed. The breed average DI is 0.52 (solid square). The patient DI is the solid circle (0.41).