

PennHIP Report

Referring Veterinarian: Dr Brian Welborn
 Email: atkinsonvetclinic@telebeep.com

Clinic Name: Atkinson Veterinary Clinic, PC
 Clinic Address: 620 S. State Hwy 11
 Atkinson, NE 68713
 Phone: (402) 925-5110
 Fax: (402) 925-5061

Patient Information

Client: Lemmer, Bonnie

Patient Name: Jade

Reg. Name:

PennHIP Num:

Species: Canine

Date of Birth: 15 Mar 2019

Sex: Female

Date of Study: 22 Jul 2019

Date of Report: 23 Jul 2019

Tattoo Num:

Patient ID: Jade

Registration Num: WS64194001

Microchip Num: 603569800

Breed: BERNESE MOUNTAIN DOG

Age: 18 weeks

Weight: 48 lbs/21.8 kgs

Date Submitted: 22 Jul 2019

Findings

Distraction Index (DI): Right DI = 0.29, Left DI = 0.28.

Osteoarthritis (OA): No radiographic evidence of OA for either hip.

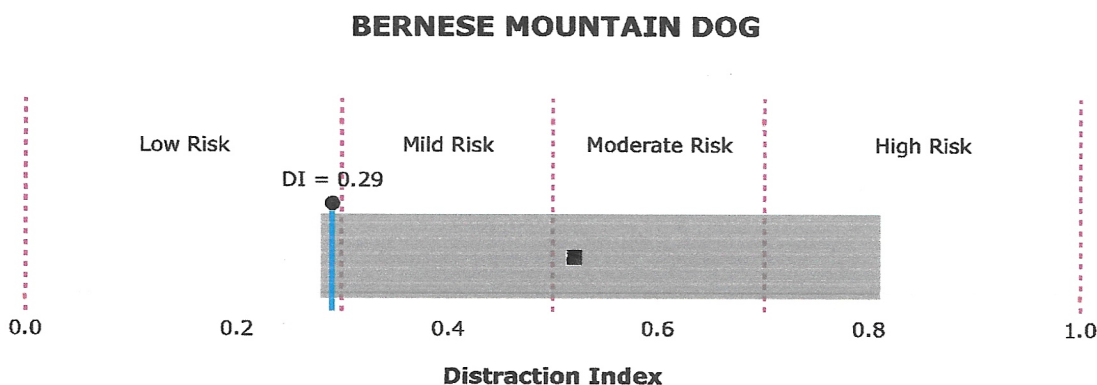
Cavitation/Other Findings: No cavitation present.

Interpretation

Distraction Index (DI): The laxity ranking is based on the hip with the greater laxity (larger DI). In this case the DI used is 0.29.

OA Risk Category: The DI is less than or equal to 0.30. This patient is at minimal risk for hip OA.

Distraction Index Chart:



BREED STATISTICS: This interpretation is based on a cross-section of 2883 canine patients of the BERNESE MOUNTAIN DOG breed in the AIS PennHIP database. The gray strip represents the central 90% range of DIs (0.28 - 0.81) for the breed. The breed average DI is 0.52 (solid square). The patient DI is the solid circle (0.29).