



Owner's Copy

PennHIP Report

Referring Veterinarian: Dr Brian Welborn Email: atkinsonvetclinic@telebeep.com	Clinic Name: Atkinson Veterinary Clinic, PC Clinic Address: 620 S. State Hwy 11 Atkinson, NE 68713 Phone: (402) 925-5110 Fax: (402) 925-5061
---	--

Patient Information

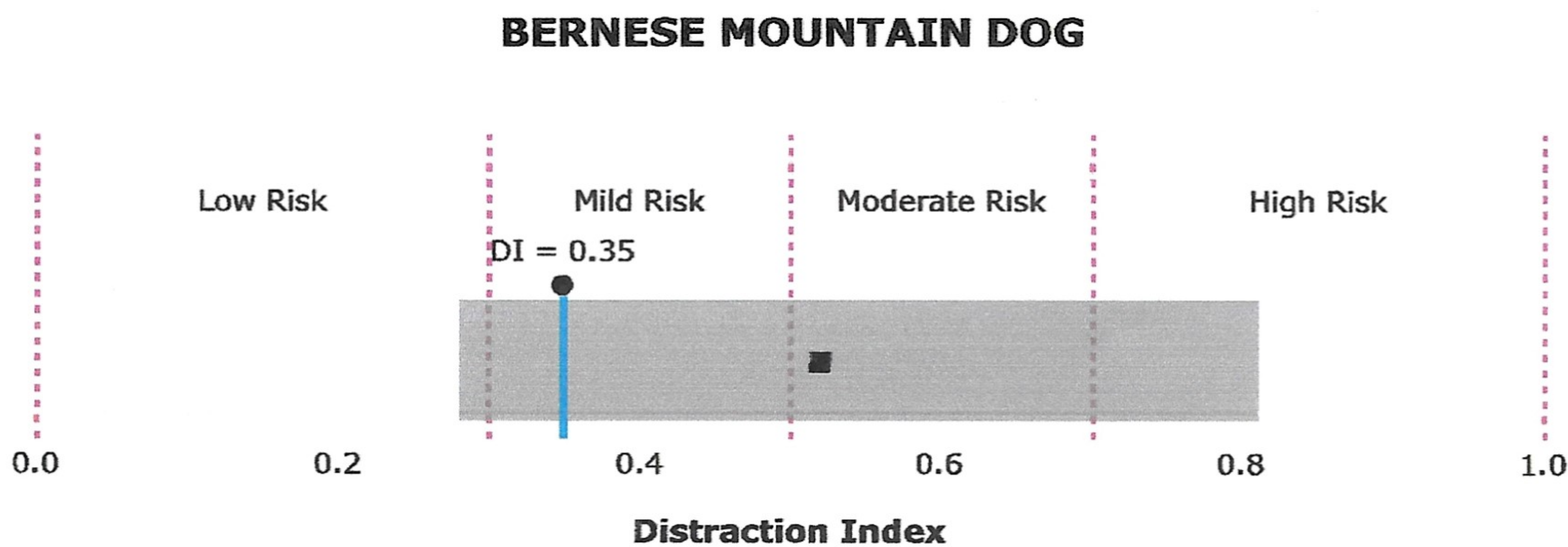
Client: Lemmer, Bonnie Patient Name: Louie Reg. Name: PennHIP Num: Species: Canine Date of Birth: 25 Apr 2019 Sex: Male Date of Study: 30 Sep 2019 Date of Report: 01 Oct 2019	Tattoo Num: Patient ID: Louie Registration Num: Microchip Num: 956000010394879 Breed: BERNESE MOUNTAIN DOG Age: 5 months Weight: 79 lbs/35.8 kgs Date Submitted: 30 Sep 2019
--	---

Findings

Distraction Index (DI): Right DI = 0.31, Left DI = 0.35.
 Osteoarthritis (OA): No radiographic evidence of OA for either hip.
 Cavitation/Other Findings: No cavitation present.

Interpretation

Distraction Index (DI): The laxity ranking is based on the hip with the greater laxity (larger DI). In this case the DI used is 0.35.
 OA Risk Category: The DI is between 0.31 and 0.49. This patient is at mild risk for hip OA.
 Distraction Index Chart:



BREED STATISTICS: This interpretation is based on a cross-section of 2883 canine patients of the BERNESE MOUNTAIN DOG breed in the AIS PennHIP database. The gray strip represents the central 90% range of DIs (0.28 - 0.81) for the breed. The breed average DI is 0.52 (solid square). The patient DI is the solid circle (0.35).