



Owner's Copy

PennHIP Report

Referring Veterinarian: Dr Brian Welborn
 Email: atkinsonvetclinic@telebeep.com

Clinic Name: Atkinson Veterinary Clinic, PC
 Clinic Address: 620 S. State Hwy 11
 Atkinson, NE 68713
 Phone: (402) 925-5110
 Fax: (402) 925-5061

Patient Information

Client: Lemmer, Bonnie
 Patient Name: Dori
 Reg. Name:
 PennHIP Num:
 Species: Canine
 Date of Birth: 19 Jul 2021
 Sex: Female
 Date of Study: 08 Dec 2021
 Date of Report: 13 Dec 2021

Tattoo Num:
 Patient ID: Dori
 Registration Num: WS73231802
 Microchip Num: 956000013534555
 Breed: BERNESE MOUNTAIN DOG
 Age: 20 weeks
 Weight: 55 lbs/24.9 kgs
 Date Submitted: 08 Dec 2021

Findings

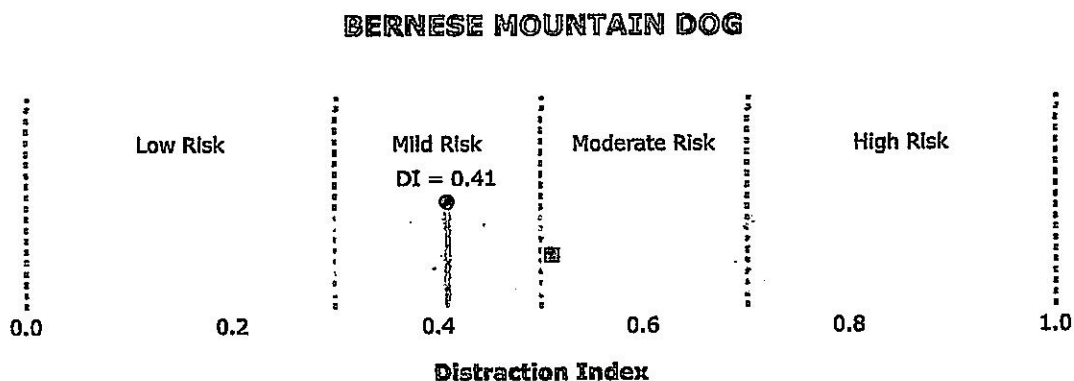
Distraction Index (DI): Right DI = 0.22, Left DI = 0.41.
 Osteoarthritis (OA): No radiographic evidence of OA for either hip.
 Cavitation/Other Findings: No cavitation present.

Interpretation

Distraction Index (DI): The laxity ranking is based on the hip with the greater laxity (larger DI). In this case the DI used is 0.41.

OA Risk Category: The DI is between 0.31 and 0.49. This patient is at mild risk for hip OA.

Distraction Index Chart:



BREED STATISTICS: This interpretation is based on a cross-section of 3596 canine patients of the BERNESE MOUNTAIN DOG breed in the AIS PennHIP database. The gray strip represents the central 90% range of DIs (0.27 - 0.80) for the breed. The breed average DI is 0.51 (solid square). The patient DI is the solid circle (0.41).