

**PennHIP Report**

Referring Veterinarian: Dr Brian Welborn Email: atkinsonvetclinic@telebeep.com	Clinic Name: Atkinson Veterinary Clinic, PC Clinic Address: 620 S. State Hwy 11 Atkinson, NE 68713 Phone: (402) 925-5110 Fax:(402) 925-5061
---	---

**Patient Information**

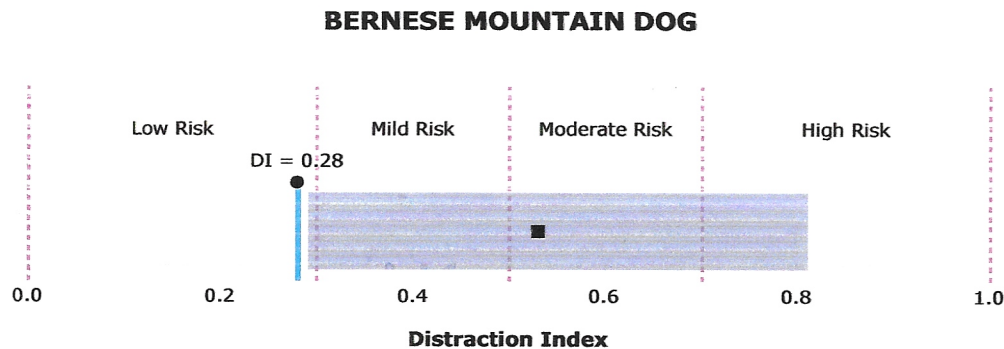
Client: Lemmer, Bonnie Patient Name: Tana Reg. Name: PennHIP Num: Species: Canine Date of Birth: 21 Apr 2016 Sex: Female Date of Study: 09 Jan 2017 Date of Report: 10 Jan 2017	Tattoo Num: Patient ID: Tana Registration Num: Microchip Num: 945000001777925 Breed: BERNESE MOUNTAIN DOG Age: 9 months Weight: 90.1 lbs/40.9 kgs Date Submitted: 09 Jan 2017
---	--

**Findings**

Distraction Index (DI):Right DI = 0.28, Left DI = 0.28.  
 Osteoarthritis (OA):No radiographic evidence of OA for either hip.  
 Cavitation/Other Findings:None.

**Interpretation**

Distraction Index (DI):The laxity ranking is based on the hip with the greater laxity (larger DI). In this case the DI used is 0.28.  
 OA Risk Category:The DI is less than or equal to 0.30. This patient is at minimal risk for hip OA.  
 Distraction Index Chart:



**Breed Statistics:**This interpretation is based on a cross-section of 2454 Canine patients of the BERNESE MOUNTAIN DOG breed in the AIS PennHIP database. The gray strip represents the central 90% range of DIs (0.29 - 0.81) for the breed. The breed average DI is 0.53. The patient DI is the solid circle (0.28).

**Summary:**The degree of laxity (DI = 0.28) ranks the hip within the tightest 5% of DIs for the breed. This amount of hip laxity places the hip at a minimal risk to develop hip OA. No radiographic evidence of OA for either hip.

**Interpretation and Recommendations:**