



YEAR: 2021

VOLUME: 1

ISSUE: 2

# INTERNATIONAL JOURNAL OF HEALTH SCIENCES OF NORTHERN LIGHTS (IJOHSON)



# THE IMPORTANCE OF BEDSIDE ULTRASOUND IN THE DIAGNOSIS OF TESTICULAR TORSION

Ramazan UNAL<sup>1\*</sup>, Mert Rusen GULSEN<sup>1</sup>, Ceren Ovacik KARAFILIK<sup>1</sup>, Nurcan OZASLAN<sup>1</sup>, Vedat AVCIERI<sup>2</sup>

<sup>1</sup>Republic of Turkey Ministry of Health Balikesir Provincial Health Directorate Edremit State Hospital, Emergency Department, Balikesir, Turkey

<sup>2</sup>Republic of Turkey Ministry of Health Balikesir Provincial Health Directorate Edremit State Hospital, Department of Urology, Balikesir, Turkey

\*Corresponding author

## ABSTRACT

The acute scrotum is a broad definition used for all scrotal swellings with or without pain. The most common differential diagnoses include testicular torsion, testicular appendage torsion, and acute epididymitis or epididymo-orchitis. Testicular torsion usually occurs during adolescence. Testicular torsion accounts for approximately 25% of acute scrotum cases. According to the studies, normal testicular dimensions are preserved and only slight changes in morphology occur if the testes are operated within 8 hours after the onset of torsion symptoms. The early diagnosis together with intervention in testicular torsion prevents irreversible changes in testes. Bedside ultrasonography done by emergency medicine specialists, especially in health institutions that do not have on-duty radiology specialists, is of great importance in the early diagnosis of testicular torsion and in reducing morbidity, as in most emergencies. We will present 2 cases diagnosed with testicular torsion by bedside ultrasound and then operated.

**Keywords;** bedside ultrasound, emergency medicine department, testicular torsion,

## Introduction

The acute scrotum is a broad definition used for all scrotal swellings with or without pain, and the majority of patients' complaint is pain. The most common differential diagnoses include testicular torsion, testicular appendage torsion, and acute epididymitis or epididymo-orchitis. Testicular torsion, which often occurs in adolescence, is a true surgical emergency characterized by decreased blood flow to the testes due to torsion of the spermatic cord. Testicular torsion accounts for approximately 25% of acute scrotum cases. Testicular torsion occurs in one of every 4000 people under 25 years of age annually, with the highest prevalence in between 12 and 18 years old. <sup>(1)</sup>

In general, there are no apparent causes, but several factors relating to the deformity have been described in "bell clapper testes", where there is an abnormal adherence of the tunica vaginalis to the testicle, and this results in an increase in the mobility of the testicle inside the tunica vaginalis<sup>(2)</sup>. Other associated factors are the increase in testicular volume, testicular tumors, testicle being in a horizontal position, a history of cryptorchidism, spermatic cord with a long intrascrotal section, high or proximal insertion of the tunica vaginalis to the spermatic cord, trauma and recently doing exercise. Environmental factors, such as low temperature,<sup>(3)</sup> have also been associated with testicular torsion.

According to the studies, normal testicular dimensions are preserved and only slight changes in morphology occur if the testes are operated within 8 hours after the onset of torsion symptoms. Despite this, they have also reported that only 50% of men who underwent detorsion within 4 hours of symptoms had normal results of semen analysis<sup>(4)</sup>. The severity of torsion seems to have a significant effect on testicular viability over time. The early diagnosis together with intervention in testicular

torsion prevents irreversible changes in testes<sup>(5)</sup>. We will present 2 cases diagnosed with testicular torsion by bedside ultrasound and then operated.

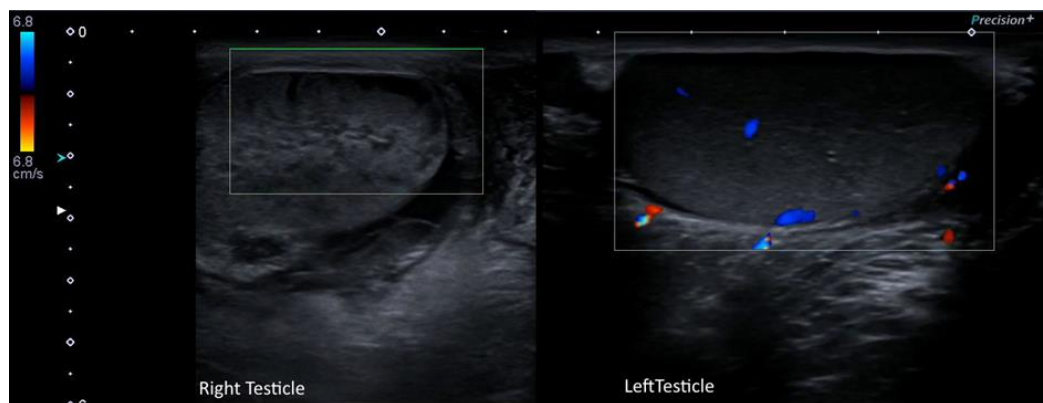
### Aim

We will present two separate cases to emphasize that early diagnosis is of great importance for testicular survival in cases of testicular torsion and that bedside doppler scrotal ultrasonography (USG) performed by an emergency medicine specialist is sufficient for diagnosis in patients presenting with acute scrotal pain.

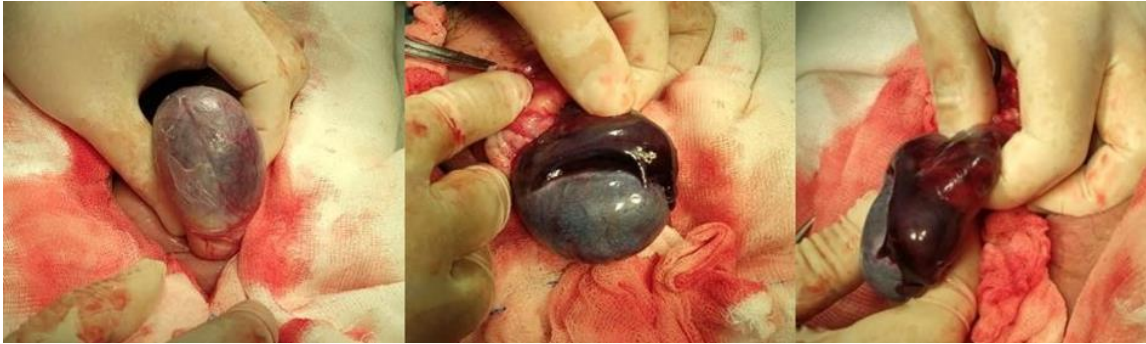### Case Presentation

#### Case 1:

A 15-year-old male patient applied to the emergency department at around 06:30 PM with the complaint of pain and swelling in the right scrotum for two days. In the physical examination of the right scrotum, there was stiffness and pain on palpation, significant enlargement compared to the left, and bruising on the scrotum skin. Scrotal pain did not change with elevation. The patient also stated that the pain was slightly better when compared to the day before. The patient's medical history was remarkable for an appendectomy due to acute appendicitis 3 weeks ago. There was no recent trauma to the scrotum. The patient was having occasional pain on the right side since the surgery and did not apply to the hospital. Considering that the patient may have testicular torsion, a color Doppler scrotal USG was performed with a high-frequency linear probe by the emergency medicine specialist. The right testis had a heterogeneous hypoechoic appearance with no blood flow and anechoic foci that may be consistent with necrosis in the testicular parenchyma. In the left testis, in addition to the presence of normal blood flow, there was a homogeneous appearance (Figure 1). The patient was consulted with the urology specialist on duty, with the preliminary diagnosis of necrotic testicular torsion. The patient was operated approximately 40 hours after the onset of his complaints. Black, necrotized and edematous testicular tissue was observed during the operation (Picture 2). As testicular tissue necrosis was detected, the patient underwent right orchiectomy.



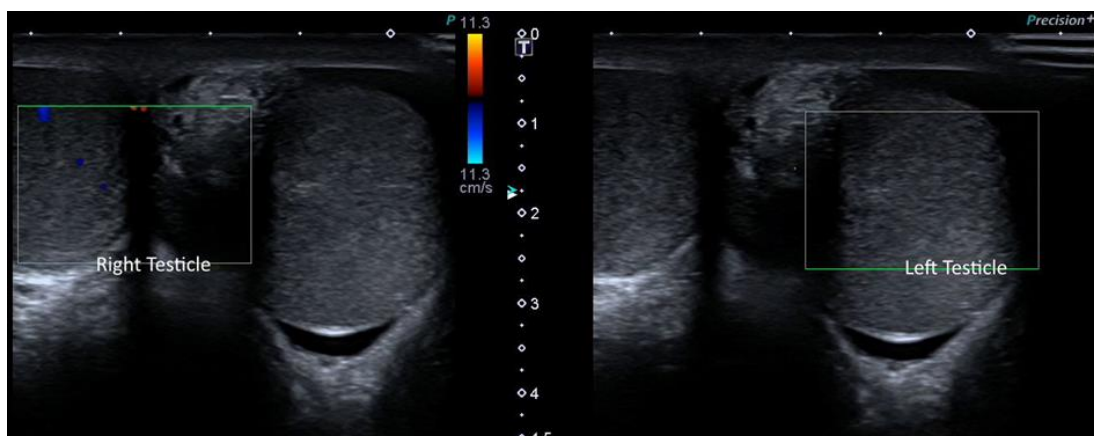
**Figure 1.** Bedside Scrotal Color Doppler Ultrasonography shows heterogeneous hypoechoic right testicular parenchyma with no blood supply and anechoic foci consistent with necrosis.



**Figure 2.** During the operation, black, necrotized and edematous testicular tissue is seen in the right testis.

**Case 2:**

A 12-year-old male patient was admitted to the emergency department at around 06:00 AM with the complaint of sudden onset left groin pain 2 hours ago. The patient, who had no history of trauma, stated that he woke up from sleep due to the severity of the pain. In the physical examination of the patient, there was swelling in the left scrotum and an increase in pain with palpation and elevation of the testis. No apparent discoloration was noticed on the skin of the scrotum. With the bedside scrotal color Doppler Ultrasonography performed by the emergency medicine specialist with a high-frequency linear probe, it was determined that there was no blood flow in the left testis with a slight increase in testicular size. The parenchyma appeared homogeneous and isoechoic with the right testis (Figure 3). Blood flow was intact in the right testis. The patient, who was consulted to the urology physician with the preliminary diagnosis of testicular torsion, was operated approximately 3 hours after the onset of his complaints. The patient, who was diagnosed with left testicular torsion, was surgically detorted. With the control scrotal USG performed one month later; the localization, size, contour, parenchymal structure and parenchymal echo pattern of both testicles were found to be normal.



**Figure 3.** On Bedside Scrotal Color Doppler Ultrasonography, it is seen that there are no blood supply in the left testis. There is a slight increase in testicular size. The parenchyma is homogeneous and isoechoic with the right testis parenchyma.

## **Discussion**

Testicular torsion is mostly a disease of adolescence and is commonly seen in between 12 to 18 years of age, as in both our cases. Scrotal pain that increases with elevation is typical in testicular torsion. Scrotal volume increase, scrotal skin redness, pain in the lower quadrant of the abdomen, nausea and vomiting may be present in addition to the scrotal pain. In the first case we presented, the fact that the intensity of pain not being changed with elevation and the relief of symptoms compared to the beginning could mislead the clinician. Early detection of testicular torsion and early intervention with detorsion are vital for the preservation of testicular vitality.<sup>(5)</sup>

In our first case, approximately 48 hours were passed after the initial onset of the patient's complaints. Hence it was determined that the testis was necrotic and orchiectomy was done. In our second case, the patient was operated three hours after the onset of his complaints and surgical detorsion was achieved. It was determined that testicular vitality was preserved with control USG performed one month later. Today, scrotal color Doppler Ultrasonography together with the patient history and physical examination has become the diagnostic method preferred by many centers.<sup>(6)</sup>

There is a delay in the diagnosis of the testicular torsion due to the absence of on-duty radiology specialists in most health institutions during non-working hours, which brings great responsibility to emergency physicians. In accordance with the literature, it is shown in our case report that bedside ultrasound performed by emergency physicians is beneficial in accelerating the diagnosis process.<sup>(7)</sup>

## **Conclusion**

In this case report, two adolescent male patients who presented with a similar clinical presentation are discussed. Both patients applied to the emergency department during non-working hours when the radiologist was not available. The diagnosis of both patients was made by the patient's history and physical examination findings supported by the absence of testicular blood flow viewed with the bedside color Doppler scrotal ultrasound performed by the emergency medicine specialist. The diagnosis was confirmed after surgical intervention in the patients. Due to testicular necrosis in the patient who applied approximately 48 hours after the onset of the complaints, orchiectomy was performed. However, the testicular vitality was successfully preserved in the patient who was operated three hours after the onset of the complaint.

As can be seen from the case examples we have presented, early diagnosis and treatment of testicular torsion are of vital importance for the preservation of testicular vitality. Bedside ultrasonography done by emergency medicine specialists, especially in health institutions that do not have on-duty radiology specialists, is of great importance in the early diagnosis of testicular torsion and in reducing morbidity, as in most emergencies.

## References

- 1- García-Fernández, Gustavo, Alberto Bravo-Hernández, and Raúl Bautista-Cruz. "Testicular torsion: A case report." *Cirugía y Cirujanos (English Edition)* 85.5 (2017): 432-435.
- 2- Sharp, Victoria J., Kathleen Kieran, and Angela M. Arlen. "Testicular torsion: diagnosis, evaluation, and management." *American family physician* 88.12 (2013): 835-840.
- 3- Srinivasan, Arun K., et al. "Climatic conditions and the risk of testicular torsion in adolescent males." *The Journal of urology* 178.6 (2007): 2585-2588.
- 4- Holcomb Jr, George. "Testicular torsion: Late results with special regard to fertility and endocrine function: G. Bartsch, S. Frank, H. Marberger, et al., J Urol 124: 375–378,(September), 1980." *Journal of Pediatric Surgery* 16.2 (1981): 218-219.
- 5- Barada, James H., Jeffrey L. Weingarten, and William J. Cromie. "Testicular salvage and age-related delay in the presentation of testicular torsion." *The Journal of urology* 142.3 (1989): 746-748.
- 6- Baker, Linda A., et al. "An analysis of clinical outcomes using color Doppler testicular ultrasound for testicular torsion." *Pediatrics* 105.3 (2000): 604-607.
- 7- Blaivas, Michael, Mark Batts, and Michael Lambert. "Ultrasonographic diagnosis of testicular torsion by emergency physicians." *The American journal of emergency medicine* 18.2 (2000): 198-200.



# A CASE REPORT TO DEVELOP MYOCLONUS WITH THE USE OF FIRST DOSE GABAPENTIN

Dilek Atik<sup>1\*</sup>, Nuray Kılıç<sup>2</sup>, Fulya Köse<sup>1</sup>

<sup>1</sup>Karamanoğlu Mehmetbey University, Karaman

<sup>2</sup>Manisa Alasehir Hospital, Manisa

## ABSTRACT

Gabapentin (GBP) has anticonvulsant and analgesic properties and is used in many ailments associated with chronic pain and neuropathic pain, mostly diabetes mellitus. In a study, they stated the incidence of myoclonus as 0.1% in epilepsy patients using Gabapentin.

**Case Report:** A 39-year-old female patient was started by Gabapentin neurosurgery for pain in the legs due to herniated L3-4 disc in the lower back. The first dose of use to relieve paraesthesia was manifested in the form of twitching and subsequent contraction in the nasolabial groove of the left rim of the patient, who started using 300 mg/day gabapentin. In our case, the patient did not have any cerebral disease such as encephalopathy or epilepsy, and his kidney functions were also normal. We think that myoclonus may develop due to GBP in the first dose of treatment, and the severity of myoclonus may increase after dose increase, and it should be kept in mind that care should be taken in treatment arrangements.

**Keywords:** Gabapentin; myoclonus; Gabapentin side effect

## Introduction

Gabapentin (GBP), which has anticonvulsant and analgesic properties, is mostly used in many ailments associated with chronic pain and neuropathic pain, such as diabetes mellitus(1,2). In addition to the effectiveness of GBP in chronic pain, oral GBP has been shown to be effective in reducing pain, especially in lumbar disc herniation (3). However, several studies have reported myoclonus associated with GBP use in patients with epilepsy, encephalopathy, impaired renal function, or end-stage renal disease (ESRD) (4,5). In a previous study, they reported the incidence of myoclonus as 0.1% in epilepsy patients using Gabapentin(6).

Here, we present a patient who developed myoclonus after the first dose of Gabapentin, who had no previous disease.

## Case Report

A 39-year-old female patient was started by Gabapentin neurosurgery for pain in the legs due to herniated L3-4 disc in the lower back. The first dose of use to relieve paraesthesia was manifested in the form of twitching and subsequent contraction in the nasolabial groove of the



left rim of the patient, who started using 300 mg/day gabapentin. His mental status was normal, and his Glasgow coma scale was 15. His blood pressure was 120/80 mmHg, his pulse was 84/min, his respiratory rate was 20/min, and his temperature was 36.8 C. In his examination, light reflex was bilaterally positive and there was no neck stiffness. Conjugated eye movements were present. Left rim was asymmetrical due to retraction. Cerebellar tests muscle strength examinations were normal. Deep tendon reflexes and Babinski test were normal. In the patient's examinations, no abnormality was detected in the brain computerized tomography, blood cell count, biochemical and urinalysis. The patient was started on hydration and nasal O<sub>2</sub>. The patient's symptoms regressed after hydration and follow-up, and no additional treatment was required.

## **Discussion**

It can be called a drug that has side effects and can cause movement disorders in people using gabapentin (GBP), even at treatment doses (7). These side effects may develop gradually in the days following the start of the drug and may improve immediately after the drug is discontinued (8). Asconape et al. Myoclonus was observed in approximately 12% of 104 epilepsy patients treated with GBP and was not intervened because their myoclonus was thin and did not affect their daily activities. In our case, no treatment was given other than hydration, since myoclonus did not affect the patient's daily activities. Again, Asconape et al. emphasize that it may develop in the presence of brain damage or encephalopathy, especially in myoclonus risk factors (6). It is emphasized that especially myoclonus may develop with the interaction of GBP with other drugs. Any drug used with GBP may increase the potential for myoclonus development (9). Asconape et al. He emphasizes that more severe myoclonus may be seen after initiation of GBP or increasing the dosage (6).

In our case, the patient did not have any cerebral disease such as encephalopathy or epilepsy, and his kidney functions were also normal. We think that myoclonus may develop due to GBP in the first dose of treatment, and the severity of myoclonus may increase after dose increase, and it should be kept in mind that care should be taken in treatment arrangements.

## **References**

1. Laird MA, Gidal BE. Use of gabapentin in the treatment of neuropathic pain. *Ann Pharmacother.* 2000;34:802–807.
2. Wiffen PJ, McQuay HJ, Edwards JE, Moore RA. Gabapentin for acute and chronic pain. *Cochrane Database Syst Rev.* 2005;20:CD005452.
3. Pandey CK, Navkar DV, Giri PJ, Raza M, Behari S, Singh RB, et al. Evaluation of the optimal preemptive dose of gabapentin for postoperative pain relief after lumbar discectomy : a randomized, double-blind, placebo-controlled study. *J Neurosurg Anesthesiol.* 2005;17:65–68.

4. Holtkamp M, Halle A, Meierkord H, Masuhr F. Gabapentin-induced severe myoclonus in a patient with impaired renal function. *J Neurol.* 2006;253:382–383.
5. Scullin P, Sheahan P, Sheila K. Myoclonic jerks associated with gabapentin. *Palliat Med.* 2003;17:717–718.
6. Asconape J, Diedrich A, DellaBadia J. Myoclonus associated with the use of gabapentin. *Epilepsia.* 2000;41:479–481.
7. Zhang C, Glenn DG, Bell WL, O'Donovan CA. Gabapentin-induced myoclonus in end-stage renal disease. *Epilepsia.* 2005;46:156–158.
8. Cho KT, Hong SK. Myoclonus induced by the use of gabapentin. *J Korean Neurosurg Soc.* 2008;43(5):237-238.
9. Eckhardt K, Ammon S, Hofmann U, Riebe A, Gugeler N, Mikus G. Gabapentin enhances the analgesic effect of morphine in healthy volunteers. *Anesth Analg.* 2000;91:185–191.



# NEW DIAGNOSIS OF HEPATIC HYDATID CYST PRESENTING WITH DYSPNEA

Mert Rusen GULSEN<sup>1\*</sup>, Fahrnisa Meryem Betul EROL<sup>2</sup>, Feride GUNEC<sup>3</sup>, Ramazan UNAL<sup>1</sup>

<sup>1</sup>Republic of Turkey Ministry of Health Balikesir Provincial Health Directorate Edremit State Hospital, Emergency Department, Balikesir, Turkey

<sup>2</sup>Balikesir University Faculty of Medicine, Department of Emergency Medicine, Balikesir, Turkey

<sup>3</sup>Republic of Turkey Ministry of Health Balikesir Provincial Health Directorate Edremit State Hospital, Department of Thoracic Surgery, Balikesir, Turkey

\*Corresponding author

## ABSTRACT

Hydatid cyst is a parasitic disease, which is transmitted to humans mostly through dog feces and frequently seen in countries where agriculture and animal husbandry are common, caused by *Echinococcus Granulosus*. Hydatid cysts are frequently localized in the liver and the lungs. The disease may have different clinical course and cause various complications depending on location and size of the cysts.

In this article, we aimed to present a 72-year-old male, who was newly diagnosed with hepatic hydatid cyst with pulmonary fistulization, which was surgically drained.

**Keywords:** hydatid disease, pulmonary fistulization, dyspnea

## Introduction

Hydatid disease (HD) is caused by the parasite named *Echinococcus*. HD can occur almost anywhere in the body and demonstrates a variety of imaging features that vary according to growth stage, associated complications, and affected tissue.<sup>1</sup> In the early stages of the disease, when the cysts are small, the patient can be asymptomatic for many years. As the cysts grow, symptoms may occur depending on the region and the pressure it causes. Although cysts are most commonly seen in the liver and lungs<sup>2</sup>, concurrent involvement is rare (4% to 25% of patients with HD<sup>3</sup>). Pulmonary involvement may cause respiratory distress, cough, hemoptysis, and chest pain<sup>4</sup>.

In this report, we present a patient who got a new diagnosis of hydatid cyst in the liver with pulmonary fistulization.

## CASE

A 72-year-old male was admitted to the emergency room with new onset of chills, cough, dyspnea, and sharp chest pain. His medical history was unremarkable. Vital signs were as follows: Heart rate: 88/min, Respiratory rate: 17/min, Oxygen saturation: 95%, Fever: 38.1°C. Physical examination findings were unremarkable. Laboratory values were as follows: White Blood Cell Count: 15.000/ $\mu$ L, Neutrophil Count: 12.600/ $\mu$ L, C-Reactive Protein: 183,5 mg/L (reference range: 0 – 5 mg/L), Total Bilirubin: 1,29 mg/dL, Direct Bilirubin: 0,57 mg/dL, and Blood Glucose: 557 mg/dL.

In the chest and abdominal computed tomography (CT); there were multiple calcific nodules (3.6cm\*4.0cm, 3.6cm\*3.0cm, 6.2cm\*5.5cm) (**Figure 1**) containing air, the largest of which was at the

level of liver segment 7-8, opening into the right hemithorax (**Figure 2**). On the following day, the patient was operated jointly with thoracic and general surgeons. The liver cyst was drained and wedge resection was performed on the area that was fistulized to the lung parenchyma. The patient was discharged on the fourth postoperative day.

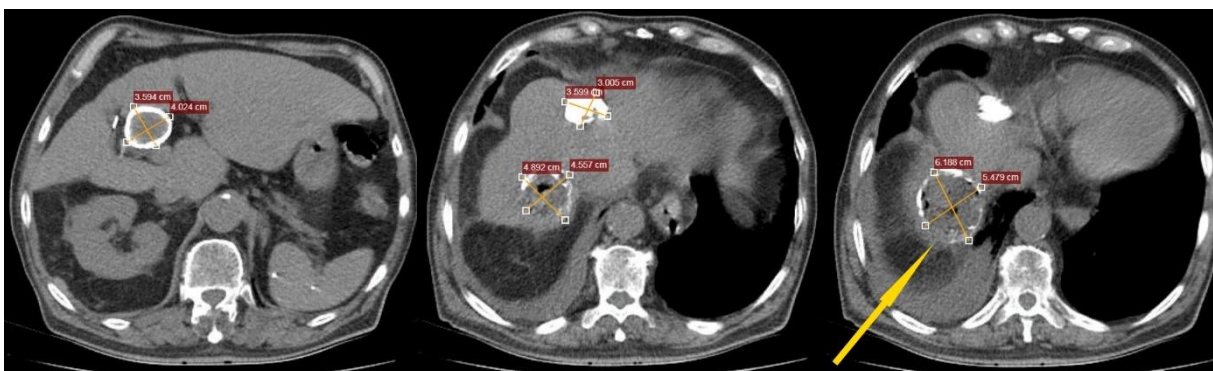
## Conclusion

More than 50% of patients with hydatid cysts in their liver may remain asymptomatic throughout their lives<sup>5</sup>. This group of patients may apply to the emergency department with acute complaints. In patients who describe fever, shortness of breath, and pleuritic chest pain, HD can be diagnosed by performing chest and abdominal CT.

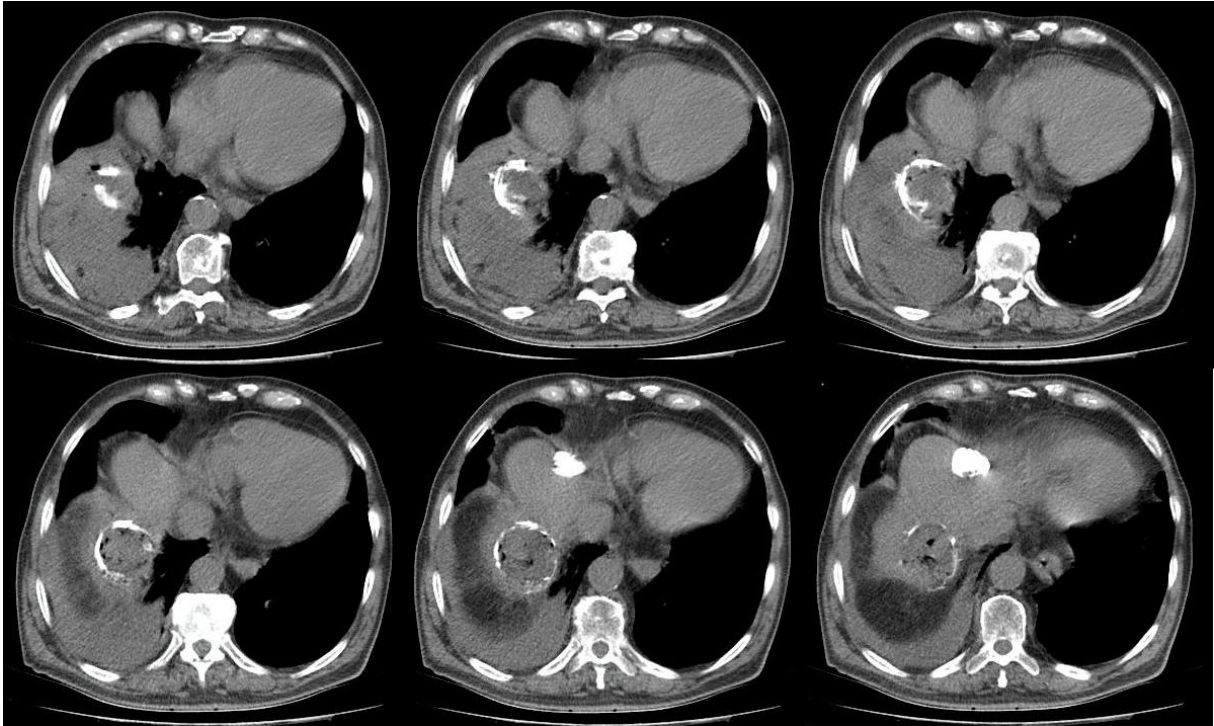
## References

1. Polat P, Kantarci M, Alper F, Suma S, Koruyucu MB, & Okur A. Hydatid disease from head to toe. *Radiographics*, 2003;23(2), 475-494.
2. Sachar S, Goyal S, Goyal S, et al. Uncommon locations and presentations of hydatid cyst. *Ann Med Health Sci Res* 2014;4:447–52.
3. Aghajanzadeh M, Safarpour F, Amani H, et al. one-stage procedure for lung and liver hydatid cysts. *Asian Cardiovasc Thorac Ann* 2008;16:392–5
4. Toleti S, Subbarao M, Dwarabu P. Hydatid disease of the lung presenting with hemoptysis and simulating a lung abscess. *Trop Parasitol* 2012;2:69–70
5. Larrieu E, Frider B, del Carpio M, et al. Asymptomatic carriers of hydatidosis: epidemiology, diagnosis, and treatment. *Pan American Journal of Public Health* 2000;8(4):250-256

## Figures



**Figure 1:** There are multiple calcific nodules consistent with hydatid cysts, which are 3.6cm\*4.0cm, 3.6cm\*3.0cm, and 6.2cm\*5.5cm in size, containing millimetric air, the largest of which was at the level of liver segment 7-8. The yellow arrow is showing the fistulized region.



**Figure 2:** It is seen that the hydatid cyst, located in the liver segment 7-8, extending from the level of the hepatic dome to the right hemidiaphragm and right hemithorax. There is air in and adjacent to it. It is fistulized into the right hemithorax.



# ATYPICAL ABDOMINAL PAIN IN CHILDREN; CHOLELITHIASIS

Nuray Kılıç<sup>1\*</sup>, Dilek Atik<sup>2</sup>

<sup>1</sup>Manisa Alaşehir Hospital, Manisa

<sup>2</sup>Karamanoğlu Mehmetbey University, Karaman

## ABSTRACT

The gallbladder is a pear-shaped sac-shaped organ that is 8-10 cm long and 4-5 cm wide in adults. The gallbladder stores bile, which is constantly secreted by the liver. Gallbladder pathologies have an important place in patients experiencing abdominal pain symptoms. Abdominal pain in children requires a multidisciplinary approach and treatment just like adults. However, it is not as common to encounter cholelithiasis in pediatric patients as in adults.

**Case report:** A 3-year-old boy was brought to the emergency room by his family with complaints of abdominal pain and occasional vomiting for 2-3 days. WBC 12.33, CRP 3.44, ALT 11, AST 31, total bilirubin 0.40, GGT 18, creatinine 0.26, and no obvious pathology was detected in the laboratory tests performed. Computed tomography was performed to detect acute intra-abdominal pathology for the patient who was not relieved by the treatment. A diagnosis of cholelithiasis was made.

Although rare, cholelithiasis should be kept in mind by emergency physicians in children who come to the emergency department with the complaint of abdominal pain, and their approach should be directed towards this. At the same time, more studies are needed to eliminate the deficiencies related to gallbladder stone management and treatment in children.

**Keywords:** cholelithiasis; Gallbladder risk factors in children; abdominal pain

## Introduction

The gallbladder is a pear-shaped sac-shaped organ that is 8-10 cm long and 4-5 cm wide in adults. The gallbladder stores bile, which is constantly secreted by the liver. Gallbladder pathologies have an important place in patients experiencing abdominal pain symptoms. Among them, gallbladder stones are the most common of all gastrointestinal system diseases, and therefore abdominal pain is one of the most common reasons for applying to the emergency department.

Abdominal pain in children requires a multidisciplinary approach and treatment just like adults. However, it is not as common to encounter cholelithiasis in pediatric patients as in adults. In this case, we aimed to describe a case of gallstones in a 3-year-old boy who applied to the emergency department with the complaint of abdominal pain.



## Case Report

A 3-year-old boy was brought to the emergency room by his family with complaints of abdominal pain and occasional vomiting for 2-3 days. The child's vital signs in the emergency room were stable. In the physical examination of the child without fever, there was widespread rebound in the right lower and upper quadrants of the abdomen. Thereupon, blood, biochemistry and urine tests were requested. WBC 12.33, CRP 3.44, ALT 11, AST 31, total bilirubin 0.40, GGT 18, creatinine 0.26, and no obvious pathology was detected in the laboratory tests performed. However, the patient was started on symptomatic treatment. Computed tomography was performed to detect acute intra-abdominal pathology for the patient who was not relieved by the treatment. We encountered a very surprising result for emergency physicians. Millimetric stones in the gallbladder of a 3-year-old male patient were not very common. Upon this situation, the patient was consulted to the pediatric surgeon. Since the bilirubin and LFT values of the patient were within the normal range, it was observed that he was relieved after the analgesic treatment. Our patient was discharged from the emergency room with the recommendation of pediatric surgery outpatient clinic control.

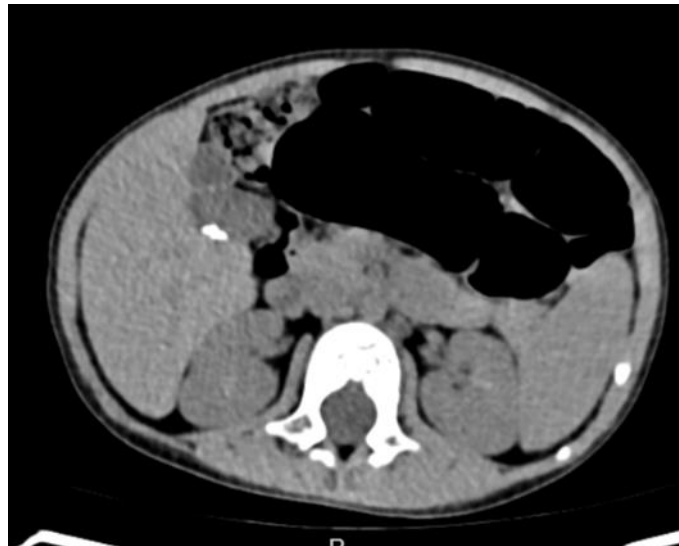

Figure 1. The image of the patient's gallbladder on computed tomography

## Discussion

There are not enough studies yet on gallstones in the pediatric age group compared to adults. Despite this, the incidence of childhood gallbladder diseases has been significantly increased in the last 20 years. It is seen as the most prominent factor in this increase due to the widespread use of ultrasonography, especially in emergency services. The uneasiness it creates in children and the low pain threshold have become an important health problem (1). Studies have shown that risk factors for gallbladder in children include female gender, genetics, hemolytic diseases, hepatobiliary diseases, cystic fibrosis, cholestasis, total parenteral nutrition, hypothyroidism, use of certain drugs such as infection, ileal disease or ileal resection, hyperlipidemia, diabetes cephalosporins and obesity have been reported. (2, 3).

The treatment of gallstones in children is still controversial. The treatment of gallstones diagnosed as asymptomatic is not clear. In such cases, the wait-see approach is prioritized. Despite this, cholecystectomy is recommended for patients with hemolytic disease, even if they are asymptomatic(4).

In studies, it has been observed that millimetric gallstones are poured out of the bile ducts in children compared to adults, and therefore cause pancreatitis in children (5). Although rare, cholelithiasis should be kept in mind by emergency physicians in children who come to the emergency department with the complaint of abdominal pain, and their approach should be directed towards this. At the same time, more studies are needed to eliminate the deficiencies related to gallbladder stone management and treatment in children.

### **References**

1. Aydın Ç. Çocuklarda safra kesesi taşı: Klinik ve cerrahi bulguların değerlendirilmesi. 2016.
2. Wesdorp I, Bosman D, de Graaff A, Aronson D, van der Blij F, Taminiou J. Clinical presentations and predisposing factors of cholelithiasis and sludge in children. *Journal of pediatric gastroenterology and nutrition*. 2000;31(4):411-7.
3. Tannuri ACA, Leal AJG, Velhote MCP, Gonçaves MEP, Tannuri U. Management of gallstone disease in children: a new protocol based on the experience of a single center. *Journal of pediatric surgery*. 2012;47(11):2033-8.
4. Tamary H, Aviner S, Freud E, Miskin H, Krasnov T, Schwarz M, et al. High incidence of early cholelithiasis detected by ultrasonography in children and young adults with hereditary spherocytosis. *Journal of pediatric hematology/oncology*. 2003;25(12):952-4.
5. Falchetti D, Ubertazzi M, Torri F, Salucci P, Alberti D, Caccia G. Endoscopic cure of pancreatic pseudocyst in a child. *Journal of pediatric gastroenterology and nutrition*. 1998;27(4):446-8.