

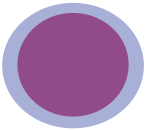

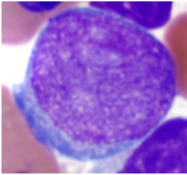
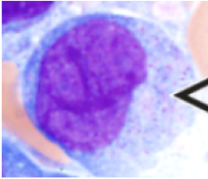
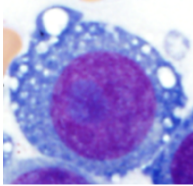
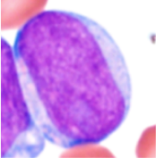
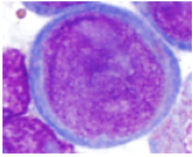
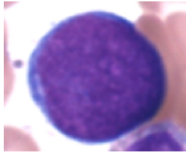
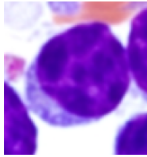
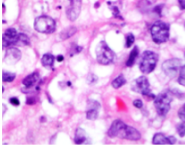


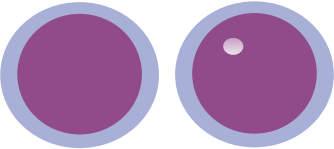






Size  Use as a reference normal lymphocytes	Small 	Medium 	Large 		
Nuclear contours	Regular 	Irregular 	Round 		
Chromatin	Dispersed  "Ground glass"	Reticular 	Finely reticular  "Velvet" (e.g. Hematogones)	Clumped (condensed)  (e.g. CLL/SLL)	Vesicular  "Small bubbles in the nuclei" For histologic sections
Nucleoli	Prominent 	Distinct 	Variably distinct 	Inconspicuous 	
Amount of cytoplasm	Scant 	Small 	Moderate 	Abundant 