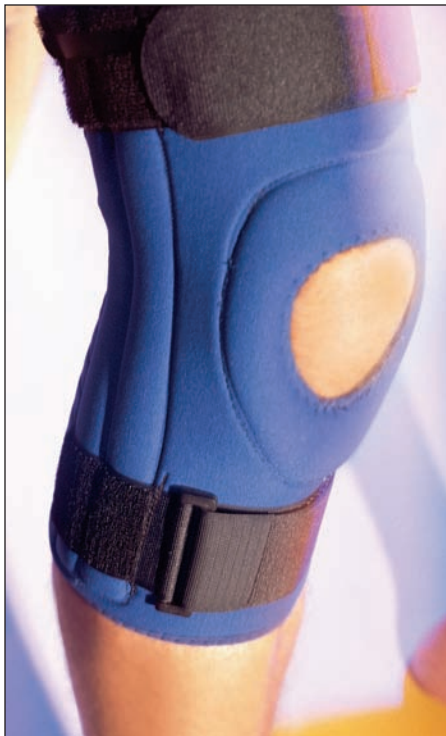



# CHRONIC OVERUSE SPORTS INJURIES IN THE ADOLESCENT/PEDIATRIC POPULATION

Injuries occur when cumulative forces exceed the tissue's ability to withstand either isolated macrotrauma or repetitive microtrauma—so properly identifying and treating is key to preventing further injury and even possibly reversing any damage.

By Elmer “El” Pinzon, MD, MPH, FABPMR, FABPM; and Mick Larrabee, PT, MS, SCS, EMT, CSCS

**T**he evaluation and management of chronic overuse sports/athletic injuries is one of the most pervasive concerns in sports medicine today. Overuse sports injuries outnumber acute, instantaneous injuries in almost every athletic activity. Because overuse sports injuries are not instantly disabling, they attract less medical attention than those that cause an acute and obvious loss of function. Therefore, their frequency of occurrence is almost always underestimated in surveys of athletic injuries. The treatment of overuse sports injuries is made difficult by various factors. Due to their insidious onset, they are commonly initially ignored and, when athletes actually present for treatment, the injuries are well established and more difficult to manage successfully. Additionally, these injuries seem less serious to the athlete and makes it difficult to convince the athlete of the importance of intensive treatment for correction.

Physicians' attitudes toward athletes with chronic overuse sports injuries are often inappropriate and frequently result in the athlete seeking inappropriate treatment options. All too often the athlete-patient is told: “If you only abstain from performing your sport, the injury will

resolve.” The athlete-patient has sought treatment not because of the injury, but rather because they are unable to continue the athletic participation. Therefore, the ability to return the athlete to functional activity is as much part of the treatment as the alleviation of the symptoms.

This article highlights a few of the most common injuries seen in athletics with a focus on the overuse/repetitive strain injury. It is important to note that with most athletes, up to 60% of the “overuse” type injuries are related to training errors. Interaction with the coach/trainer is critical in solving this problem. Pain will get the athlete into the clinic but the tricky part can be figuring out exactly what is causing the pain. The old acronym PRICE (Prevention, Rest, Ice, Compression, & Elevation) along with NSAIDs can do a very nice job of decreasing/eliminating the chemical pain associated with the inflammatory response. However, the real challenge is to identify the underlying dysfunction.

## Background

Overuse injuries are almost always a result of change in three general areas: the athlete, the environment, or the activities. Identifying these changes requires

patience, precision in history-taking, and a great understanding of the demands of the specific sporting activity. The most common cause of overuse athletic injuries is continued athletic participation despite the presence of symptoms associated with another injury (e.g., pitcher who continues to throw despite persistent elbow tendonitis). Continued participation with an existing injury also occurs as the result of inadequate rehabilitation. Some overuse dysfunctions are the result of normal physiological changes such as rapid growth spurts in which musculotendinous flexibility often decreases and indirectly causes tendonitis (e.g., Osgood-Schlatter knee syndrome). Environmental alterations may occur in the athlete's personal environment (e.g., equipment and clothing) or the more global sports environment (e.g., running hills in a training regiment previously limited to running flat surfaces). Advancing to a higher level of athletic proficiency involves both quality and quantity of workouts. Merely increasing workout time in an abrupt manner can result in overuse athletic injuries, especially when an athlete attempts to perfect a single, isolated skill. It should be obvious that discovering the changes that cause overuse problems requires an

emphasis in history-taking—more so than the diagnosis and management of acute injuries. Ultimately, the physician's role becomes one of reinforcing and reminding the athlete to identify the appropriate changes to be made in their regimen.

The prevention of recurrences of overuse injuries is the most important aspect of managing overuse injuries. Generally, overuse injuries involve bone, ligaments or, in a majority of cases, musculotendinous structures. Muscle fatigue can occur because of relative lack of either strength or endurance. Then when the muscle unit tightens, it may undergo physiological structural damage (i.e., hemorrhage or localized edema). The muscle then undergoes spasms and shortening, which indirectly lead to weakness so that subsequent re-injury occurs with less provocation. Thus, the "overuse-tightness-pain-disuse-weakness-easier-overuse cycle" continues until broken by active treatment interventions.<sup>1-5</sup>

As society's emphasis on continued physical activity and athletics throughout the lifespan has increased, so have the knowledge and skill required by the community of health care providers involved in managing the related injuries. It is essential for all sports medicine providers to realize that a team approach (physicians, physical therapists, athletic trainers, coaches, etc.)—that takes advantage of the collective knowledge, talent, and expertise of all these specialists in a collaborative effort—affords the athlete the optimal conditions for successful return to sport.

A thorough physical exam, biomechanical assessment, and functional movement analysis can all provide great insight into how the body moves and reveal any joint dysfunction and/or muscle imbalances. A muscle imbalance leads to changes in the length-tension relationships of involved muscles. This change in force coupling decreases neuromuscular efficiency and leads to more rapid fatigue. As the muscles fatigue, there is often a biomechanical compensation which may overload tissues not used to that new stress. Eventually, breakdown must occur and the athlete enters the cumulative injury cycle of pain.

Special considerations and unique aspects of musculoskeletal conditions in children should be revealed. Musculoskeletal growth may reveal significant progression in treatments. The

underlying principle is that the skeletal system grows and the musculoskeletal system needs to "catch up." With muscle imbalance plus growth, a possible result may be muscle contracture and, possibly, bony deformities. As children grow, their coordination and psyche are developing and therefore competitive sports may require an adaptation of the sport to the age/size of the growing child. While overuse syndromes in adults may result from microscopic tears or ruptures in the musculoskeletal system, in children, the bone-tendon junction is the primary weak point that indirectly leads to different types of overuse syndromes. For example, Osgood-Schlatter disease results from microscopic avulsion fractures at the insertion of the patellar tendon during adolescence when the child is active and developing and when the relatively weak secondary ossification center of the proximal tibia is developing.<sup>3</sup>

#### Clinical Assessment, Diagnostic Evaluation, and Treatment Options

With the heightened interest in personal fitness and athletic participation, the physician is expected to see a variety of sports-related injuries and must be able to recognize these conditions in order to institute prompt and proper management. A thorough history, physical examination, radiographic studies, laboratory studies and, occasionally, further imaging studies are essential to establish and confirm the appropriate diagnosis. The mechanism of injury must be established in order to proceed on the correct path. Symptoms must be evaluated in detail and categorized for initial stimulus, location, intensity, and characterization of the pain pattern (the major symptom in overuse injuries). The primary purpose of the physical examination is to precisely define the anatomical structures involved in the overuse injury. With musculoskeletal injuries, the easiest way to localize the maximally painful area is to have the athlete assume the position of maximal discomfort and then to point out the most painful location. This usually involves stretching the involved muscle. Radiographic and other diagnostic testing are occasionally used to evaluate and often exclude other sources of more serious pathology but should never be used initially to make a diagnosis. Instead, such diagnostic testing should be used as a supplement to the thorough history and physical examination.<sup>1-6</sup>

Although there exist an indefinite and varied number of chronic overuse sports injuries, we have chosen a select number that we've found to be most prevalent and most often-treated syndromes to address in the following sections.

#### Calcaneal Apophysitis (Sever's Syndrome)

*History/Pathogenesis:* One of the most common complaints in the young athlete is posterior heel pain. Lack of adequate ankle dorsiflexion in a running or jumping athlete is always causative. There is a high incidence of overpronation, but pronation/eversion is likely to be compensation for lack of true dorsiflexion. This condition is due to overuse and repetitive microtrauma from pull on the calcaneal apophysis by the Achilles tendon. This process resolves when the apophysis fuses to the main body of the calcaneus—by 9 years old in girls and 11 years old in boys. Athletes who wear soccer-type, cleated, hard-soled shoes are at greater risk because the shoes have four cleats at the heel and nine at the sole. This syndrome is characterized by pain in the posterior aspect of the heel, especially after sports activities in prepubertal children.<sup>1-3,6-10</sup>

*Signs/Symptoms:* Patients have posterior heel pain and an antalgic limp, especially with activity. There is hypertrophy of the adductor brevis muscle and, when asked to dorsiflex the ankle, the athlete will evert/pronate.

*Physical Exam:* Examination shows tenderness, especially with compression, at the junction of the Achilles tendon and the calcaneal physis and/or at the medial plantar fascia attachment.

*Diagnostic Tests:* If indicated, evaluate with baseline x-rays, MRI, bonescan, or ultrasound. Radiographs may occasionally, but not routinely, reveal advanced Sever's calcaneal apophysitis or a calcaneal spur, especially with a lateral view. MRI imaging is obtained for chronic cases of Achilles tendonitis to detect degeneration.

*Differential Diagnoses:* Achilles tendonitis, infection, or tumor.

*Acute Treatment:* Relative rest; analgesia through appropriate doses of NSAIDs and with physical modalities such as ice, ultrasound, iontophoresis, phonophoresis, topical anesthetic skin refrigerant (e.g., Gebauer's Spray and Stretch®) and electrical stimulation (e.g., RS Medical's

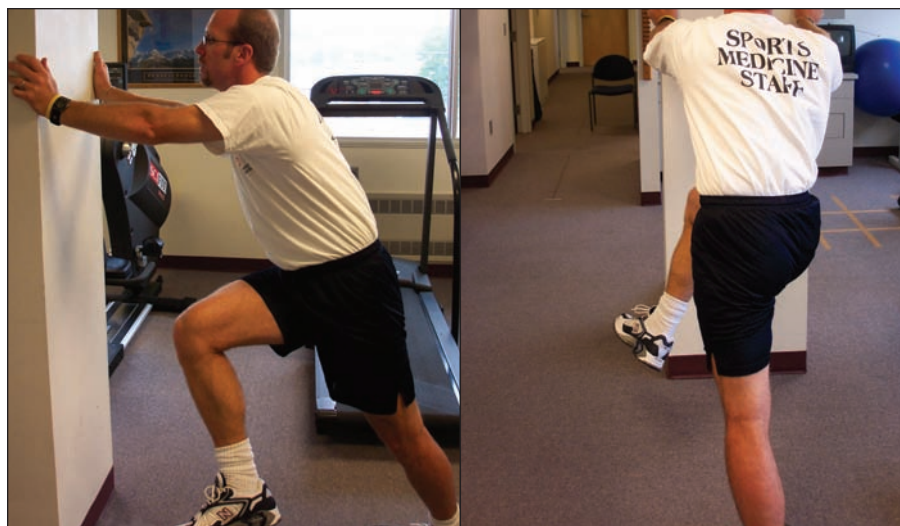

FIGURE 1. Multiplanar calf stretch with use of “tristretch.” (All photos courtesy of M. Larrabee)

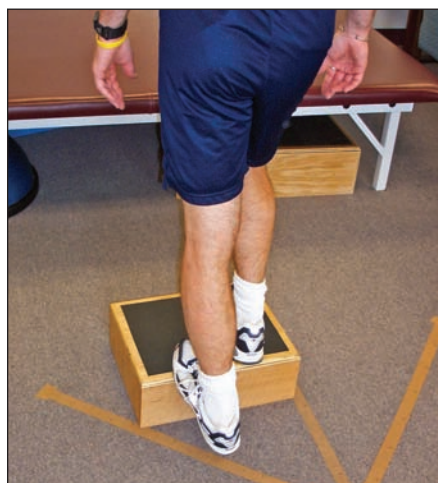

FIGURE 2. Plantar fascial stretch.

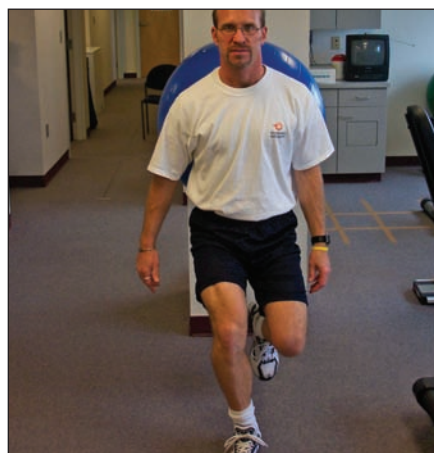

FIGURE 3. Single-leg wall squat with “thera-band ball.”

Sequential Stimulator or Transcutaneous Stimulator).

**Long-term Treatment/Rehab:** Treatment includes short-term modification or restriction of the precipitating activity. Extensive Achilles stretching with the heel locked in mild inversion is the mainstay of treatment—with stretching several times per day (see Figures 1 and 2). Physical therapy is prescribed to ensure proper stretching and occasionally administer ultrasound for tendonitis/fasciitis. Shoe modifications including heel lifts or heel cushions and Achilles tendon stretching is crucial. Neither steroid injections nor surgery is indicated. Running and jumping is permitted as symptoms improve.<sup>3,9-18</sup>

### Osgood-Schlatter Syndrome

**History/Pathogenesis:** This condition results from repetitive injury and small avul-

sion injuries at the bone-tendon junction where the patellar tendon inserts into the secondary ossification center of the tibial tuberosity or, most likely, a stress fracture of the apophyseal cartilage from traction forces. The onset of the disease during early adolescence (usually 12-13 years old in males) coincides with development of this secondary ossification center, which is a weak link to repetitive quadriceps contraction. Primarily traumatic or overuse events explain the two to three times incidence in males and five times greater incidence in adolescents involved in sports, especially with repetitive running or jumping.<sup>1-3,6-10</sup>

**Signs/Symptoms:** Patients report pain exacerbated by running, jumping and kneeling activities. Patients also exhibit pain with prolonged sitting with knees flexed. Symptoms may have occurred

on and off in the past. There tends to be relatively weak quadriceps and tight hamstrings for the athletic demands required.

**Physical Exam:** Examination shows tenderness and swelling at the insertion of the patellar tendon in the tibial tubercle, with the tibial tubercles revealing enlargement usually with associated tenderness to palpation. The hamstrings are usually tight and quadriceps are relatively weak. The knee motion is usually not restricted but kneeling is painful during the acute phase. The patellofemoral joint is usually stable.

**Diagnostic Tests:** If indicated, evaluate with baseline x-rays, MRI, bonescan, or ultrasound. Radiographs may reveal soft tissue swelling. Occasionally small spicules of heterotopic ossification may be seen anterior to the tibial tuberosity. MRI imaging is obtained for chronic cases to detect advanced degeneration. As the condition progresses, the more vertical portion of the tibial physis width increases and the apophysis becomes irregular or fragmented.

**Differential Diagnoses:** Sinding-Larsen-Johansson disease, infection, or neoplasm.

**Acute Treatment:** Intermittent ice after sporting activities, relative rest; analgesia through appropriate doses of NSAIDs and with physical modalities such as ice, ultrasound, iontophoresis, phonophoresis, topical anesthetic skin refrigerant, protective knee pad, and TENS electrical stimulation.

**Long-term Treatment/Rehab:** Treatment includes short-term modification or restriction of the precipitating activity. Extensive quadriceps and hamstring stretching is the mainstay of treatment—with stretching several times per day (see Figure 3). Physical therapy is prescribed to ensure proper stretching and occasionally administer ultrasound. Immobilization is needed for severe/recalcitrant cases, especially with the use of a prefabricated knee immobilizer. Neither steroid injections nor surgery is indicated—with rare exceptions for patients who have persistent symptoms after growth is completed. The young athlete may have to stop training for up to two to three months, and may need to refrain from fully effective training for up to six to seven months. Running and jumping is permitted as symptoms improve.<sup>3,9-18</sup>




FIGURE 4. Side-lying hip abduction.

### Iliotibial Band Friction Syndrome (ITBFS)

*History/Pathogenesis:* ITBFS is an inflammatory, nontraumatic overuse injury of the knee predominantly affecting long-distance runners—especially with excessive downhill running—or bicyclists who are not conditioned for longer rides. Tendonitis or bursitis occurs when the posterior edge of the ITB impinges against the lateral femoral epicondyle. This repeated trauma to the soft tissues in that area creates swelling and pain that is aggravated by further knee motion. Pain occurs after foot strike in the gait cycle, usually at about 30 degrees of knee flexion. As the knee flexes, the ITB moves posteriorly and rubs over the lateral femoral epicondyle causing inflammation and pain after prolonged activity. ITBFS is the second most common running-related injury, accounting for 12% of all overuse injuries in the running population. It can be exacerbated in a runner with a varus knee deformity, worn-out running shoes, or in increased foot supination, which increases lateral knee force. In the cyclist, the foot position on the pedals and raising the height of the seat to decrease the degree of knee flexion should be evaluated.<sup>1,3,6-8</sup>

*Signs/Symptoms:* Lateral knee pain made worse by running, pain with ascending and descending stairs, or stiff-legged walking in advanced cases.

*Physical Exam:* Tenderness to lateral femoral condyle and distal ITB. Possible leg length discrepancy, increased subtalar joint pronation, SIJ dysfunction, increased Q angle, positive Ober's test, hip weakness (particularly gluteus medius), and poor neuro-muscular control during single leg activities (squat and/or step down). Check footwear and appropriateness for foot type.

*Diagnostic Tests:* If indicated, evaluate with baseline x-rays, MRI, bonescan, or ultrasound.

*Differential Diagnoses:* Lateral meniscal/collateral ligament injury, patellofem-

oral syndrome, occult lesion, or stress fracture.

*Acute Treatment:* Relative rest; analgesia through appropriate doses of NSAIDs and with physical modalities such as ice, ultrasound, iontophoresis, phonophoresis, topical anesthetic skin refrigerant and electrical stimulation.

*Long-term Treatment/Rehab:* Thorough lower quarter examination to identify the cause and help formulate the treatment plan. For runners, it's a good idea to alternate running on different sides of road or changing direction on the track. Corrective exercise for the hip musculature (emphasis on gluteus medius; see Figure 4), manual therapy (to break up fibrotic adhesions, scar tissue, and trigger points), stretching (hip flexors, hamstrings, calves, and ITB), self myofascial release techniques, and orthotic intervention (if deemed appropriate).<sup>11-18</sup>

### Sports Injuries of the Elbow in Children

*History/Pathogenesis:* Excessive throwing and the subsequent abduction/valgus stress causes most elbow injuries. The injury occurs at either the medial (tension) or lateral (compression) side of the humerus. Medial injuries are either acute (avulsion fracture of the medial epicondyle) or chronic/gradual onset (traction apophysitis of the medial epicondyle; i.e., 'little league elbow'). This occurs usually in early/late cocking and is responsible for valgus stress that leads to medial/lateral injuries. Acceleration, deceleration and follow-through are responsible for anterior/posterior lesions. Lateral pathology is usually secondary to osteonecrosis of the capitellum. Panner disease occurs in children less than ten years old and with good prognosis. Osteochondritis dissecans (osteonecrosis of the capitellum in adolescents) has a cautious prognosis.<sup>1,3,6-10</sup>

*Signs/Symptoms:* The most common

history is aching pain over the involved elbow and is activity-related. Sudden, forceful pitch may cause avulsion of the medial epicondyle, with acute swelling/pain, especially in 9 to 12 year old children. Osteonecrosis of the capitellum may result in osteochondral loose body, which causes a "locking/catching" sensation.

*Physical Exam:* Examination shows tenderness and swelling at the insertion of the involved humeral condyle, with associated tenderness to palpation. Mild swelling and limitation in ROM of the elbow motion is present. Valgus stress may be painful and there may be valgus laxity as measured by palpable gapping.

*Diagnostic Tests:* If indicated, evaluate with baseline x-rays, MRI, bonescan, or ultrasound. AP/lateral radiographs of the elbow may reveal soft tissue swelling. Occasionally, small spicules of heterotopic ossification may be seen in the medial epicondyle (e.g., 'little league elbow') or irregularity/fragmentation of the capitellum. MRI imaging may be obtained to assess UCL integrity.

*Differential Diagnoses:* Ulnar neuritis, subluxing ulnar nerve, infection, or atypical neoplasm.

*Acute Treatment:* Resting the arm, with no throwing for three to six weeks, followed by rehabilitation to restore elbow motion and upper extremity strength. Intermittent ice after sporting activities, relative rest; analgesia through appropriate doses of NSAIDs and with physical modalities such as ice, ultrasound, iontophoresis, phonophoresis, topical anesthetic skin refrigerant, protective elbow pad, and electrical stimulation.

*Long-term Treatment/Rehab:* Treatment includes short-term modification or restriction of the precipitating activity. Extensive elbow flexor/extensor stretching is the mainstay of treatment—with stretching several times per day (see Figure 5 and 6). Physical therapy is prescribed to ensure proper stretching and occasionally administer ultrasound. Immobilization is occasionally needed for severe/recalcitrant cases. Neither steroid injections nor surgery is indicated—with rare exceptions for patients who have persistent symptoms after growth is completed. The young athlete may have to stop training for up to one to two months, and may need to refrain from fully effective training for up to two to three months. Throwing is permitted as symptoms improve.<sup>3,9-18</sup>



FIGURE 5. Forearm extensor strengthening.

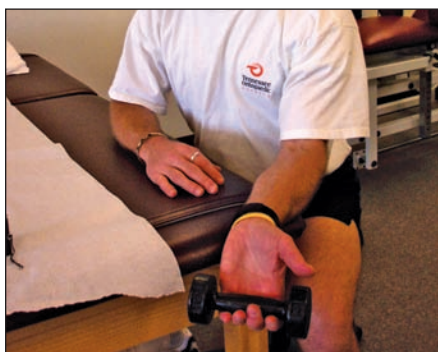


FIGURE 6. Forearm flexor strengthening.

### Elbow Pain—Lateral Epicondylitis

*History/Pathogenesis:* Injury of the forearm and wrist extensor muscles causing pain at the lateral epicondyle and extensor forearm at the elbow (i.e., ECRB). Usually occurs in the 4th decade of life and indicates a degenerative process in the tendon, aggravated by repetitive stress and muscular microtears. Commonly referred to as “tennis elbow” but also present in non-tennis players as well.<sup>1-3,6,7</sup>

*Signs/Symptoms:* Pain at lateral elbow, pain with wrist and forearm motions, pain with gripping objects (e.g., screwdriver, making fist, shaking hands). Pain radiates from dorsum of the forearm to the fingers.

*Physical Exam:* Localized tenderness just anterior and distal to the lateral epicondyle, pain/weakness to resisted wrist extension (especially with extended elbow) and/or middle finger extension. Pathoanatomic changes occur primarily in the ECRB and secondarily at the EDC. Important to rule out C-6/7 radiculopathy, especially with paresthesias.

*Diagnostic Tests:* If indicated, evaluate with baseline x-rays, MRI, ultrasound, or EMG.

*Differential Diagnoses:* medial epicondylitis, little league elbow, intraarticular

pathology or stress fracture, gout, cervical spine disease, posterior interosseous nerve entrapment.

*Acute Treatment:* Relative rest; equipment modifications (decrease racquet string tension for tennis player or improve ergonomics of workstation); analgesia through appropriate doses of NSAIDs, physical modalities such as ice, ultrasound, iontophoresis, phonophoresis; counterforce bracing and/or wrist splinting (especially at night); along with forearm stretching, and topical anesthetic skin refrigerant and electrical stimulation.

*Long-term Treatment/Rehab:* Activity modification (improve technique through local tennis pro or modify workstation), stretch tight musculature and strengthen weak musculature (see Figure 5).<sup>11-18</sup>

### Elbow Pain—Medial Epicondylitis

*History/Pathogenesis:* Injury of the forearm and wrist flexor/forearm pronator muscles causing pain to the medial elbow. Valgus stress lesion of the medial epicondylar physis; possible avulsion fracture. A catch-all phrase for “little-leaguer’s elbow” or “golfer’s elbow.” Can mimic Panner’s disease (osteochondritis and/or osteochondrosis of the capitellum).<sup>1-3,6,7</sup>

*Signs/Symptoms:* Pain in medial elbow accentuated during early and late cocking of throwing motion, pain with resisted wrist flexion, pronation, and forearm motions. Mild weakness is often noted for grasping activities. For pitchers, may notice a decrease in control of pitches.

*Physical Exam:* Look for increased carrying angle (greater than 10° in males and 15° in females), pain with point tenderness over the tip of the medial epicondyle extending distally one to two inches along the common flexor origin (usually PT and FCR), pain/weakness of wrist flexors and pronators with elbow extended, possible loss of full extension of elbow (flexion contracture consistent with avulsion fracture), assess for ulnar collateral ligament stability, pain/weakness with resisted wrist flexion.

*Diagnostic Tests:* If indicated, evaluate with baseline x-rays, MRI, ultrasound, or EMG.

*Differential Diagnoses:* Lateral epicondylitis, little league elbow, medial epicondyle avulsion, chronic valgus instability or tears of the medial collateral ligament, intraarticular pathology or stress fracture, gout, cervical spine disease, ulnar nerve entrapment.

*Acute Treatment:* Relative rest; analgesia through appropriate doses of NSAIDs and with physical modalities such as ice, ultrasound, iontophoresis, phonophoresis, topical anesthetic skin refrigerant and electrical stimulation. If avulsion fracture with minimal displacement, apply posterior splint for two to three weeks then gradually progress ROM/strengthening. If displacement greater than 5mm, open reduction and internal fixation.

*Long-term Treatment/Rehab:* Activity modification, stretch tight musculature and strengthen weak musculature (see Figure 6). With young baseball players, it is critical to promote good throwing mechanics, limit the types of pitches thrown (especially breaking pitches such as the screwball), and keep a cap on the number of innings pitched per week (less than 10 is a safe recommendation based on the data).<sup>11-18</sup>

### Achilles Tendinitis

*History/Pathogenesis:* Painful inflammation of the Achilles tendon as a result of repetitive stresses. Injury of the lower leg muscles (gastrocnemius/soleus) that leads to a degenerative tendon condition characterized by chronic pain and inflammation on the posterior aspect of the ankle. Predisposing factors include tightness of the Achilles tendon, cavus foot, functional talipes equines, or pronated foot secondary to forefoot or hindfoot varus or tibia varus. Most frequently occurs in sports requiring jumping/running, especially in uneven terrain and hill-running.<sup>1-3,6,7</sup>

*Signs/Symptoms:* Pain/tenderness 2cm to 6cm above the Achilles’ tendon insertion on the calcaneus but also along the length of the tendon. Occasionally with warmth/swelling with crepitus and tendon nodule present. Pain with running (especially sprinting) and standing heel raise. Preactivity and morning stiffness.

*Physical Exam:* Tenderness to palpation 2cm to 6cm above the Achilles’ tendon insertion (thickening of the tendon is often noted). Pain/weakness with resisted plantarflexion and walking on toes. Decreased ankle dorsiflexion. Often patient will present with increased subtalar pronation. If chronic, may see atrophy of calf muscles.

*Diagnostic Tests:* If indicated, evaluate with baseline x-rays, MRI, or bone scan.

*Differential Diagnoses:* Posterior tibial ligament injury or Achilles tendon avulsion, inflammatory arthritides, plantar

fasciitis syndrome, occult lesion, stress fracture of calcaneus, or sural neuritis.

**Acute Treatment:** Relative rest (decrease speedwork, running hills or stairs; general decrease in overall intensity, duration, and/or frequency); new shoes to control excessive motion, if present; heel lift; analgesia through appropriate doses of NSAIDs with physical modalities such as ice, ultrasound, iontophoresis, phonophoresis, topical anesthetic skin refrigerant and electrical stimulation; gentle calf stretching; orthotics or arch supports, if significant hyper-pronator; night splints or walking boot (if severe).

**Long-term Treatment/Rehab:** Proper shoe wear for foot type with orthotic intervention, if necessary; gait analysis of running athlete to identify biomechanical faults; gastrocnemius/soleus stretching; gastrocnemius/soleus strengthening with emphasis on eccentric loading of musculature in a sport-specific manner (see Figure 1); surgical debridement if conservative treatment fails.<sup>11-18</sup>

### Patellar Tendinitis

**History/Pathogenesis:** Symptomatic degeneration of the patellar tendon with vascular disruption and an inflammatory repair response. Often triggered by overuse and repetitive overload of the quadriceps tendon at its insertion on the upper pole of the patella, the infrapatellar tendon at its origin from the inferior pole of the patella, or its insertion at the tibial tubercle and exacerbated by poor lower quarter biomechanics. Younger patients are engaged in jumping sports (“jumper’s knee”). Older patients involve a lifting strain or weight gain.<sup>1-3,6,7</sup>

**Signs/Symptoms:** Anterior knee pain/tenderness at the inferior pole of the patella, patellar tendon, and distally toward the tibial tuberosity. Patients often point to tender spot of concentration. Reported nocturnal pain, as well with sitting, squatting, kneeling, or climbing stairs. Pain is worse with “loading” activities such as landing from a jump, running up/down hill, and/or resisted leg extensions.

**Physical Exam:** Tender point on inferior pole of patella or patellar tendon. Frequent tightness to the quadriceps, hamstrings, and tensor fascia lata muscle groups. Check patellar alignment and tracking through long arc extension—normal movement makes a reverse “C” shape as the knee moves from flexion to extension. Pain with a three-quarters to

full squat.

**Diagnostic Tests:** If indicated, evaluate with baseline x-rays, MRI, or ultrasound.

**Differential Diagnoses:** ACL or PCL ligament injury, inflammatory or infectious condition, patellofemoral syndrome, occult lesion, or stress fracture.

**Acute Treatment:** Relative rest (decrease speedwork, running hills or stairs); new shoes to control excessive motion, if present; analgesia through appropriate doses of NSAIDs with physical modalities such as ice, ultrasound, iontophoresis, phonophoresis, and topical anesthetic skin refrigerant and electrical stimulation; gentle quadriceps and hamstring stretching (see Figure 3); counter-force bracing and/or patellar taping can be used short-term to allow athlete to perform corrective exercises in a relatively pain-free manner.

**Long-term Treatment/Rehab:** Strength training should emphasize closed kinetic chain work with eccentric loading.<sup>11-18</sup>

### Shin Splints

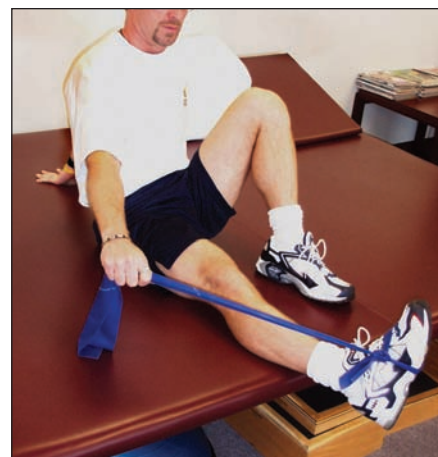**History/Pathogenesis:** Most commonly, the term ‘shin splints’ represents medial tibial stress syndrome which is a periostitis. Pain is along the medial distal two-thirds of the tibial shaft border at the periosteal/fascial junction. It is an overuse syndrome of either the posterior or anterior tibial muscle-tendinous units. Predisposing factors involve poor conditioning, running on hard surfaces, and abnormal foot alignment—especially with hyper-pronation.<sup>1-3,6,7</sup>

**Signs/Symptoms:** Often insidious and progressive in nature. Usually related to sudden increase in intensity/duration of activity (primarily running), or a change in playing/running surface (to a harder, less-forgiving surface). Early in the course, pain with onset of exertion usually relieved with rest. Later in the progression, pain after cessation of activity—possibly worse pain than during activity.

**Physical Exam:** Pain/tenderness along the middle to distal thirds of the tibia, along the posteromedial border. Diffuse tenderness often along the tendon of the tibialis posterior and/or soleus. Foot/ankle examination often reveals excessive pronation. In chronic cases, may find induration, soft tissue swelling, or nodularity.

**Diagnostic Tests:** If indicated, evaluate with baseline x-rays, MRI, or bone scan.

**Differential Diagnoses:** Posterior tibialis or



**FIGURE 7.** Eccentric strengthening with “theraband cords.”

peroneal ligament injury, peroneal muscle strain or chronic compartment syndrome, occult lesion, or stress fracture.

**Acute Treatment:** NSAIDs and cryotherapy is most beneficial early on in acute stage; topical anesthetic skin refrigerant and electrical stimulation. Complete rest if possible, otherwise 20-50% reduction in mileage/intensity with gradual progressive return to normal activity. Cross training with non-impact activities such as cycling, swimming, aqua jogging, and elliptical trainers.

**Long-term Treatment/Rehab:** Slow, steady, progressive return to run. Eccentric strengthening with bands/cords to the foot/ankle invertors (see Figure 7). Proper shoe wear (for foot type and activity) along with orthotic intervention if necessary.<sup>11-18</sup>

### Plantar Fasciitis

**History/Pathogenesis:** Inflammatory stress syndrome of the plantar fascia or plantar aponeurosis, usually at its medial calcaneal origin. It is believed that this syndrome is related to the stress on the plantar fascia from the weight of an activity combined with weight transfer up onto the toes which leads to MTP joint extension and causes a “windlass” effect on the plantar fascia. Accounts for approximately 10% of all running-related injuries and is the most common cause of heel pain in runners.<sup>1-3,6,7</sup>

**Signs/Symptoms:** Tenderness noted at the anteromedial calcaneal margin and tightness of the Achilles tendon, with burning pain at the anteromedial aspect of the heel. Worsens with activity (walking or running) but tends to be worst with the first few steps in the morning (imme-



**FIGURE 8.** Shoulder rotator muscle strengthening.

diately after getting out of bed). Pain intensity increases with prolonged weight bearing, especially if walking barefoot or in dress shoes.

**Physical Exam:** Pain localized to the antero-medial aspect of the calcaneus. Tightness to the gastrocnemius/soleus complex. PROM displays hypermobility to the subtalar joint, the midfoot complex, and the first ray. Gait evaluation reveals overpronation at the midfoot with excessive calcaneal eversion at heel lift. Pain on passive toe extension with the foot in dorsiflexion.

**Diagnostic Tests:** If indicated, evaluate with baseline x-rays (calcaneal spur is not diagnostic), MRI, or ultrasound.

**Differential Diagnoses:** posterior tibial ligament injury, tarsal tunnel syndrome, occult lesion, or stress fracture.

*“The unprecedented level in popularity over the last few decades in increased participation in athletic sporting events has led directly to the increase in chronic overuse sports injuries.”*

**Acute Treatment:** Relative rest; new shoes to control excessive motion if present; analgesia through appropriate doses of NSAIDs with physical modalities such as ice, ultrasound, iontophoresis, phonophoresis, topical anesthetic skin refrigerant and electrical stimulation; calf stretching (early morning and throughout the day); manual therapy techniques/deep soft tissue work to the gastrocnemius and soleus along with deep transverse friction massage to the arch and insertion point; soft gel heel cups; arch taping during ath-

letic activities.

**Long-term Treatment/Rehab:** Conservative therapy may last four to twelve months (see Figure 2). Custom orthotic intervention may be necessary. Night splinting.<sup>11-18</sup>

### Rotator Cuff Tendinitis

**History/Pathogenesis:** The rotator cuff is composed of four muscles: supraspinatus, infraspinatus, teres minor, and subscapularis. These muscles form a cover around the head of the humerus and whose function is to rotate the arm and stabilize the humeral head against the glenoid. Repetitive shoulder activity (especially overhead) causes breakdown in the cuff musculature (especially the supraspinatus) from tensile overload, poor blood supply, aging, subacromial impingement, and results in tendonitis. Weakness in the rotator cuff muscles results in altered glenohumeral movement causing impingement of the cuff muscles under the acromion, enhancing the pain and inflammation.<sup>1-3,6,7</sup>

**Signs/Symptoms:** Shoulder pain with overhead activity; weakness in the shoulder musculature; numbness/paresthesias (usually between the lateral neck to the elbow); night pain. In young patients impingement is usually related to laxity caused by an instability, in those 25 to 40 years of age there is generally an overuse of the rotator cuff and, for those over 40, the impingement is caused by overloading the cuff muscles beyond threshold.

**Physical Exam:** First one must rule out cervical spine dysfunction by checking

cervical ROM and any radicular findings. Painful AROM especially above 90° of forward elevation. Pain/weakness to shoulder flexors, abductors, internal rotators, and/or external rotators. Frequently one may see positive findings with impingement testing (Hawkins-Kennedy or Neer’s). May see scapular dyskinesia.

**Diagnostic Tests:** If indicated, evaluate with baseline x-rays, MRI, or arthrogram.

**Differential Diagnoses:** Bursitis-tendinitis with impingement, little league shoulder, microinstability, dislocation, adhesive

capsulitis, DJD of the AC or GH joint, thoracic outlet syndrome, cervical spondylosis, Pancoast tumor, or stress fracture.

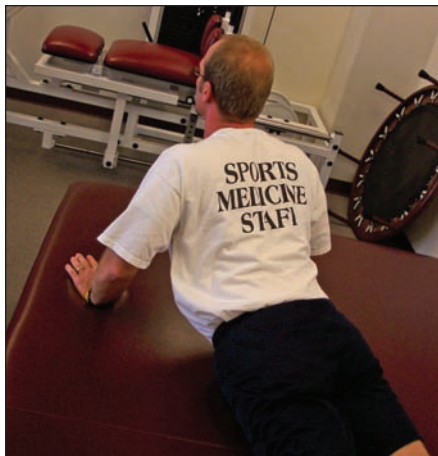**Acute Treatment:** NSAIDs; short course of prednisone; subacromial injection; physical modalities such as ice, ultrasound, iontophoresis, phonophoresis, topical anesthetic skin refrigerant and electrical stimulation; relative rest (limit overhead work); flexibility exercises to regain full ROM.

**Long-term Treatment/Rehab:** Strength and conditioning of the entire shoulder girdle (deltoid, rotator cuff, biceps, triceps, and scapular stabilizers) throughout full ROM (see Figure 8). Progressive return to overhead activity. Sport-specific retraining for overhead athletes (especially throwers and swimmers). Retraining of the scapula-humeral rhythm and periscapular muscles.<sup>11-18</sup>

### Low Back Pain

**History/Pathogenesis:** Pain in the childhood spine, although unusual, is often due to organic causes—especially when present for more than a few weeks. 47% of all low back pain in the young athlete is caused by spondylolysis. Acute pain is felt in the low lumbar, lumbosacral, or sacroiliac/pelvic region. Often accompanied by sciatica or radiculopathy, with pain radiating distally down the distribution of the sciatic nerve or specific radicular nerve. 90% of people experience low back pain in their lifetime and 5-10% will experience chronic pain. Spondylolysis involves a defect in the pars interarticularis of the vertebral complex, especially at the L5 level. The defect ranges from a stress reaction to a traumatic fracture. Spondylolisthesis results from anterior displacement of a vertebral body on the subjacent vertebra. Back pain from spondylolysis and/or spondylolisthesis occurs most frequently in the young athletic population (10 to 18 years of age) and is most common in sports that emphasize extension activities (e.g., gymnastics, ballet, soccer, volleyball, diving, weight lifting, football, figure skating, and wrestling).<sup>1-3,6,7,9,10,19</sup>

**Signs/Symptoms:** Back pain exacerbated by neurologic signs and symptoms (radiculitis, weakness, gait dysfunction, sensory changes, or bowel/bladder loss) or systemic symptoms (fever, malaise, weight loss, nocturnal pain) suggest serious problems. Pain in the low back exacerbated by movement and often accompanied by focal muscle spasm in the lumbar extensors. Patients tend to prefer to stand



**FIGURE 9.** Prone-lying press up with “Mckenzie Method.”

in a semi-flexed position and move slowly rather than sit still. Discogenic pain tends to be sharp or burning and often shoots into the lower leg. Spondylolysis and spondylolsthesis patients tend to have pain into the buttocks that is worse with extension and lateral side-bending.

**Physical Exam:** pain, tightness, and often spasm to the lumbar paraspinals. Repeated movement testing (flexion and extension) can be very useful to identify disogenic pain. Quadrant testing to identify instabilities. Straight leg raise and slump test to assess dural inflammation. Assess strength/endurance of core trunk musculature. Myotomal and dermatomal scan to differentiate level of nerve root involvement. Special questions regarding bowel/bladder changes, “saddle” anaesthesias, or visceral disease. Abnormal neurologic signs may be a late manifestation of tumor, with occasional pathologic reflexes noted (Babinski’s sign).

**Diagnostic Tests:** If indicated, evaluate with baseline AP/lateral/oblique x-rays, bone scan, MRI or CT, or EMG.

**Differential Diagnoses:** Scheuermann’s disease—exaggerated normal posterior convex curvature of the thoracic spine associated with wedging of the vertebra usually occurs in early-middle adolescent boys—is the most common cause of pain in the thoracic/thoracolumbar regions, while spondylolysis/spondylolisthesis are the most common cause of pain in the lumbar/lumbosacral regions. Also noted are facet osteoarthritis, musculoskeletal-ligamentous strain, occult lesion, infection, stress/compression fracture or pars interarticularis defect.

**Acute Treatment:** Relative rest; analge-

sia through appropriate doses of NSAIDs and with physical modalities such as ice, ultrasound, topical anesthetic skin refrigerant and electrical stimulation. “Back School” or “McKenzie Method” exercises emphasizing self-correction (see Figure 9), proper posture, body mechanics, and self-management techniques. Encourage active approach to problem with movement-based therapy.

**Long-term Treatment/Rehab:** Back pain treatment in children is diagnosis specific. Conservative treatment with activity modification and mild analgesia is appropriate initially. Emphasis is to improve overall strength and conditioning (special emphasis to the core stabilizers: transversus abdominus, internal obliques, multifidus, and lumbar transversospinalis). In Scheuermann’s disease, hyperextension exercises and emphasis on posture correction are appropriate, although occasional bracing is recommended when adequate spinal growth remains and the curve is less than 75 degrees. Improve strength to the gluteus maximus/hamstrings for hip extension. Nutritional counseling and weight management can help “unload” the spine to achieve normal activities of daily living (ADLs).<sup>9-19</sup>

### Conclusion and Summary

The unprecedented level in popularity over the last few decades in increased participation in athletic sporting events has led directly to the increase in chronic overuse sports injuries. Sports provide many benefits including improvement in health status and physical fitness, relaxation, entertainment, and, for a select few, some prestige and a good source of income. Indirectly, the burgeoning population of elite athletes to the “weekend warriors” will continue to increase exponentially with the number of sports overuse injuries. Injury occurs when cumulative forces exceed the tissue’s ability to withstand such forces either due to isolated macrotraumatic events or repetitive microtraumatic events. Often, specific biomechanical or physiological factors predispose an athlete to injury. It remains in the medical/health personnel’s domain to properly identify and assist the athlete to correct these conditions to treat, prevent and possibly reverse the detrimental effects of chronic overuse sports injuries. As always, prevention is always the best treatment but should be addressed alongside proper and successful rehabilitation. ■

*Elmer “El” Pinzon, MD, MPH, FABPMR, FABPM, is Fellowship-trained in minimally-invasive spinal/pain procedures, musculoskeletal/sports medicine/electrodiagnostic medicine. Dr. Pinzon practices at the University Spine & Sports Specialists, PLLC, in Knoxville, Tenn. He is Clinical Asst. Professor, University of Tennessee Medical Center-Knoxville (UTMCK), Dept. of Surgery, Division of Surgical Rehabilitation, Knoxville, Tenn. He may be contacted at epinzon@utmck.edu or 865-675-5000.*

*Mick Larrabee, PT, MS, SCS, EMT, CSCS, is a Board-certified, Sports Physical Therapist and a USA Triathlon Coach- Level I. He is a Strength and Conditioning Specialist at Optimal Performance, Inc., Knoxville, Tenn. (www.optimalperformanceinc.com)*

### References

1. Garrick JG and Webb DR. *Sports Injuries: Diagnosis and Management*. W.B.Saunders. 1990.
2. Brotzman SB. *Handbook of Orthopaedic Rehabilitation*. Mosby-Year book. 1996.
3. Snider R.K. *Essentials of Musculoskeletal Care*. American Academy of Orthopaedic Surgeons. 1997.
4. Windsor RE and Lox DM. *Soft Tissue Injuries: Diagnosis and Treatment*. Hanley & Belfus, Inc. 1998.
5. Mense S and Simons DG. *Muscle Pain: Understanding its Nature, Diagnosis, and Treatment*. Lippincott, Williams, & Wilkins. 2001.
6. Paget S, Pellicci P, and Beary III JF. *Manual of Rheumatology and Outpatient Orthopedic Disorders*. Little, Brown, and Co. 1993.
7. Mellion MB. *Sports Medicine Secrets*. Hanley & Belfus Inc. 1994.
8. Dubin J. Conservative therapy stretches iliotibial band for recovery. *Biomechanics*. Apr 2006. 13(4): 44-60.
9. Schepsis AA and Busconi BD. *Sports Medicine*. Lippincott Williams & Wilkins. 2006.
10. Madden CC, Putukian M, Young CC, and McCarty EC. *Netter’s Sports Medicine*. Saunders-Elsevier. 2010.
11. Prentice W, et al. *Therapeutic Modalities for Physical Therapists*. McGraw-Hill. 2002.
12. Zachazewski JE, et al. *Athletic Injuries and Rehabilitation*. W.B. Saunders. 1996.
13. Clark M. *Integrated Training for the New Millennium*. National Academy of Sports Medicine. 2001.
14. Hertling D and Kessler RM. *Management of Common Musculoskeletal Disorders: Physical Therapy Principles and Methods*. Lippincott-Raven. 1996.
15. Nordin M and Frankel VH. *Basic Biomechanics of the Musculoskeletal System*. Lea & Kebiger, Inc. 1989.
16. Tippet SR and Voight ML. *Functional Progressions for Sports Rehabilitation*. Human Kinetics. 1995.
17. *Current Concepts of Orthopaedic Physical Therapy- HSC 11.2*. Orthopaedic Section of the American Physical Therapy Association. 2001.
18. Travell JG and Simons DG. *Myofascial Pain & Dysfunction: The Trigger Point Manual. Vols. 1 & 2*. Williams & Wilkins. 1999.
19. Frontera WR and Silver JK. *Essentials of Physical Medicine & Rehabilitation*. Hanley & Belfus, Inc. 2002.