

AGNI Primary Molar Crowns User Manual

Indications:

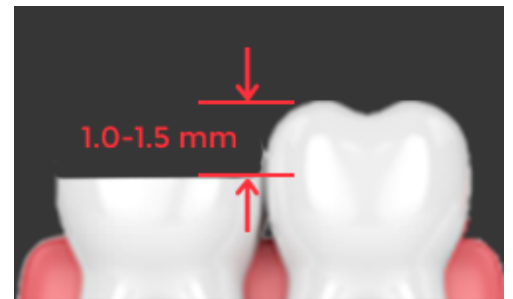
- Extensive caries
- Fractured teeth
- Developmental disorders
- Pulpal exposures
- Long-term adult provisionals

Preparation:

A small tapered, carbide bur (69-L or 169-L) or Diamond bur will work well for tooth reduction.

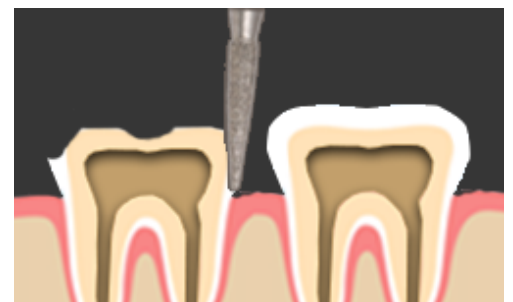
Occlusal reduction:

It carried out to obtain clearance of approximately 1.5 mm.



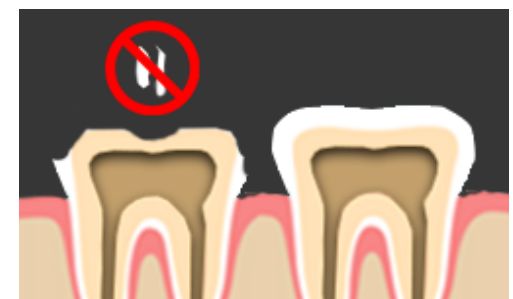Proximal surface:

The mesial and distal contact points are cleared and a smooth taper from occlusal to gingival should be obtained that is free of ledges or shoulders.

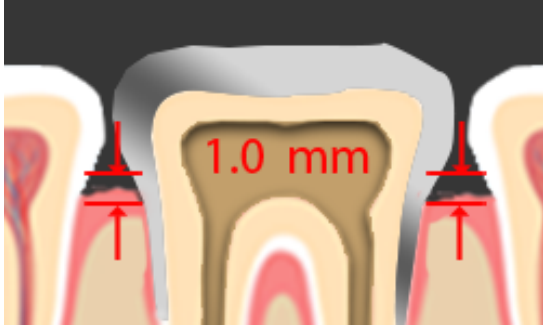


Cervical finish line:

If a step or ledge is present the operator will have difficulty seating the crown and may be tempted to trim it unnecessarily.



AGNI Primary Molar Crowns User Manual



Crown selection:

- Select the crown and trial fit.
- The crown margin should be located approximately 1.0 mm subgingivally both to give retention and a good cement seal.



Trimming:

- If crown is too long or gingival blanching occurs, trim crown using a Crown scissors or with an abrasive wheel.



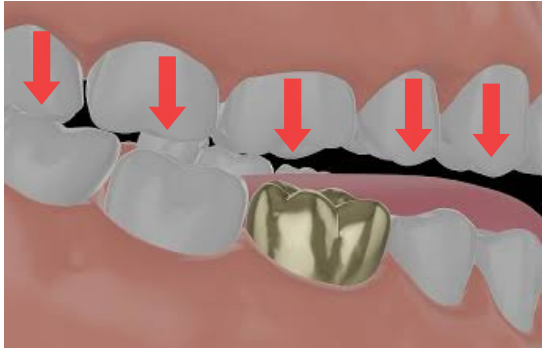
- Crimping pliers are recommended for ease and efficiency in crimping stainless steel crowns; however, conventional orthodontic pliers can also be used.



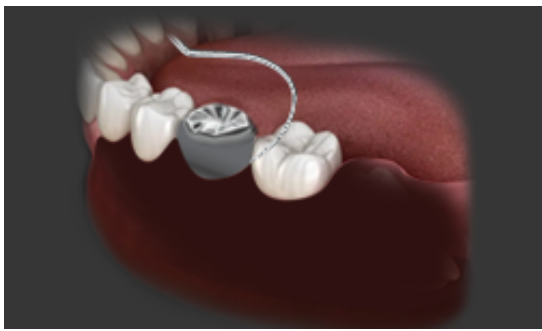
Crown cementation:

- Isolate tooth, rinse and dry. Mix cement and fill crown, assuring voids are not present in cement.
- Stainless steel crowns are not a tight fit except at the margin, so a larger than normal volume of cement should be mixed.

AGNI Primary Molar Crowns User Manual



- *Seat crown firmly, check occlusion.*
- *Have patient bite into occlusion until cement is set.*



- *Remove excess cement interproximally with scaler or explorer. Floss interproximal areas.*