

# COURSE SYLLABUS

20/100

**T**

**H E**

20/70

**S U N**

20/50

**C O A S T**

20/40

**S E M I N A R**

20/25

**F O R O P T O M E T R Y**

20/20

---

**A P R I L 2 5 - 2 6 , 2 0 2 6**

## Saturday April 25

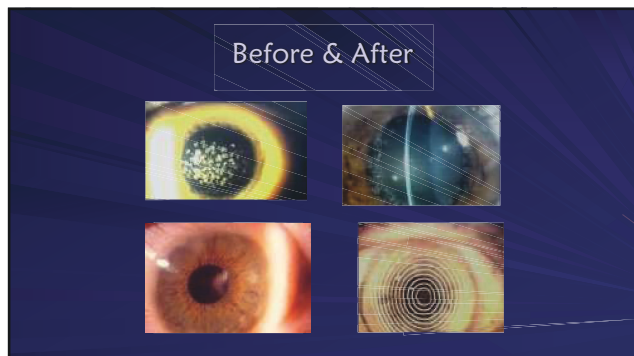
---

- 7:45 am - 8:15 am**      **Registration**  
**Exhibit Hall Open**  
**Continental breakfast** - sponsored by *St. Luke's Cataract and Laser Institute*
- 8:15 am - 9:55 am**      **Advances in Cornea, Cataract, Refractive and Glaucoma Surgery (2, TQ, COPE: 103831-GO)**  
Neel R. Desai, M.D. and Priti Panchal, O.D.
- 9:55 am - 10:40 am**      **Break**  
**Exhibit Hall Open**
- 10:40 am - 12:20 pm**      **Amblyopia Management for Primary Care O.D.s (1, COPE: 103274-FV)**  
**Acquired Brain Injury: What the O.D. Needs to Know (1, COPE: 103273-FV)**  
Richard Sorkin, O.D.
- 12:20 pm - 1:10 pm**      **Lunch** - sponsored by *Retina Vitreous Associates of Florida*  
**Exhibit Hall Open**
- 1:10 pm - 1:20 pm**      **Lighthouse of Pinellas Update**
- 1:20 pm - 1:30 pm**      **FOA Update**
- 1:30 pm - 3:10 pm**      **Pharmaceutical Update - Innovations and Insights for Eye Care (2, TQ, COPE: 103324-PH)**  
Greg Caldwell, O.D.
- 3:10 pm - 3:30 pm**      **Break**
- 3:30 pm - 5:10 pm**      **Latest Advances in Eye Care Technology - Innovations in Early Detection and Management (2, TQ, COPE:103700-GO)**  
Greg Caldwell, O.D.

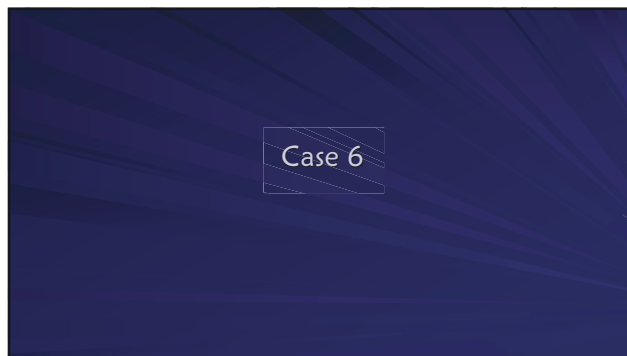
## Sunday April 26

---

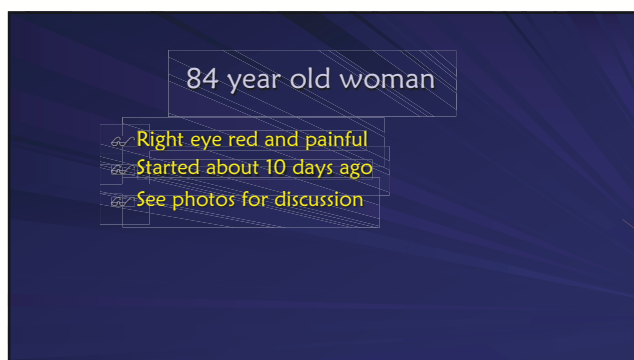- 7:30 am - 8:00 am**      **Registration**  
**Continental breakfast** - sponsored by *the POA*
- 8:00 am - 9:40 am**      **Grand Rounds - Improving Eye Care and Outcomes for Patients (2, TQ, COPE: 103866-TD)**  
Greg Caldwell, O.D.
- 9:40 am - 10:00 am**      **Break**
- 10:00 am - 11:40 am**      **Prevention of Medical Errors (2, COPE: 102834-EJ)**  
Alice Sterling, O.D.
- 11:40 am - 12:00 pm**      **Lunch** - sponsored by *LENZ Therapeutics*
- 12:00 pm - 1:40 pm**      **Florida Jurisprudence (2, COPE: 101024-EJ)**  
Alice Sterling, O.D.



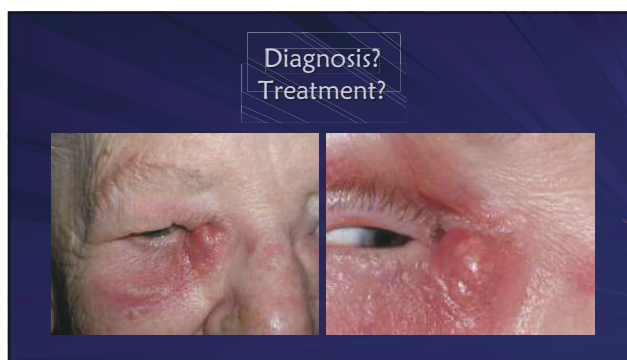58



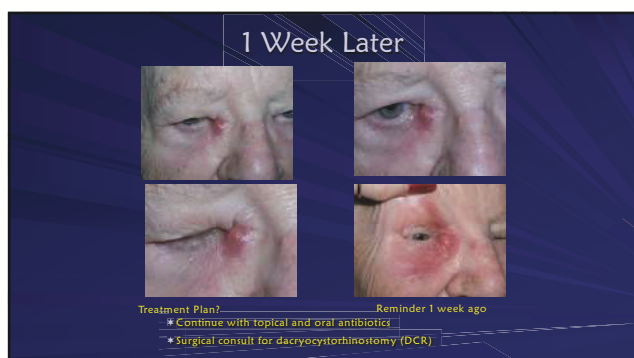59



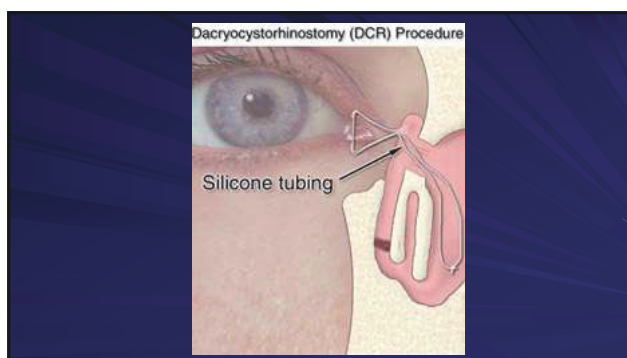
60



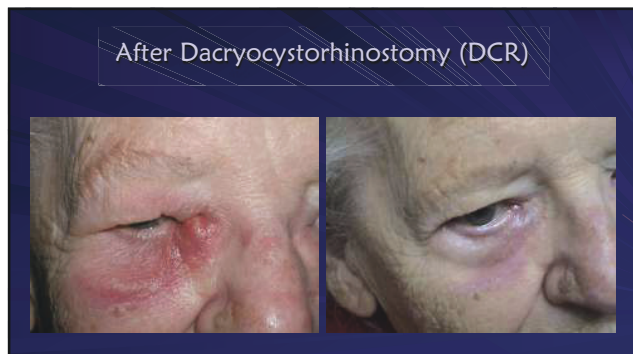61



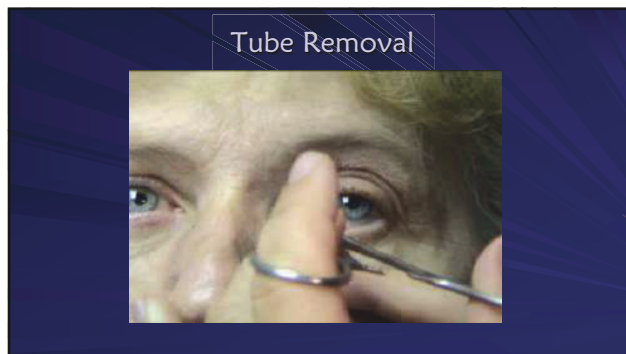
62



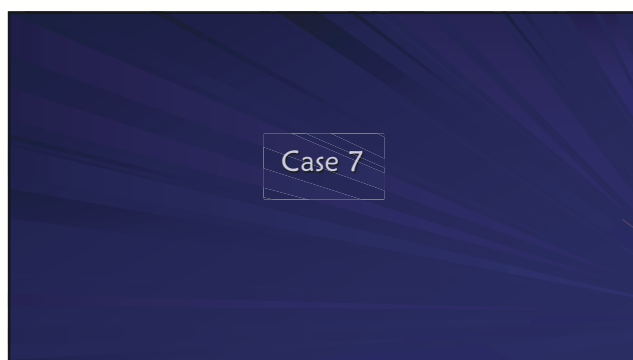
63



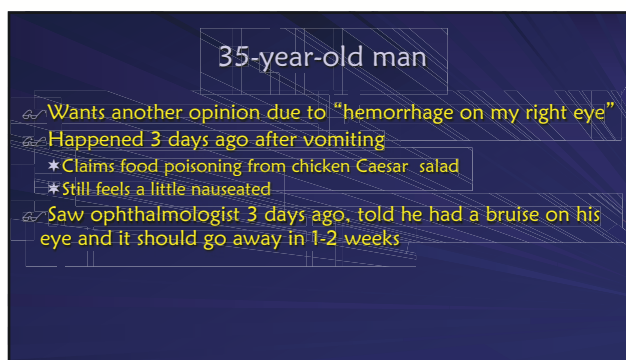
64



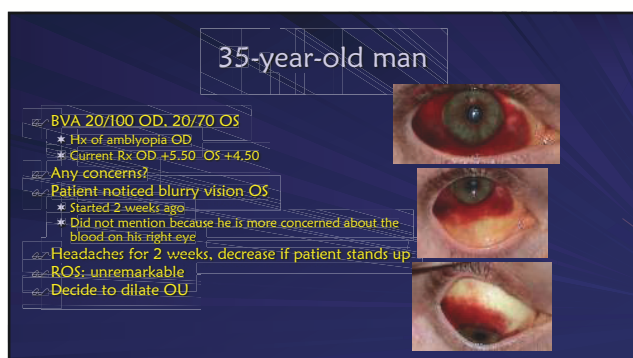
65



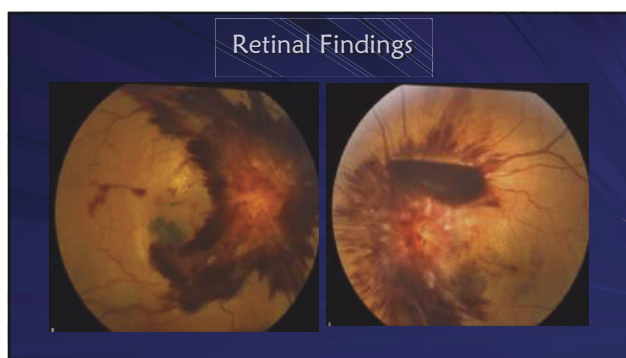
66



68



69



70

### Differential Diagnosis

- Hypertensive retinopathy
- Blood dyscrasia
- Terson's syndrome
- Valsalva retinopathy
- Purtscher's retinopathy
- Shaken baby syndrome

71

### Terson's Syndrome

- Terson's syndrome originally was defined by the occurrence of vitreous hemorrhage in association with subarachnoid hemorrhage
- Terson's syndrome now encompasses any intraocular hemorrhage associated with intracranial hemorrhage and elevated intracranial pressures
- Intraocular hemorrhage includes the development of subretinal, retinal, sub-hyaloidal, or vitreal blood
- The classic presentation is in the sub-hyaloidal space

72

### Treatment

- Emergency referral to neurologist due to high suspicion of intracranial hemorrhage and elevated intracranial pressure
- Intracranial hemorrhage confirmed with MRI
- Patient later diagnosed with Hairy Cell Leukemia and cryptococcal meningitis

73

### Case 8

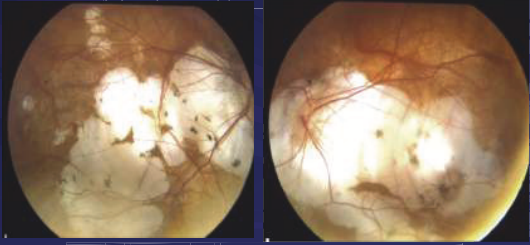
74

### 58-year-old woman

- VA OD 20/200 OS 20/400
- Longstanding history of macular degeneration
- Anything suspicious here?
  - \*?? Longstanding AMD in 58-year-old??
- History of cataract surgery OU
- Glasses Rx OD -1.00 OS -1.00

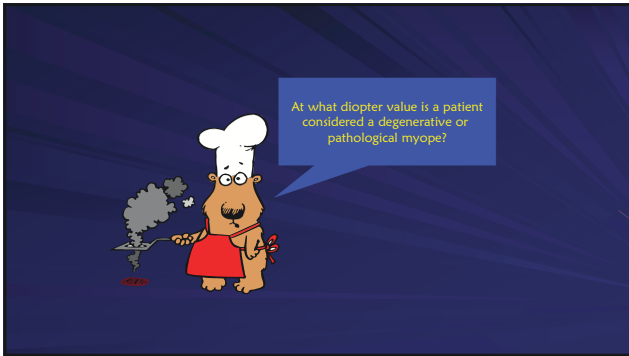76

### Axial length 29.85 mm

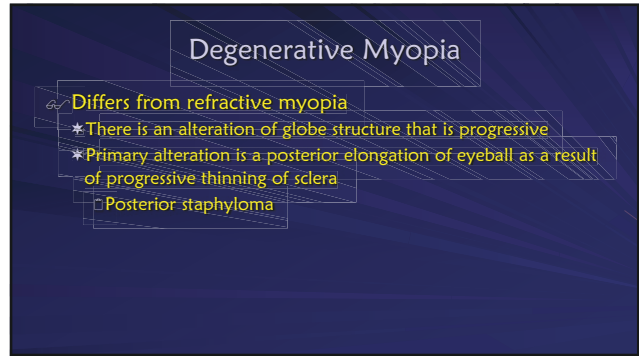


OD -18.00 OS -18.50 prior to cataract surgery

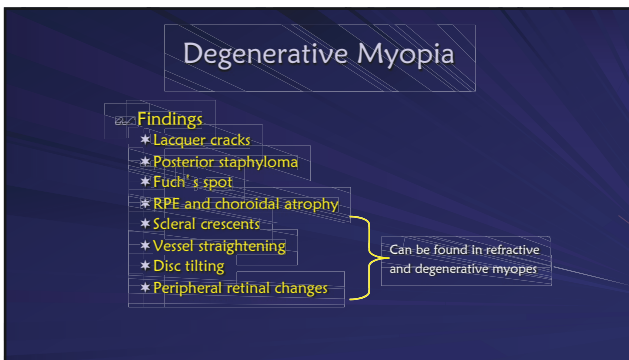
77



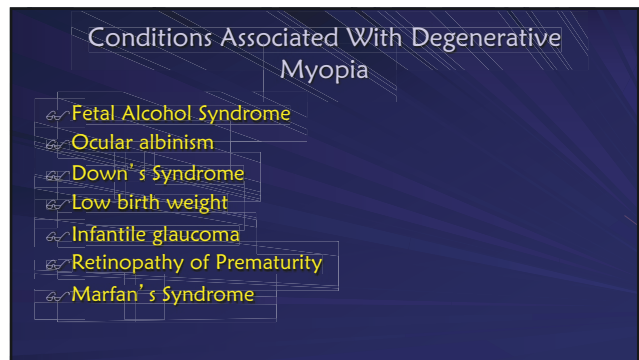
78



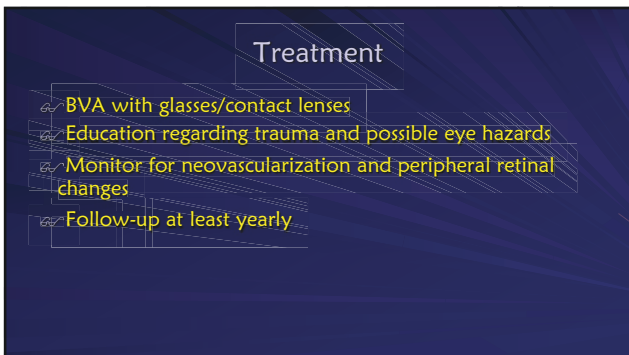
79



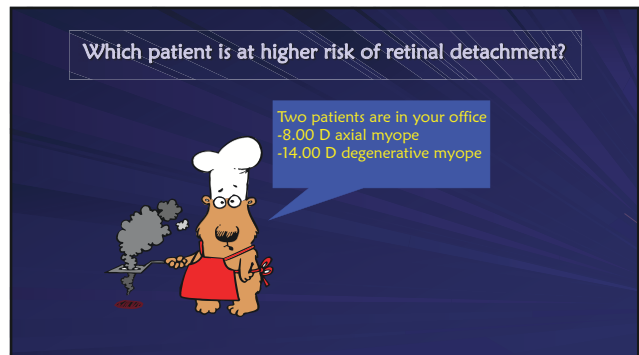
80



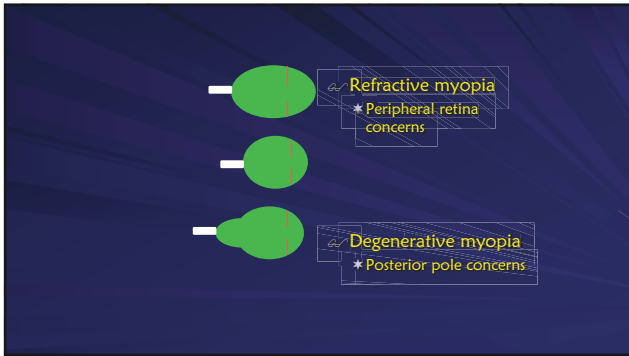
81



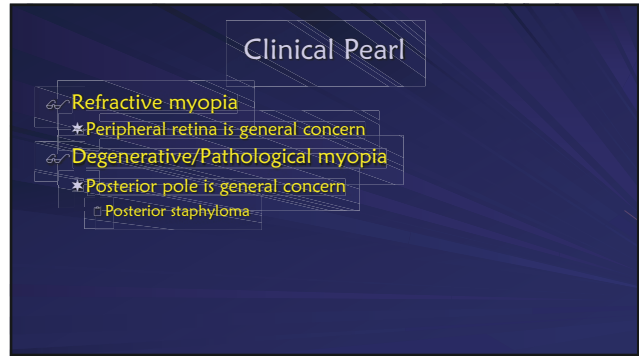
82



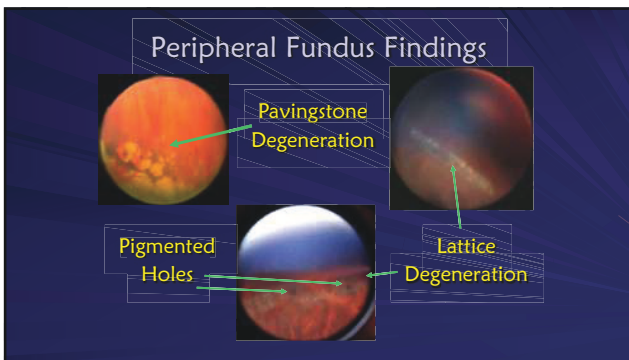
83



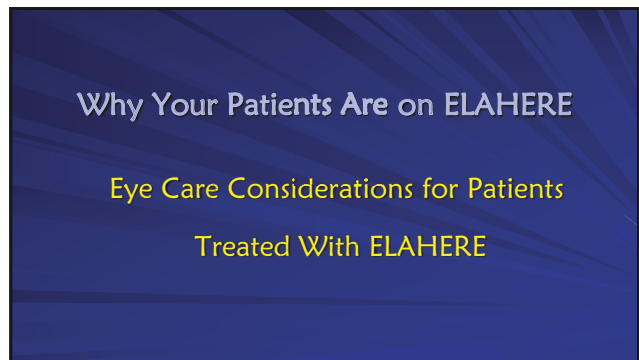
84



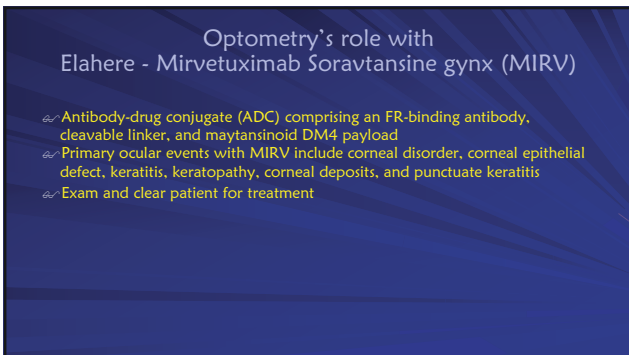
85



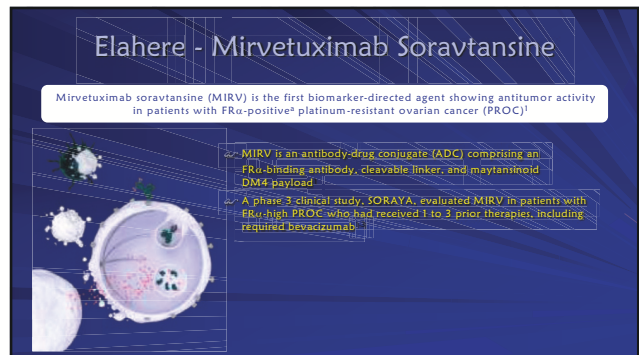
86



87



88



89