

BODY DIVISIONS, BASIC OF CELLS AND EMBRYOLOGY

When studying anatomy, one finds that its vocabulary is vital to understanding what and where we are looking at. If we look at the body divisions without an understanding of the basic vocabulary, we may miss a lot. For instance, the Human body is the typical vertebral body plan which means it has **bilateral symmetry**, or that it can be divided into only two equal parts.

The Human body contains two main **body cavities**, the dorsal body cavity and the ventral. The **Dorsal body cavity** is divided into Cranial (brain) and vertebral. The Ventral cavity contains visceral organs, which include the heart lungs, intestine, and kidneys. It is divided by the diaphragm into two divisions, the Thoracic and abdominopelvic cavities. The Thoracic cavity is subdivided into three portions. Two lateral parts are called the pleural cavities, holding the lungs. The middle portion is called the mediastinum and holds the heart, esophagus and trachea.

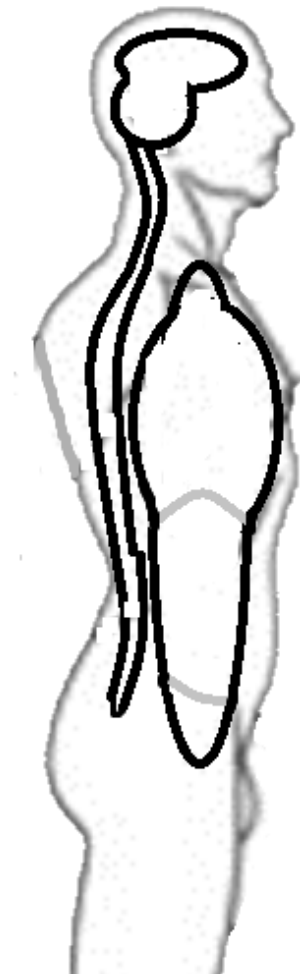The Abdominopelvic cavity is divided into the Abdominal cavity and pelvic cavity by the pelvic inlet. The Pelvic Inlet is on the sacrum to the pubic bone. Abdominal cavities include the stomach, intestines, and kidneys. The Pelvic cavity holds the bladder and some reproductive organs.

If we take time to look at the word roots, we can learn something new. For instance, if we look at the list of root words below and read the writings above again, we find something easier.

Words to remember:

Bi= two
 Lateral= to the sides or away from the midline
 Sym= same
 Metry= measure
 Doral= top
 Ventral= bottom
 Media=middle
 Thoracic= chest

1. On the image, label the two main body cavities?
2. Label the divisions of the dorsal body cavity?
3. Label the divisions of the ventral body cavities?
4. Draw and label a transverse plane on the image.
5. Draw and label a coronal plane on the image.
6. What is contained in the pleural cavities?
7. What is found in the mediastinum?
8. What are visceral organs?



9. Label the pleural cavity and mediastinum on the image provided.
10. On the image draw and label the midsagittal plane
11. On the image draw and label a transverse plane.
12. Label the abdominopelvic cavity.
13. Label the abdominal cavity.
14. Label the pelvic cavity.

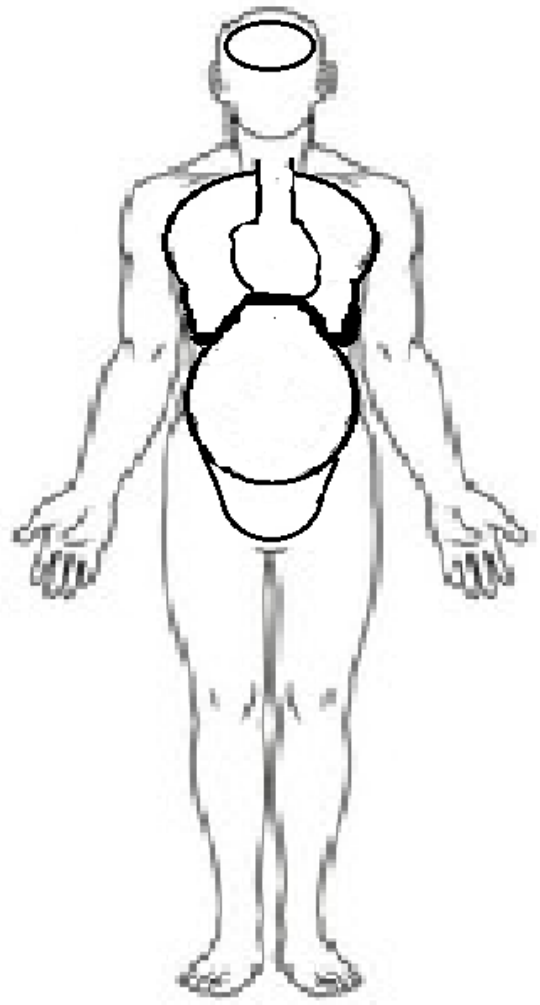
Before studying anatomy, it is important to go over some basic terms that are needed to know if one is to truly learn anatomy. One of these is the concept of Anatomical position. **Anatomical position** is described as follows: The head and feet point forward; thumbs are pointing out to the sides (laterally) and the hands are open and feet slightly separate. The reason for this position is two-fold. For one, it is the way that the body has maximum exposure, and the other is that it gives us a reference point ALL directions in medicine and anatomy are based on Anatomical position. It must be mentioned that when referring to right and left, it will be the body you are looking at that is important.

Gross anatomy also requires a special language to determine directions when looking at a body in an anatomical position. If we are heading upward towards the head area, that direction is called superior unless we are in embryology when it is cephalic. If we are moving down, away from the head, then we can say we are moving inferiorly or in the case of embryology it is caudal. When looking at something in front we can say it is anterior while something behind will be posterior. If we are looking at something as if going towards the midline, we call it medial while going away from the midline it would be called laterally.

When we are dealing with the arms and legs, we tend to talk about things being either closer to the trunk, or proximal or farther from the trunk which would be distal. We can also look at something as being on the top called dorsal or on the bottom which is ventral. Dorsal and ventral can become confusing as sometimes they are used synonymous with back and front respectively.

There are some cuts that can be made on the human body which are used for directions and naming. This is vital as the body has bilateral symmetry and can be cut by a mid-sagittal plane into right and left sides. It is interesting to note that Sagittal refers to how an arrow would fly so a midsagittal cut would be if Sagittarius shot you in your midpoint.

Those who have learned Spanish will know that Corona means crown. A coronal plane is one which divides the anterior aspect of the body from the posterior. The last main way to divide the body would be a transverse plane which divided top from bottom. Transverse planes can occur anywhere along the body so various landmarks are used to determine the area, usually the level of the spine is used in anatomy to determine what area is being looked at. For instance, if we are looking at an L4-L5 transverse plane view, it would be between Lumbar vertebrae four and lumbar vertebrae five.



15. For the directional terms, define the following using your own words:

Superior
Inferior
Anterior
Posterior
Medial
Lateral
Superficial
Deep
Proximal
Distal
Dorsal
Ventral
Bilateral symmetry
Sagittal
Coronal
Transverse

16. When it comes to the skull bones, what are they compared to the sternum?
17. In the Arms and legs, you will use Proximal or Distal depending on the distance to the torso, what do these two words mean?
18. Where would the pleural cavity be compared to the Mediastinum?
19. Describe the position of the cranial cavity to the vertebral cavity.
20. Using anatomical terms describe the location of the feet as they sit in anatomical position
21. Describe the location of the thumbs using anatomical terms when they are in anatomical position

Human Cells

The Animal version of the Eukaryotic Cell is the basic unit of human life. It consists of a Cell membrane made of phospholipids, proteins and cholesterol. The cell membrane is referred to as Semi-permeable which means that some stuff can pass through it. To allow other things through and to have contact with the outside environment, it has Trans-membrane Proteins that pass through the entire membrane. This membrane is called a fluid mosaic model as it is made up of different substances and is not stagnant.

The trans-membrane proteins can be used for a few things such as protein pumps that actively pump sodium (Na) out and Potassium (K) in using energy in the form of Adenosine triphosphate or ATP for short. These are

called Na/KATPase. Besides the trans-membrane proteins, the cell membrane can also have peripheral proteins that can function as receptors or cell markers.

Other than the specialized structures mentioned, the cell can also bring other things in via endocytosis or more specialized pinocytosis, cell drinking. In this process the cell membrane invaginates allowing food and potentially harmful things in for destruction. There is an opposite action called exocytosis where items inside the cell are expelled such as would happen with digestive enzymes or immune proteins.

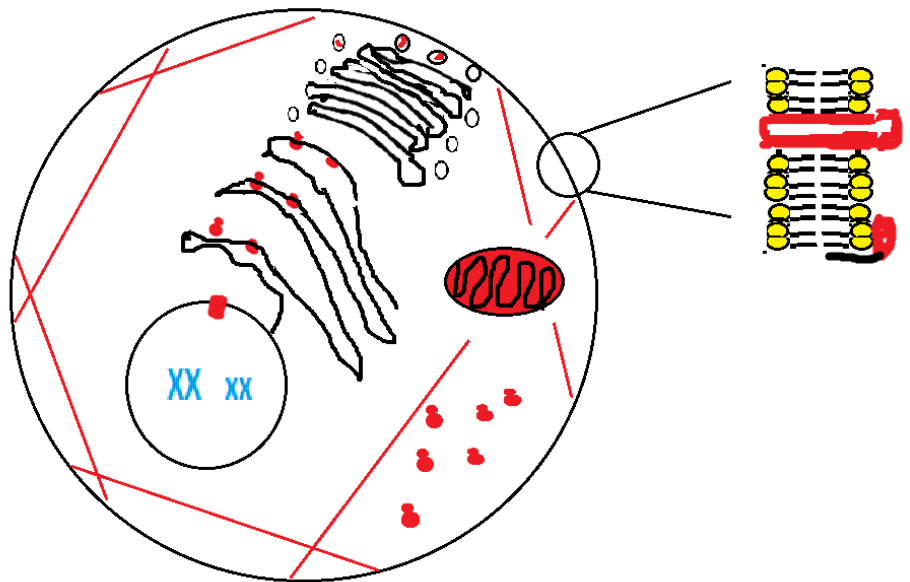
Inside this bag of water, we have different Organelles (little organs). A Cytoskeleton (Cyto- means bag) is made of proteins and gives the cell its shape. We also have a Nucleus that holds DNA, our genetic material, in a second phospholipid membrane. Our genetic material is held together by proteins called histones into a globular structure called a nucleosome. Nucleosomes are held together in a “beads on string” like structure called a chromatid. Two homologous (similar) pairs are tied together to form chromosomes. Each one of these will encode for similar proteins. Our cells we will have 22 pairs of autosomal chromosomes and 2 sex chromosomes (only one pair if you are female 2 different chromosomes if male).

The Endoplasmic Reticulum, (ER) is an extension of the Nucleus that is divided into two parts. The rough ER (rER) makes proteins for secretion as well as some that will lay in the membrane. It can also modify proteins by adding sugars (glycol means sugar) via a process known as N-glycosylation. This means that it needs ribosomes which will give the structure a rough appearance. The smooth ER (sER), makes Cholesterol, stores fats, holds and releases Calcium (Ca).

The Golgi Apparatus is sometimes referred to the post office of the cell because it determines where vacuoles go. It can also modify proteins in various ways including O-glycosylation. These vesicles can sometimes act as a storage site for proteins which might be secreted.

Mitochondria Makes Adenosine Triphosphate or ATP (a way to store energy) for cell. It has its own DNA so it suggests that it is an example of symbiosis within all multi-cellular organisms. Unlike the cytoplasm which has special enzymes that can break sugar anaerobically into pyruvate, the Mitochondria needs oxygen to take pyruvate and break it down further.

22. Label the organelles in the cell below.



23. On the image above the label the phospholipids
24. What type of cell is a human cell?

25. How many Autosomal Chromosomes does it have?
26. How many total chromosomes does it have?
27. What part of a cell is described as a Fluid Mosaic Model? Why?
28. Define the following terms as simple as possible:
 - a. Cyte-
 - b. endo-
 - c. exo-
 - d. trans-
 - e. glyco-

The cell can go through that is known as a Cell cycle. This is broken down into an Interphase, where the cell is doing what it normally does. This includes taking in nutrients, making energy, repairing itself and getting ready for reproduction. These are the requirements to be considered alive. It can be broken down into three parts. G1 cells are actively using and making energy, making proteins, and growing. In S-phase the cell makes two copies of its genetic material (will have four pairs of chromosomes in it). In G2 enzymes are needed for cell division.

There are two types of Cell reproduction we will deal with in Human Anatomy. The first is Mitosis, which is how your cells reproduce to keep you functioning as an organism. There are some phases here. Prophase is the beginning and is when the cell starts to form the mitotic spindles at the centrioles from microtubules (a protein). This ends when the nuclear envelope is destroyed, and the chromosomes are lined up by the mitotic spindles.

When the chromosomes form a straight line in the dividing cell you have reached metaphase and the line that hold the chromosomes next to each other in that line is referred to as the metaphasic plate. Once the two sets of paired chromosomes are pulled apart, you are no longer in metaphase.

The end of Metaphase leads to Anaphase. This is when the chromosomes are pulled to different poles of the cells. This phase ends when the nucleus begins to form.

The last phase of mitosis is Telophase. This is when the two new cells, now referred to as daughter cells, are formed. This phase ends with mitosis.

29. Cells can be in any stage of the cell cycle but are usually found at what stage?
30. What is Mitosis?
31. Draw the four stages of mitosis and explain what differentiates the stage:

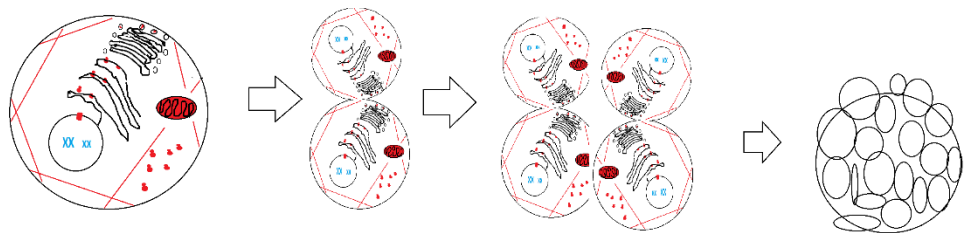
There is another type of cell division that occurs but only in sex cells or Gametes called Meiosis. It is divided into Meiosis I (MI) and Meiosis II (MII). These two parts are done after mitosis, so each cell has only two pairs of chromosomes, so the cell is referred to as a diploid cell ($2N$). Each meiosis has all the stages seen in mitosis so there is a prophase, Metaphase, Anaphase, and Telophase.

In MI the homologous chromosomes are split into two cells. Then, the chromosomes are divided into chromatids, so the cell still has two copies of the genetic material in the form of two sets of chromatids. These cells go through MII that separate the chromatids into more cells each with one set of chromatids (23 only). The cell is now called a haploid cell (n).

32. Draw what you would get from one cell that went through MI and MII. How many sets of chromosomes does each cell have? How many chromatids?

Basic Embryology is important for much of body positioning it begins counting from conception as week one (Don't get confused with weeks of pregnancy). Conception is when sperm and Oocyte (each is a haploid cell). When this happens, they combine genetic material of paternal and maternal origin. The cell is now a Zygote which will be a diploid cell.

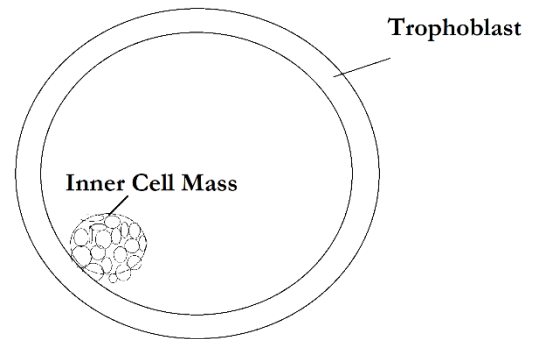
Zygote begins a rapid mitosis, called cleavage, to divide into smaller cells called Blastomeres. In about seventy-two hours the zygote is a solid cluster of



From cells to Morula

cells called a Morula. By the fourth day, the Morula becomes a fluid filled sphere called a Blastocyte. The Blastocyte is composed of two distinct cell types, the trophoblasts are the cells outside holding in the fluid and forming a sphere. Inside the sphere is the inner cell mass, which part of it will become the embryo.

On day nine, the inner cell mass divides into two sheets of cells with the Epiblast making the top layer and the hypoblast forming the bottom layer. The epiblast will form a cavity which will then make up the Amniotic sac. The hypoblast will form the yolk sac. Where the two layers connect is called the bilaminar embryonic disc, it is this area that will become the embryo.



By day fifteen, a raised groove appears on the dorsal surface of the epiblast, called the primitive streak. This occurs because some of the epiblast cells begin to migrate inward, between the epiblast and hypoblast. The epiblast continues to

migrate and forms a third layer under the epiblast layer and over the hypoblast called the mesoderm. There are now three distinct cell layers: Ectoderm (the topmost), Mesoderm (middle) Endoderm (bottom most) next to the yolk sac.

On week four, the body will look like a tadpole. The embryonic disc begins to grow faster than the yolk sac. Part of the yolk sac becomes part of the inside of the tube which is the primitive gut. Neurogenesis also begins leading to a big head region called the cephalic end and a long tail called the caudal end.

Between day twenty-eight and the second month, limb buds appear, and embryo starts to have a human form, a tube within a tube. In short you are a donut. You end up bilaterally symmetrical, your right is a mirror image of your left even if there are different organs on either side.

13. What is a Morula?

14. What is a Blastocyst?

15. What cells is a Blastocyst composed of?

16. At what week do you have a Bilaminar disc?

17. What are the two cell layers of a bilaminar disc called?

18. Draw a Bilaminar disc labeling the Amniotic sac, the yolk sac, the hypoblast, and the epiblast:

19. What are the three cell layers in week three?

20. Define the following in simplest terms:

- a. Bi-
- b. Derm-
- c. Epi-
- d. Meso-
- e. Endo-
- f. Hypo-

With the germ layers formed, we find the parts of the embryology that will become a human, the back is considered the top or dorsal area. What will become the front is the bottom or ventral area. From the three germ layers, different cells and matrixes (non-cellular material) are made. The formation of Cells in a matrix constitutes a tissue. Different tissues will come together from organs and organs will come together to form organ systems and organ systems will come together forming organisms.

There are four classes of tissues that are divided into more specific tissue types. The first is Epithelia/Endothelial tissue. While this tissue usually lines the body and lumens, the tissue's characteristic is that it is composed of many cells with little matrix. The matrix in this type of tissue is found on the bottom layer called the basement membrane. The cells in this tissue can be either simple (one cell layer thick) or stratified (many layers). The next tissue you will see is the Connective tissue. This tissue is characterized by having more matrix than cells. The last two tissues are the contractile, that have many cells connected that can move or cause movement. The other is nervous tissue made of neurons that will be discussed later.

21. What is a tissue?

22. What are the four classes of tissues and what makes each different?

1.

2

3

4

23. What is an organ?

24. What is an organ system?