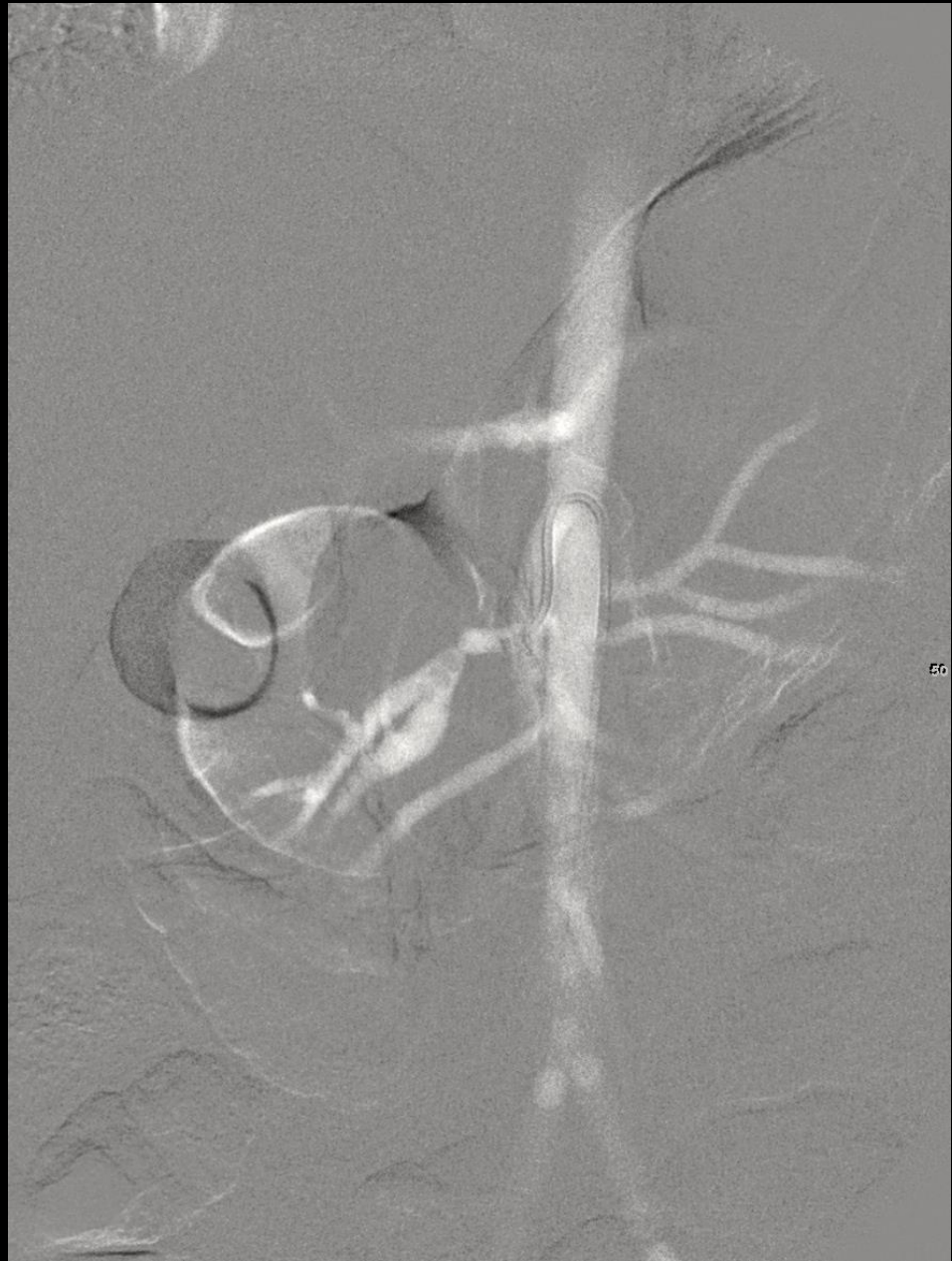
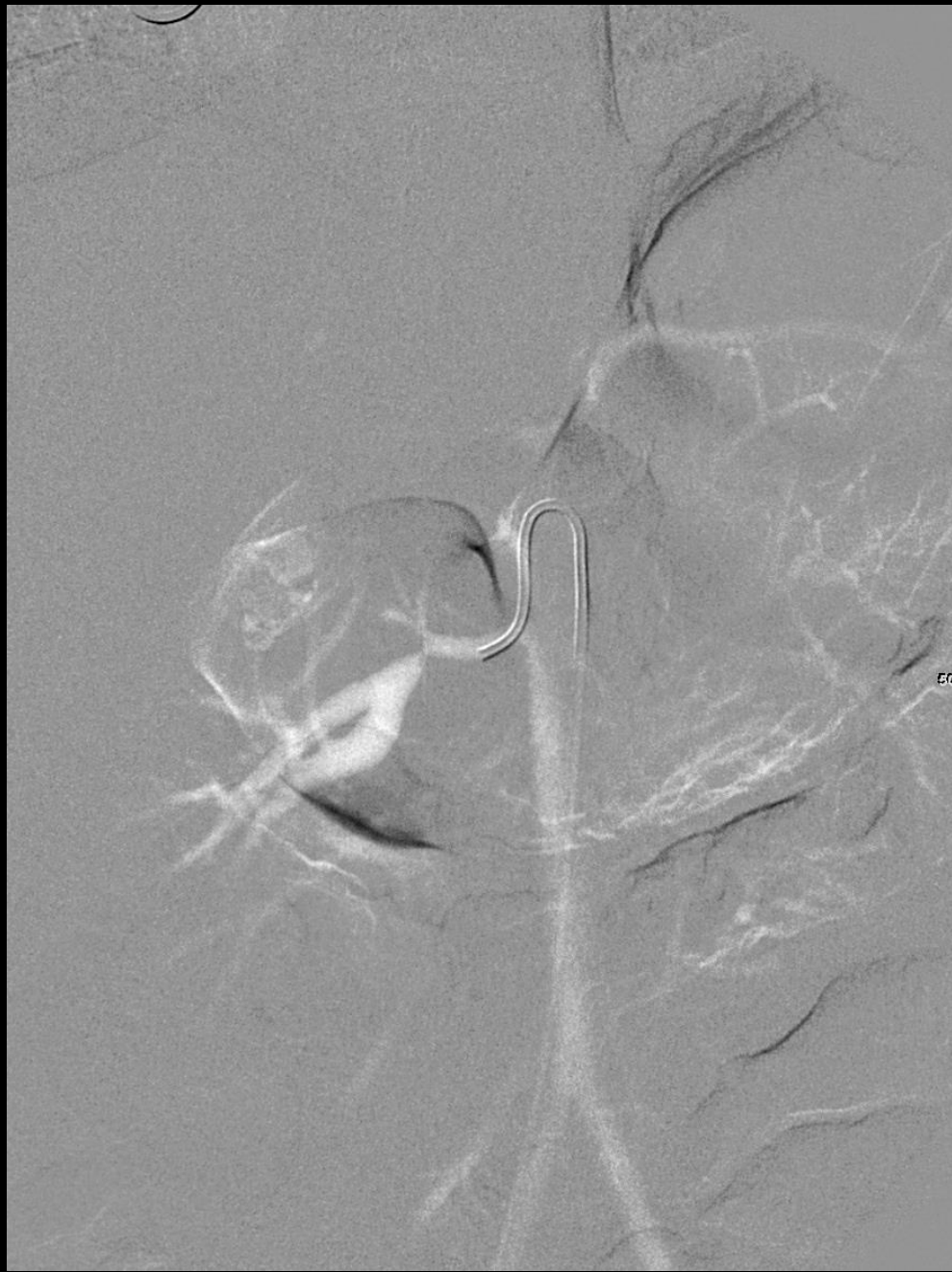
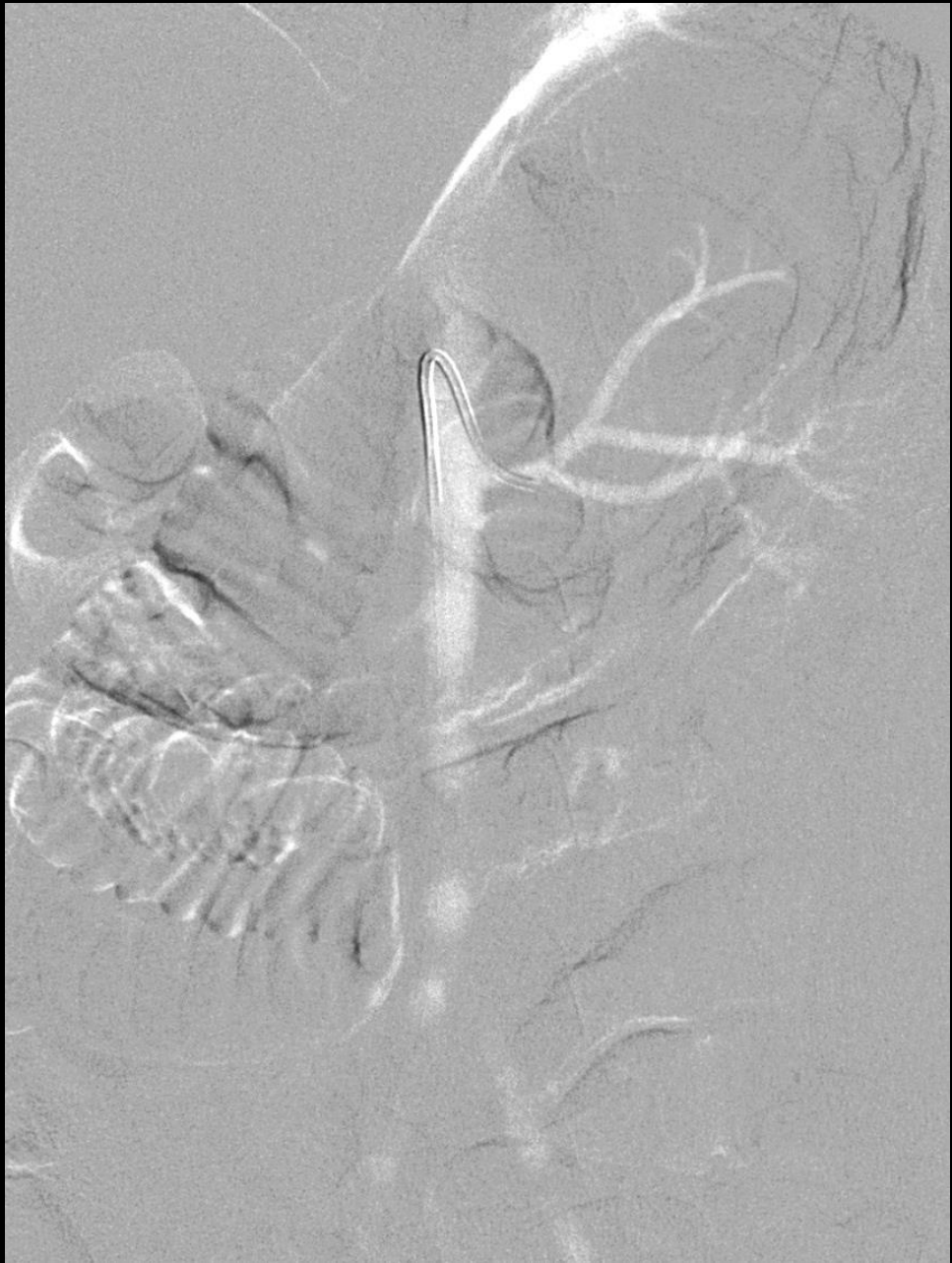CASE CONFERENCE

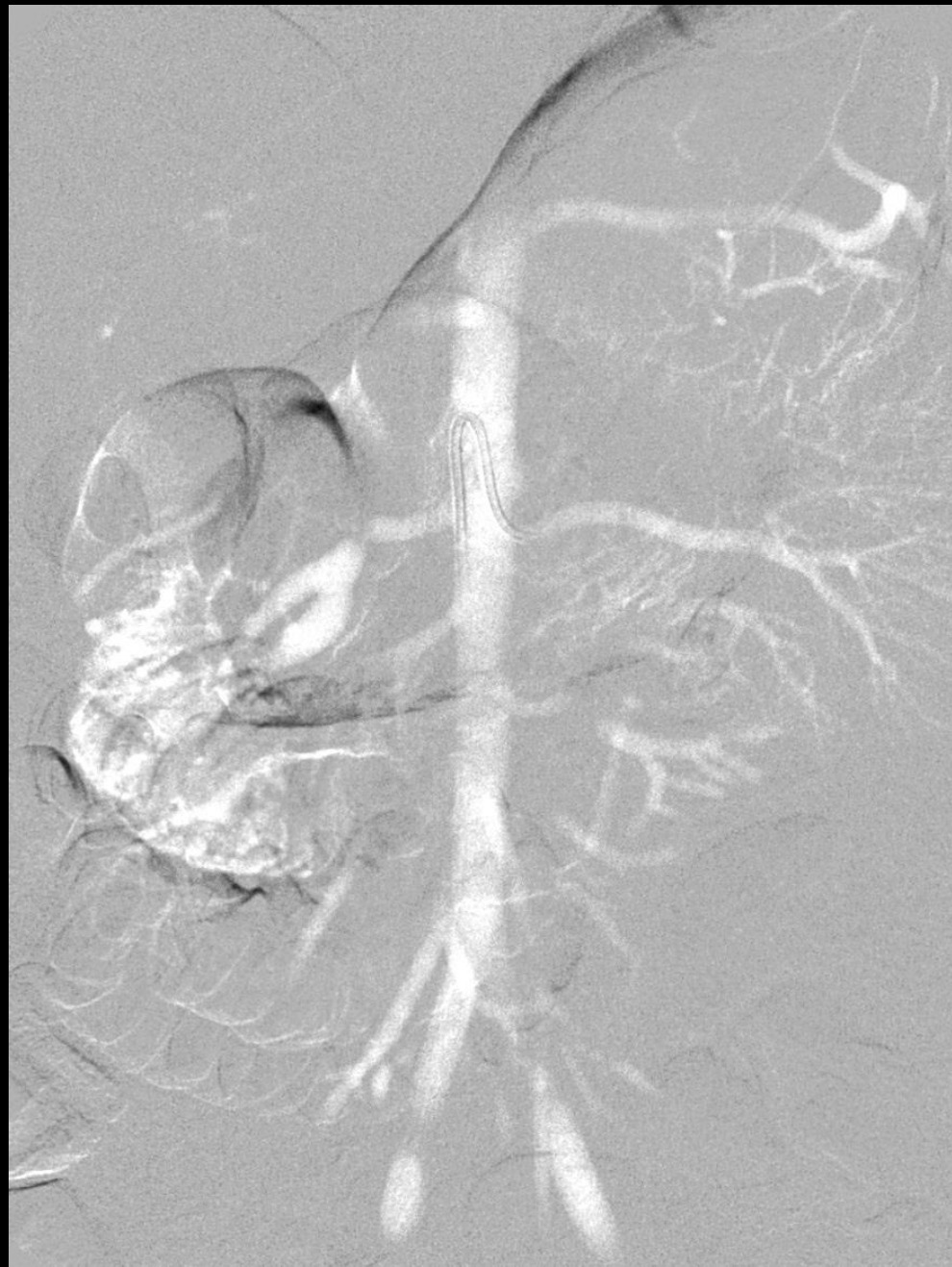6/04/2106

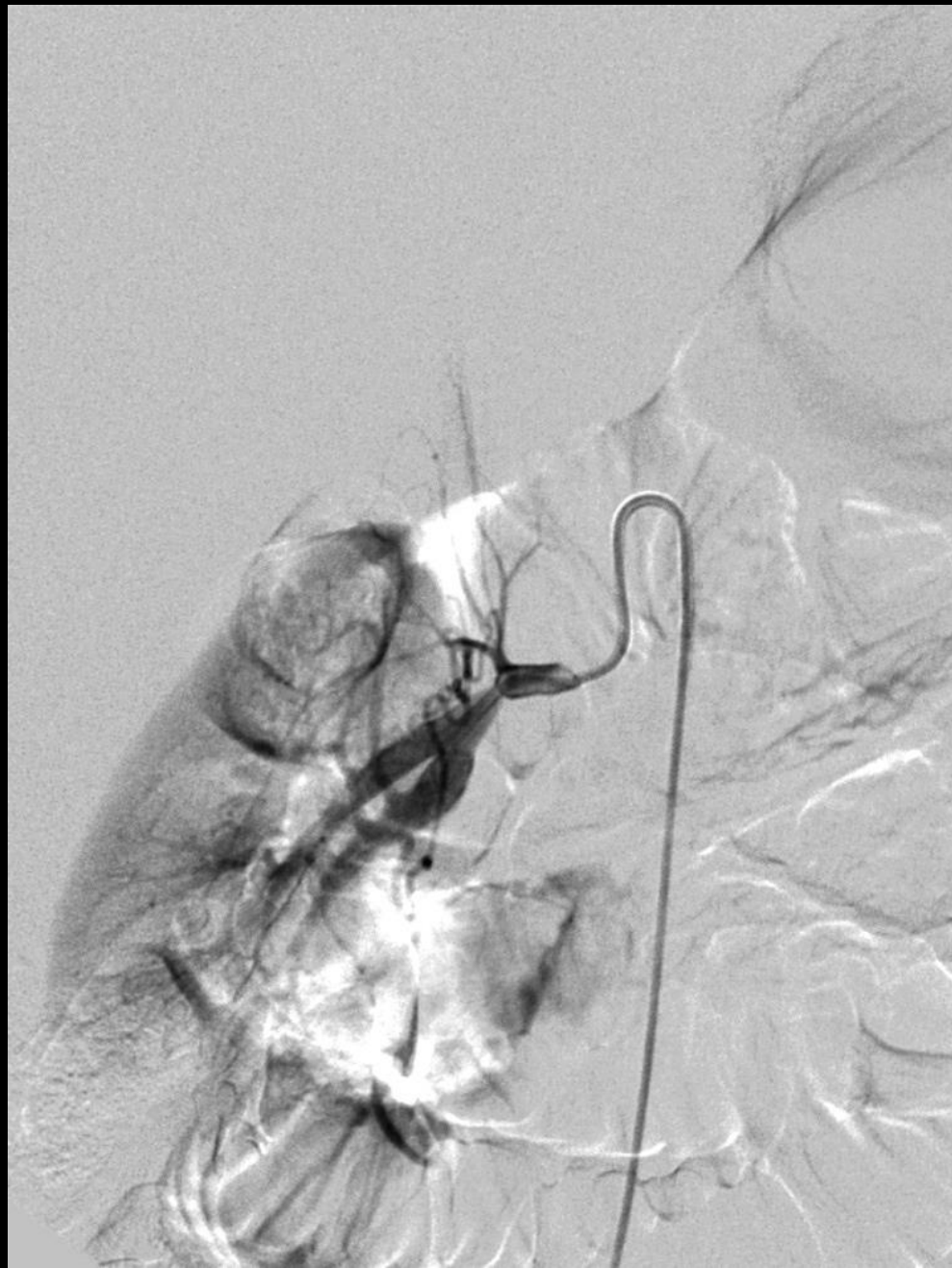**CO₂ CHILD
RENAL ANGIOPLASTY
ANGIODYSPLASIA**

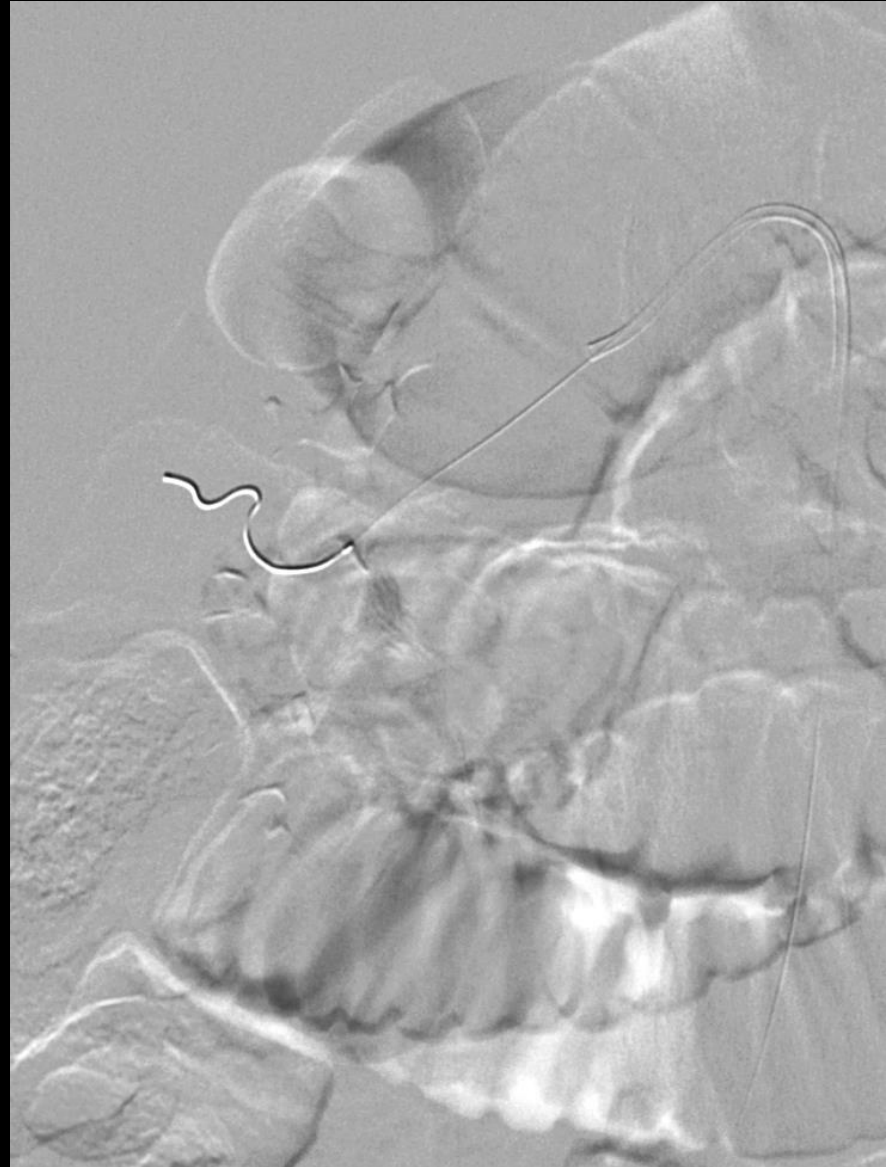
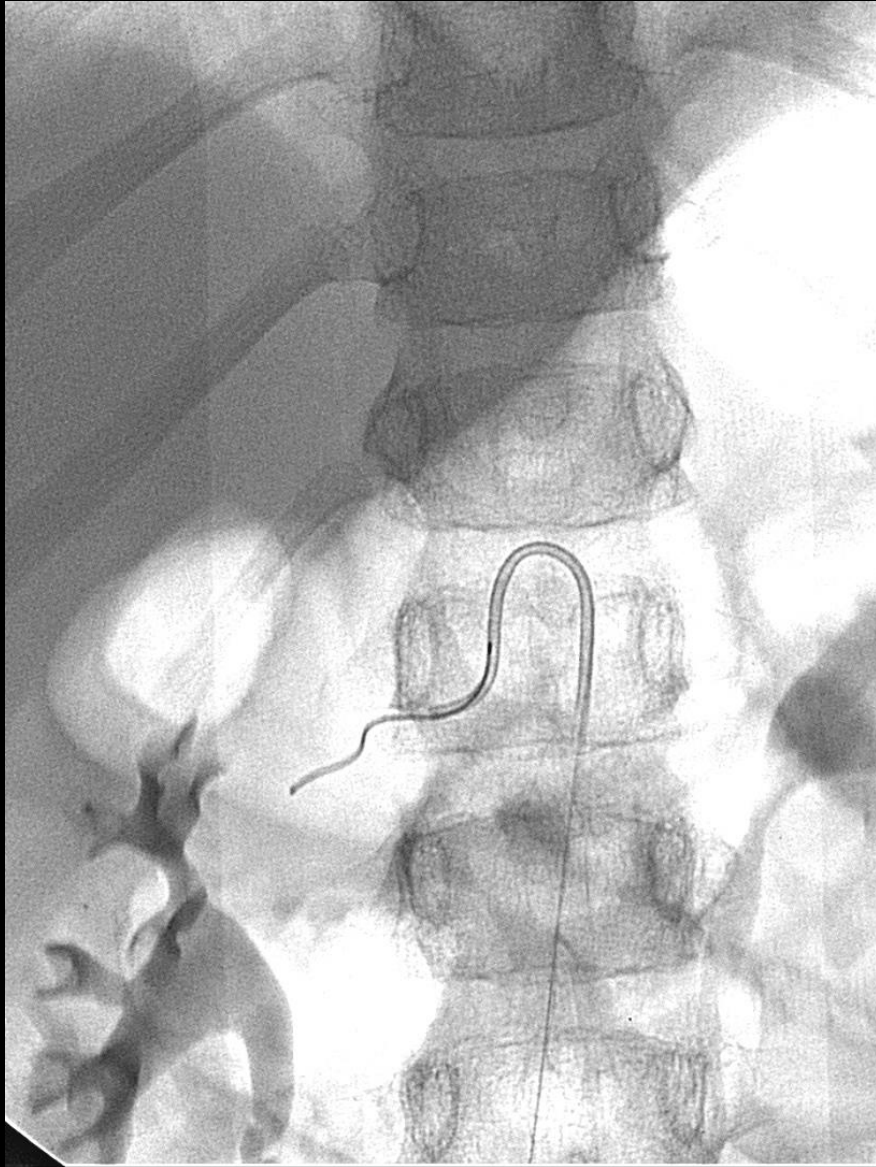


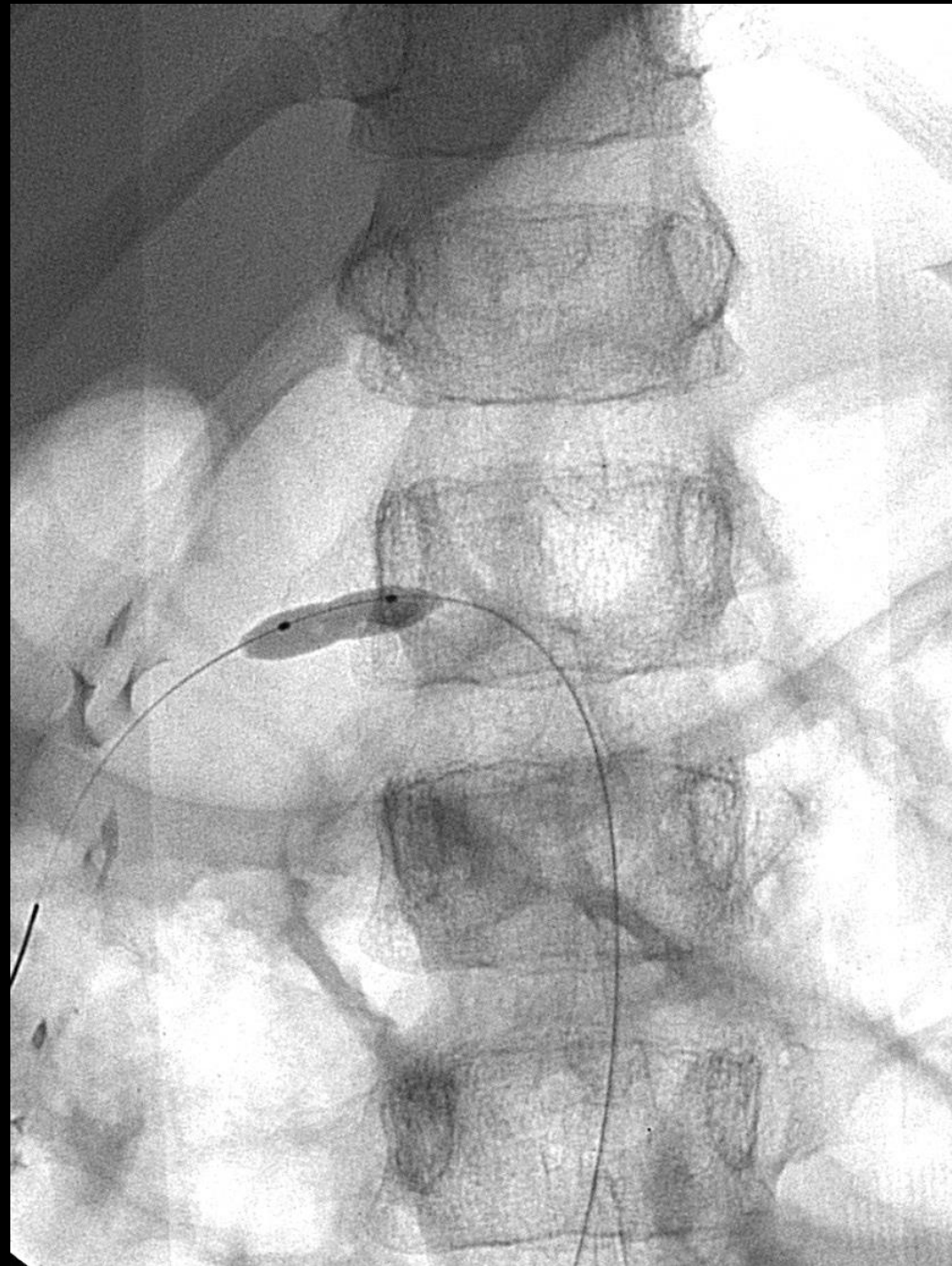


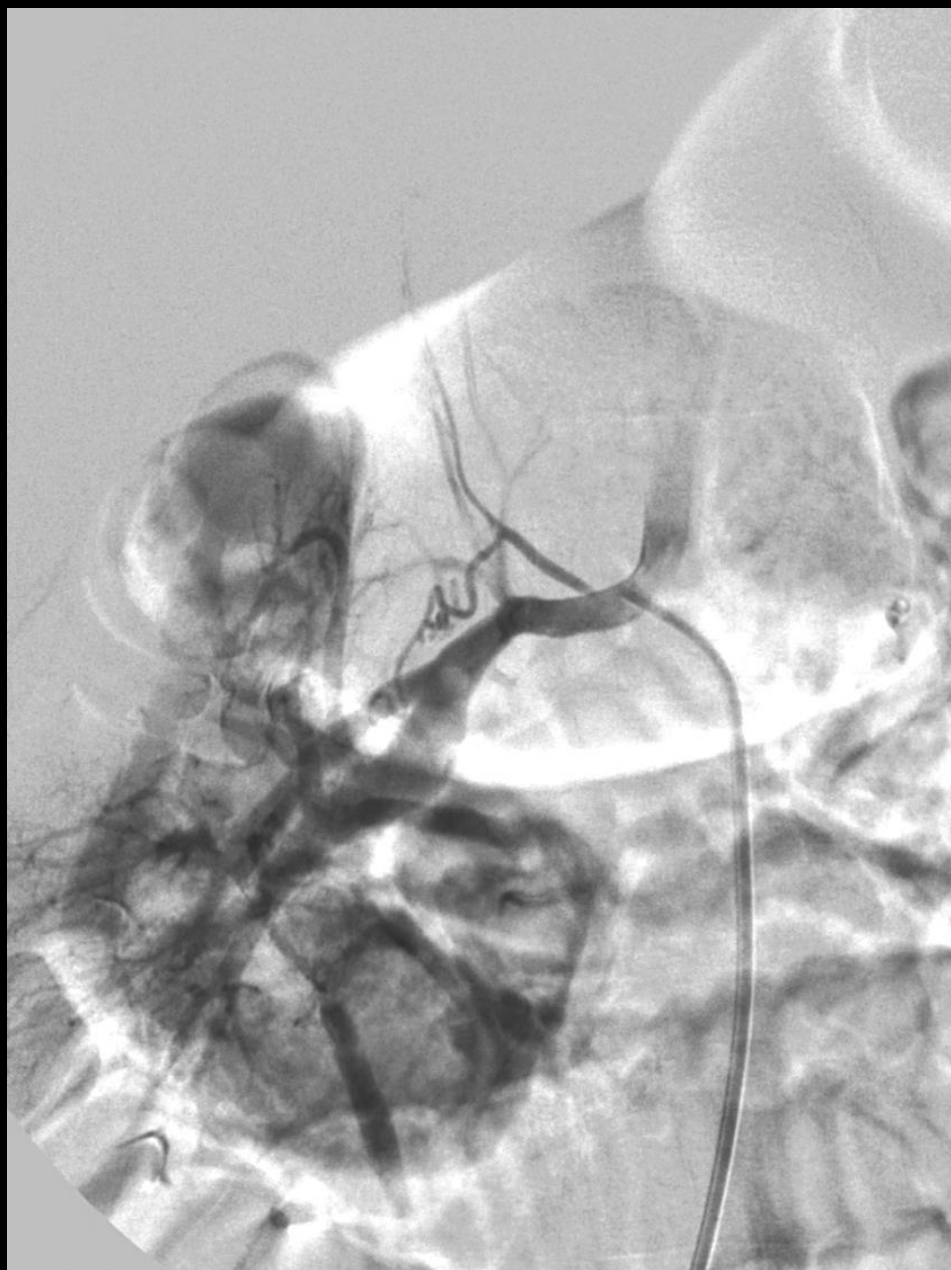




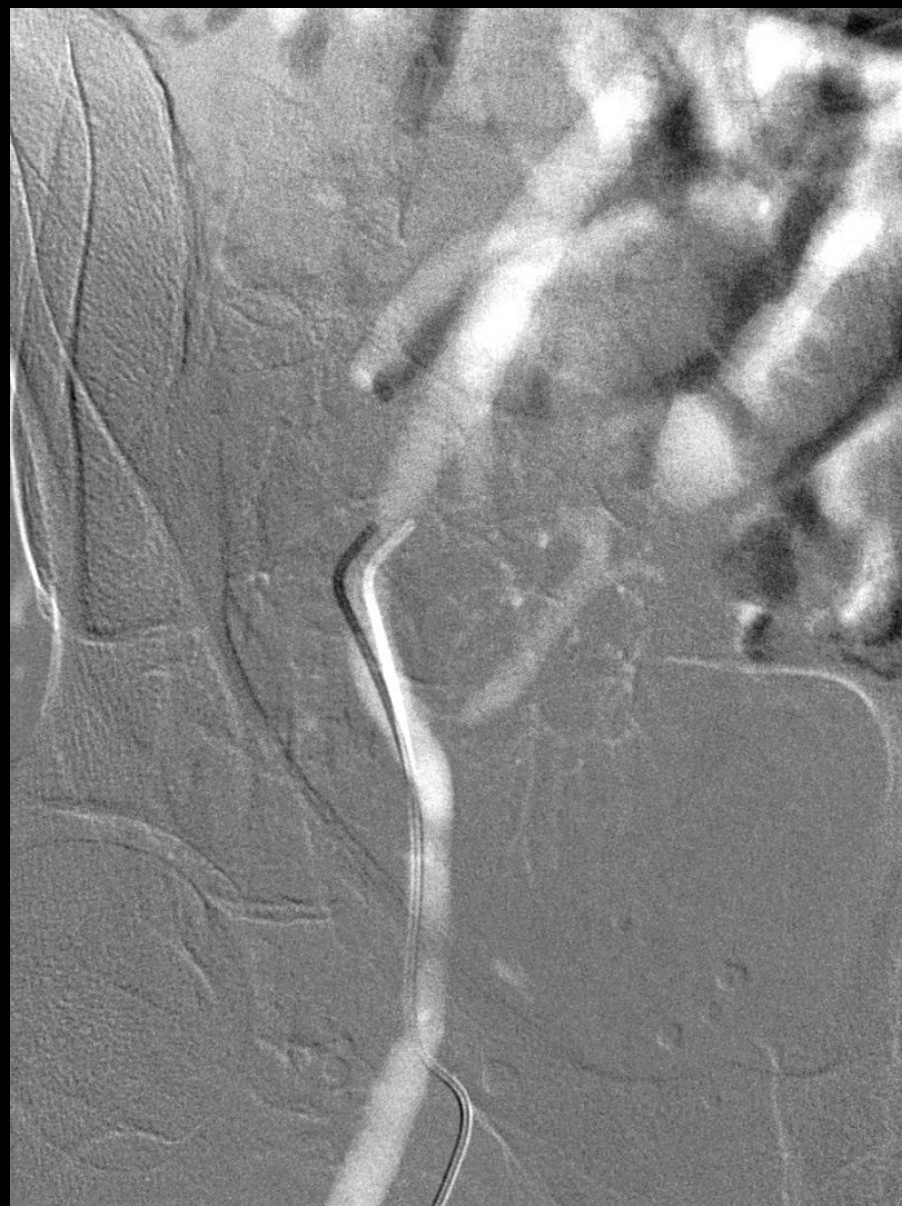
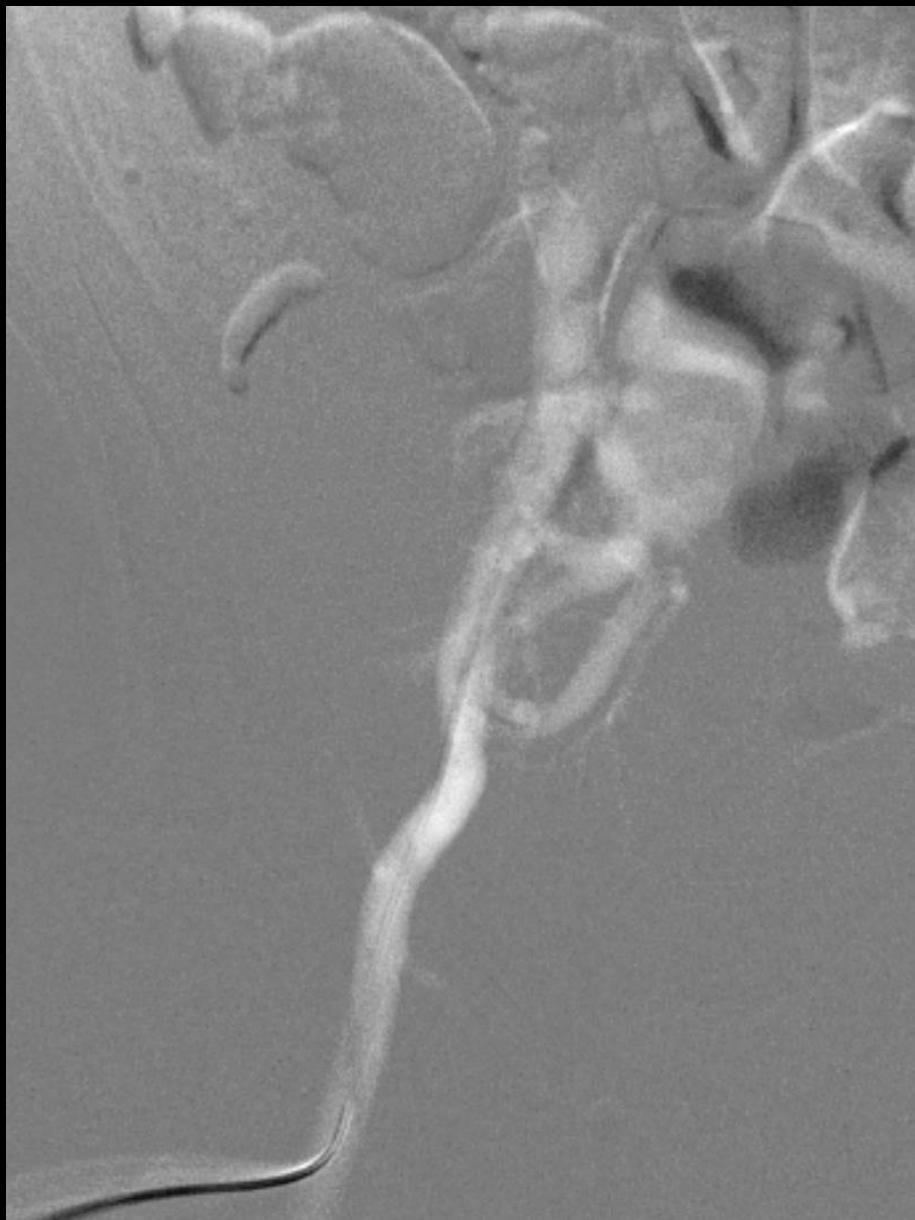


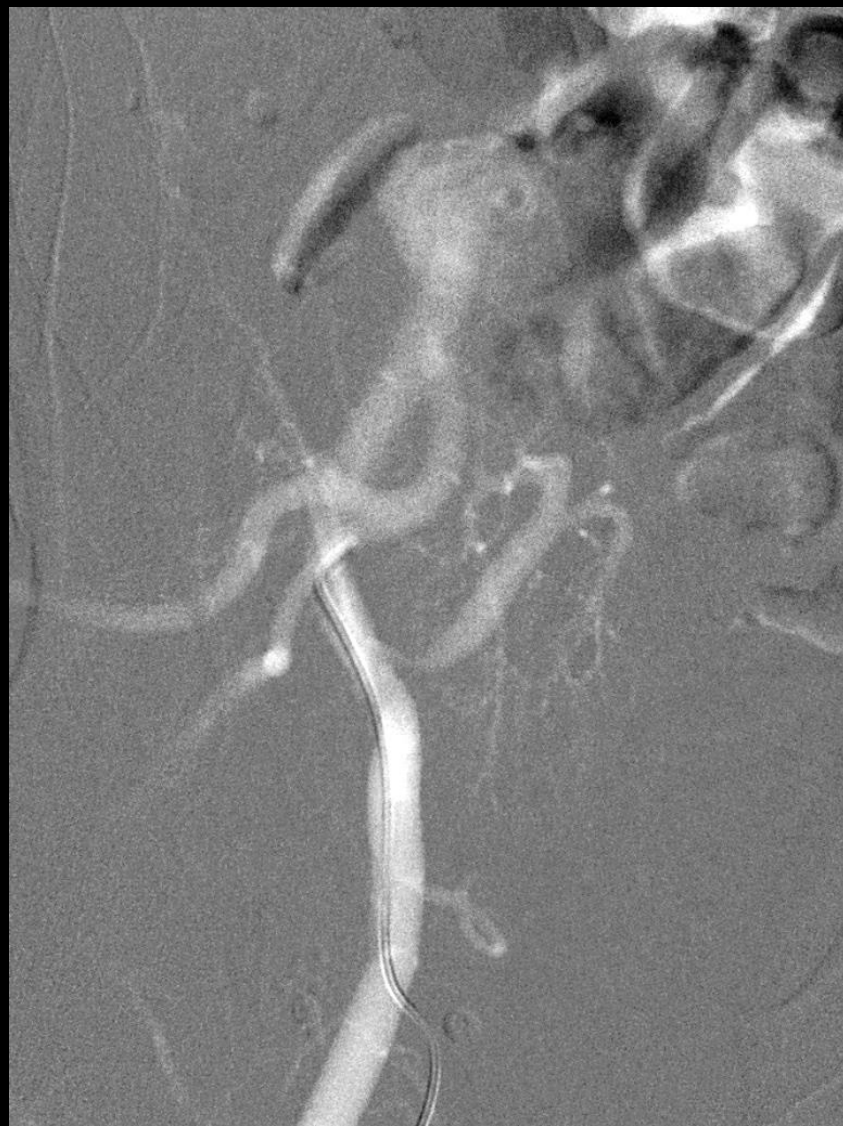
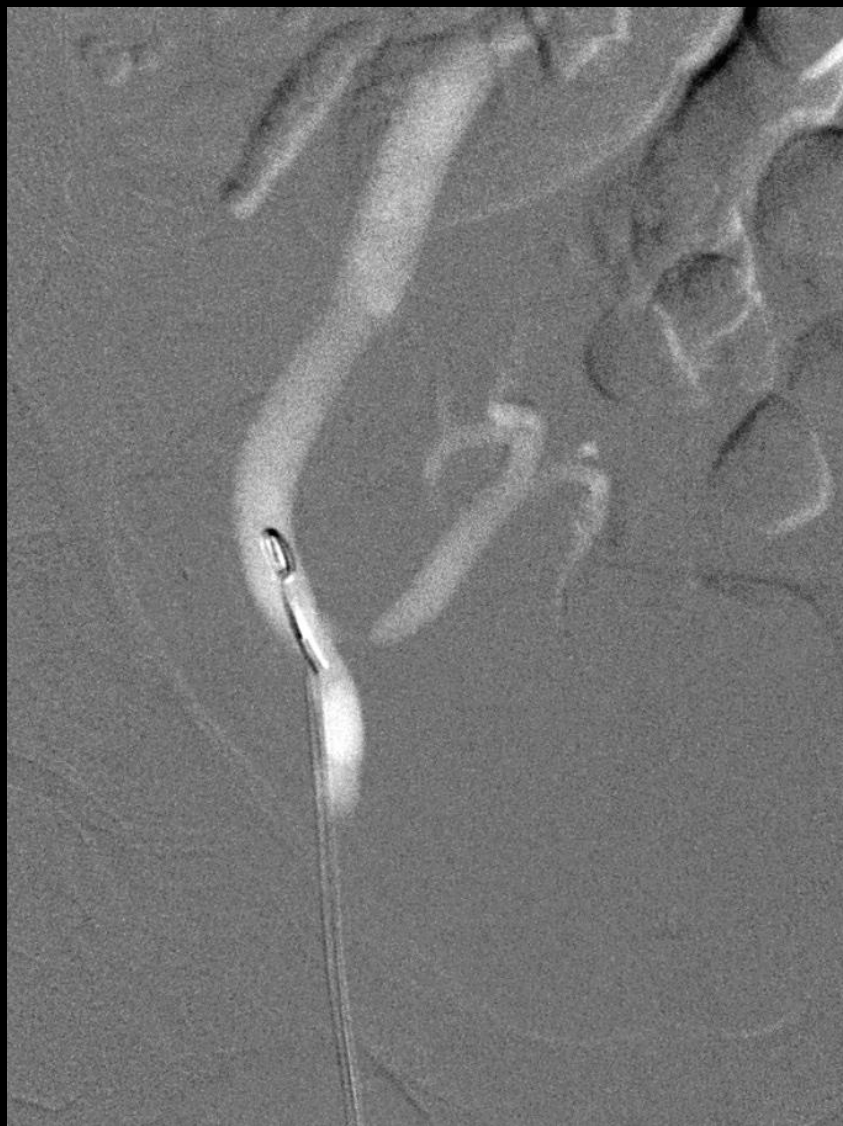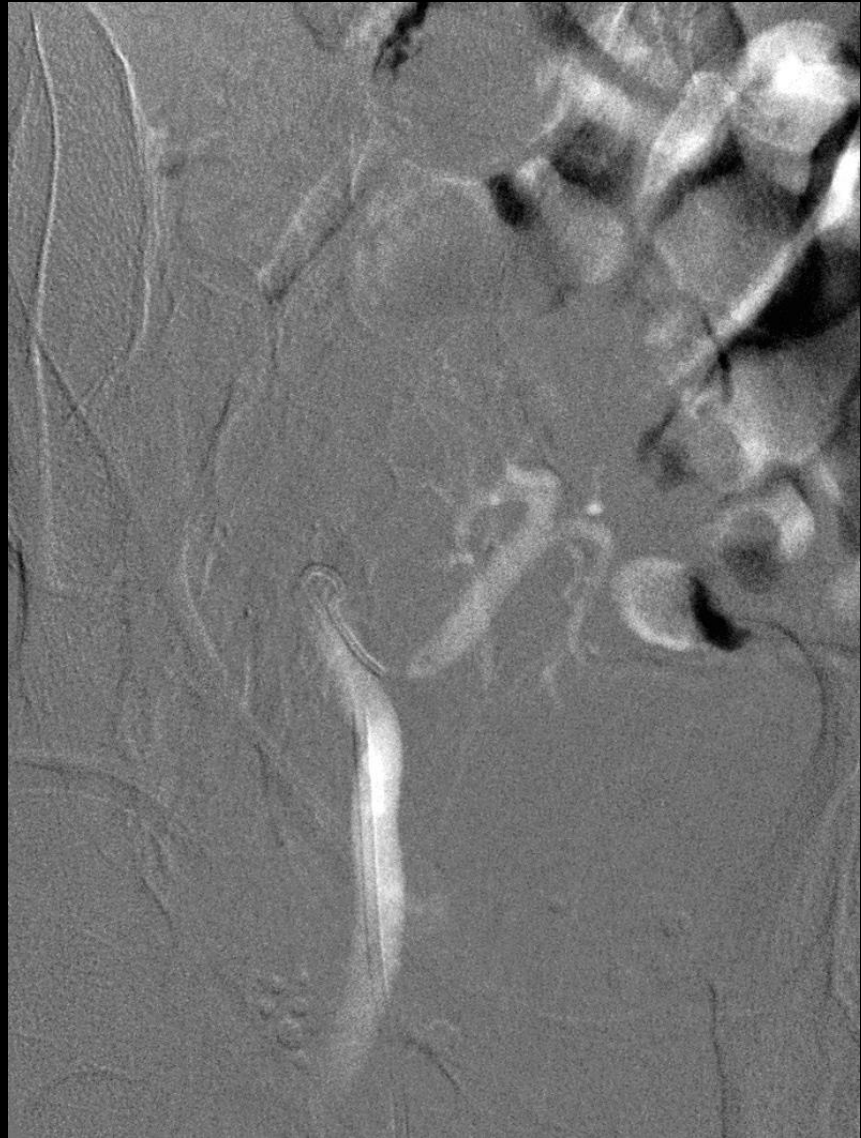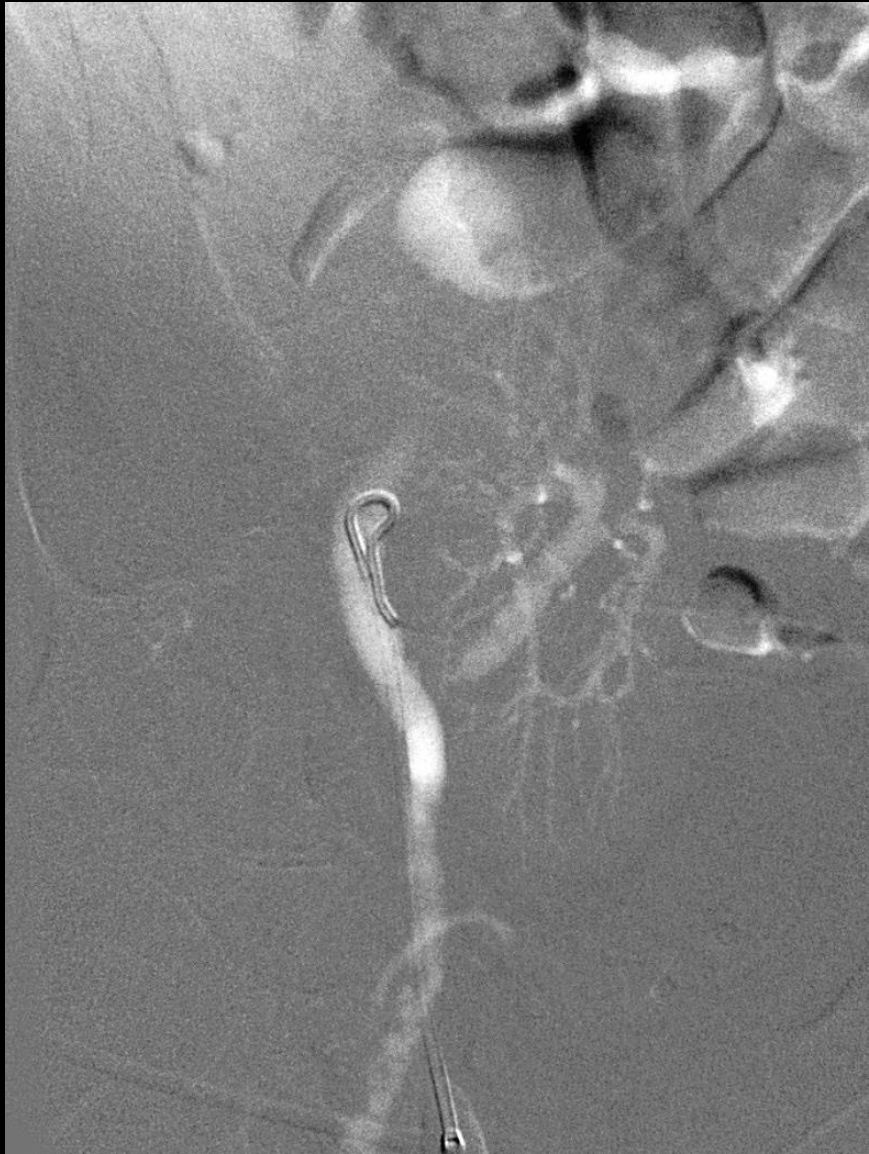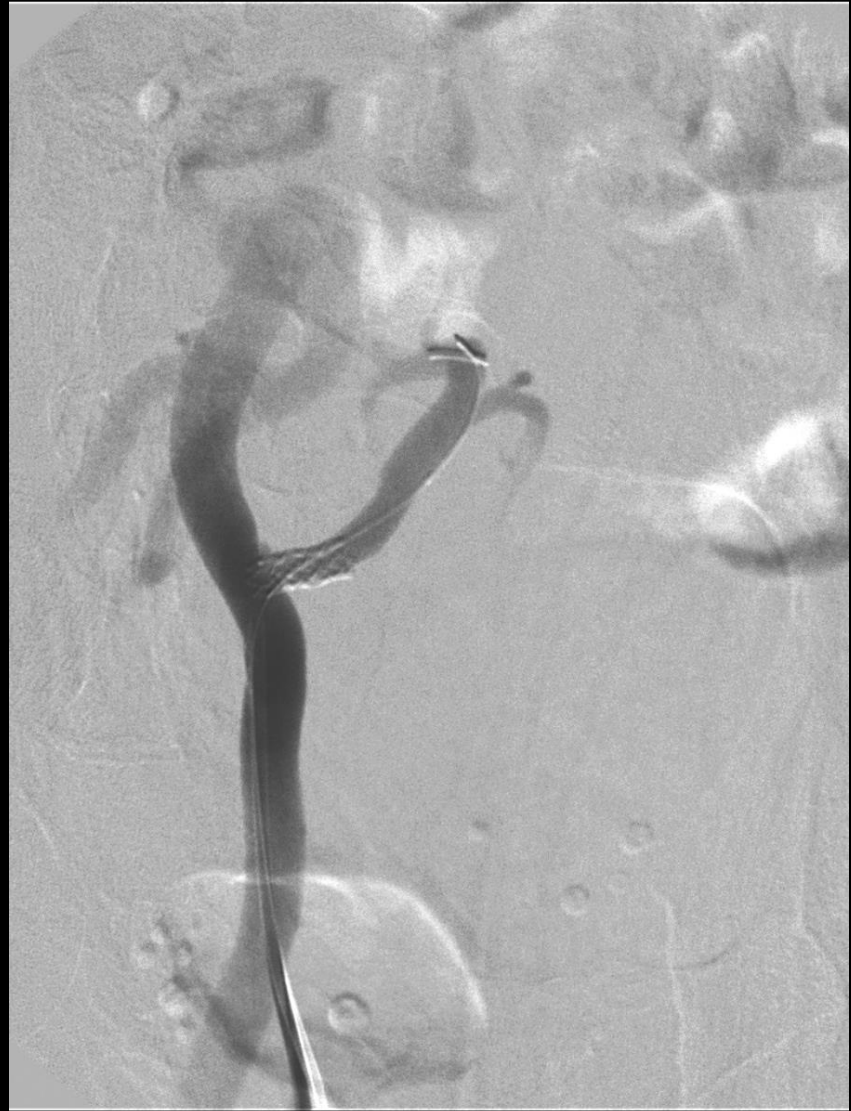


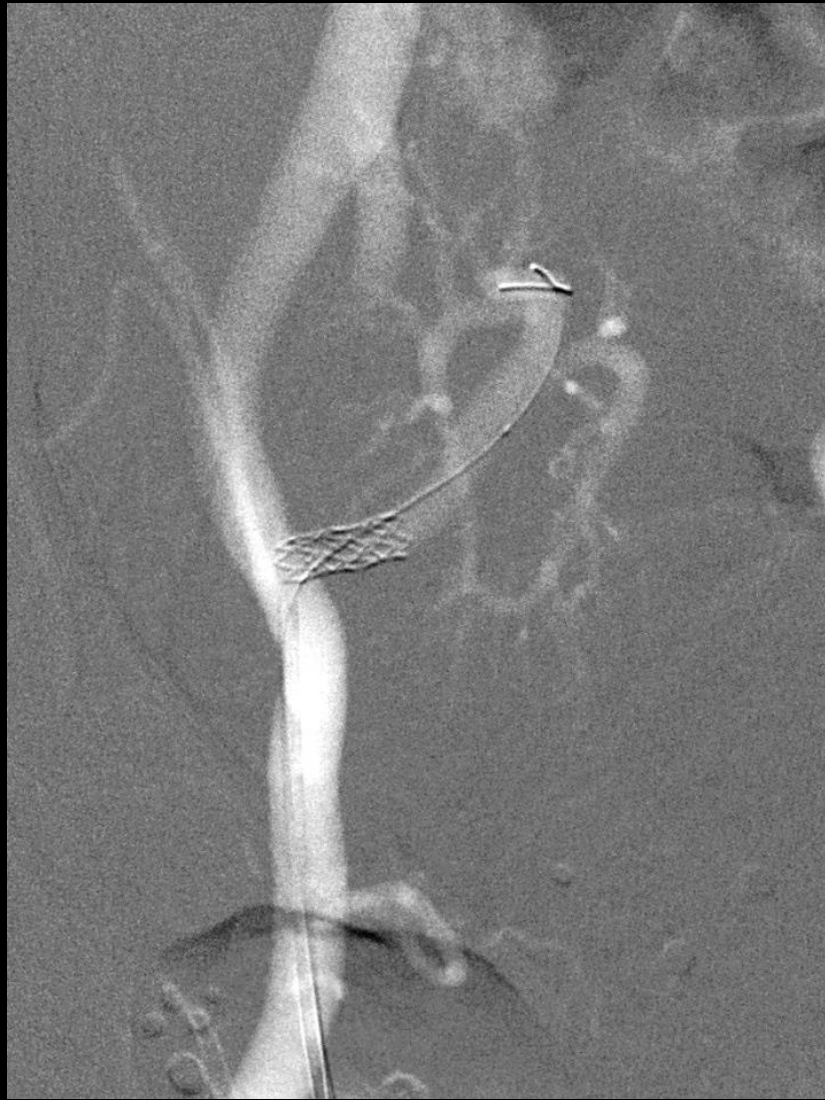**CO₂ RENAL STENT IN TRANSPLANT
USING HAIRPIN CATHETER**

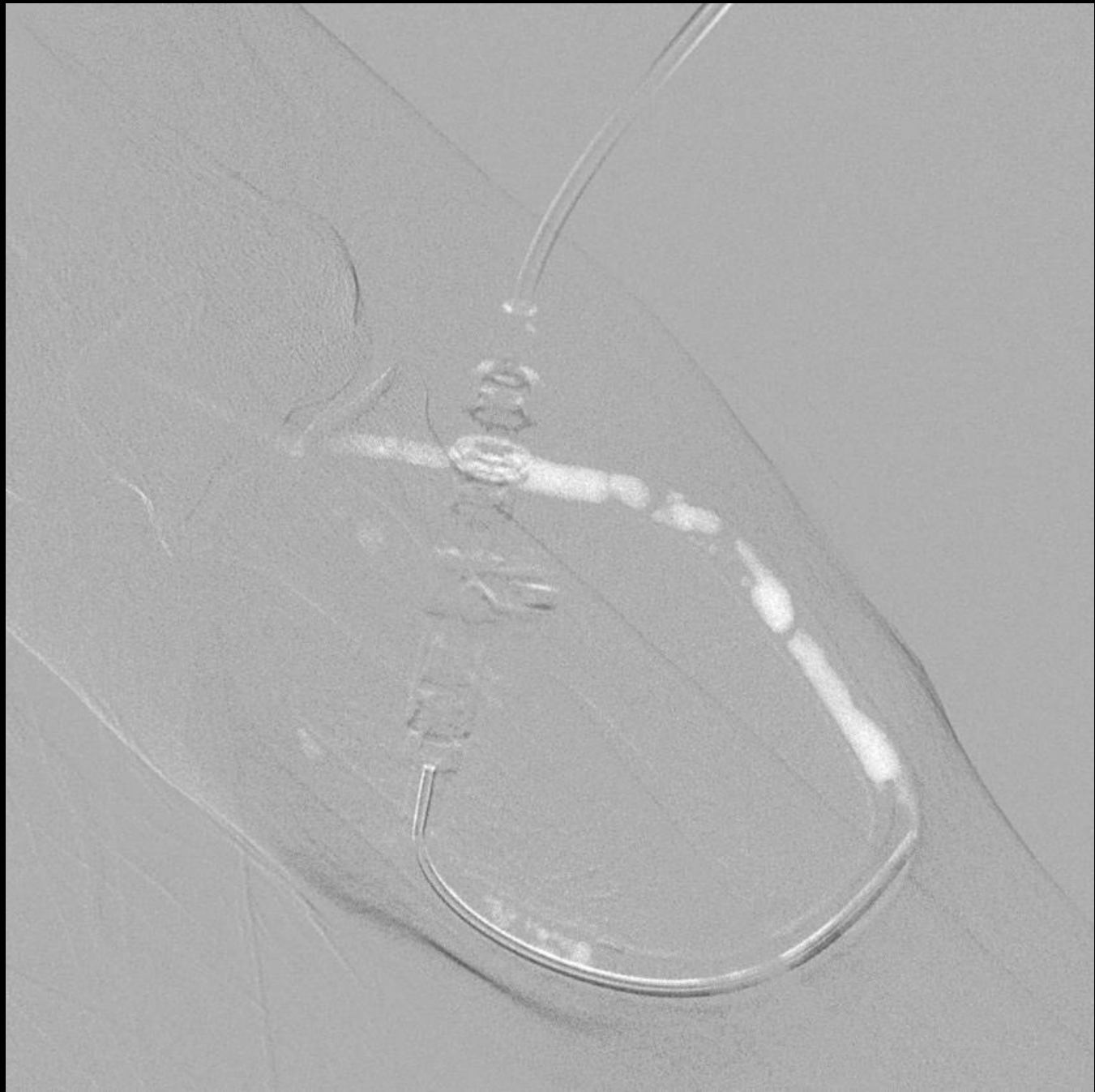


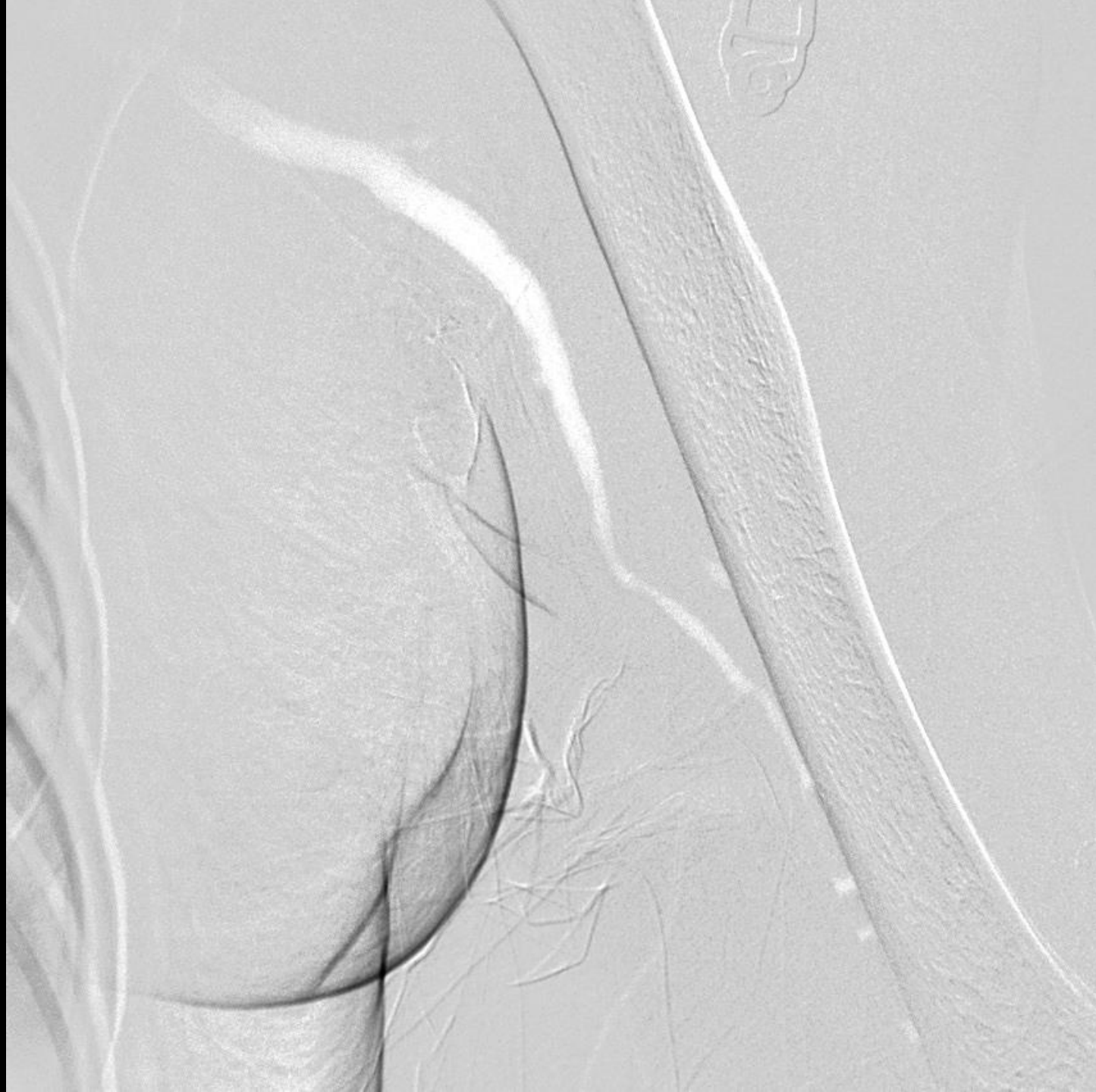


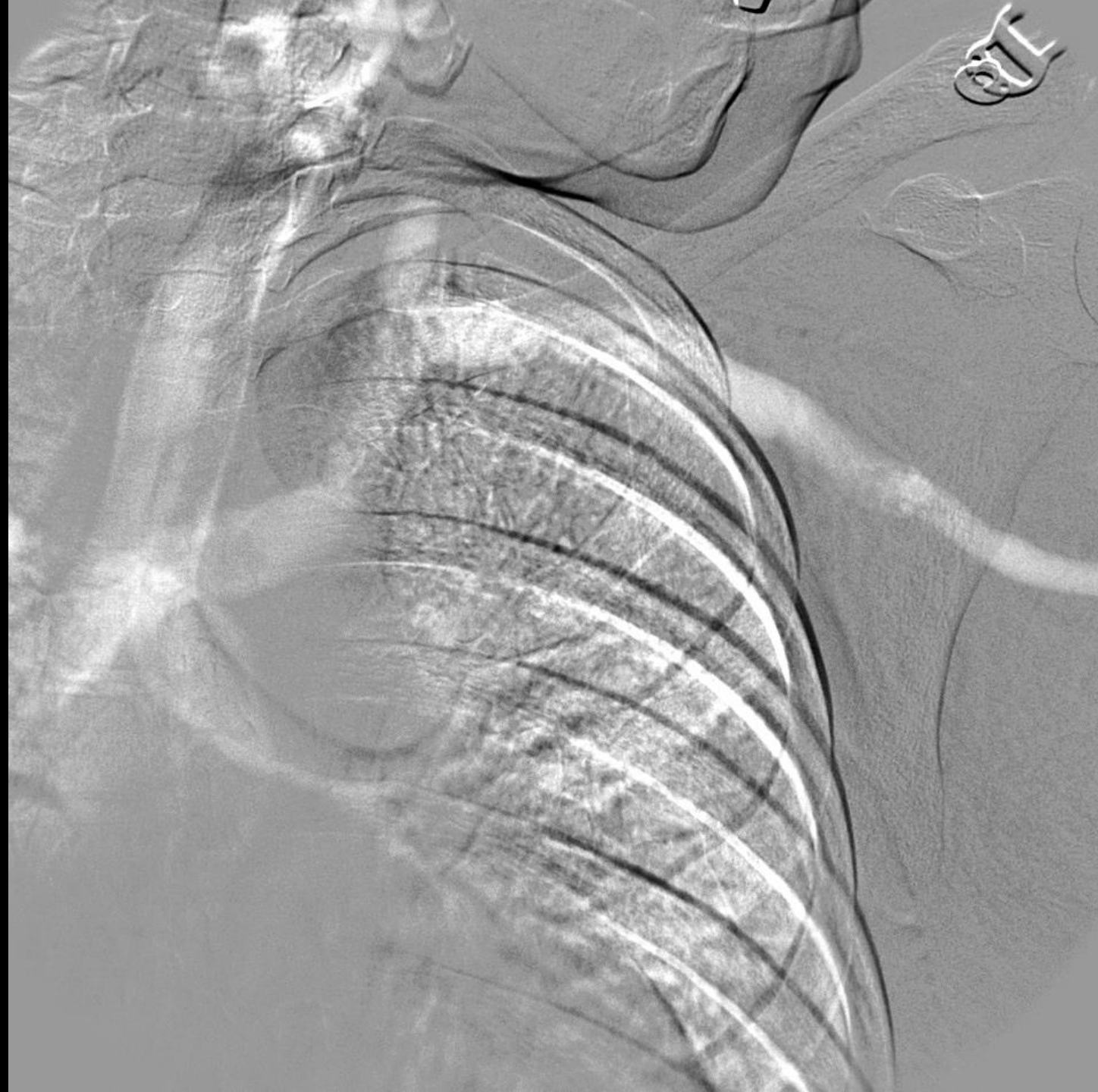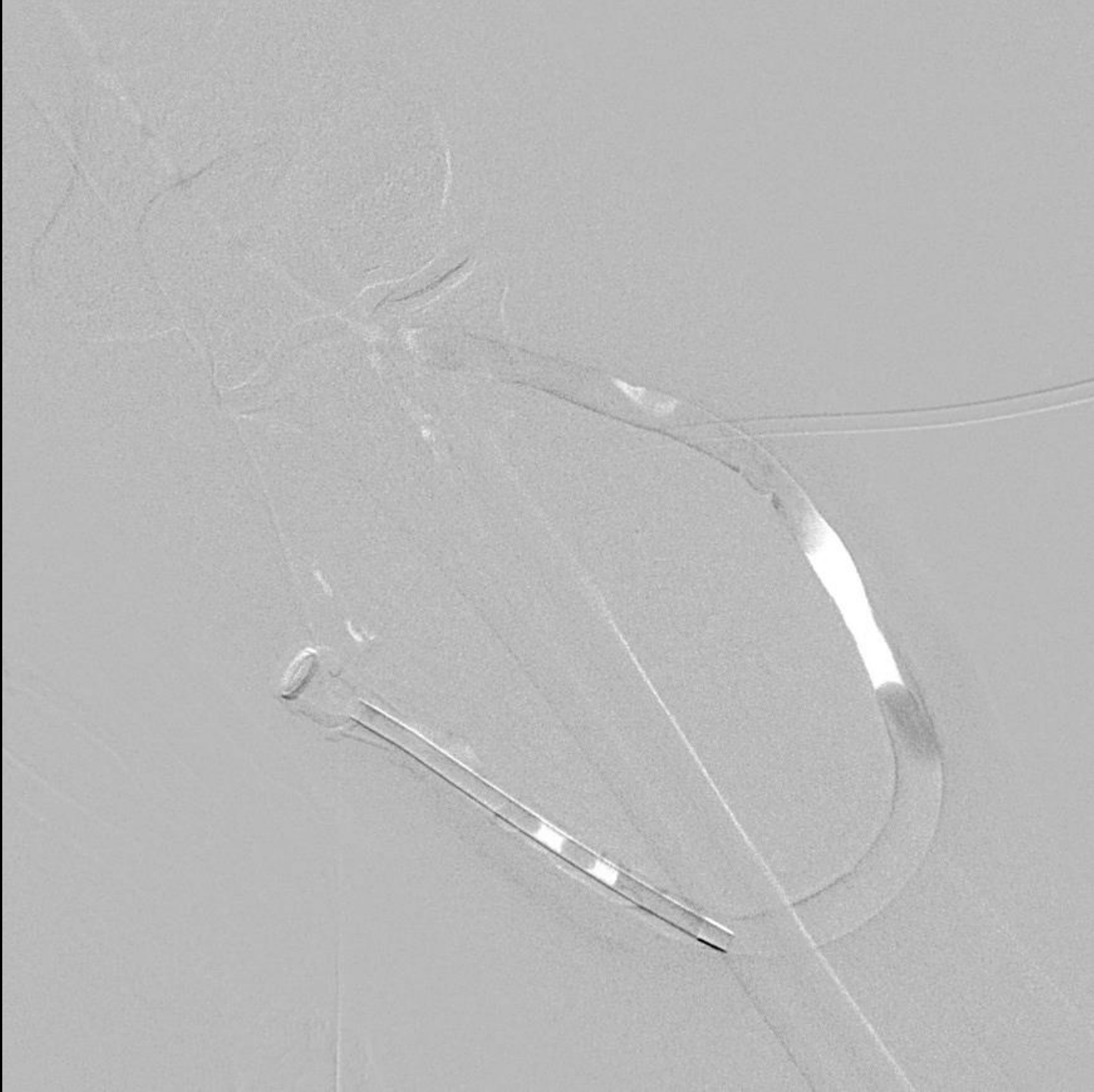


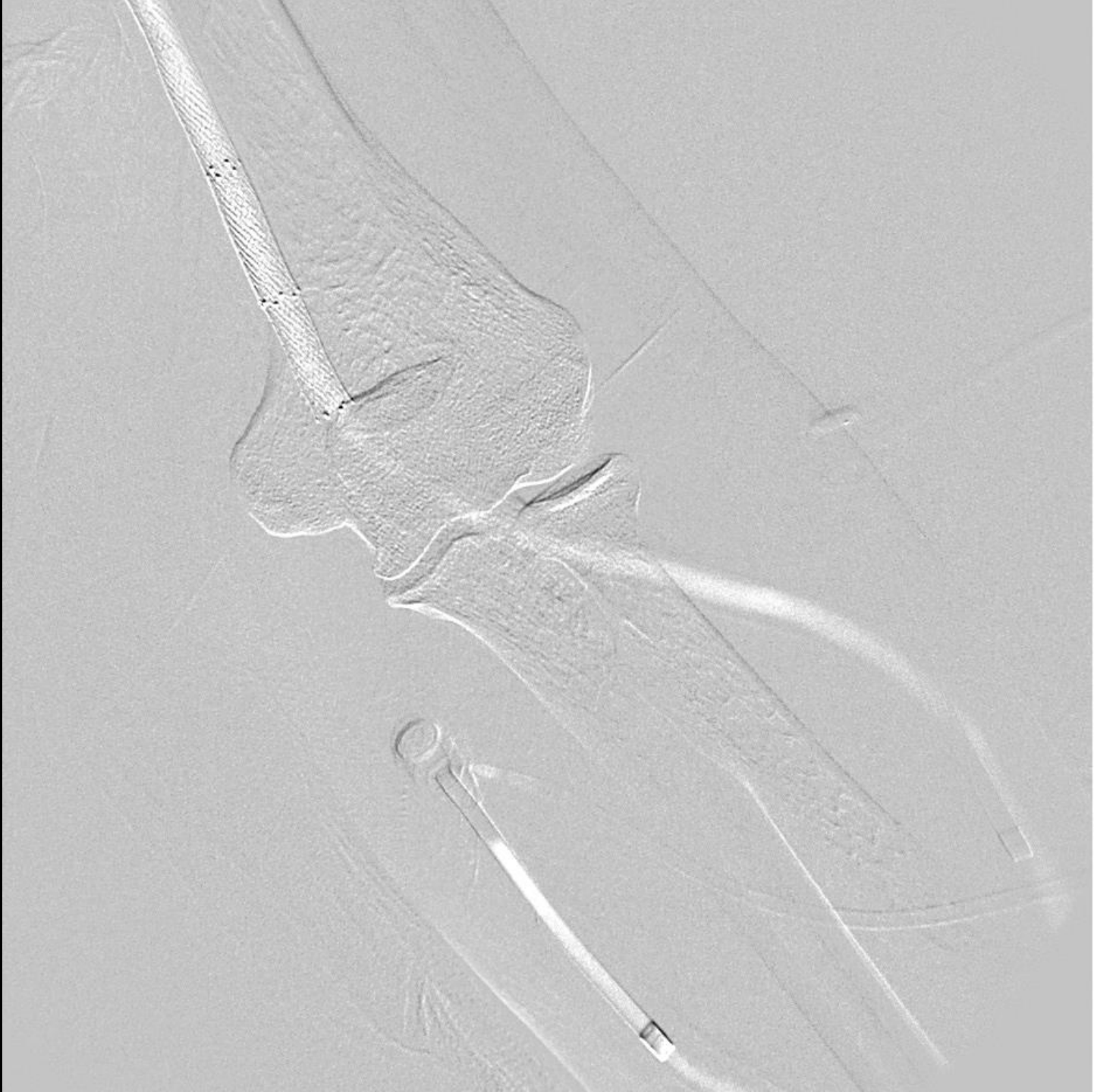CO2 DIALYSIS GRAFT DECLOT

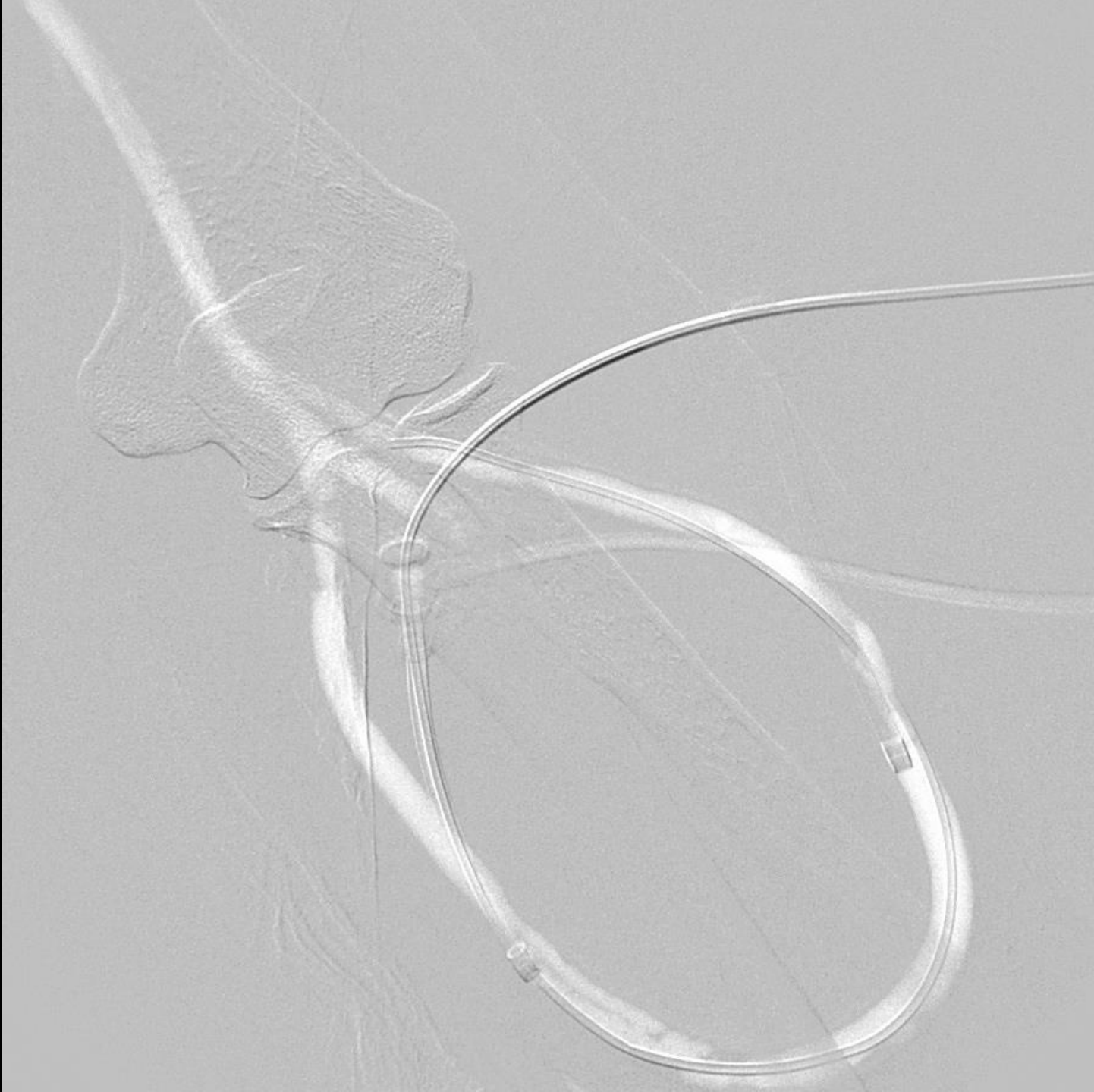


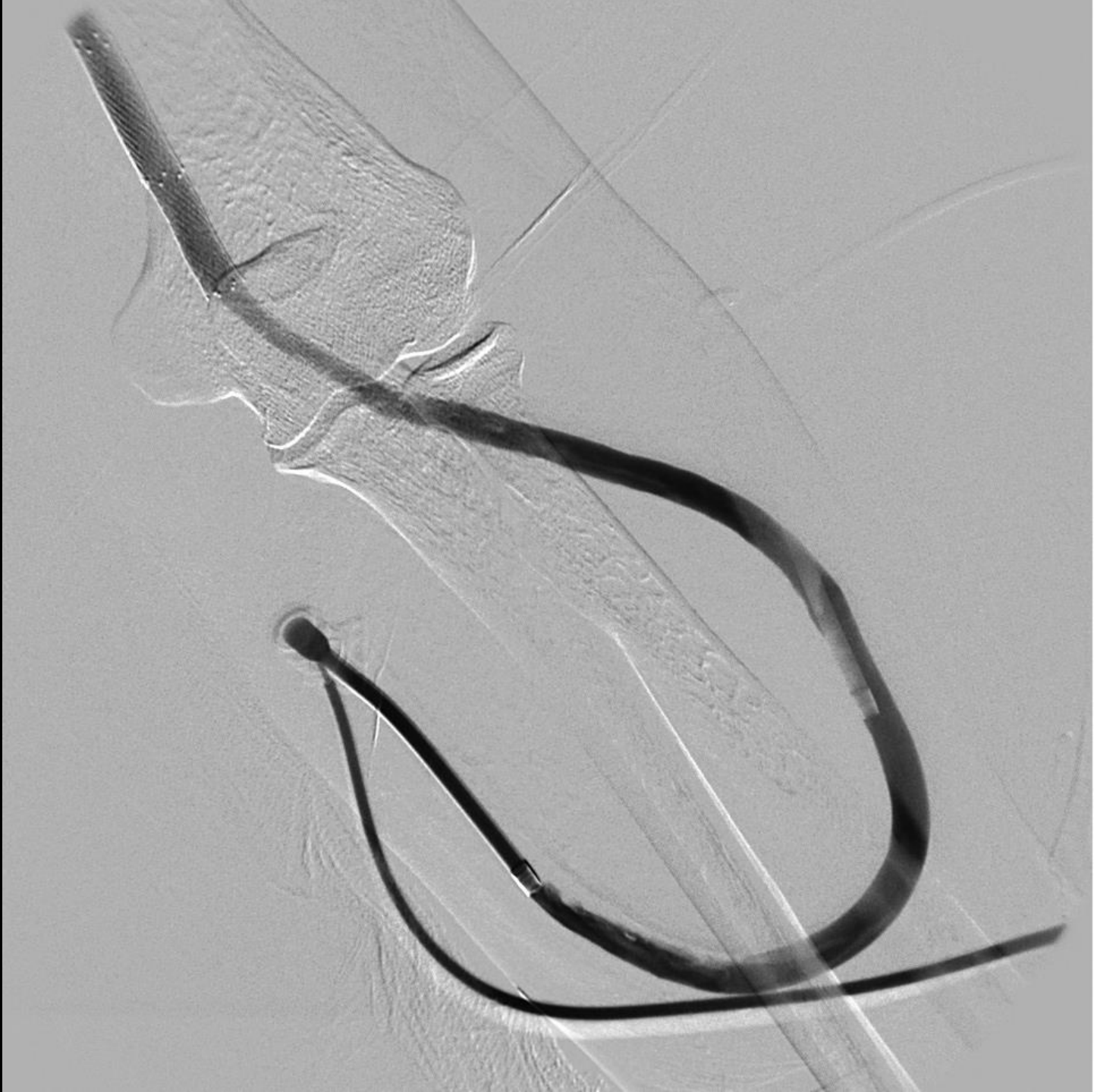


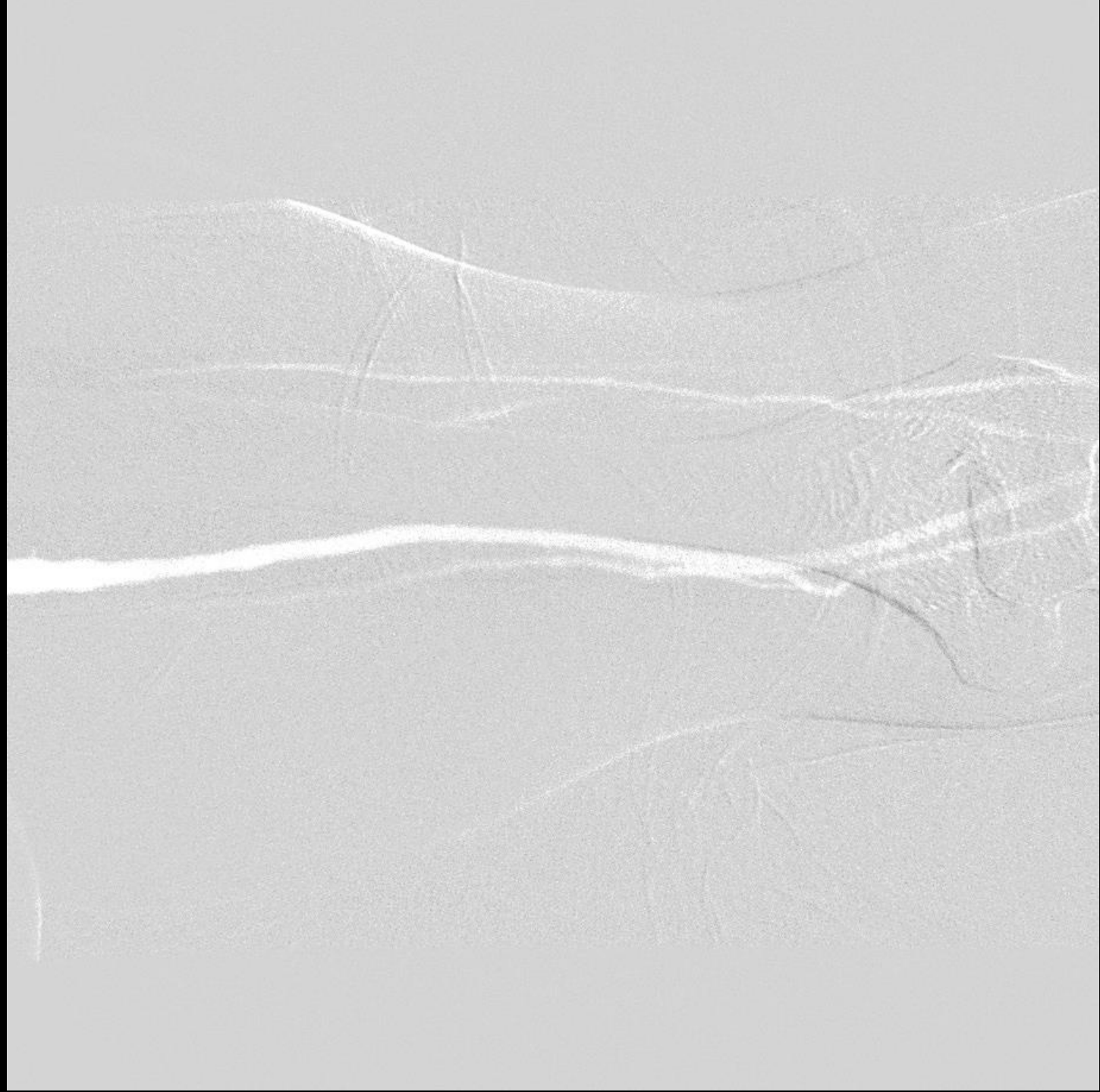




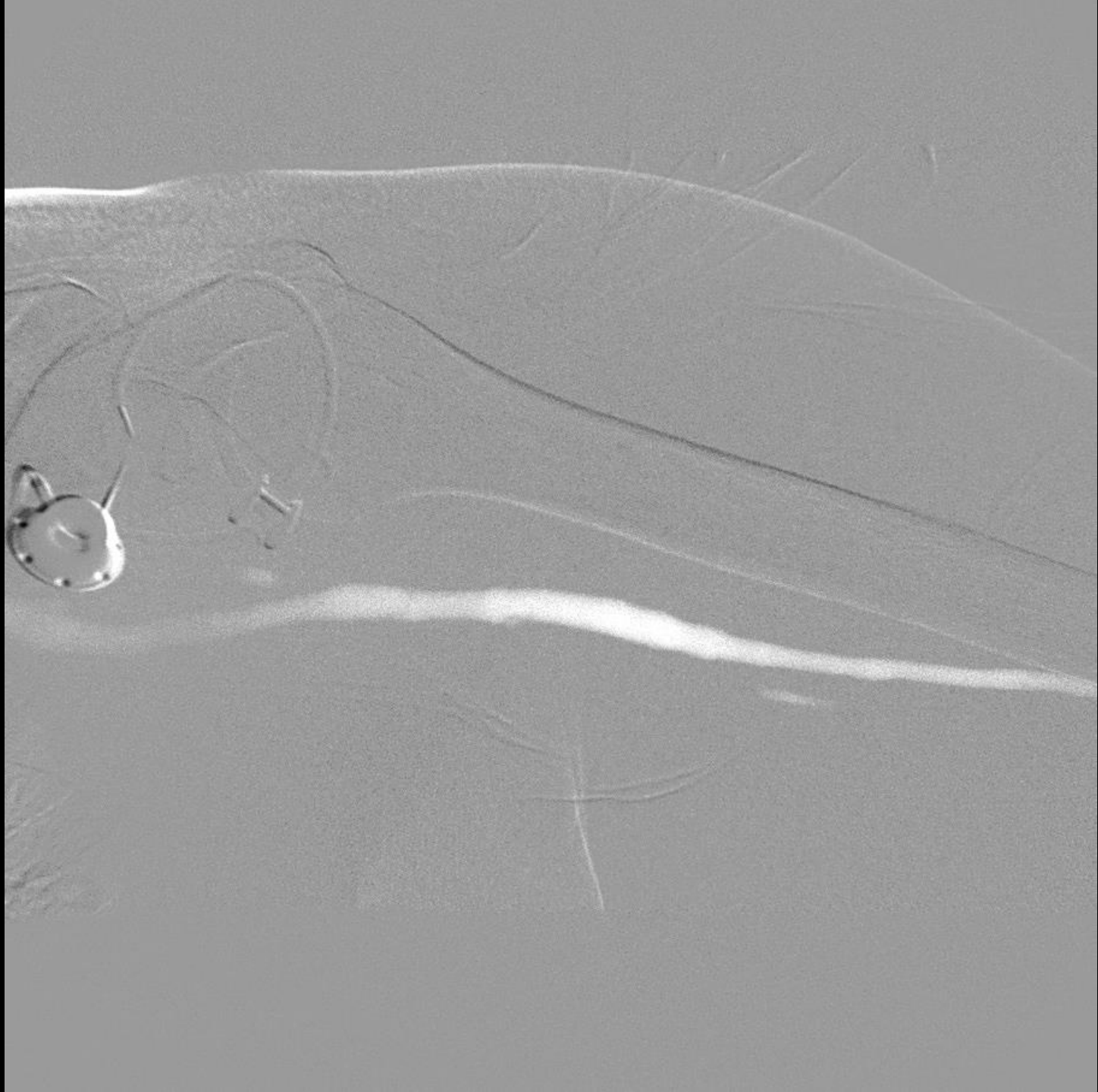


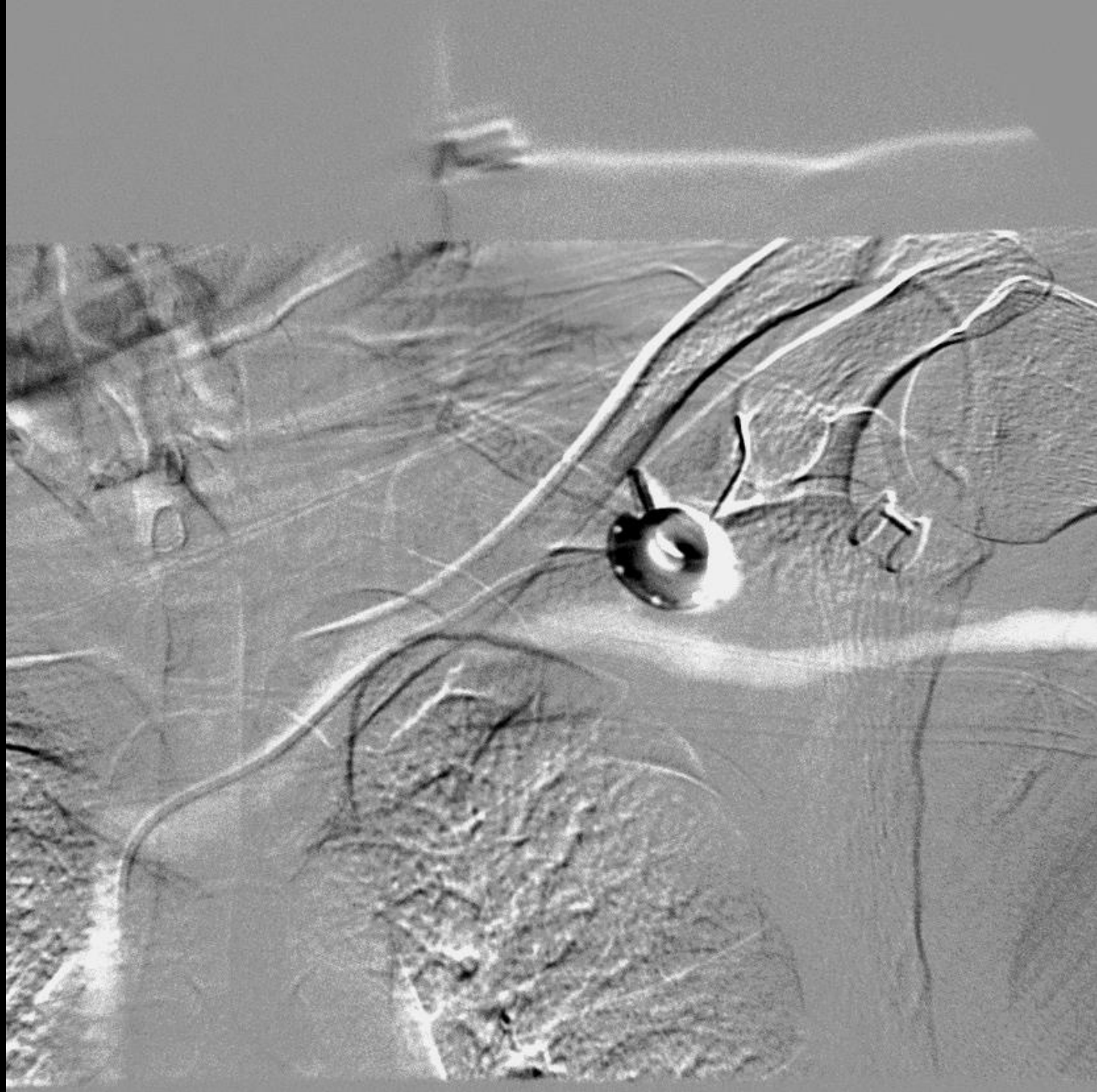
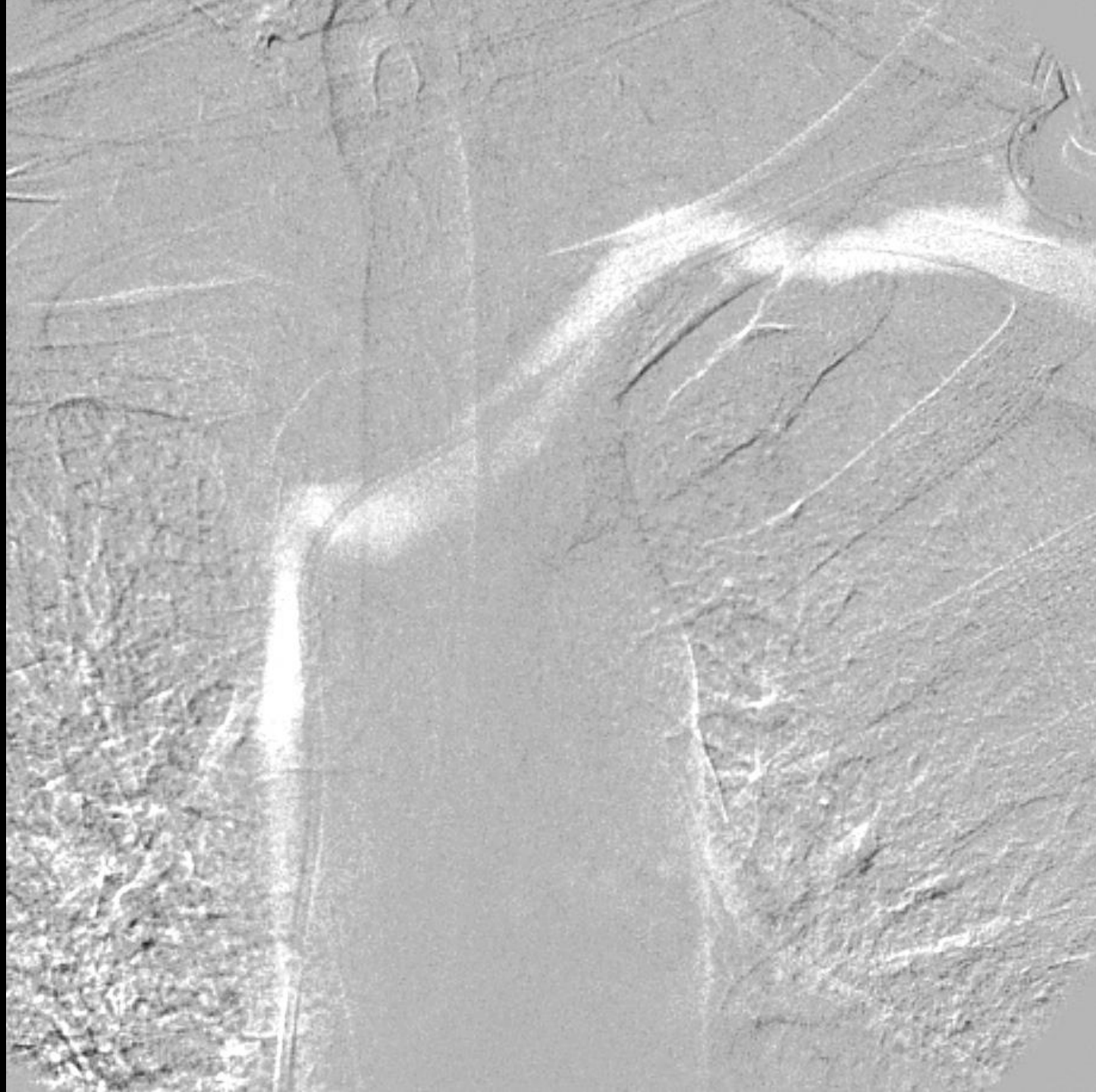CO₂ HAND VENOGRAM

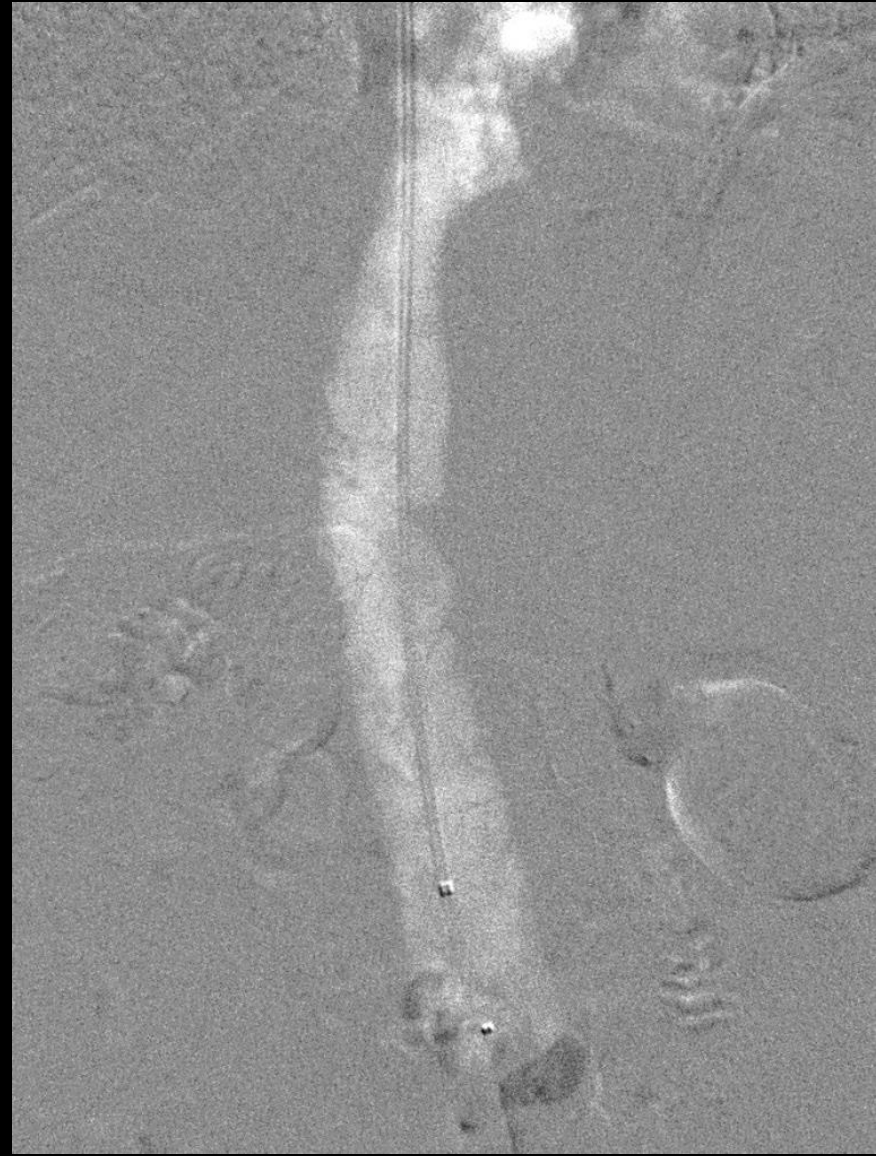
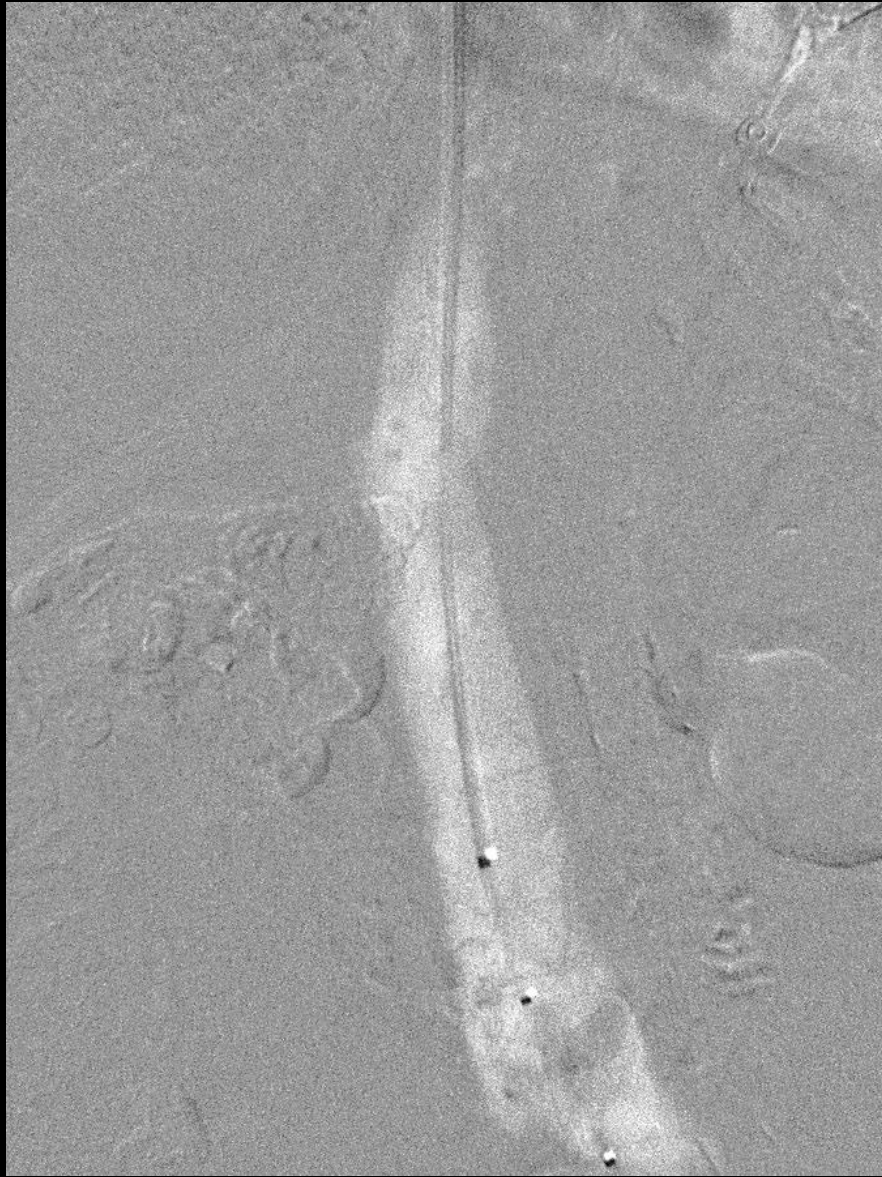


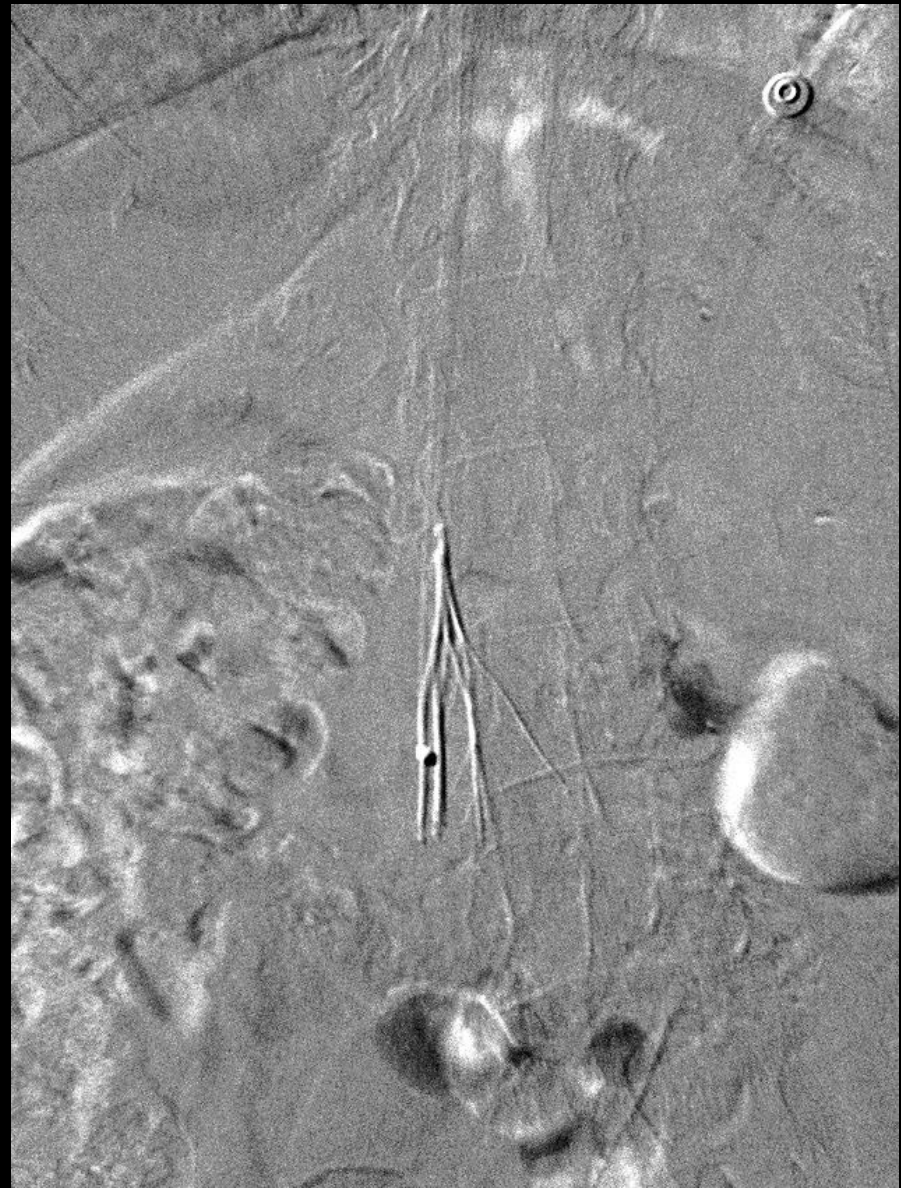
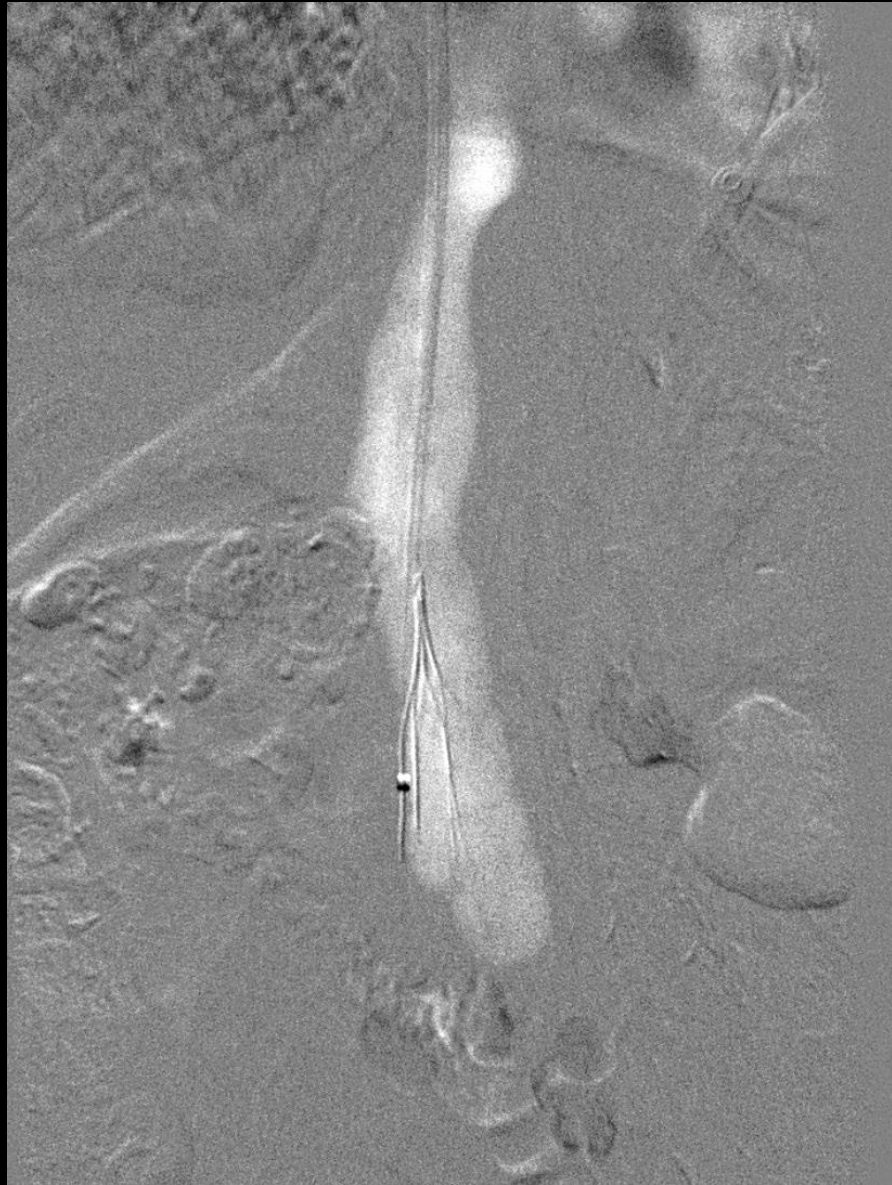


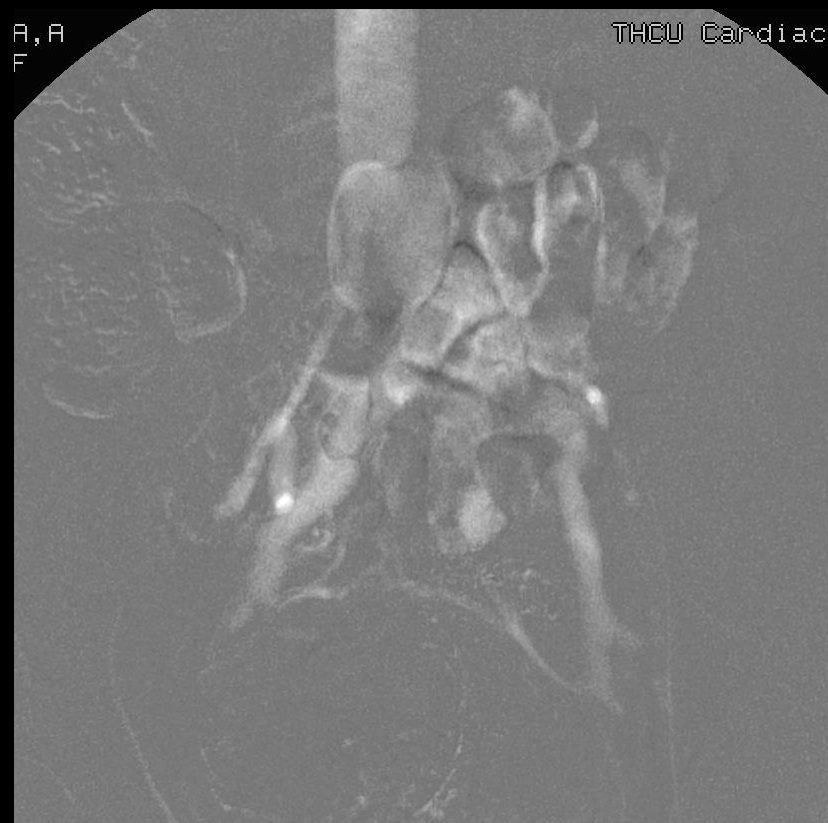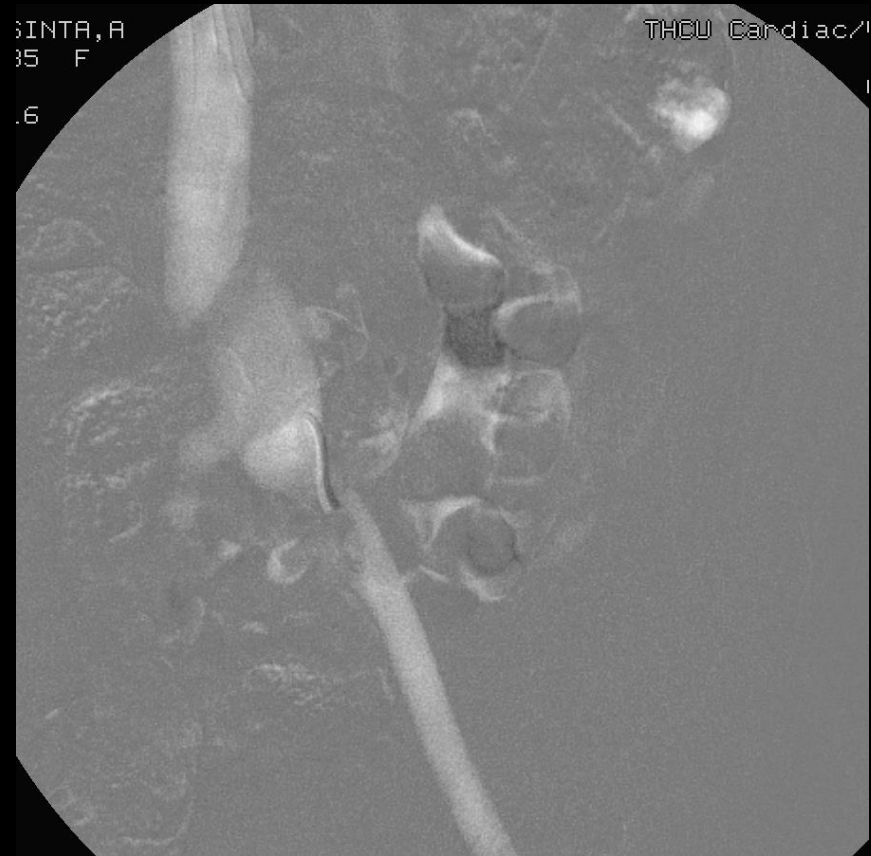CO₂ IVC Filter Placement



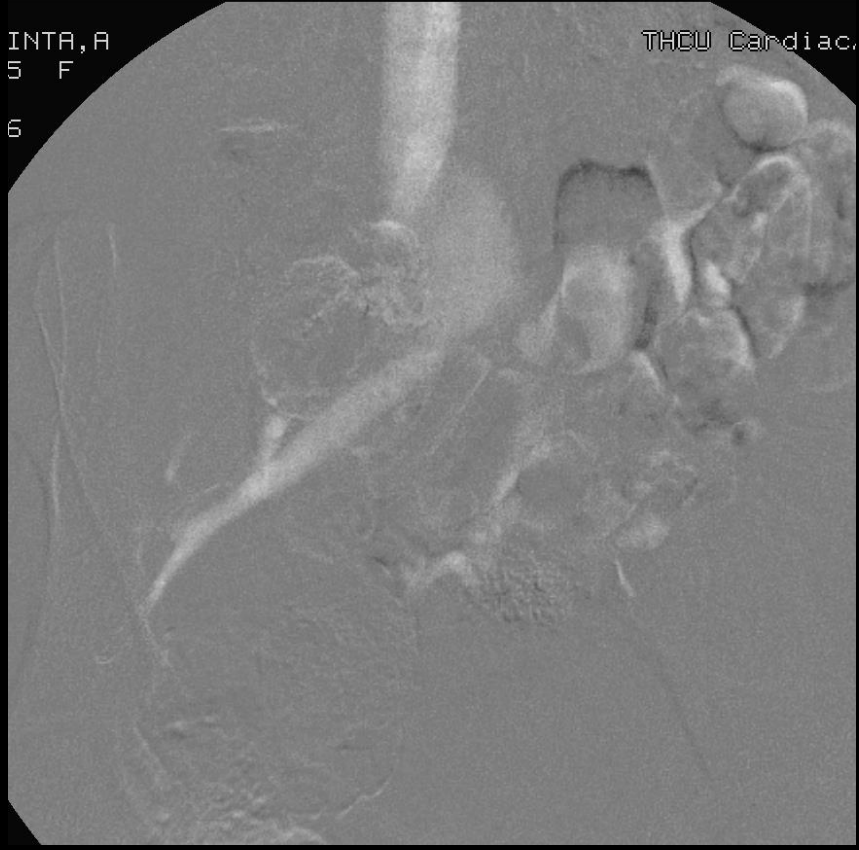

CO₂ MAY THURNER

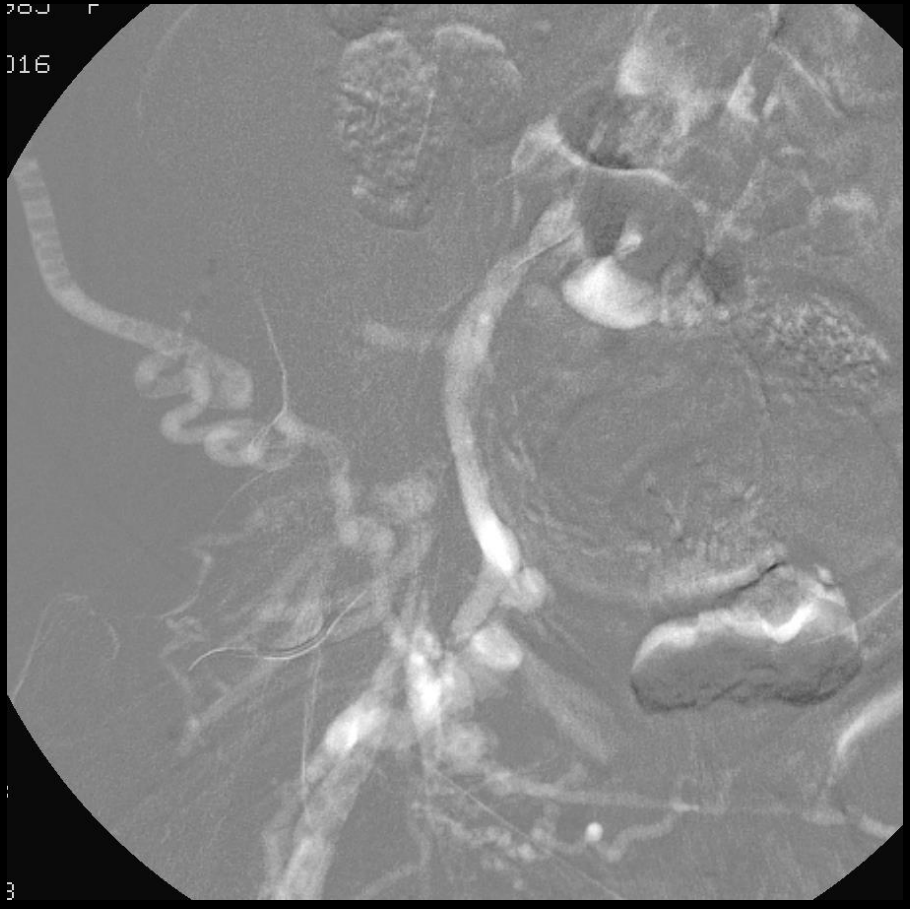


INTA, A
5 F
6

THOU Cardiac.

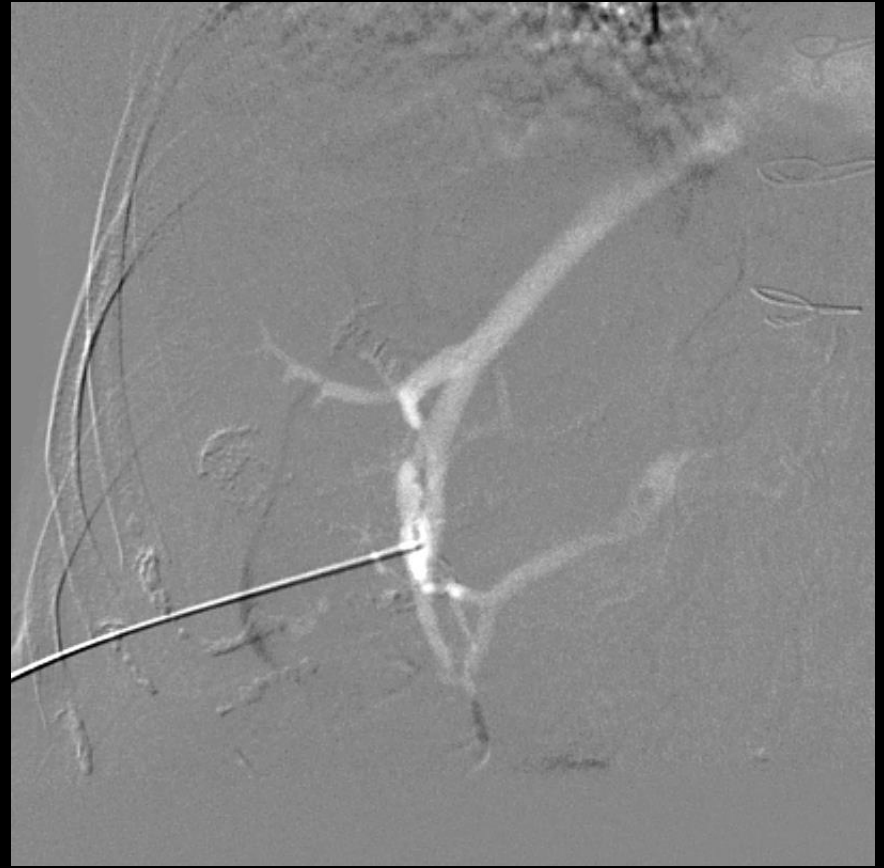
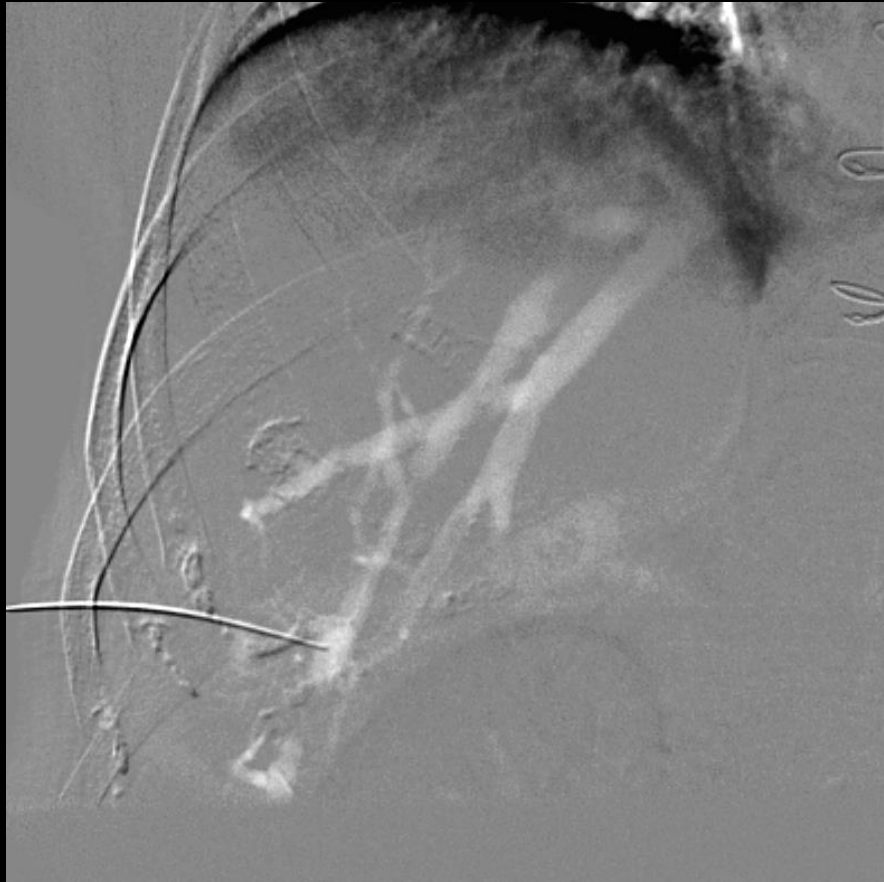
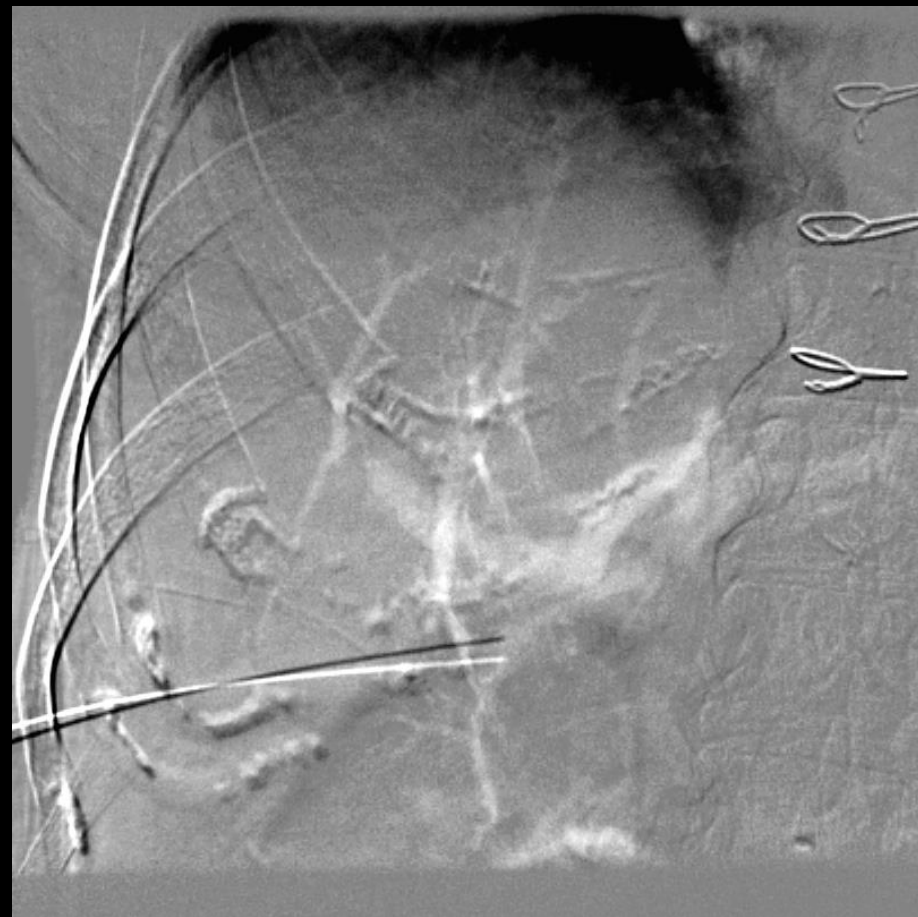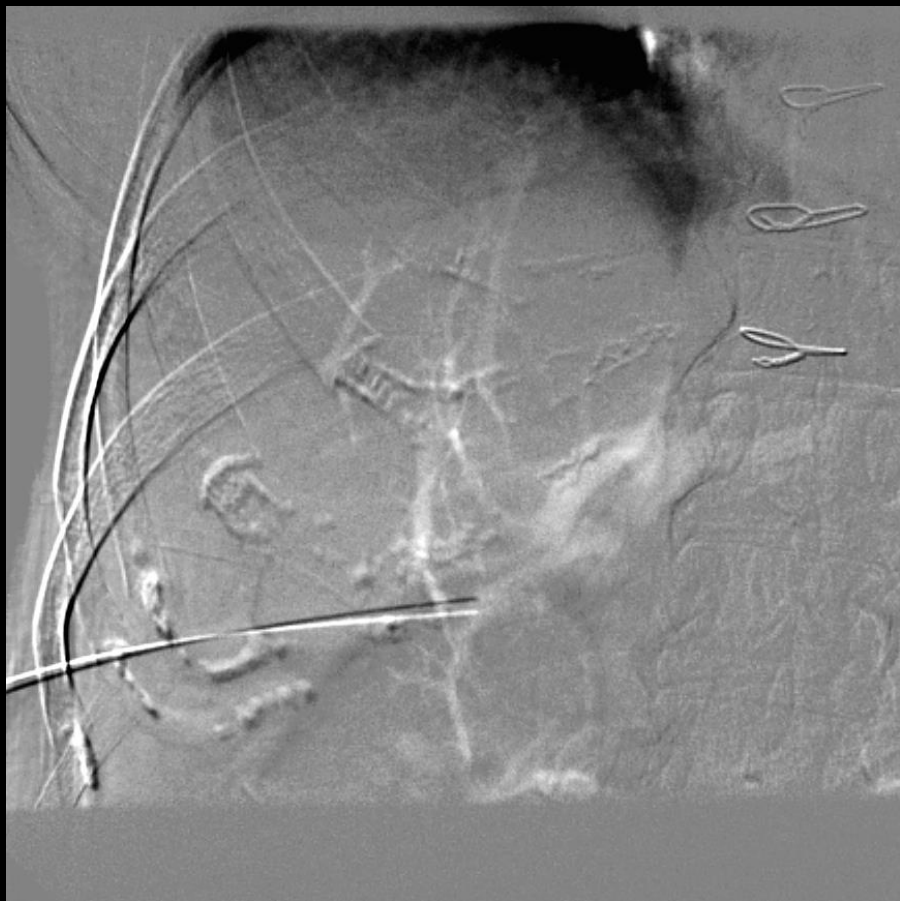700 F
116

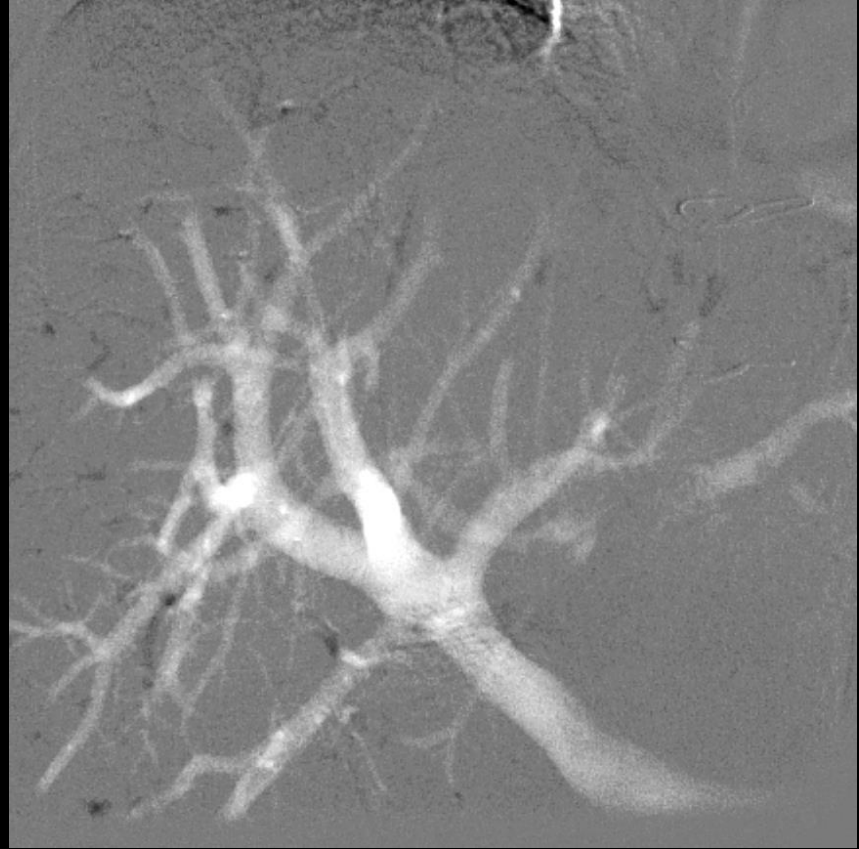
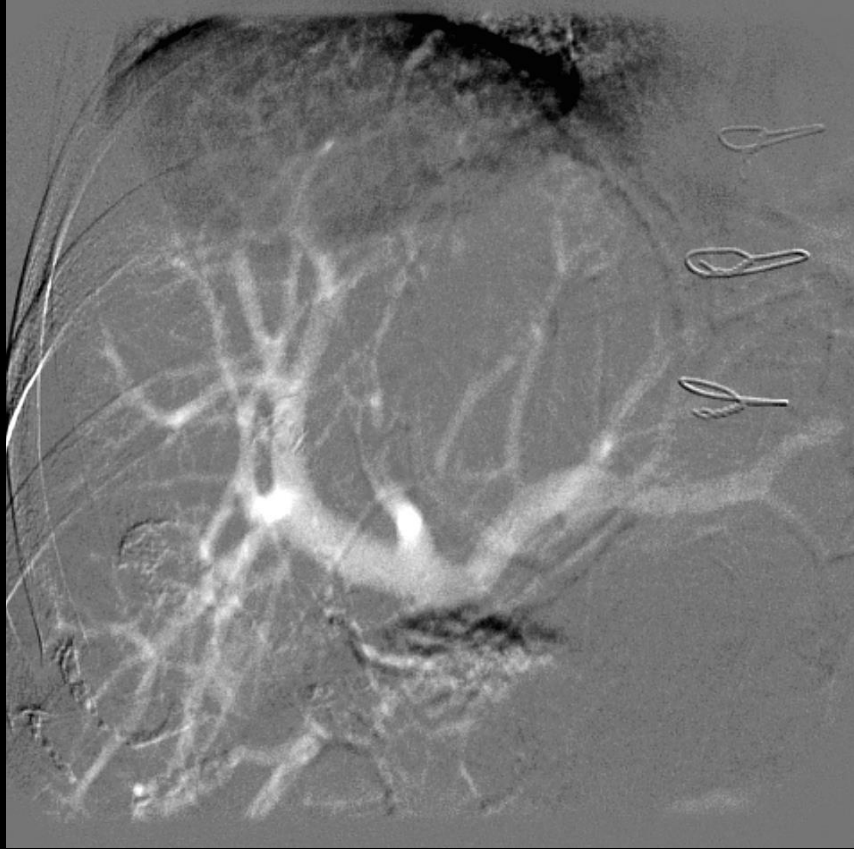
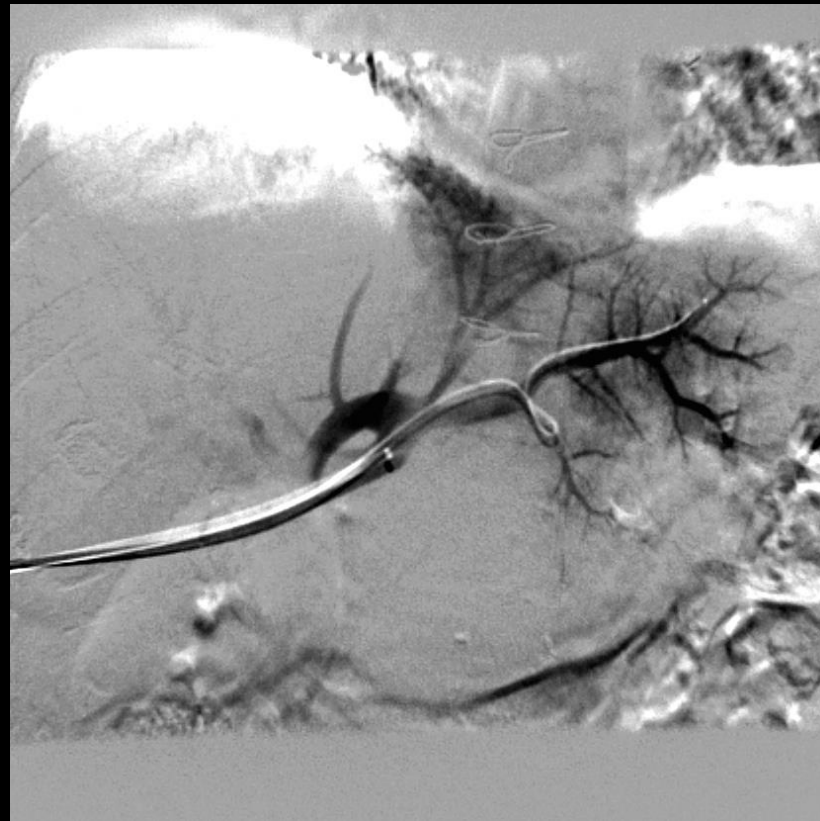
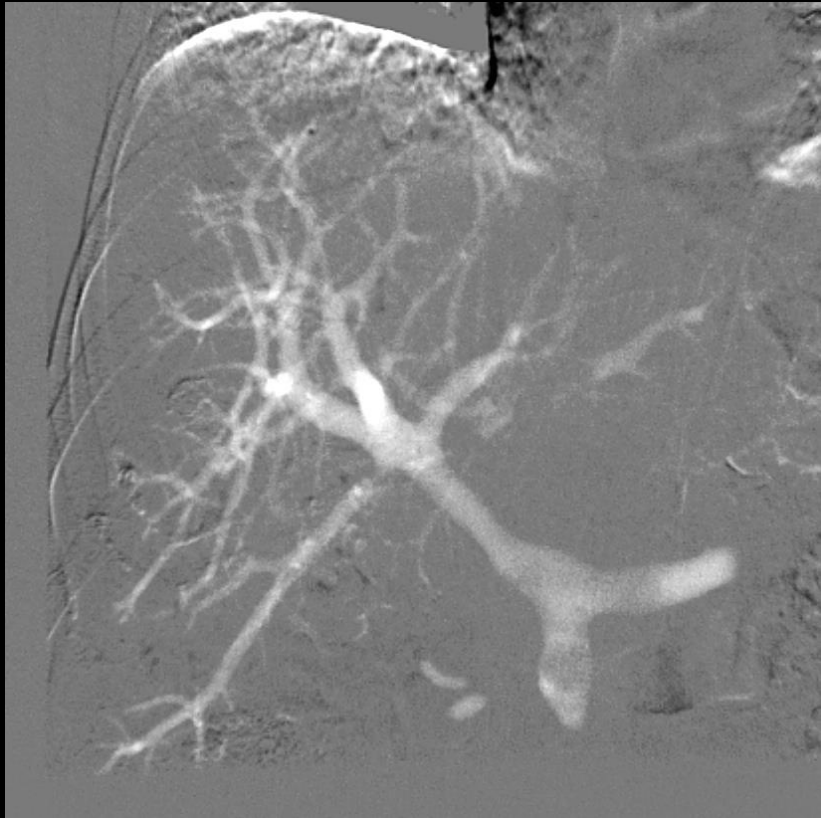3

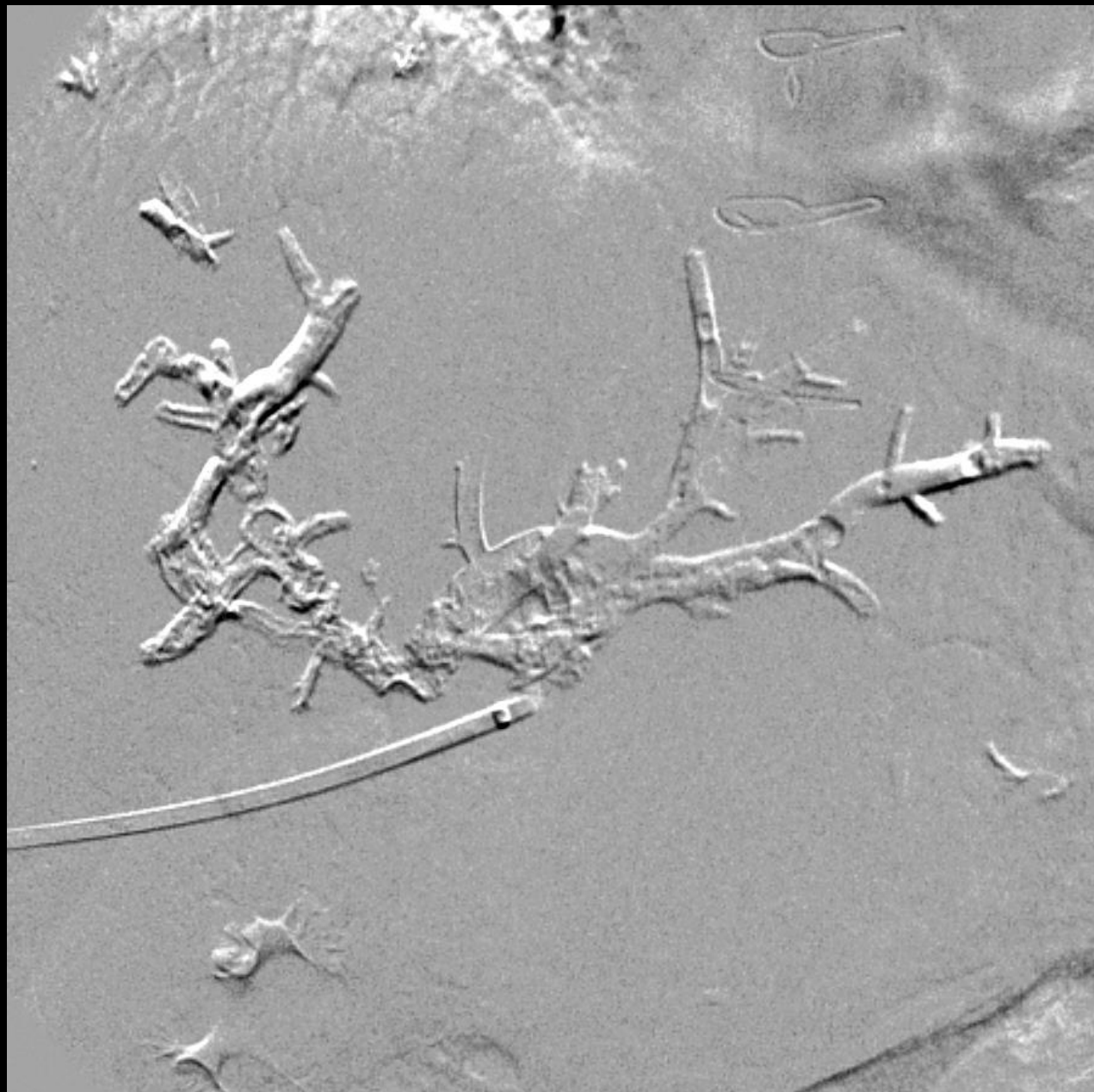**CO₂ PORTAL VEIN
EMBOLIZATION**

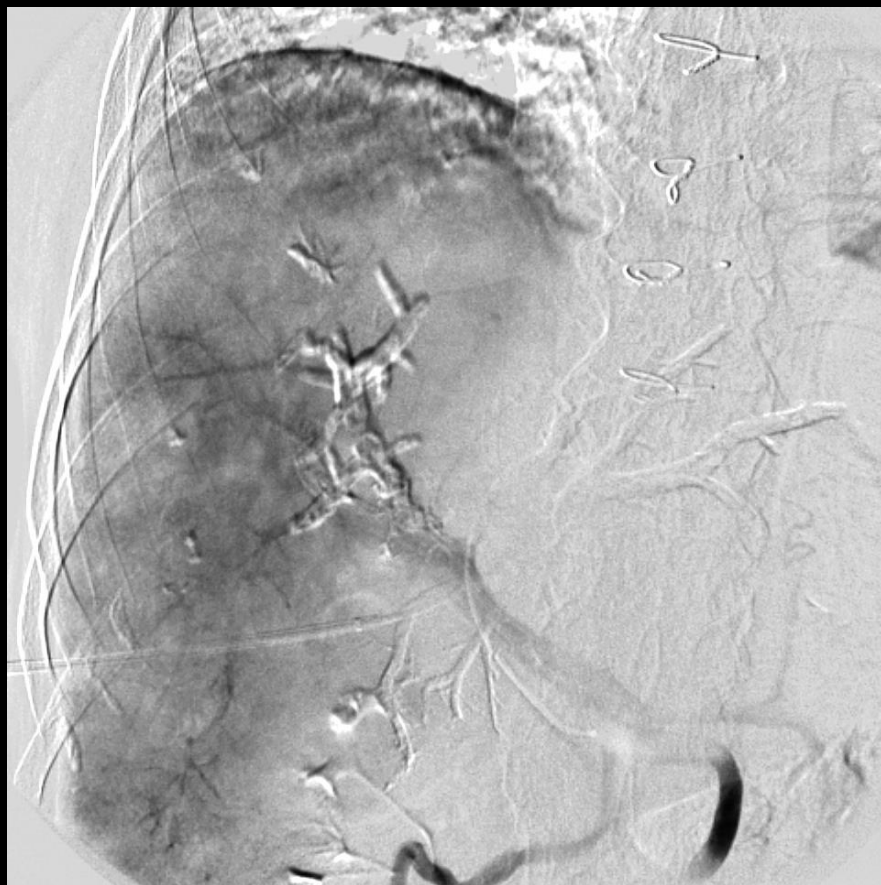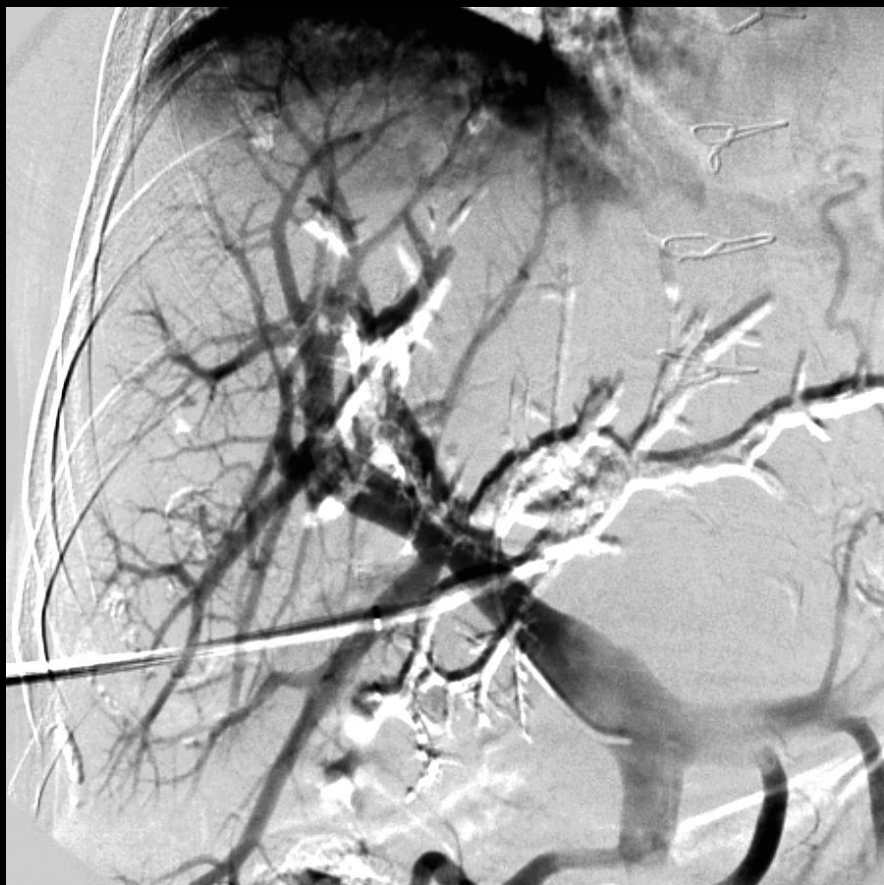




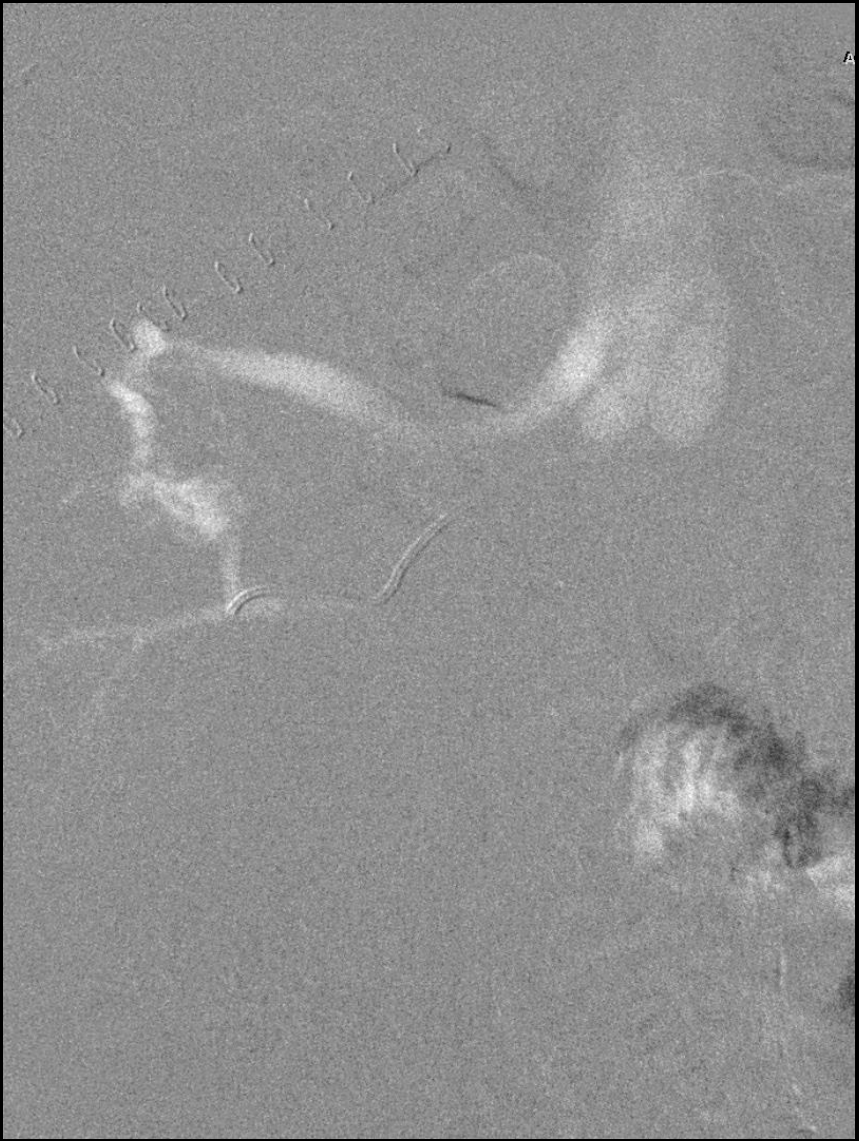
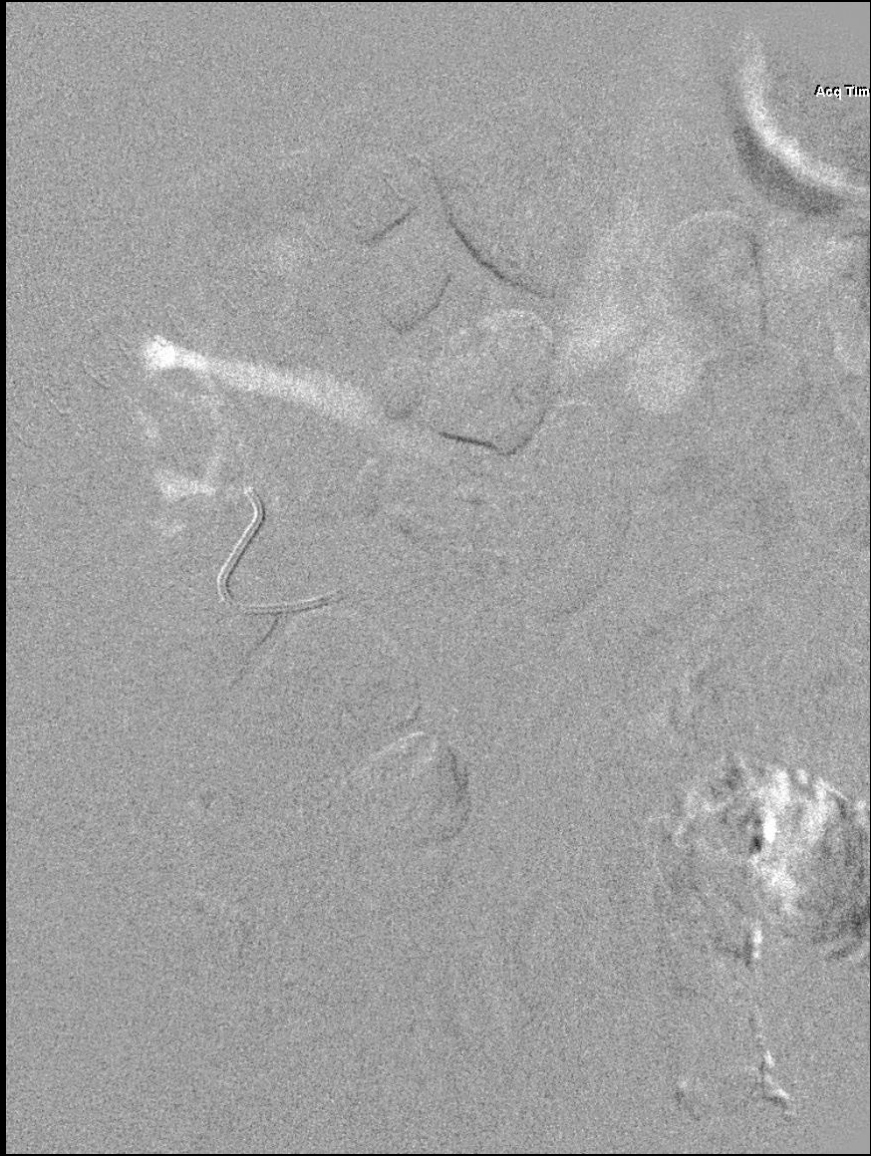


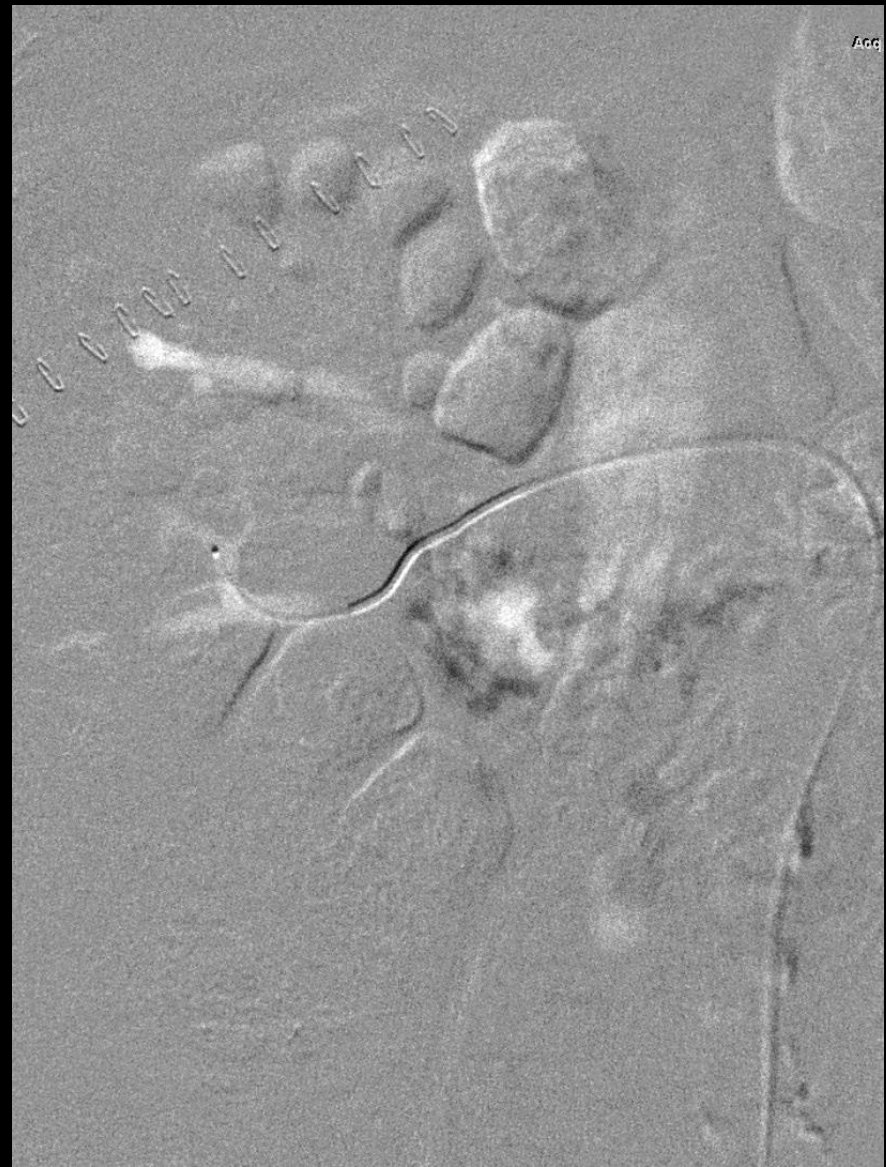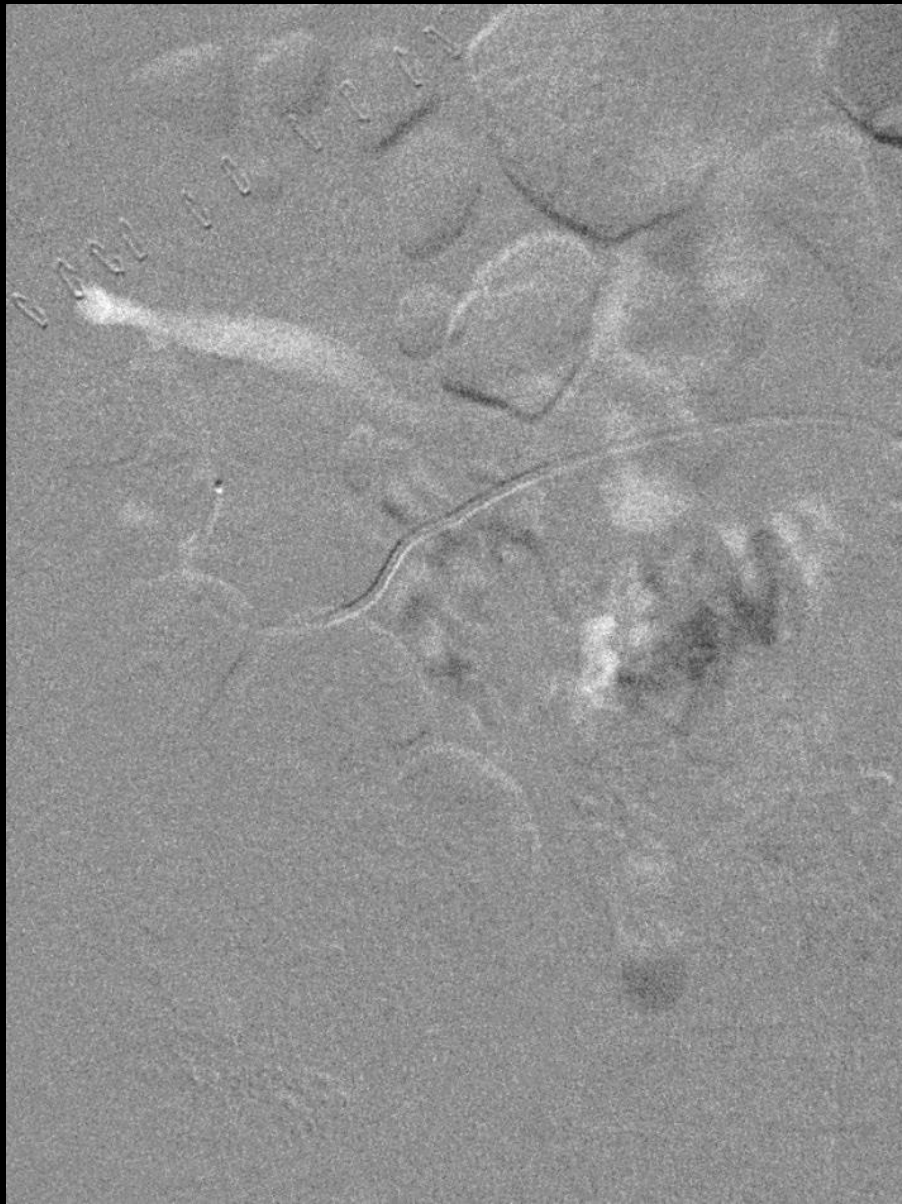


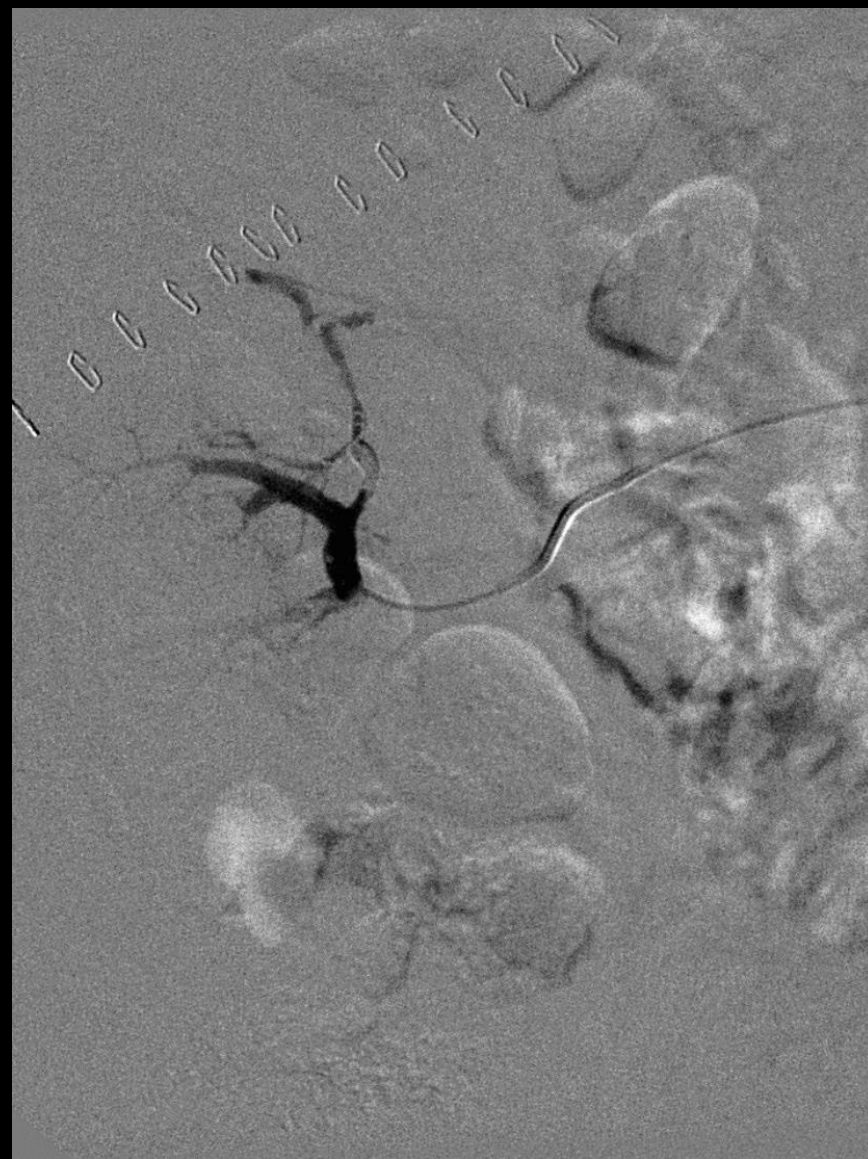


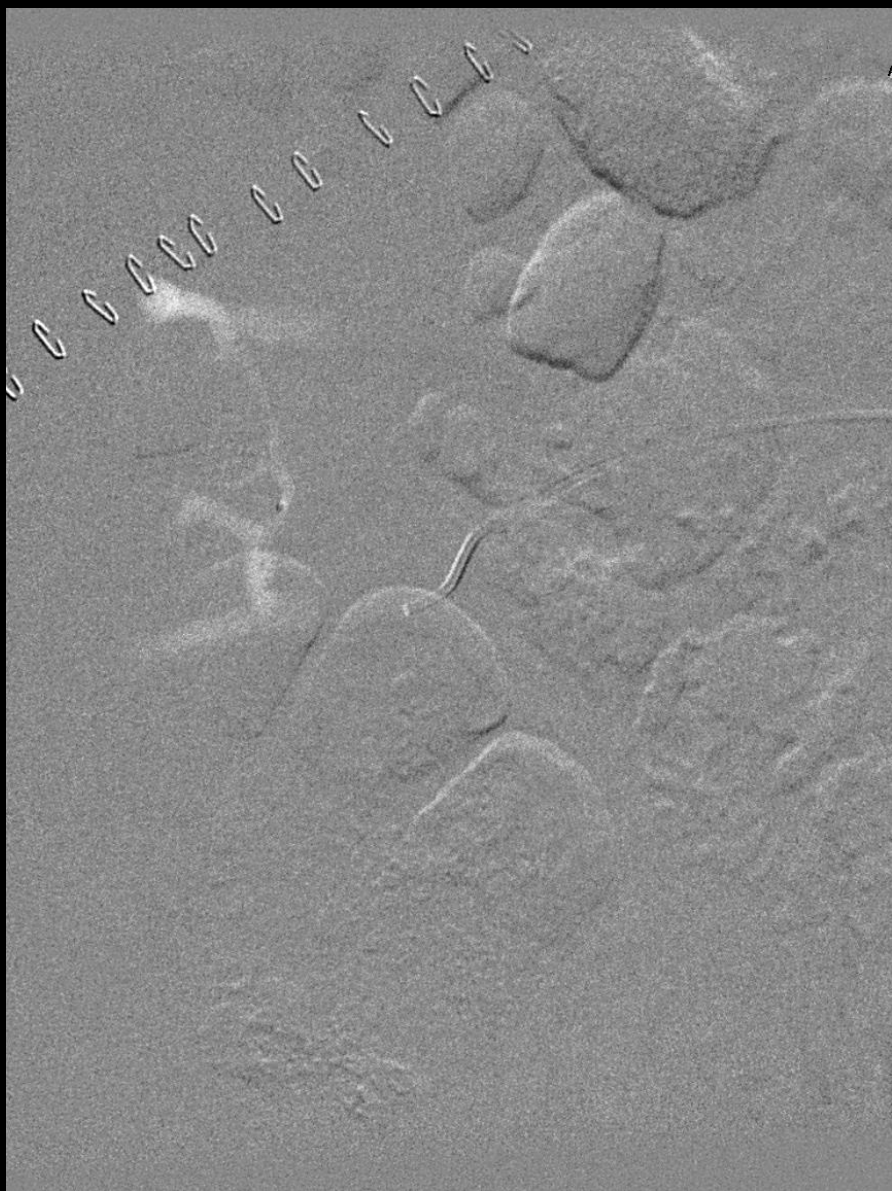

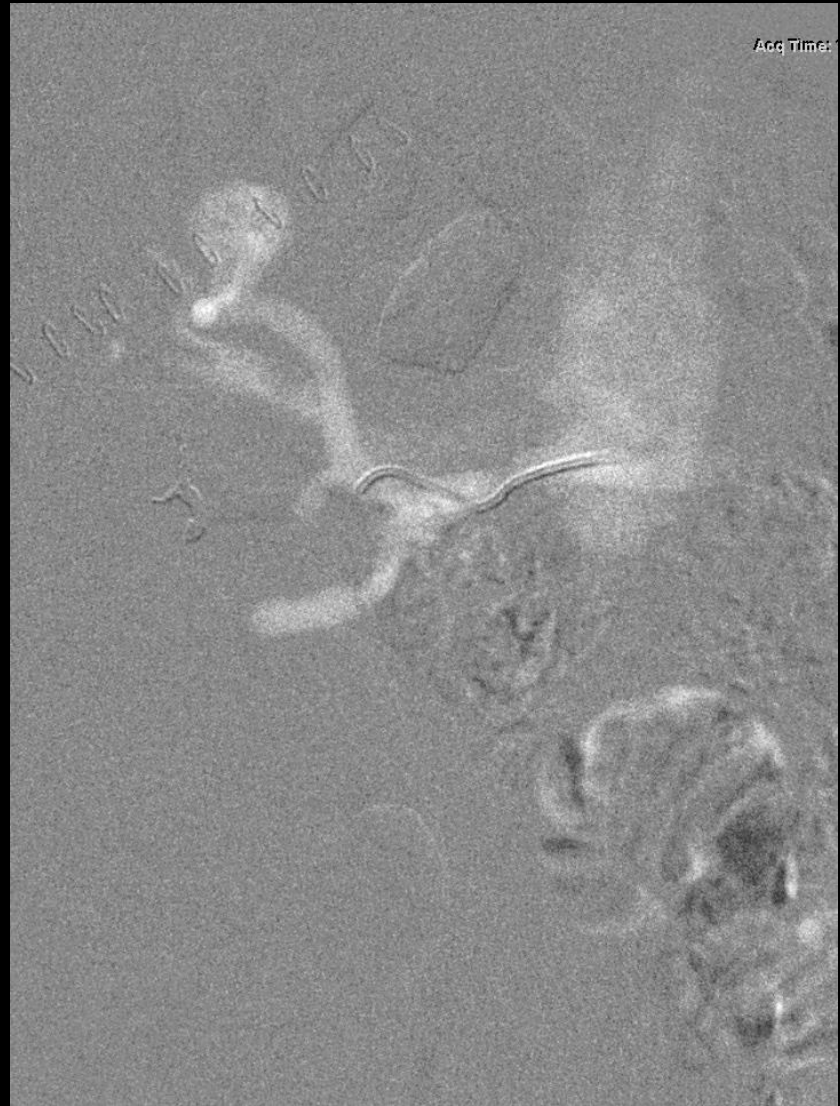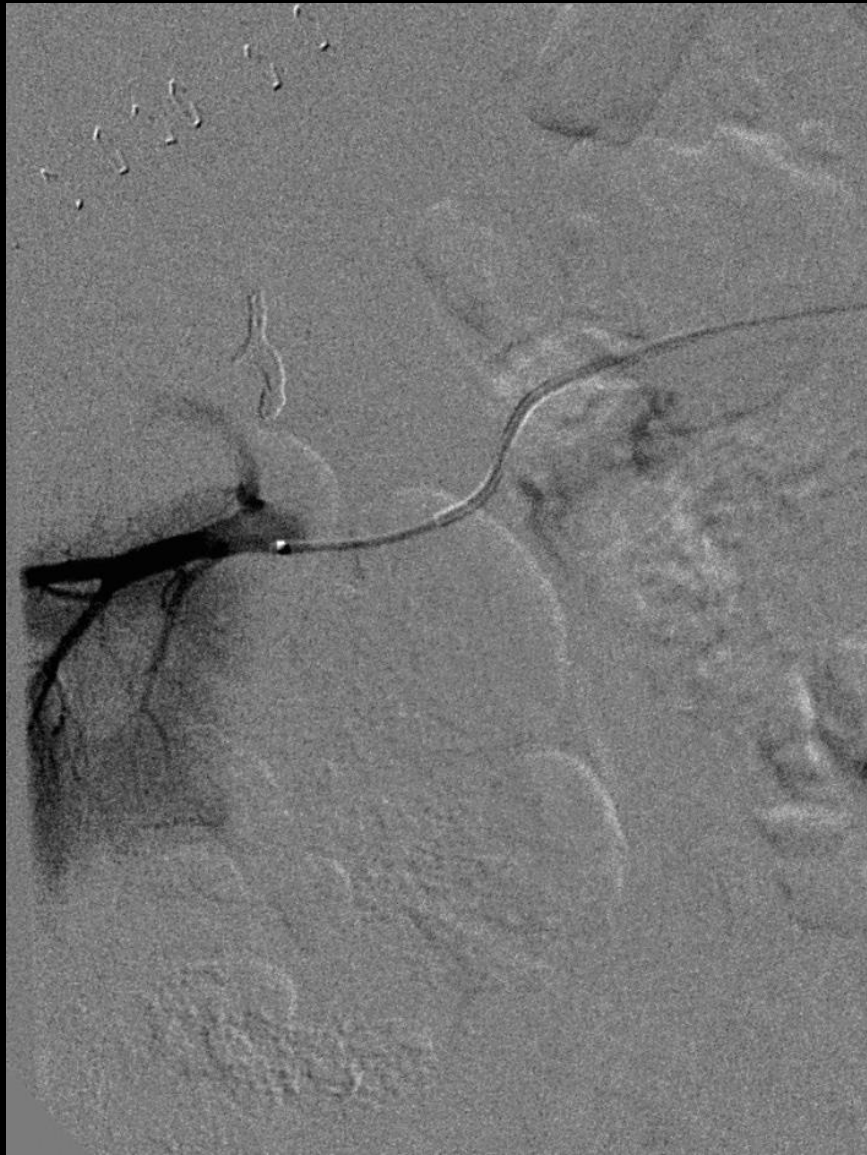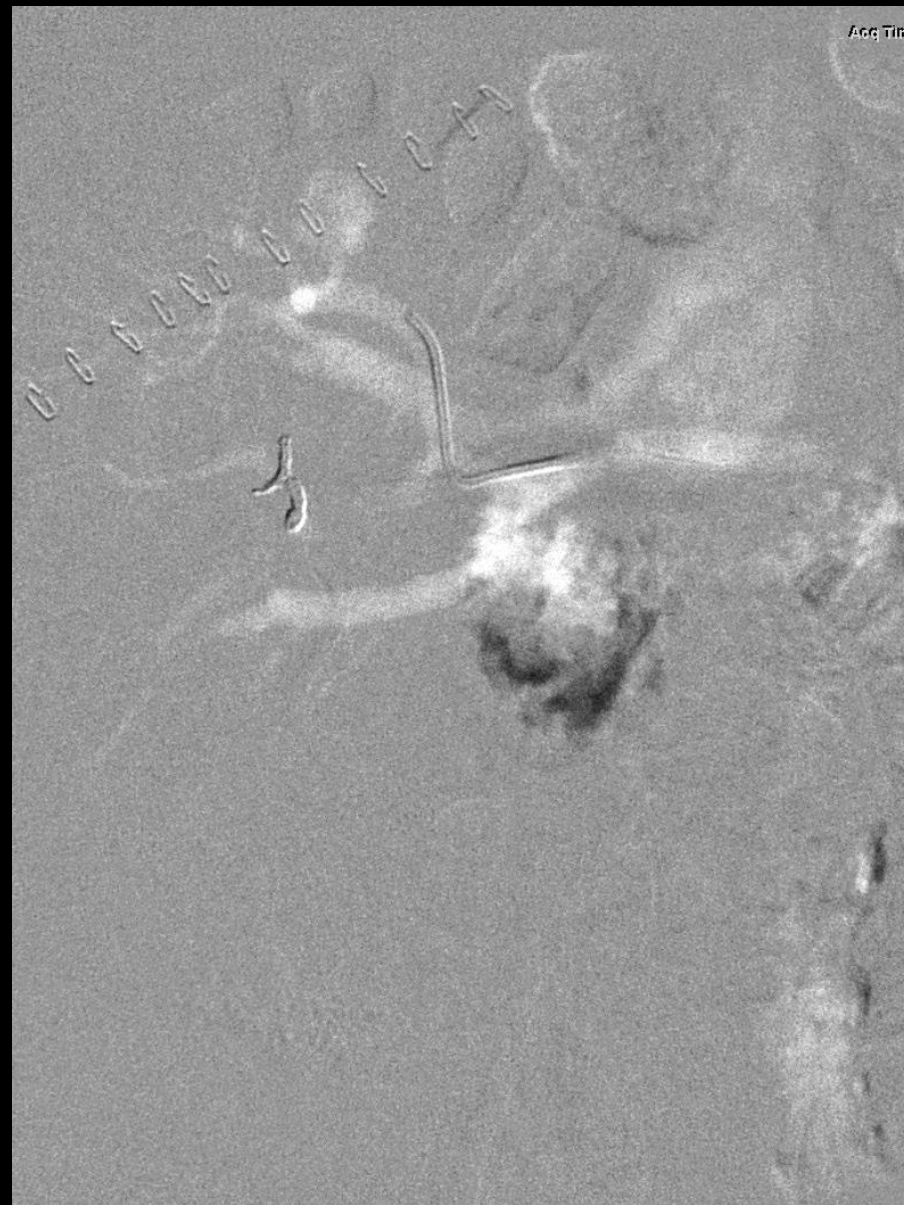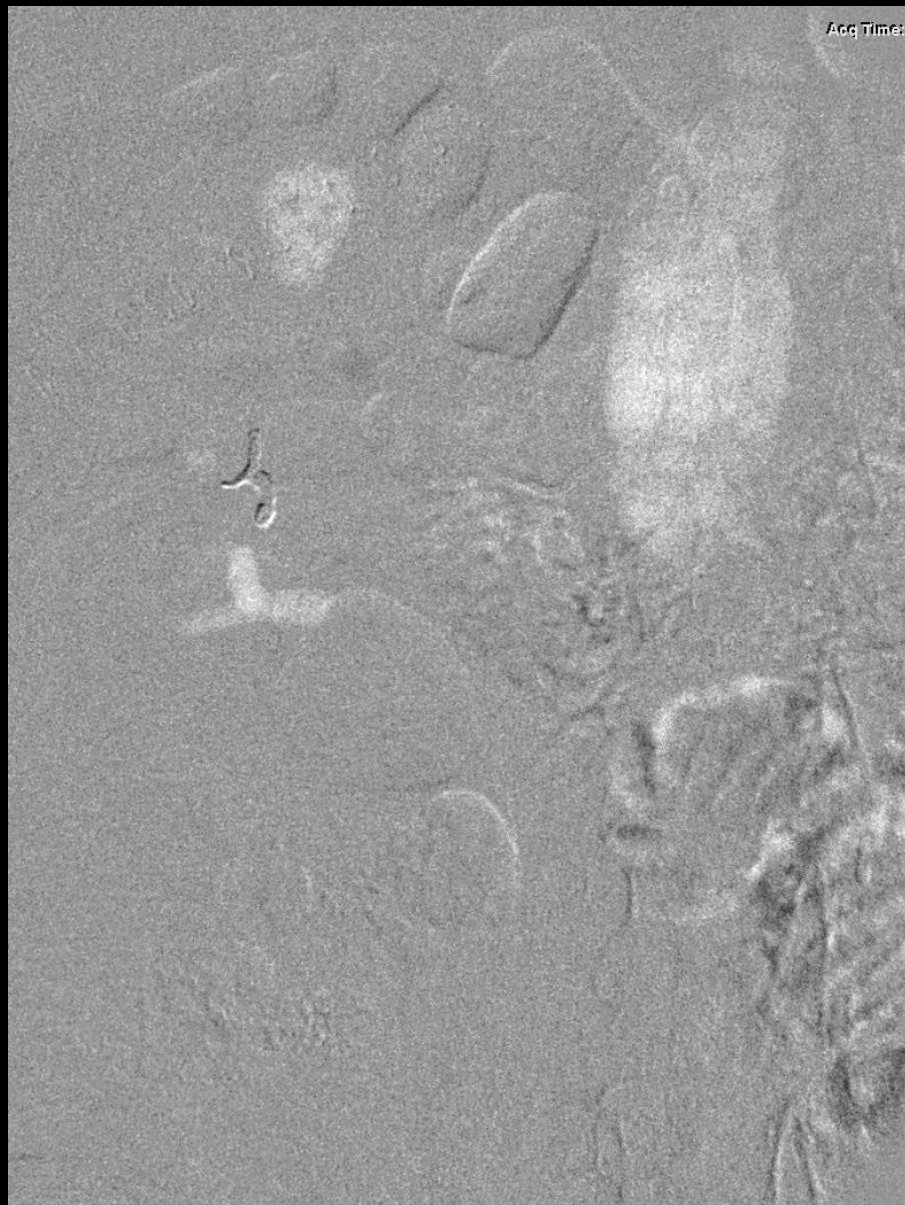
**CO₂ RENAL BLEED IN TWO
PLACES**

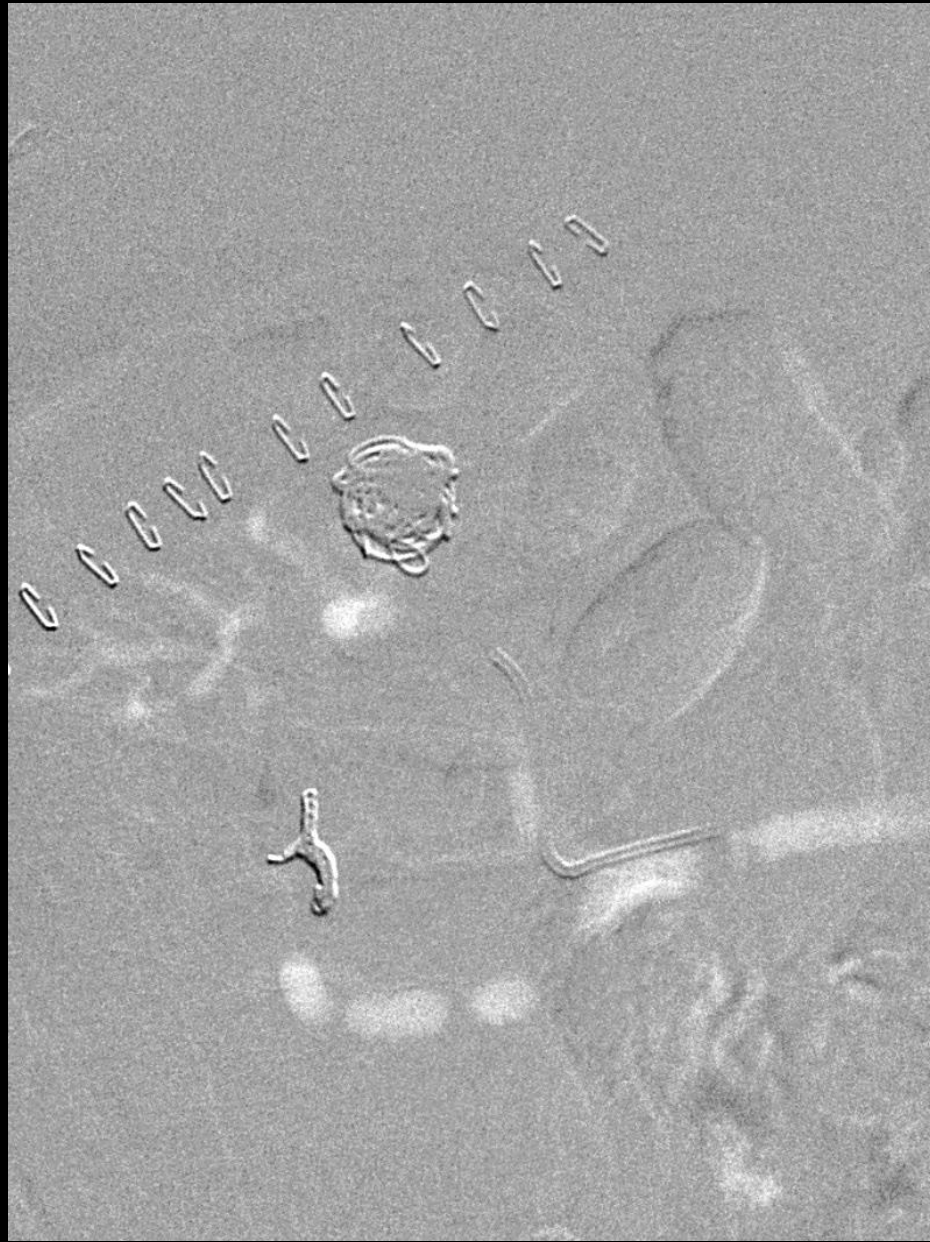
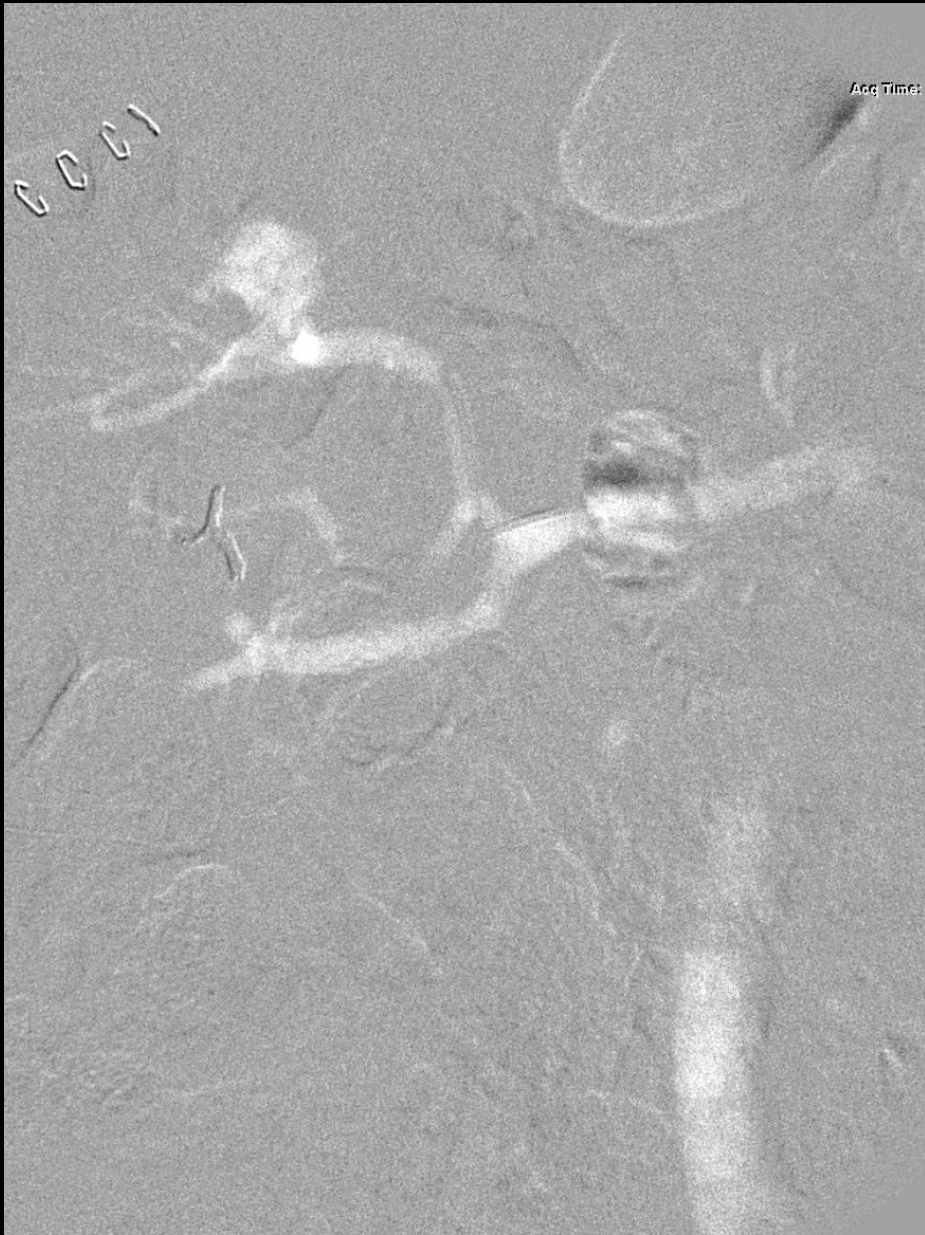




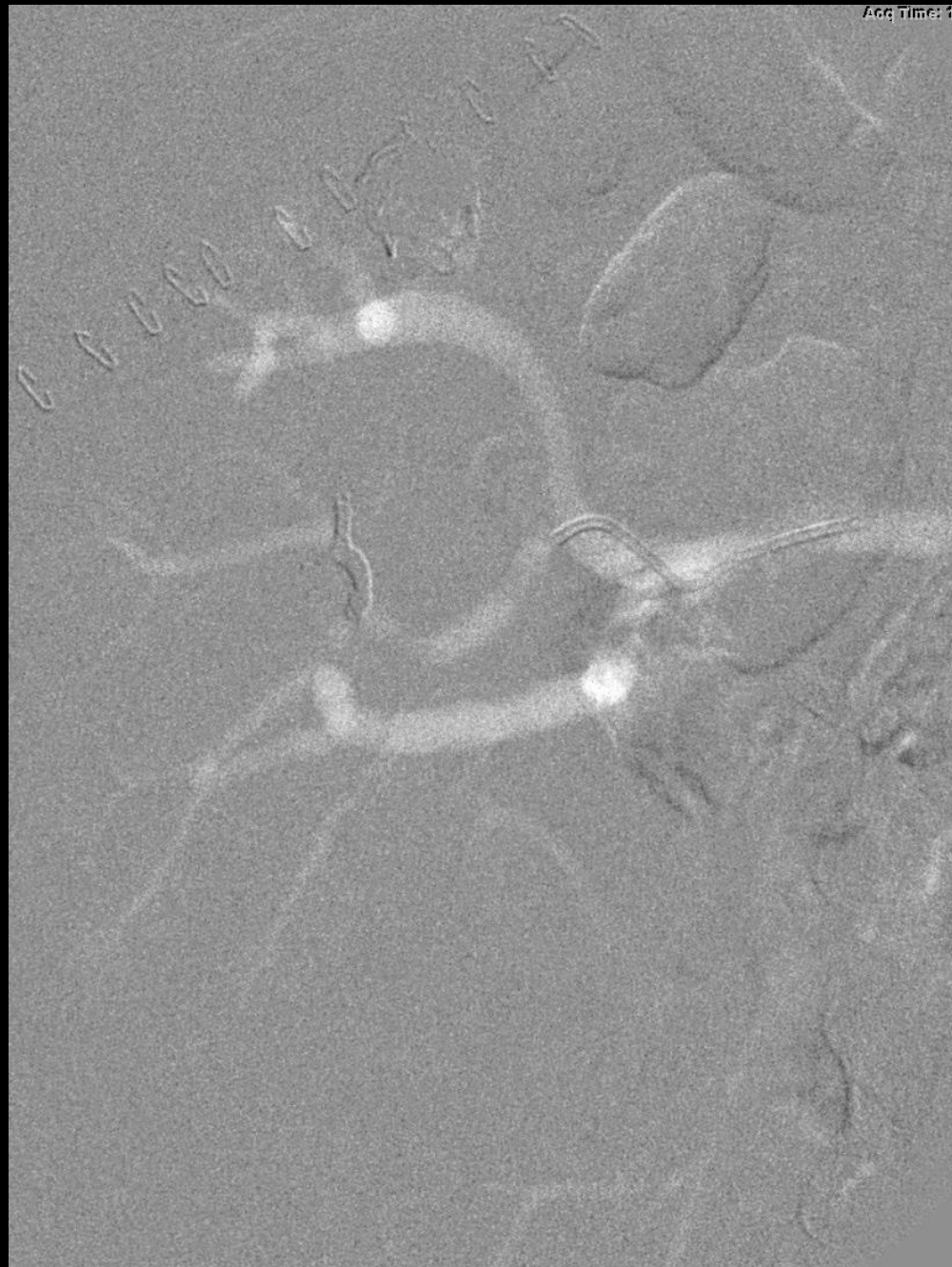




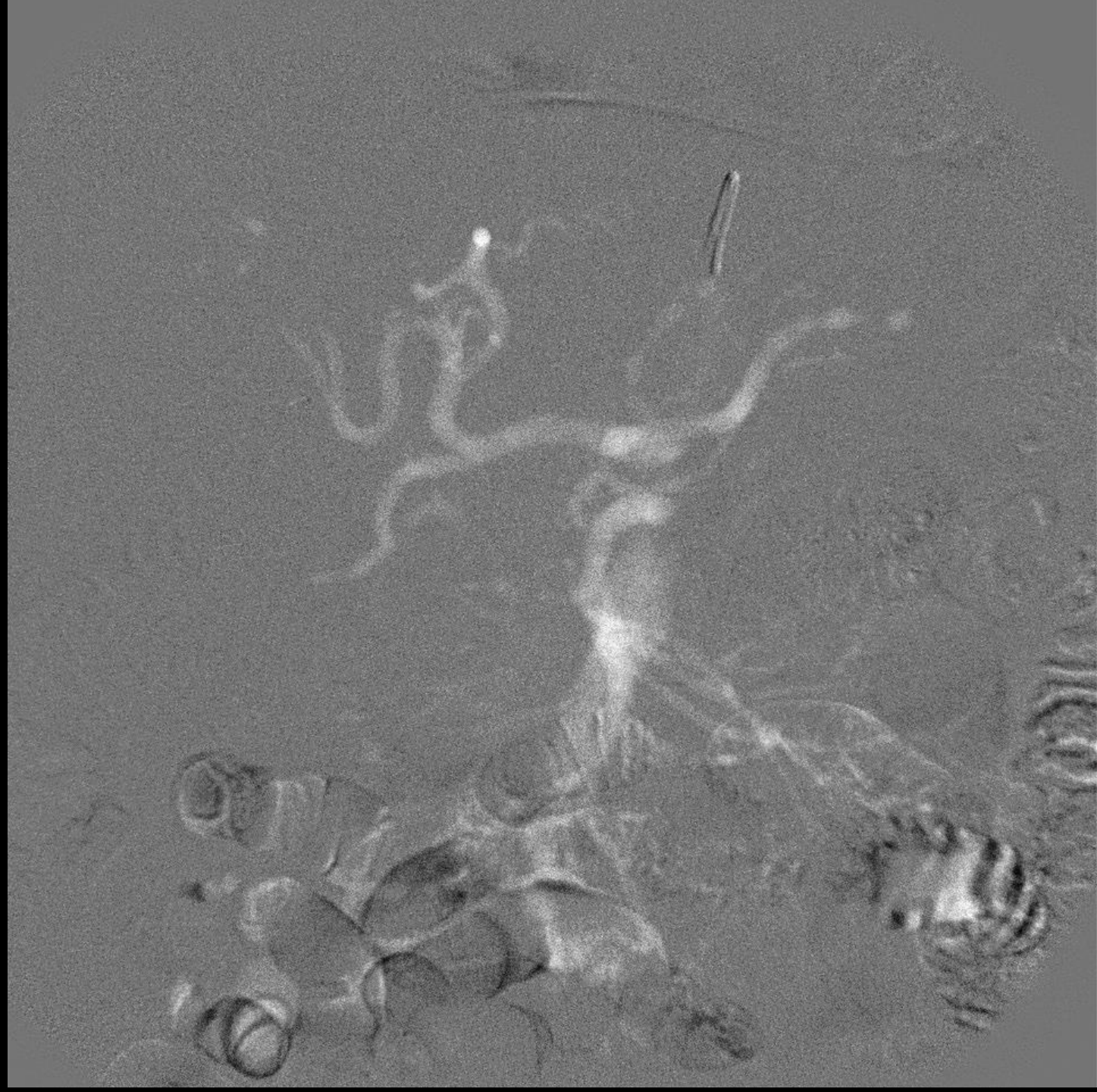


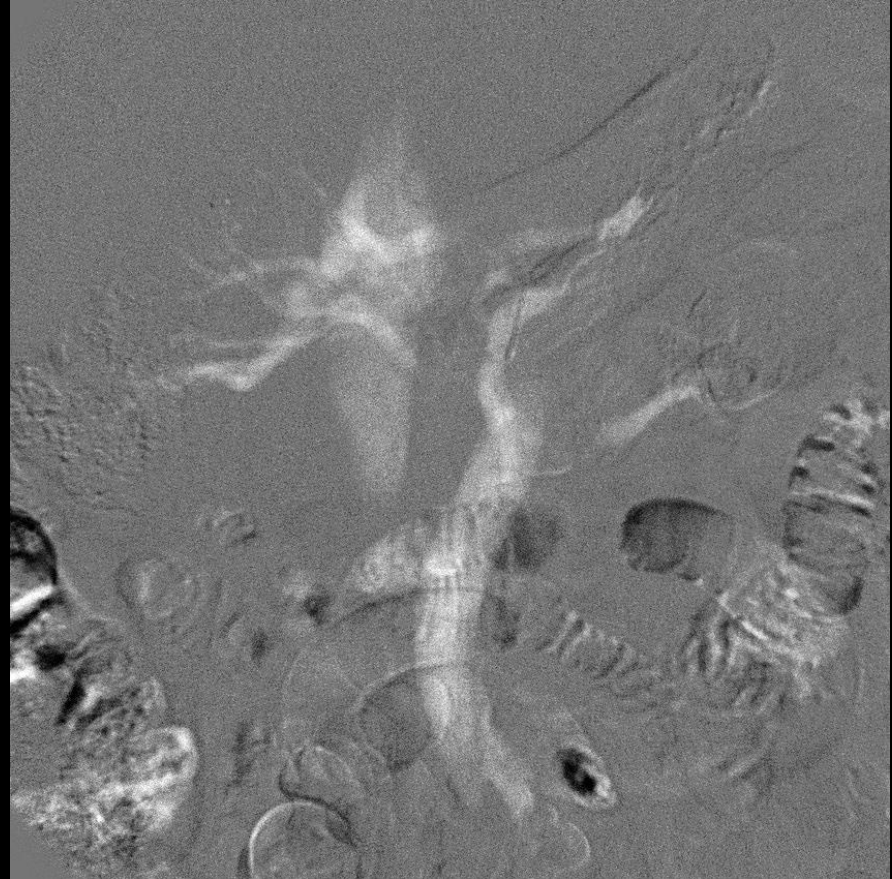
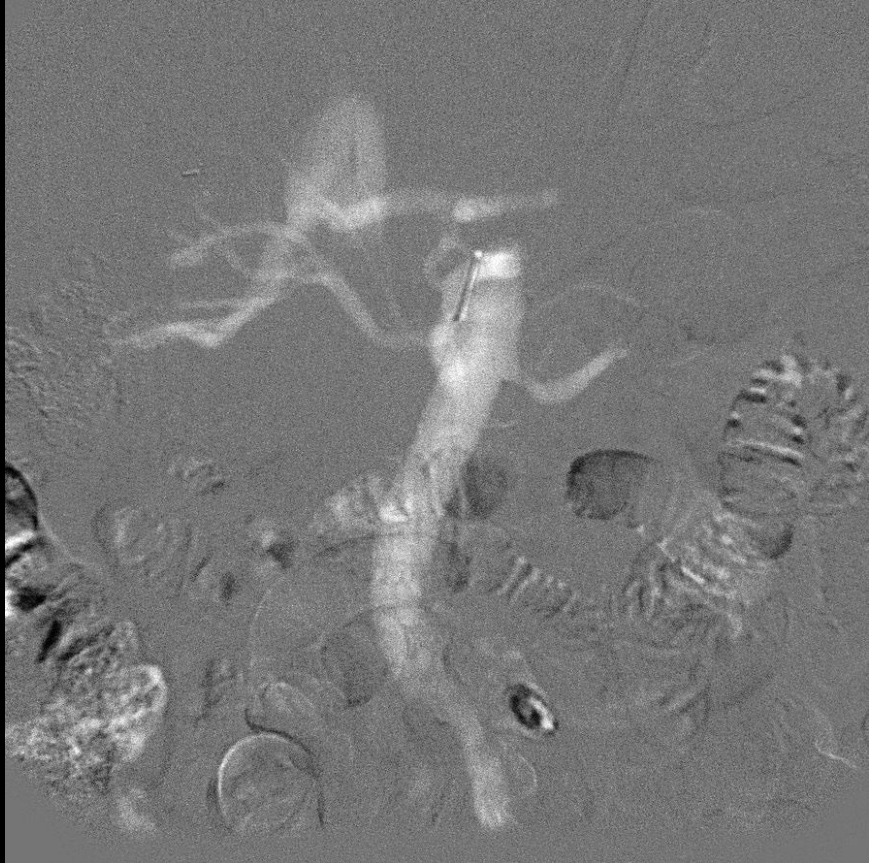
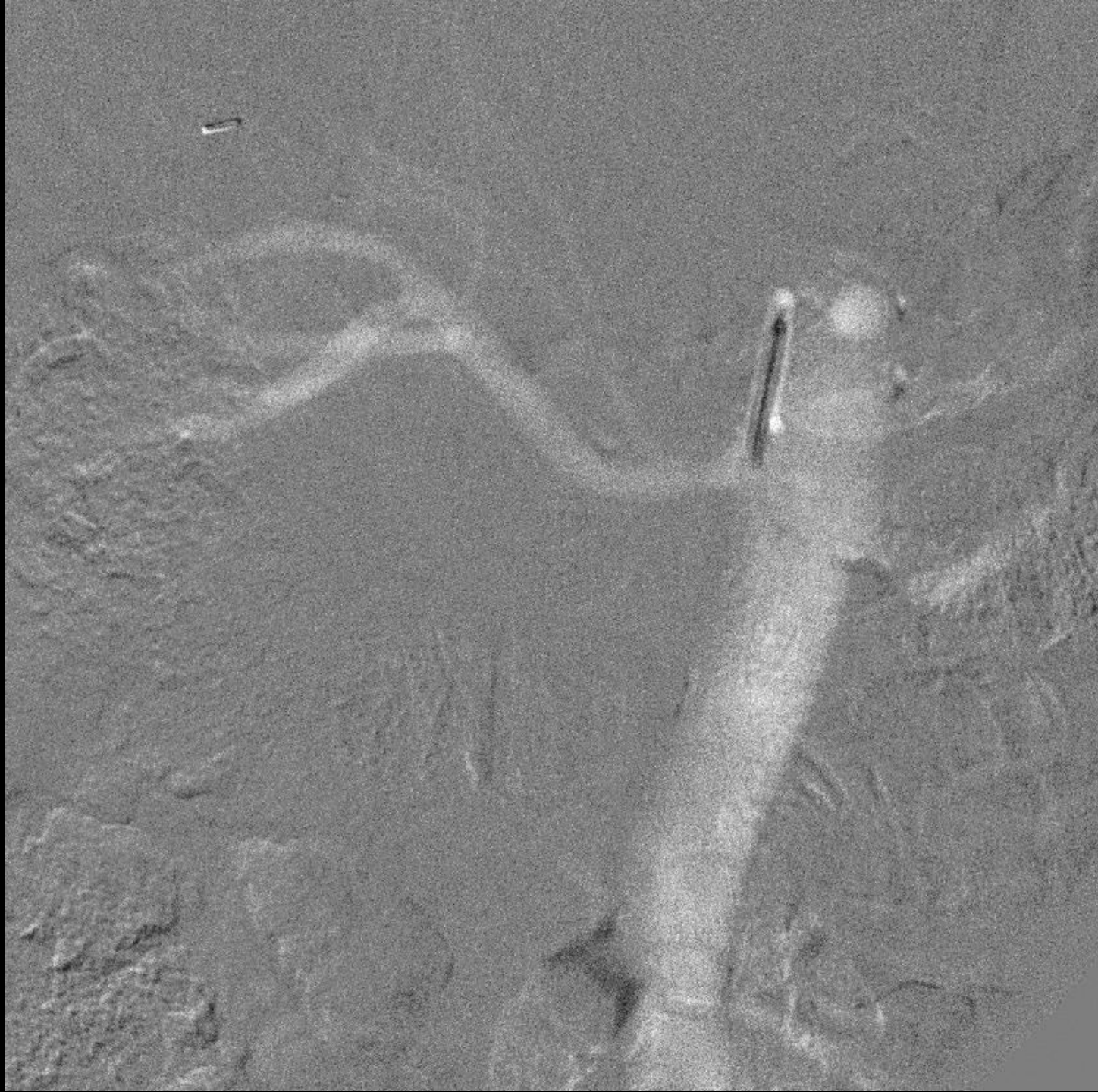Acq time: 1

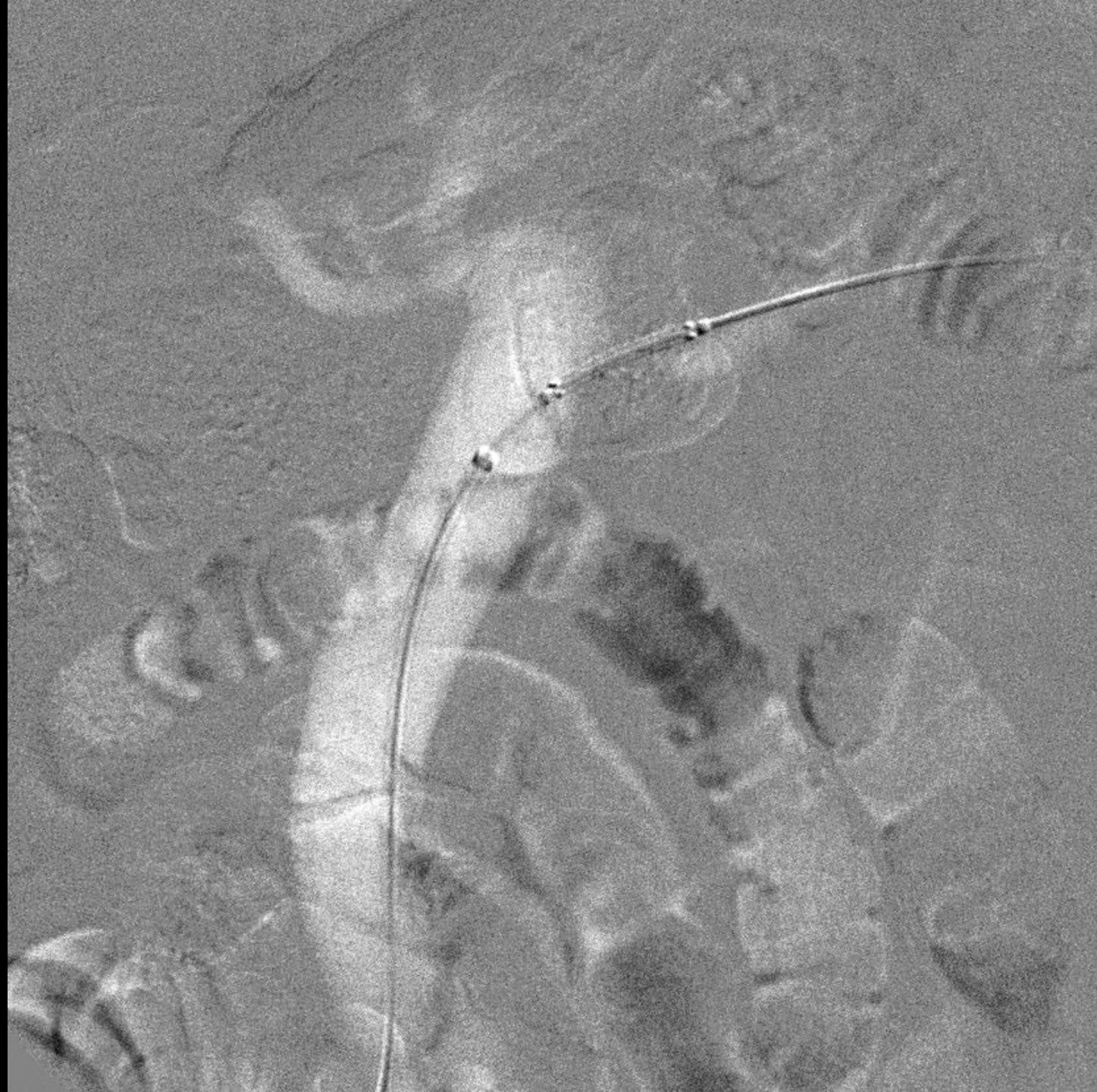

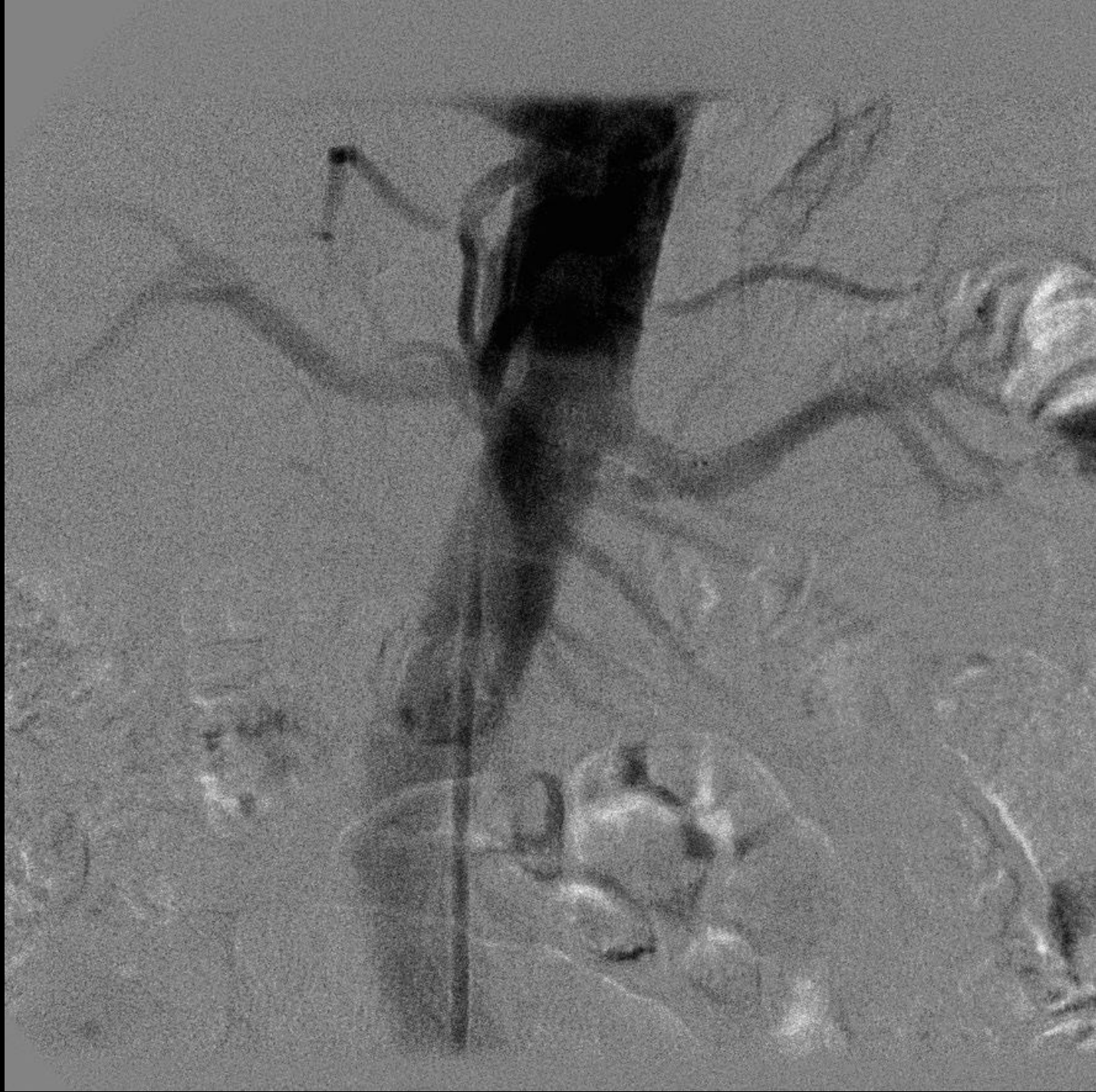
RENAL AVF AND STENOSIS



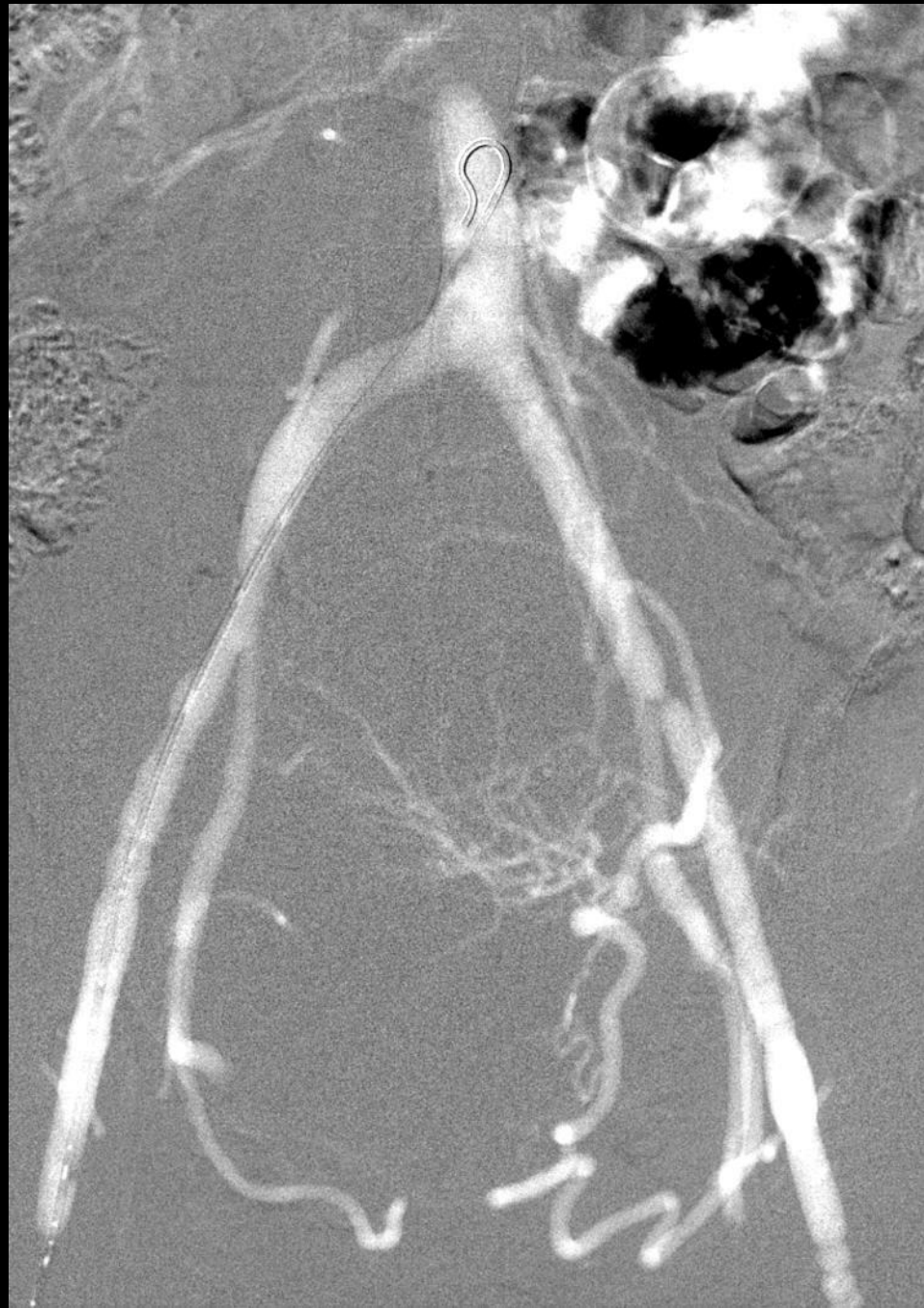

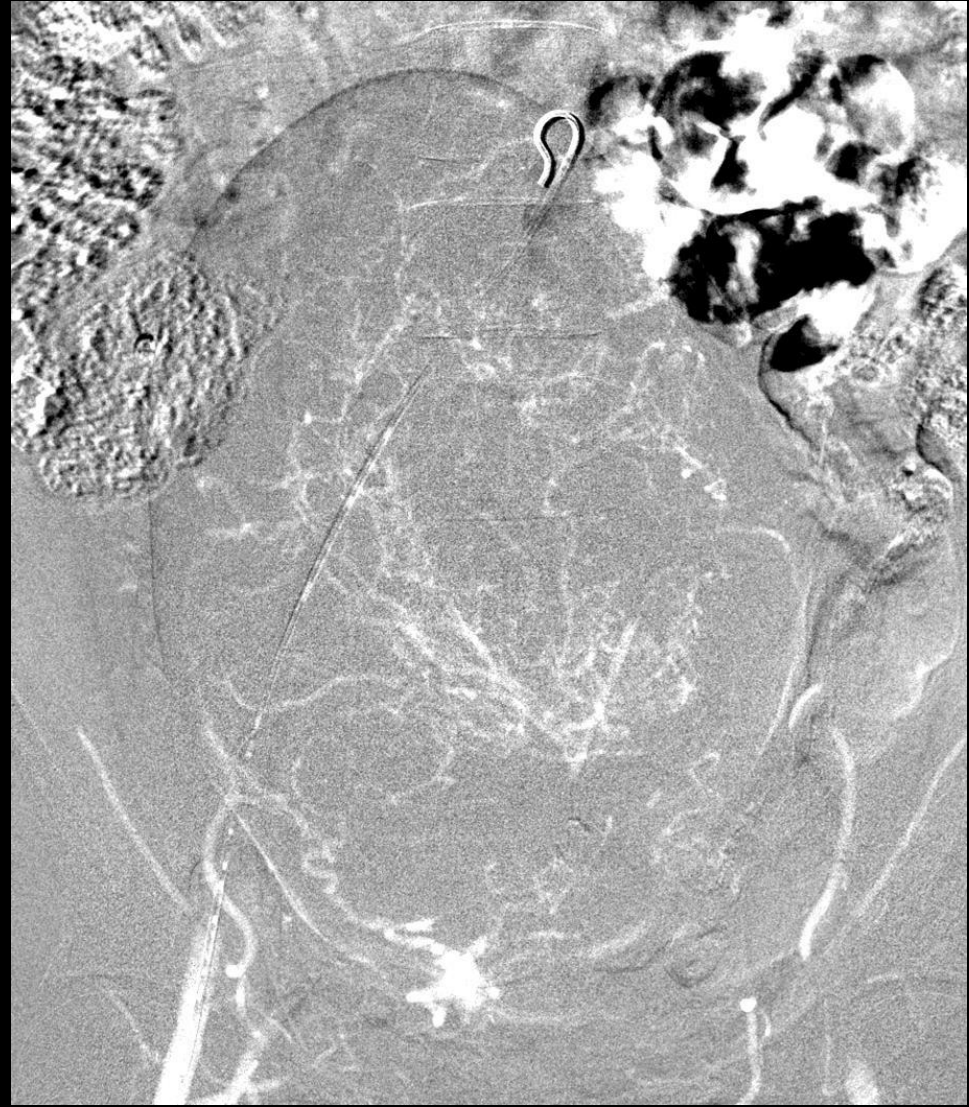

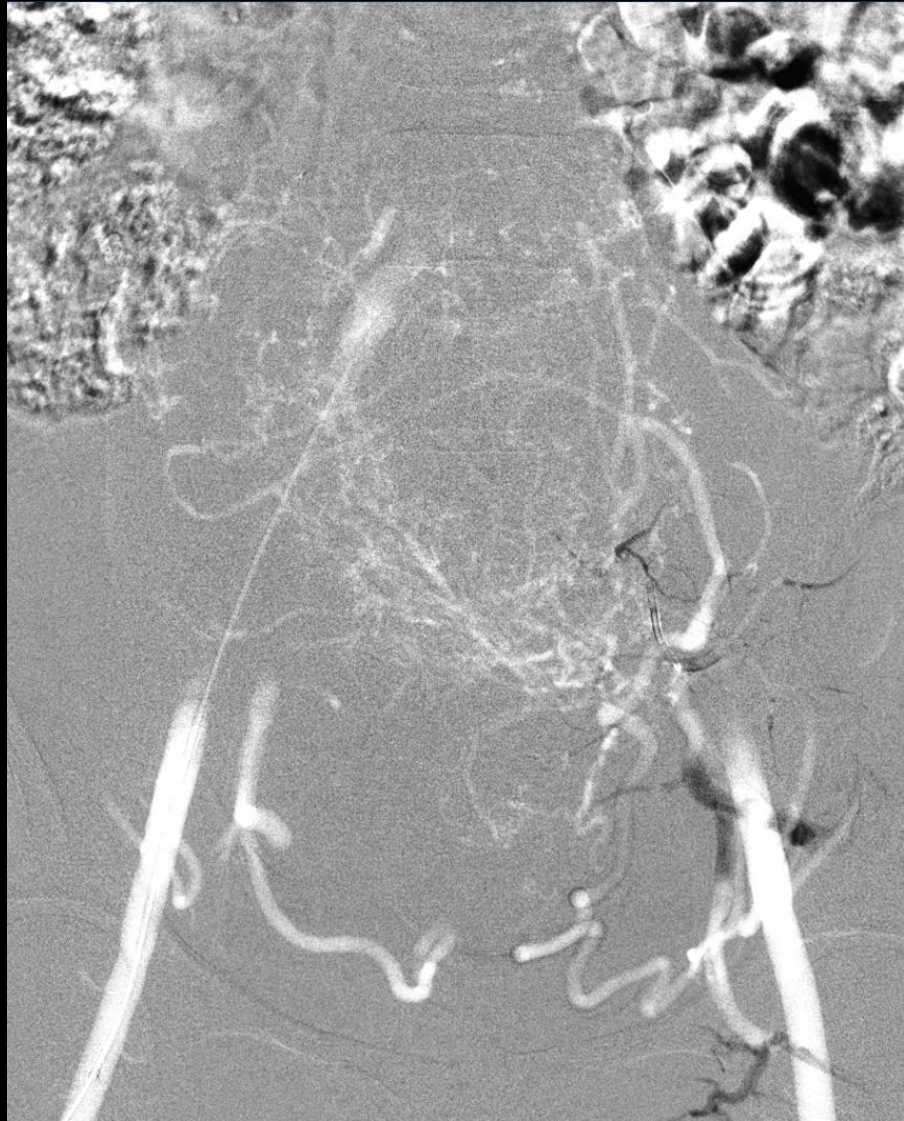


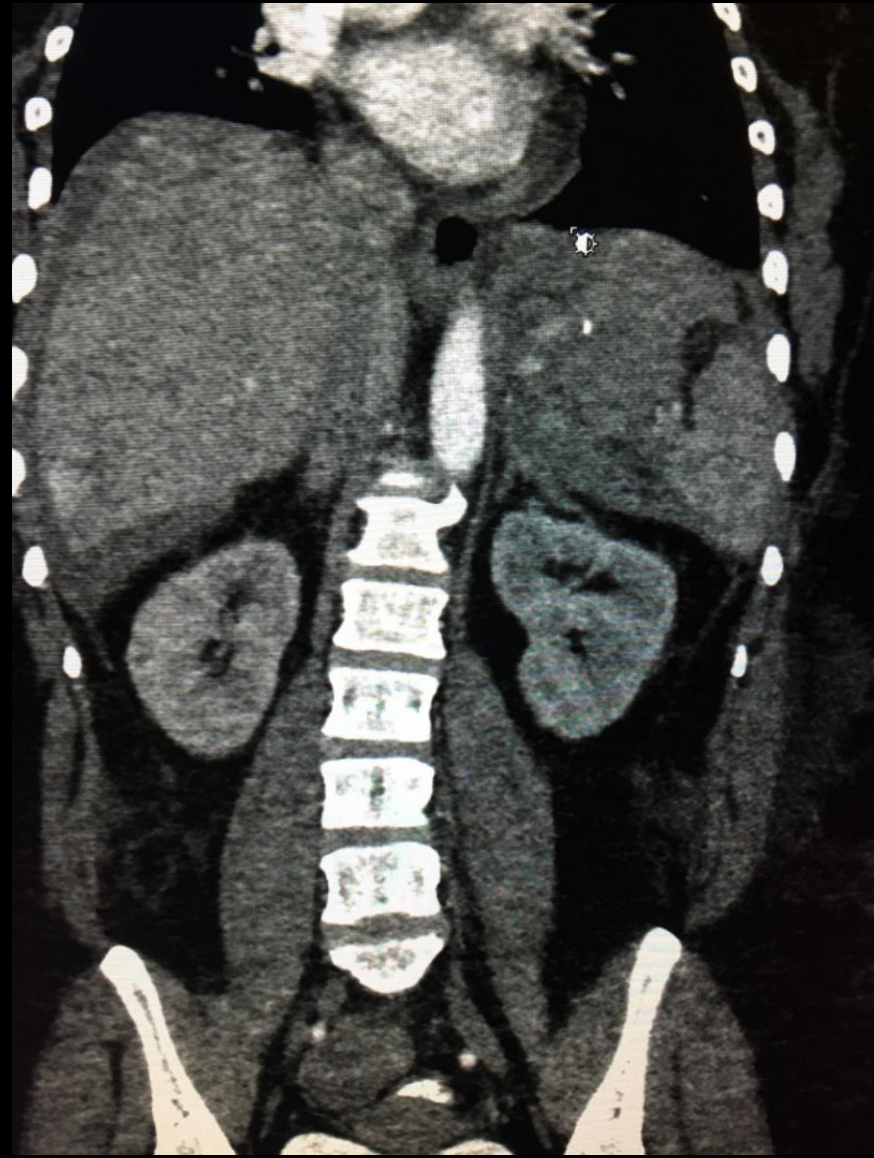
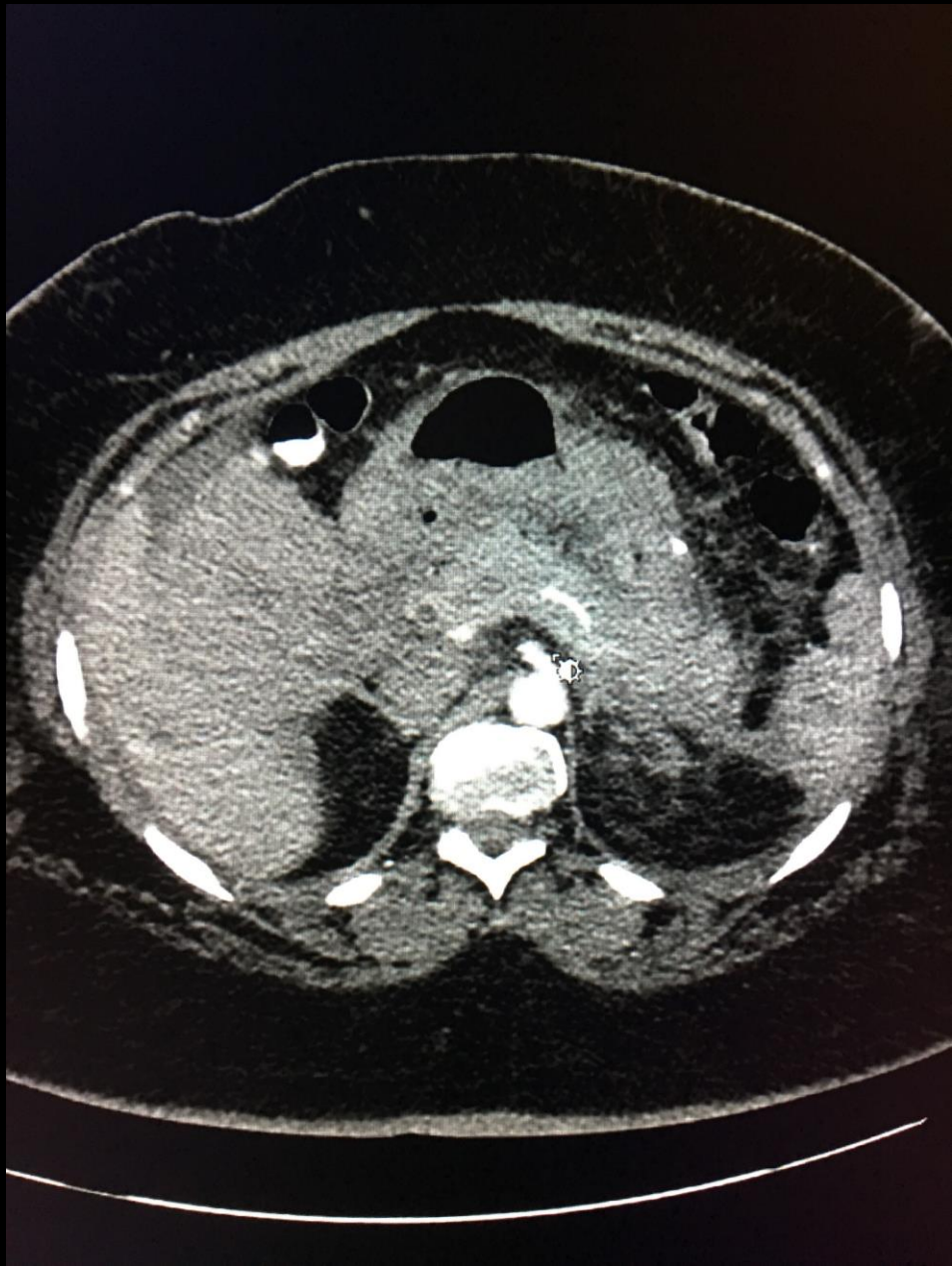


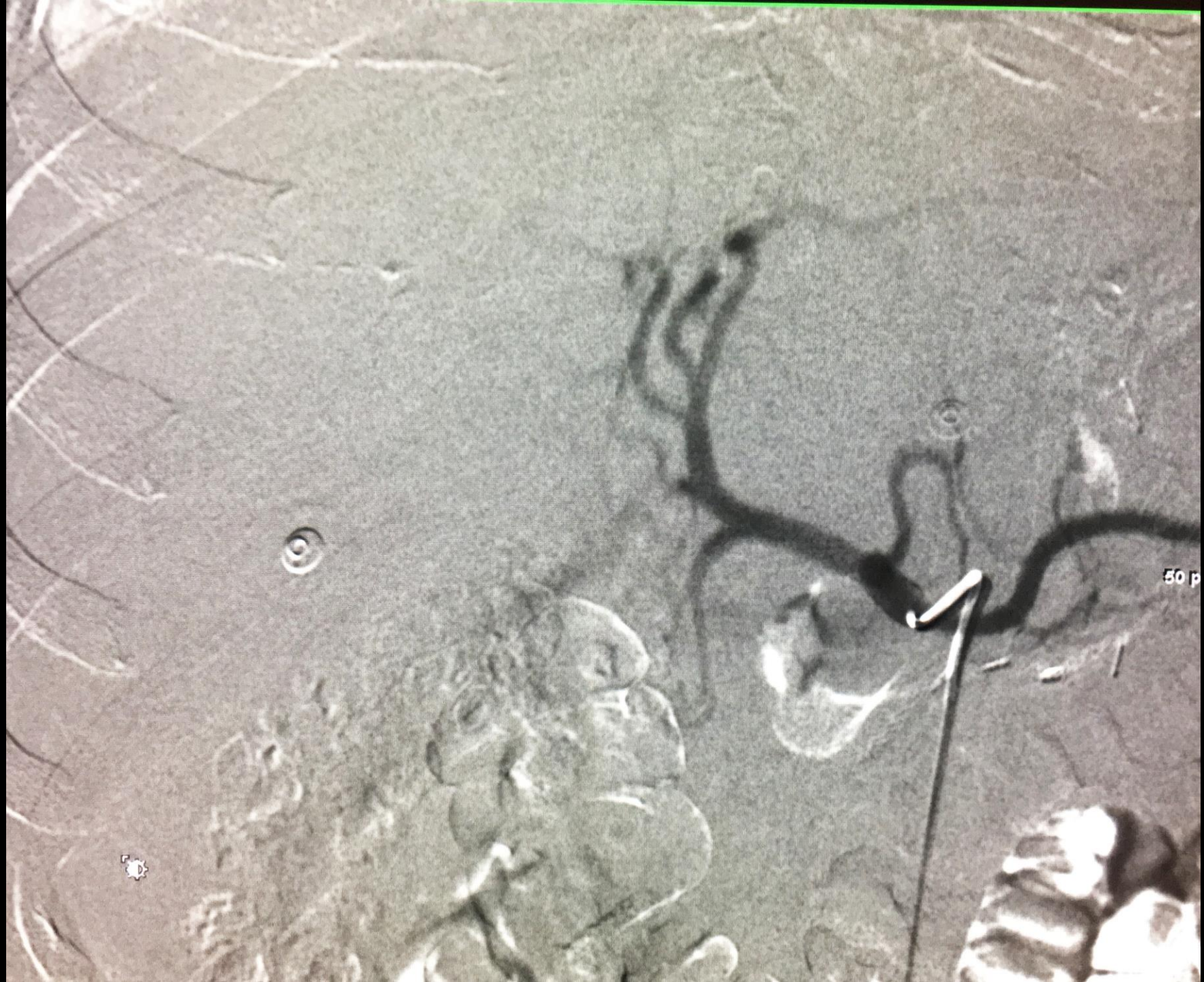
UTERINE FIBROID EMBOLIZATON



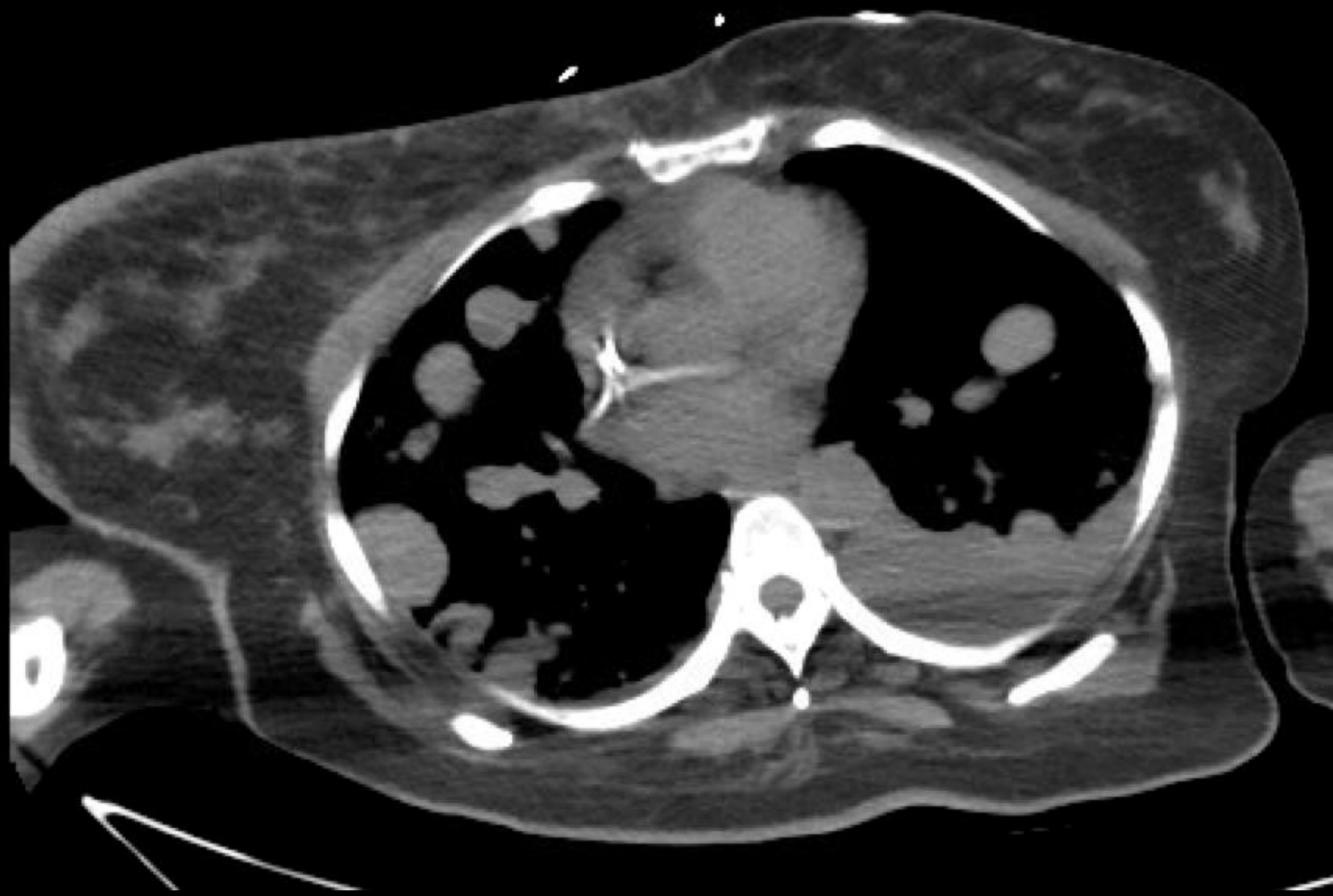

CO2 liver bleed

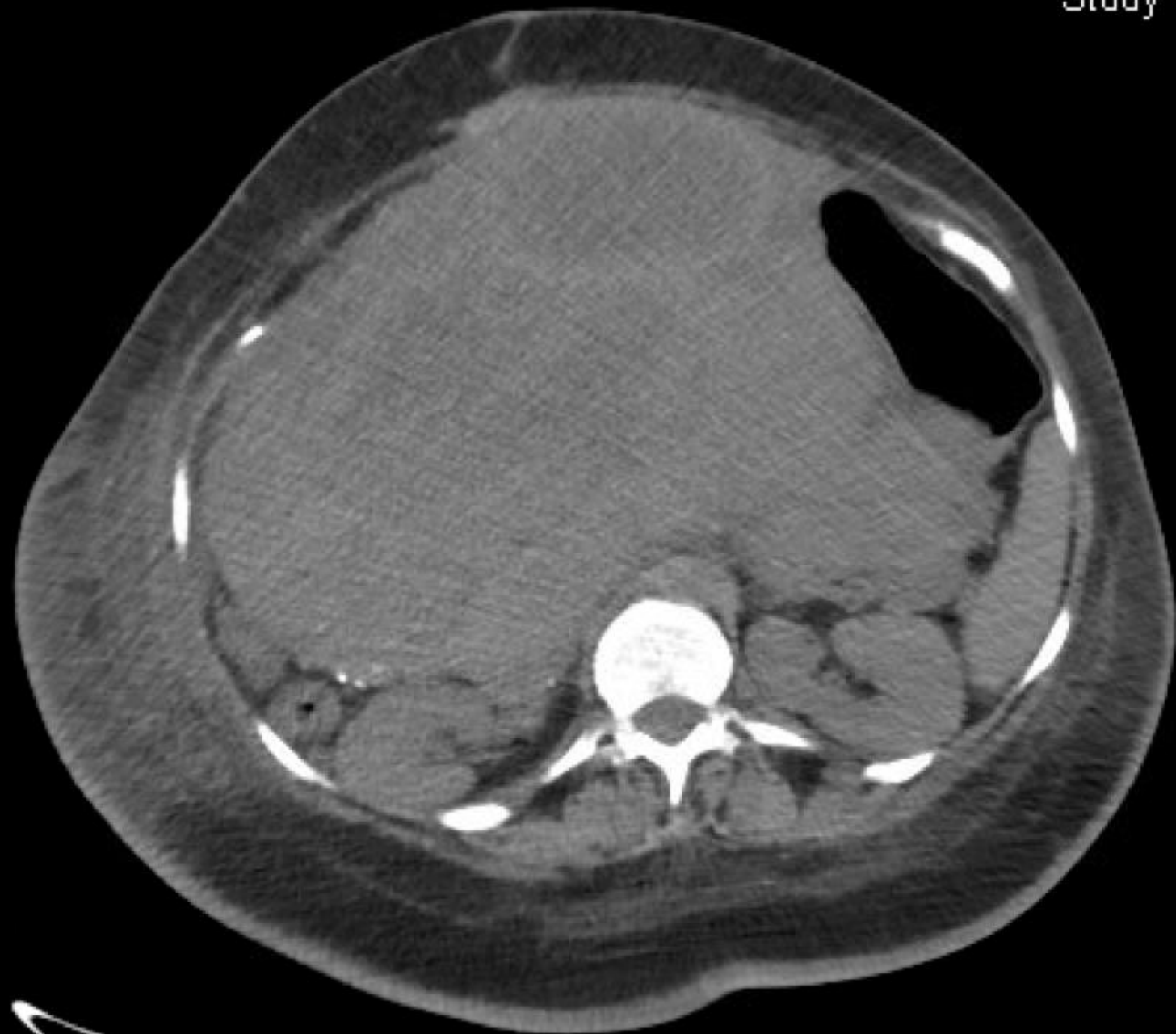



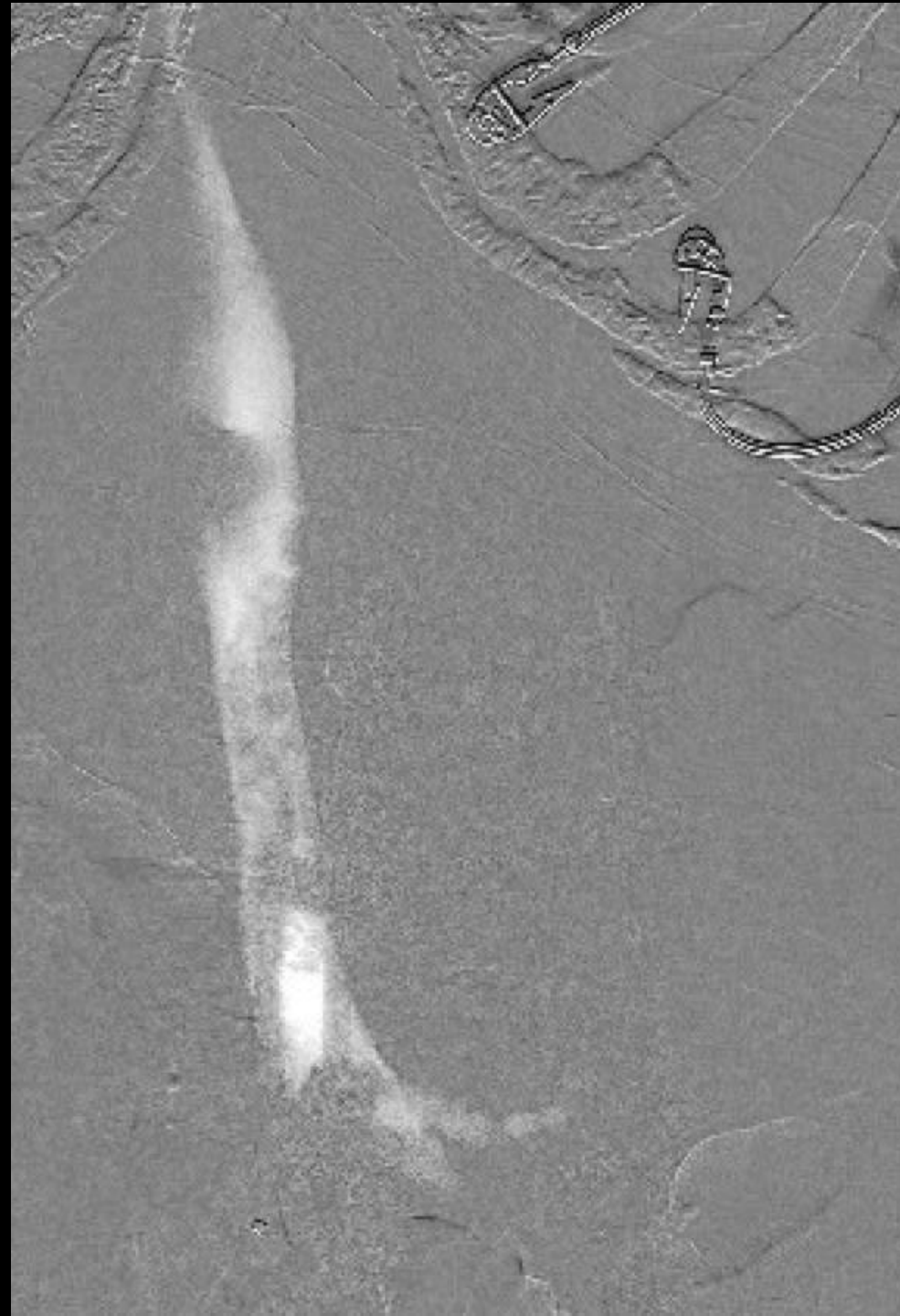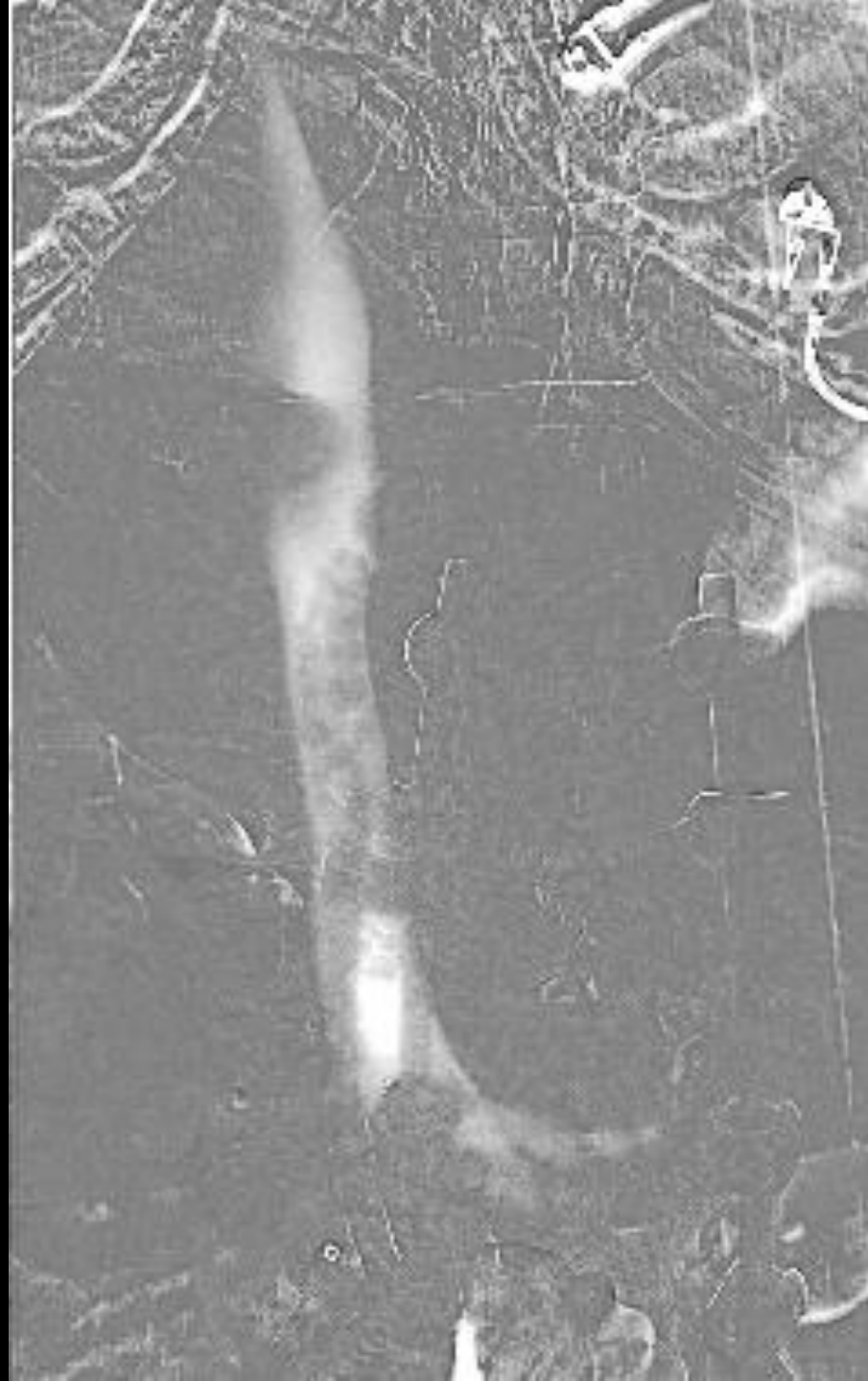**CO₂ IVC Filter, lovenox cerebral
hemorrhage, metastatic
leiomyosarcoma**

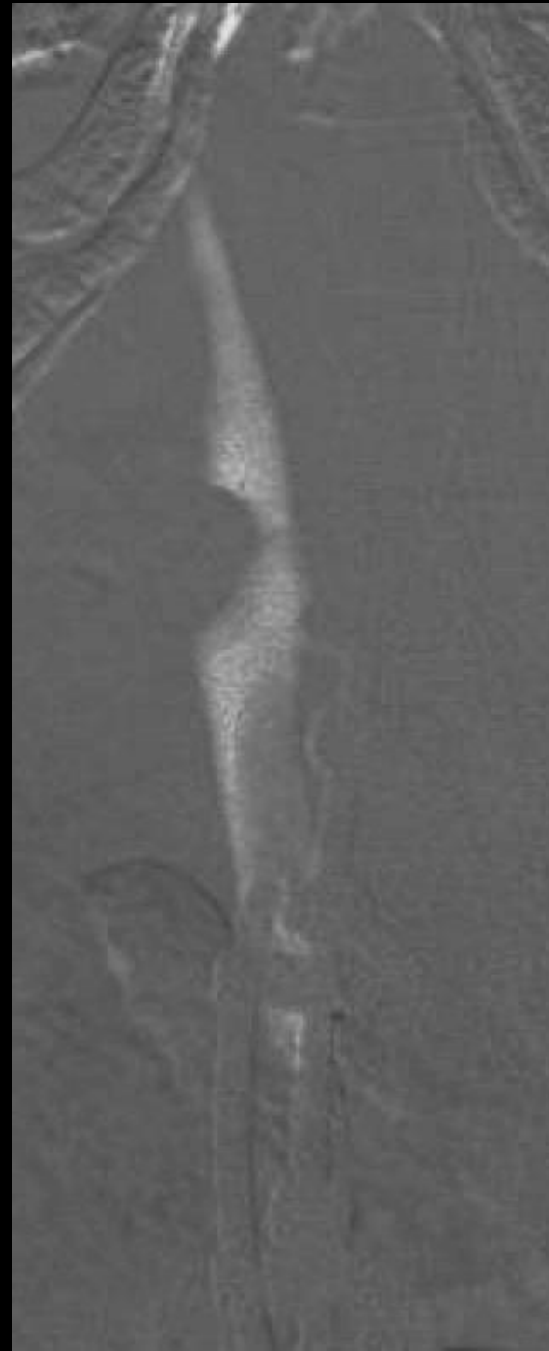

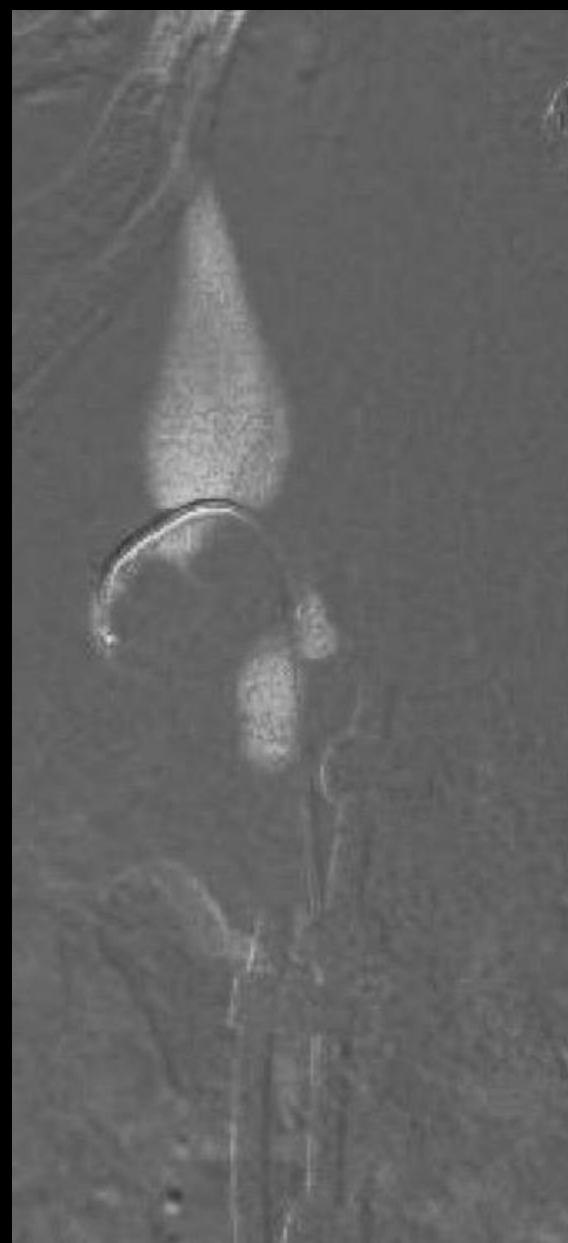
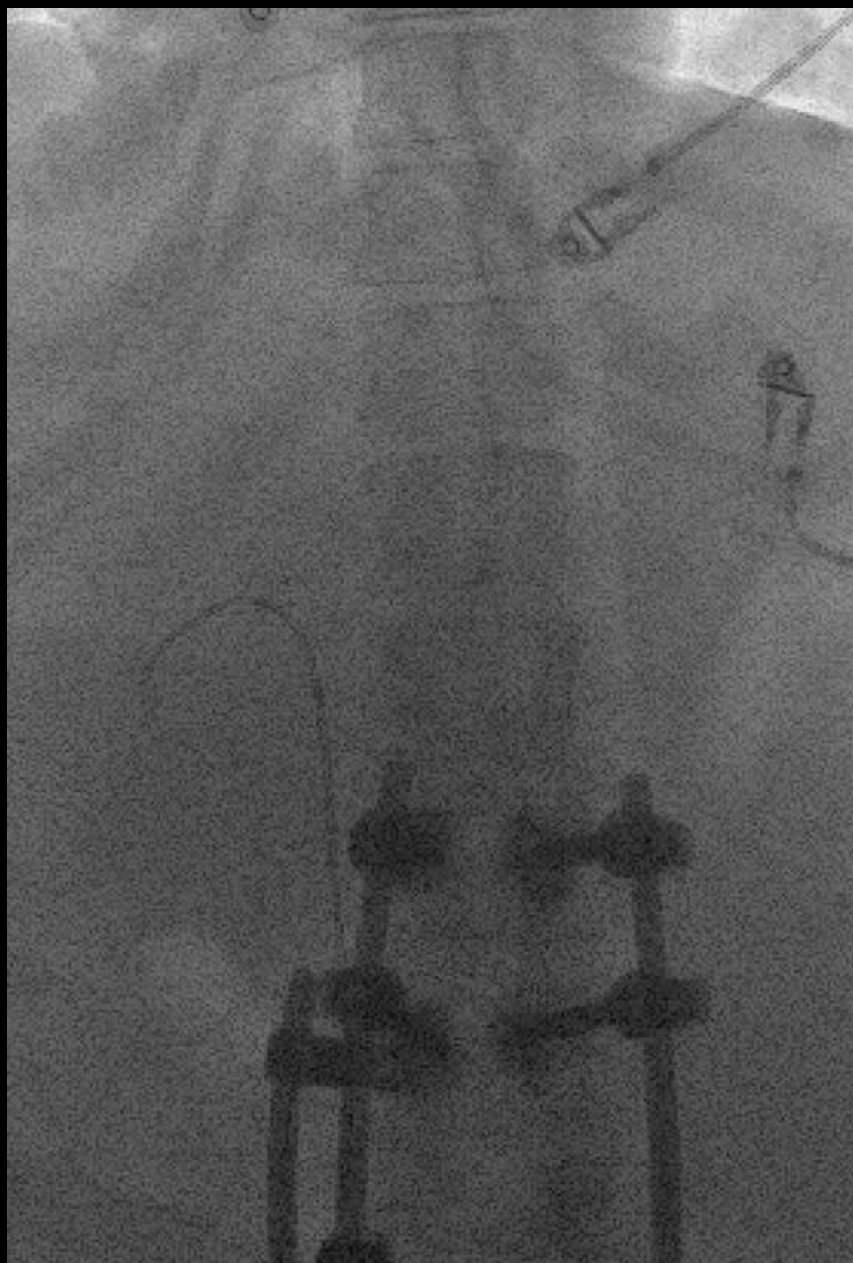
Study Time
MR

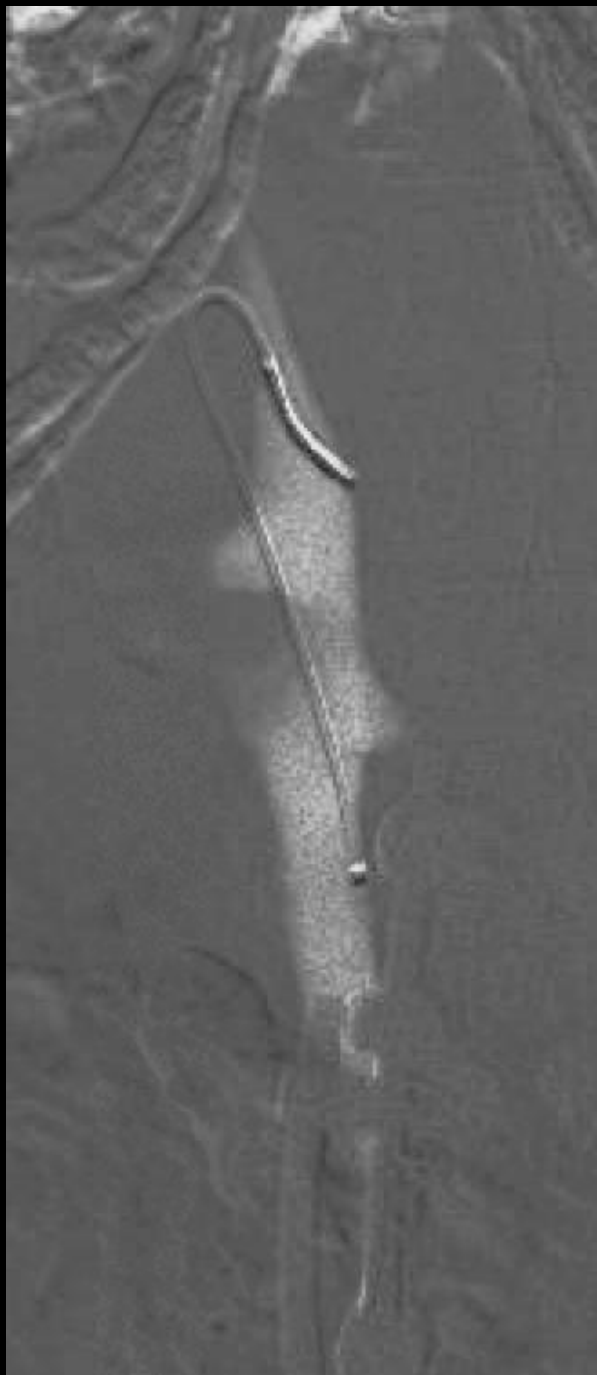


7

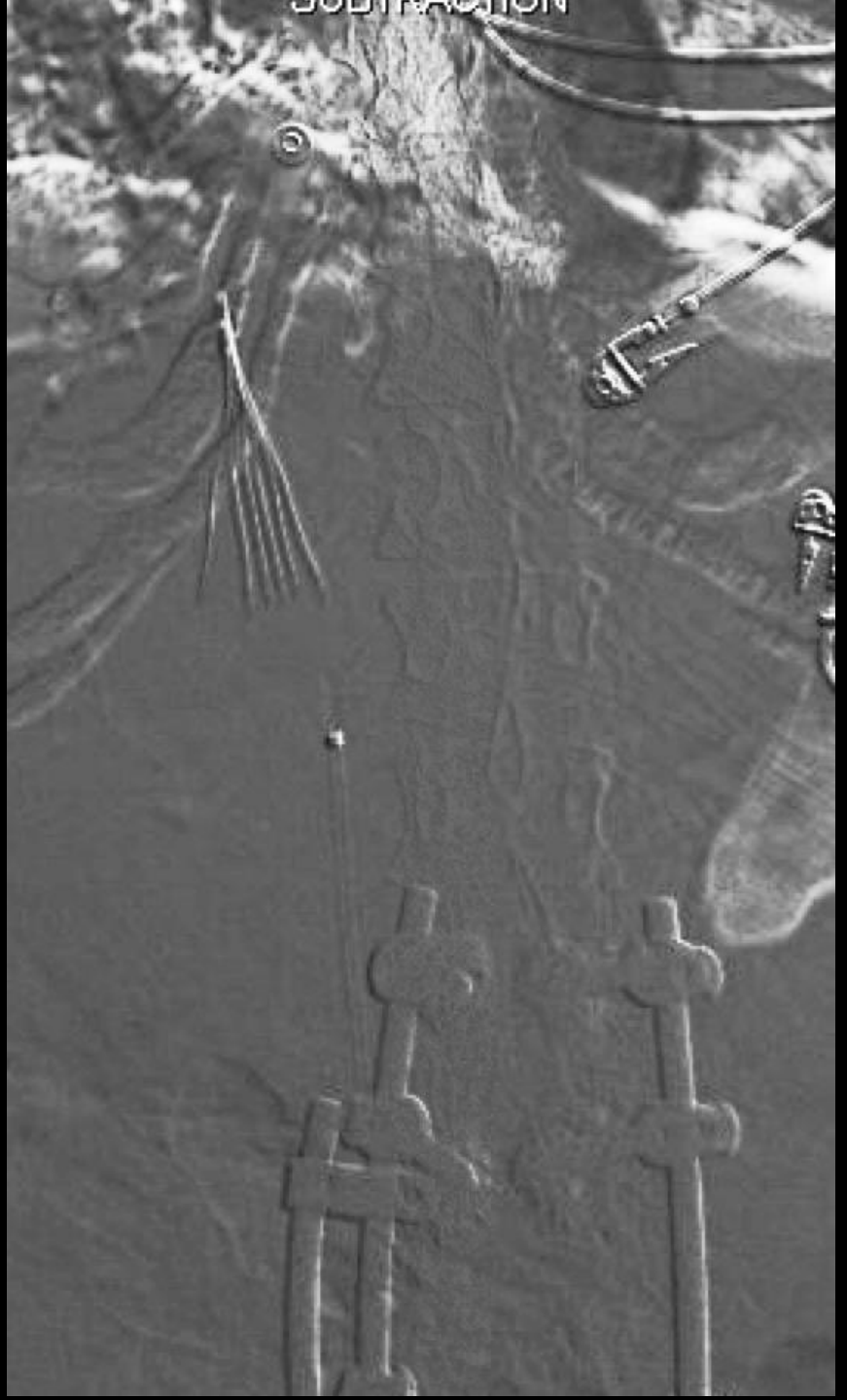






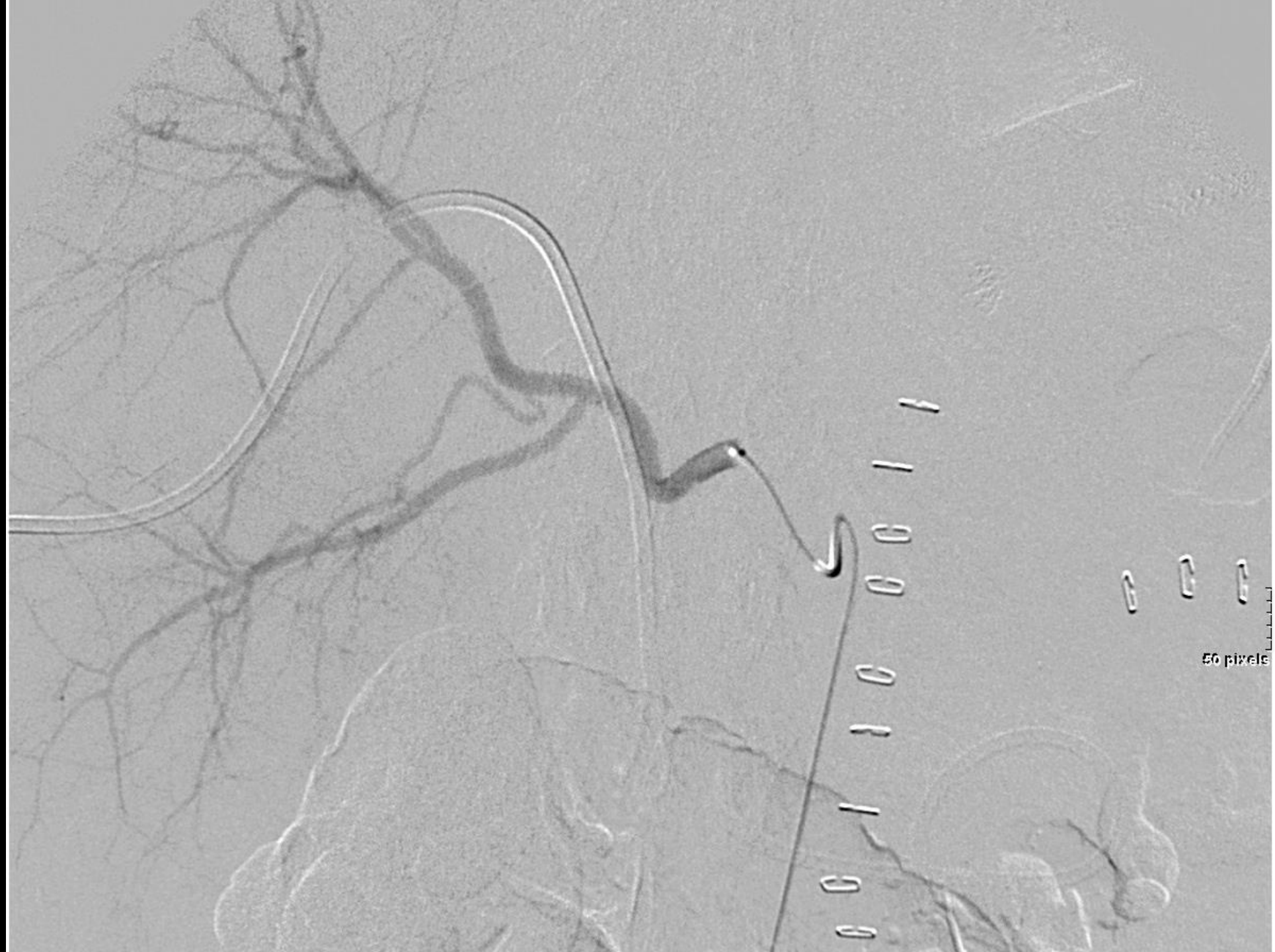
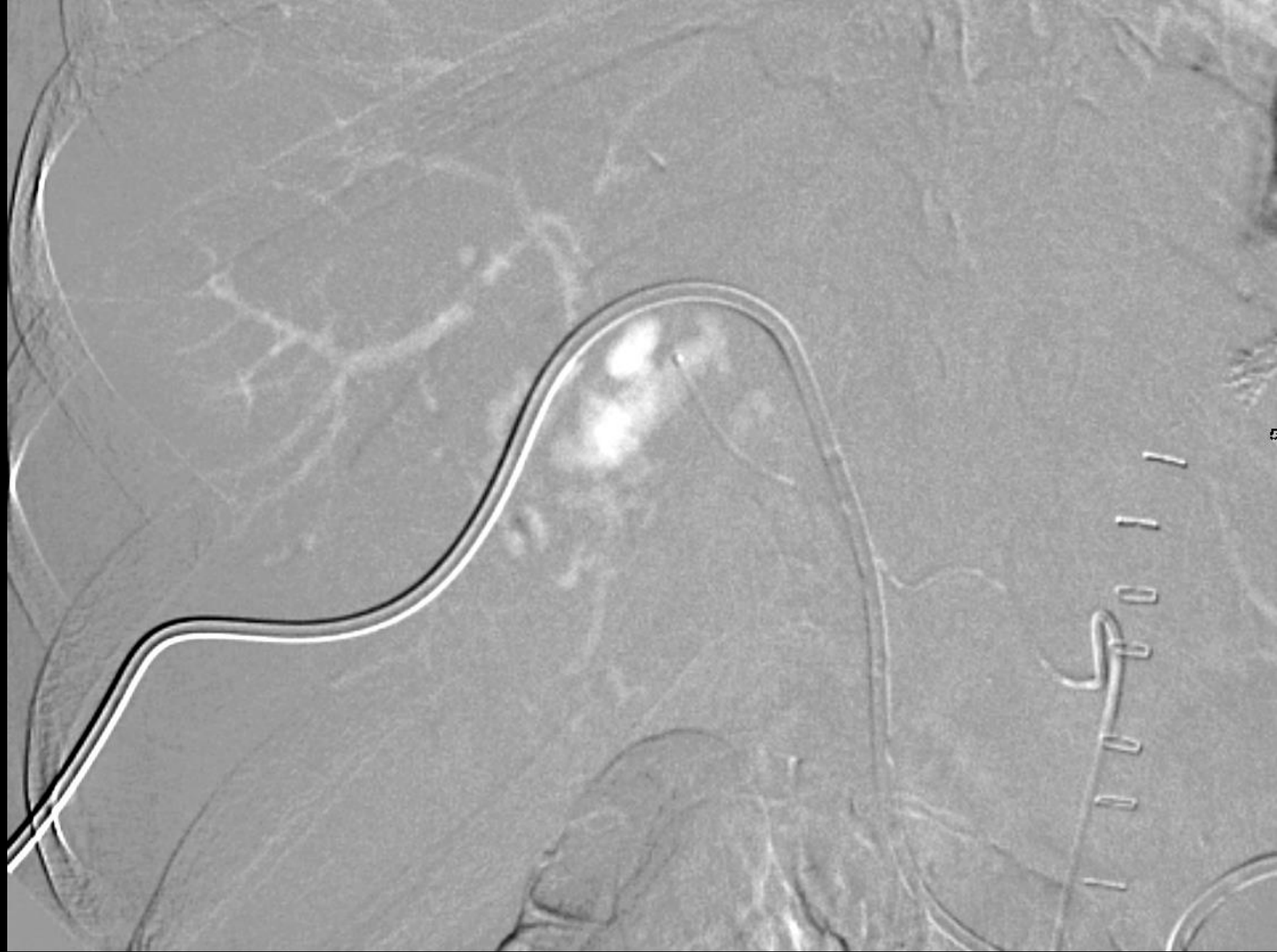SUBTRACTION

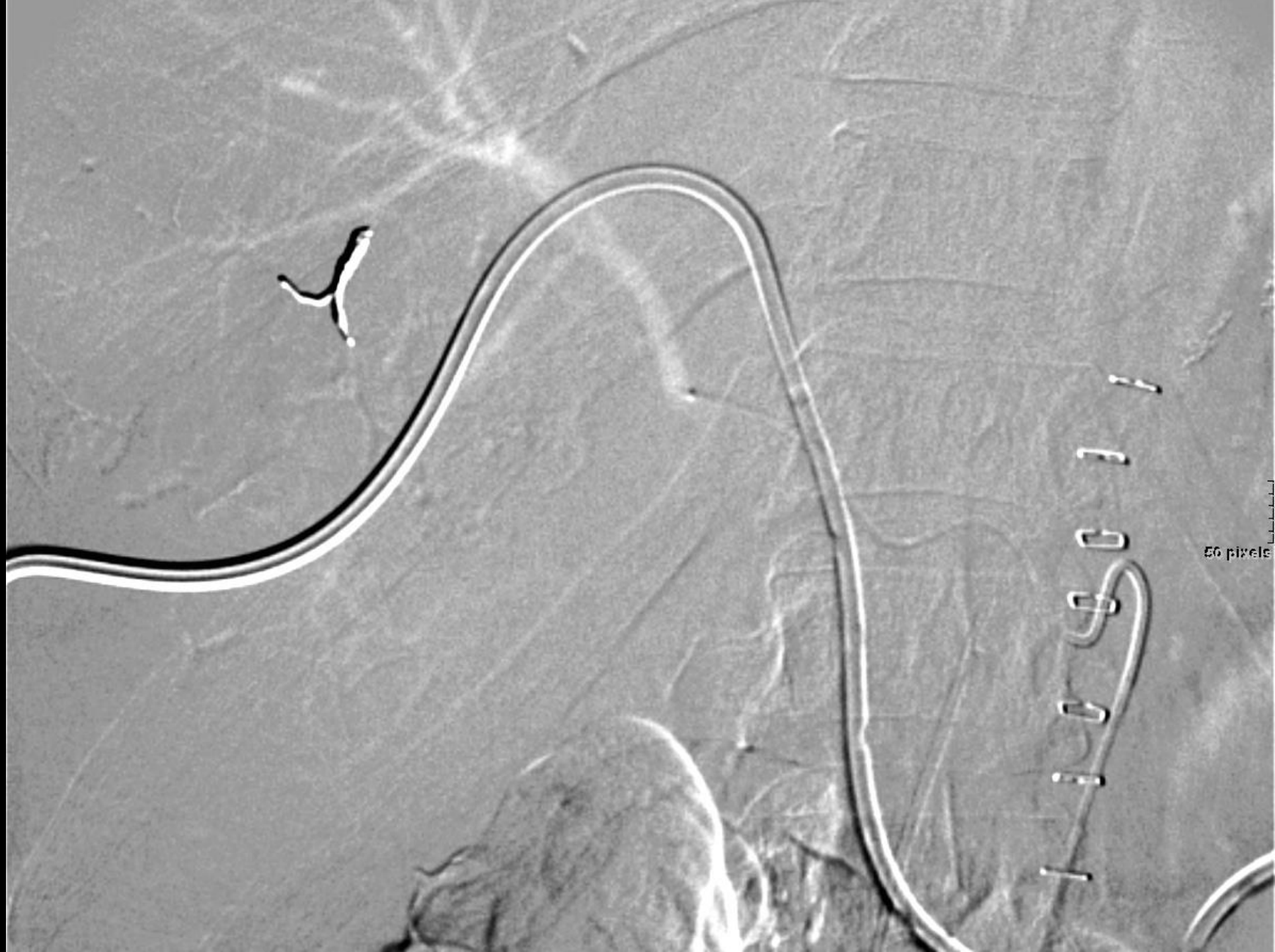

Biopsy Bleed

**BILIARY BLEED POST
CATHETER WITH CO₂**







CASE CONFERENCE

6/04/2106