

# Daily Routine Use Of CO2 to Minimize Contrast in an Office Based Lab

## Karl R Stark MD FACS

Midwest Aortic and Vascular Institute  
Kansas City, Kansas, USA

Associate Professor  
Surgery UMKC School of Medicine  
Kansas City, Kansas, USA



19th Annual Conference

2018  
May 30 - June 01

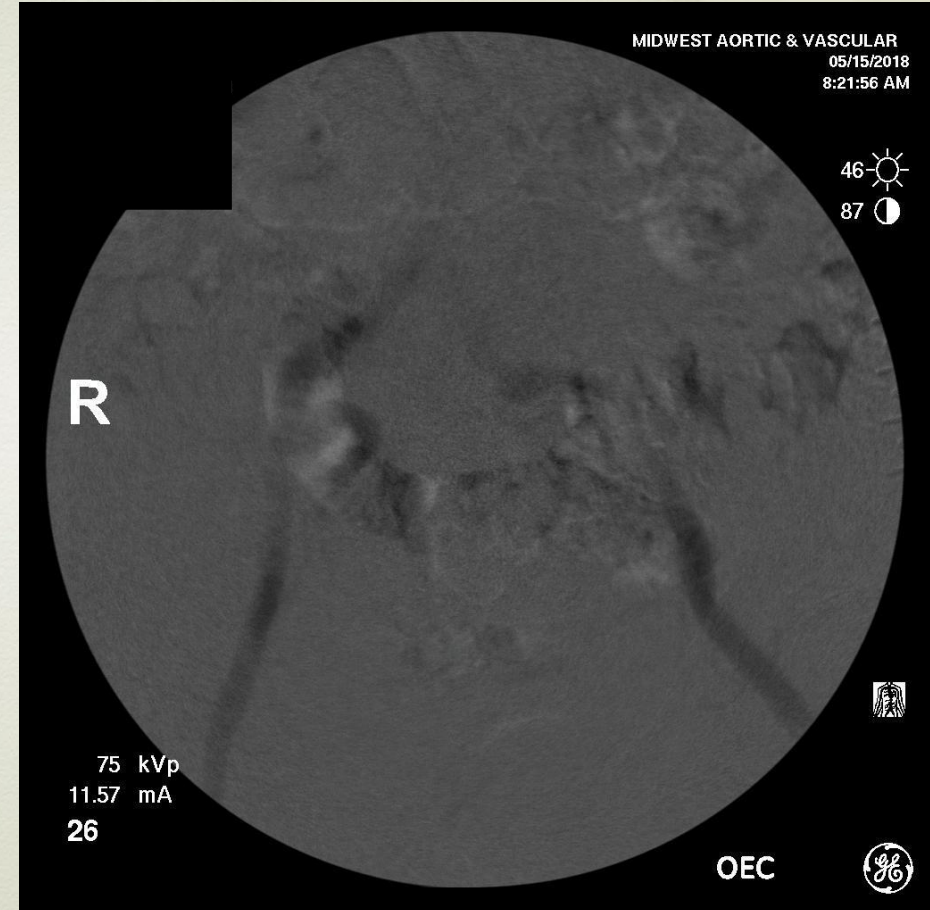
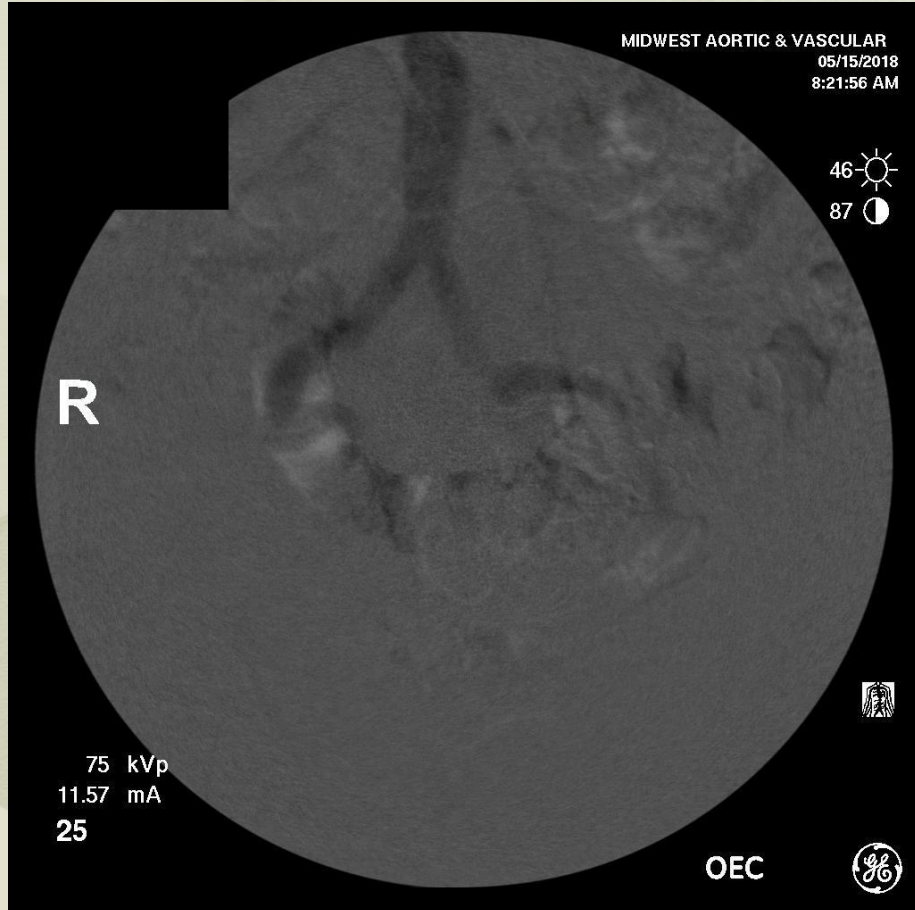
THE PERIPHERAL EVENT OF THE YEAR



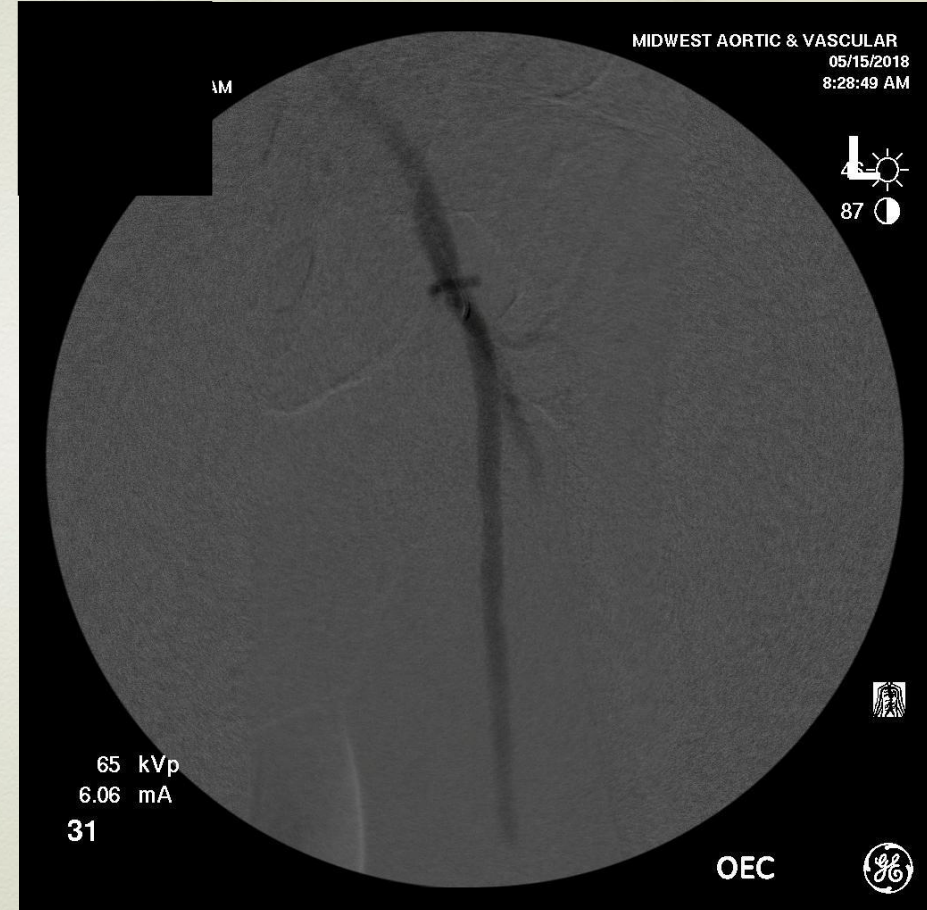
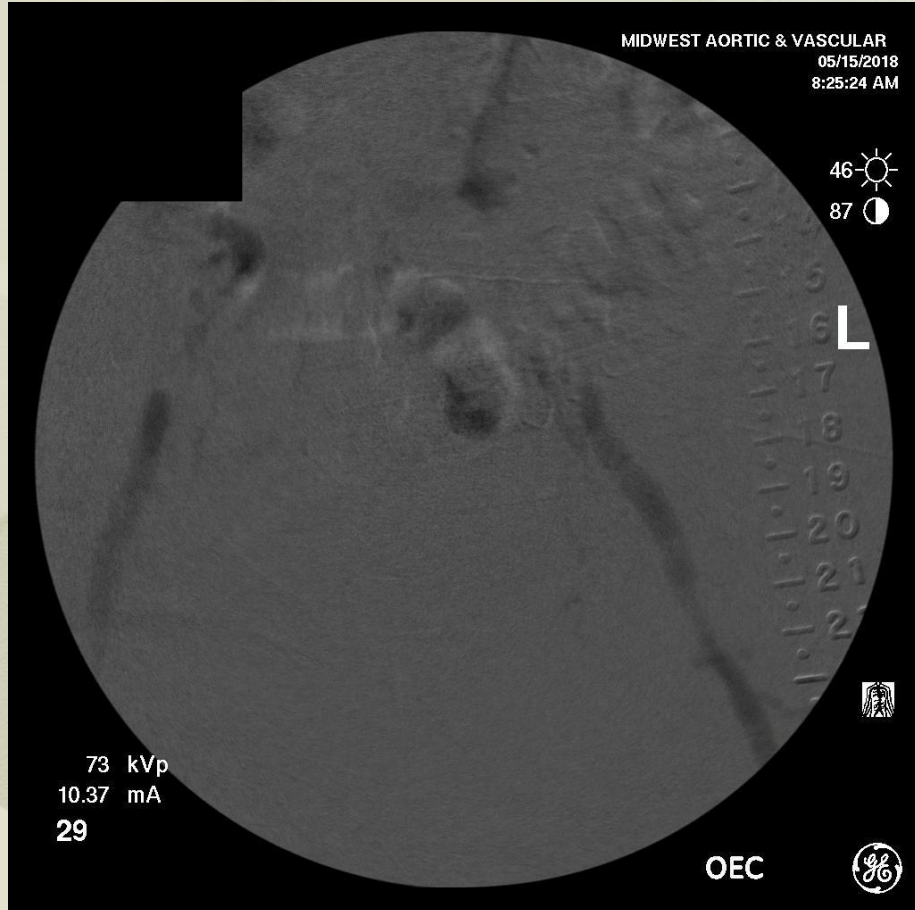# Case 1

- 74year old white male
- Former smoker
- Diabetes Mellitus
- A/A .43
- Necrotic second toe

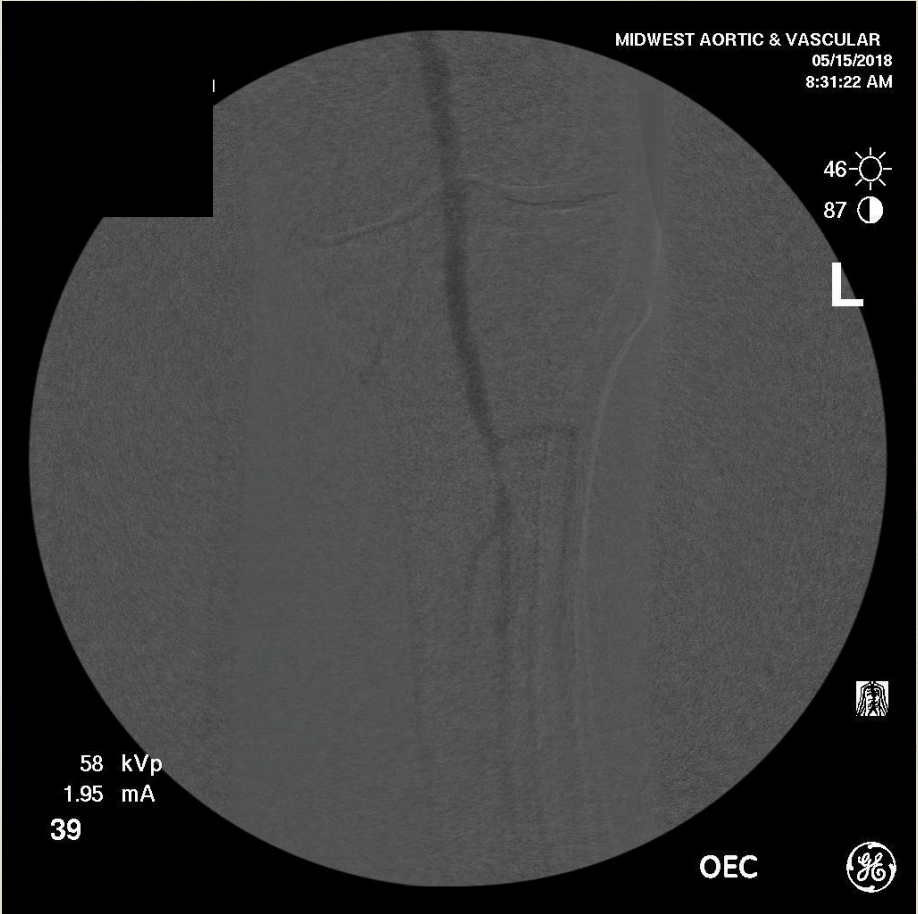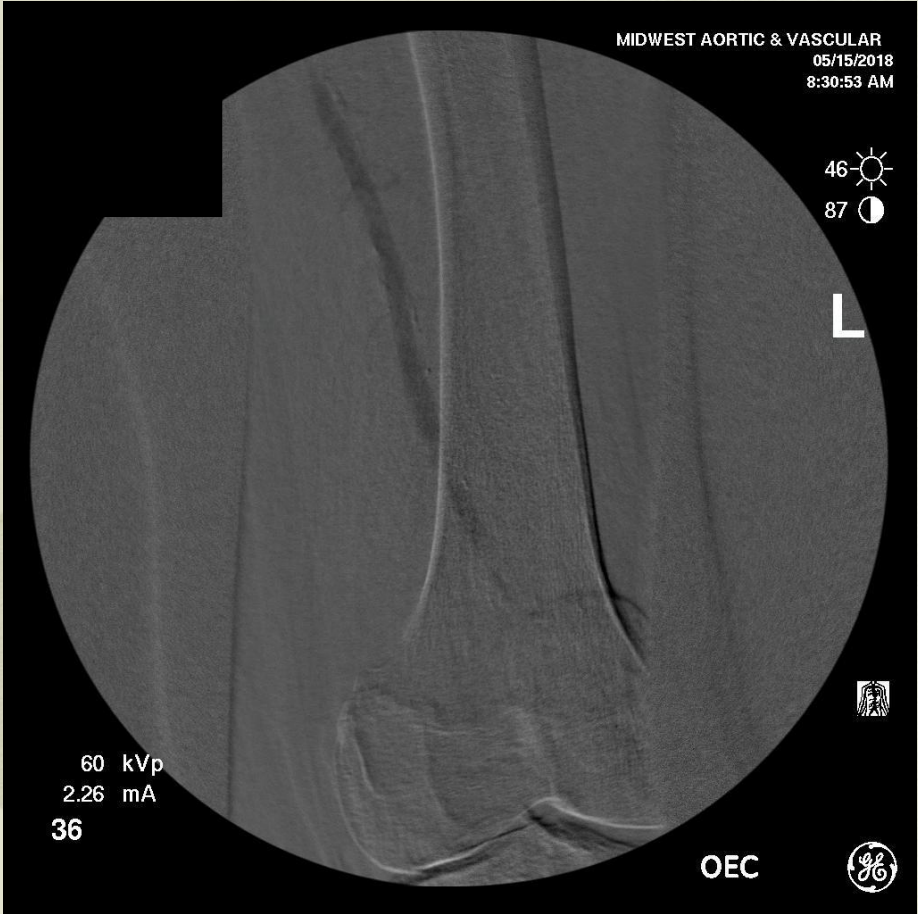Don't have reprocessing available. Can't stack images, yet adequate evaluation is done.



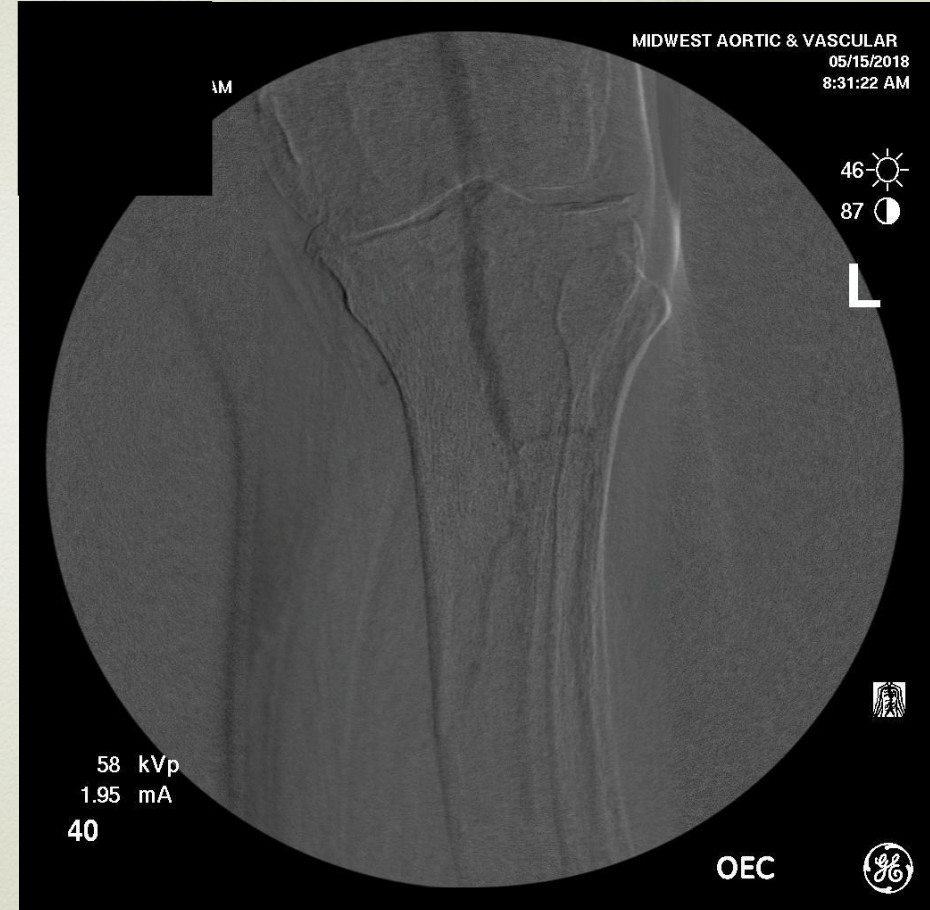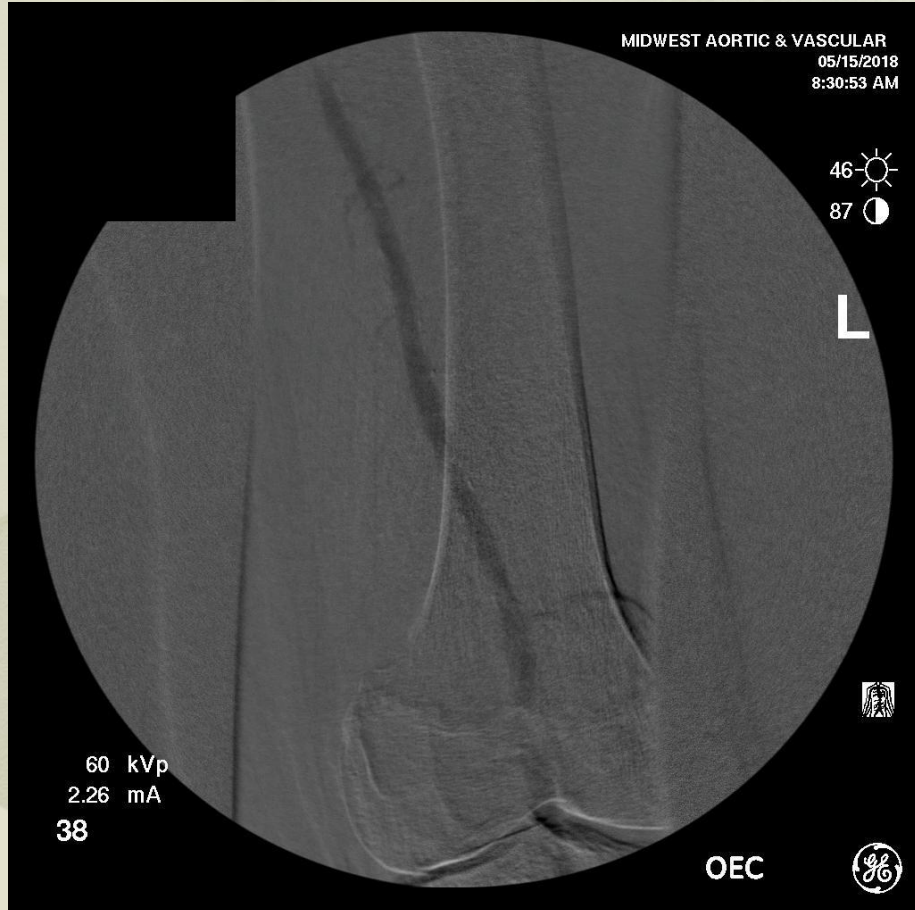**As with contrast; local injection of limited amount of agent directly area being evaluated.**



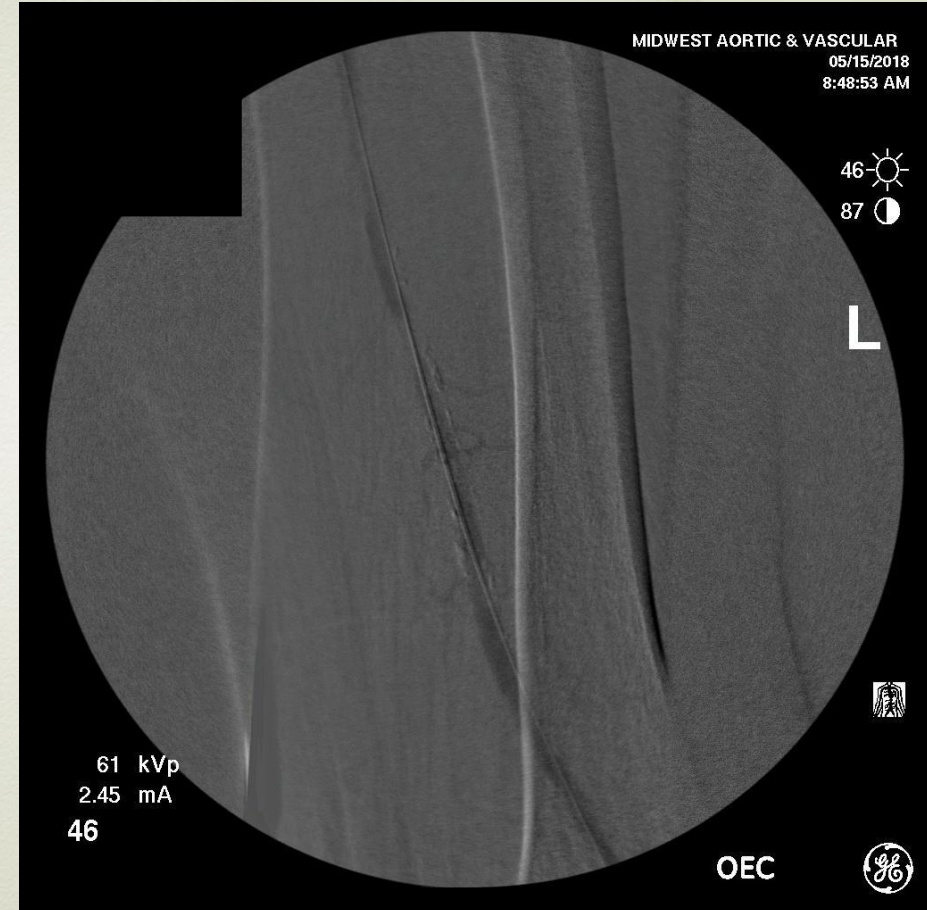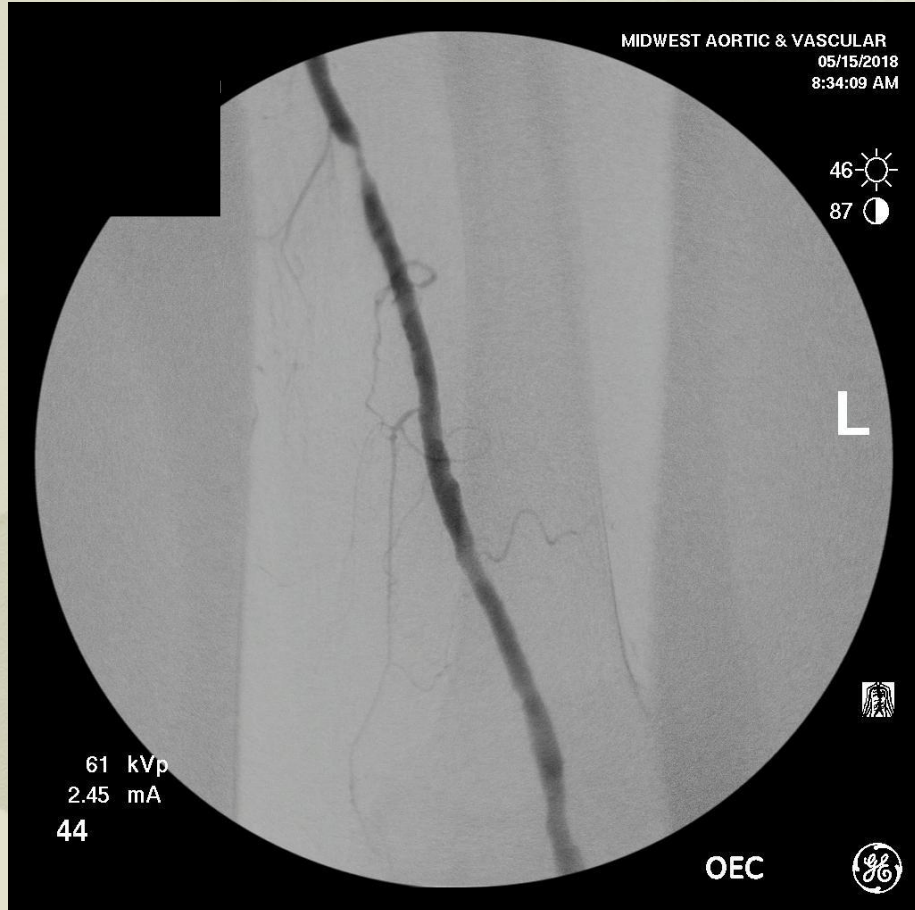
# Sequential images with limited injections of CO2



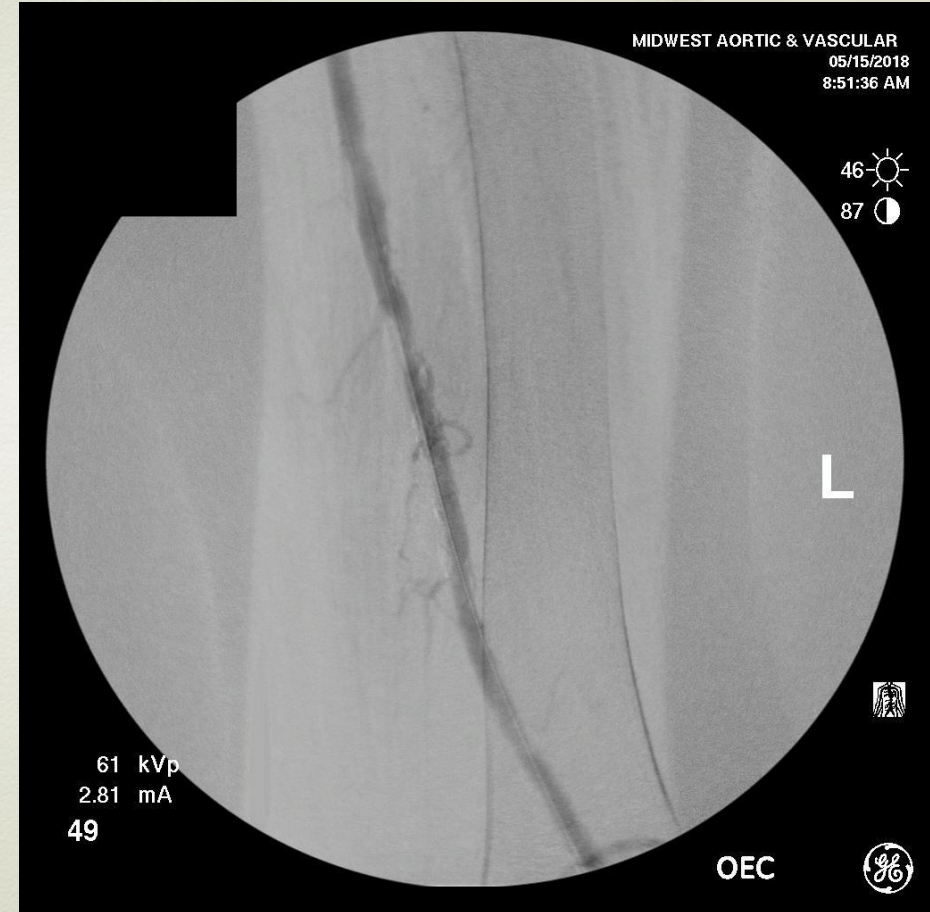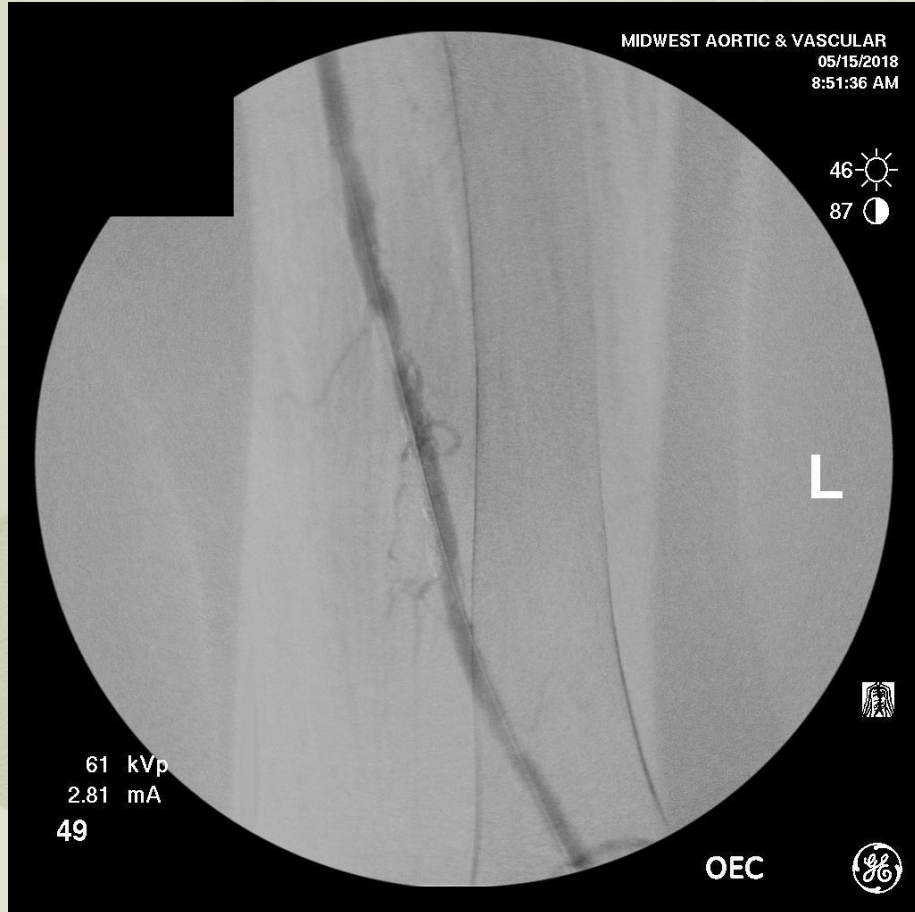# Generally see adequate images.



**Confirm with limited contrast injection 2 to 3 cc's.**

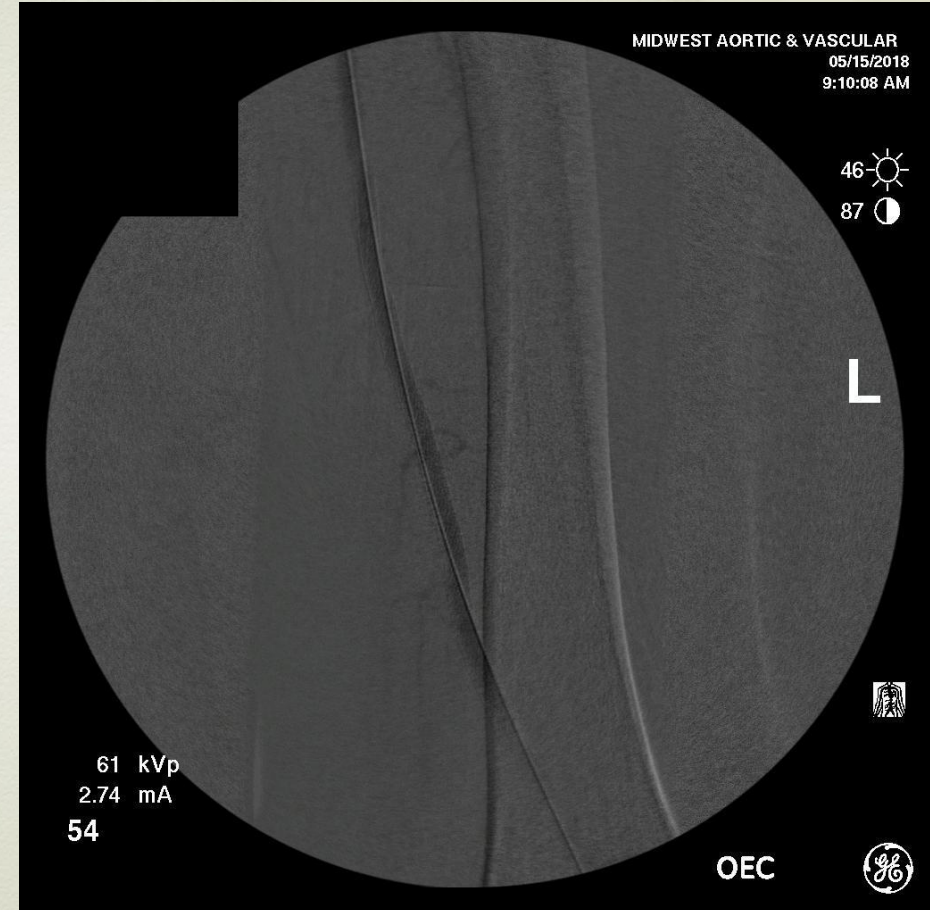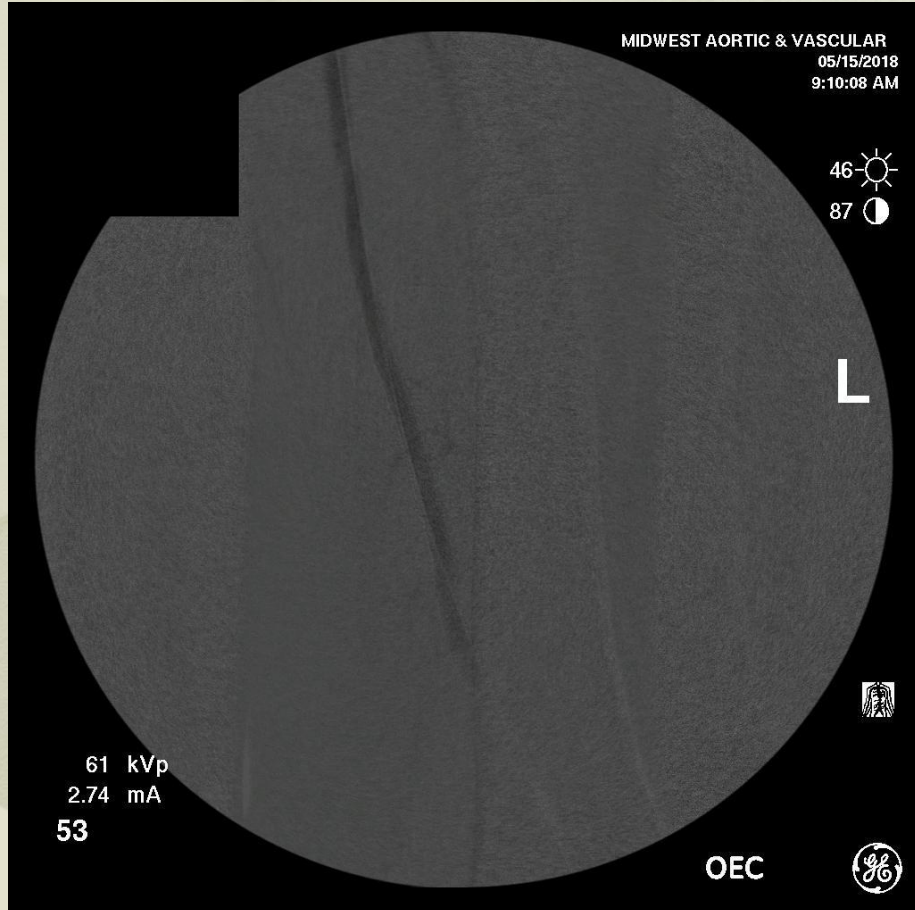


# Use CO2 for intervention.



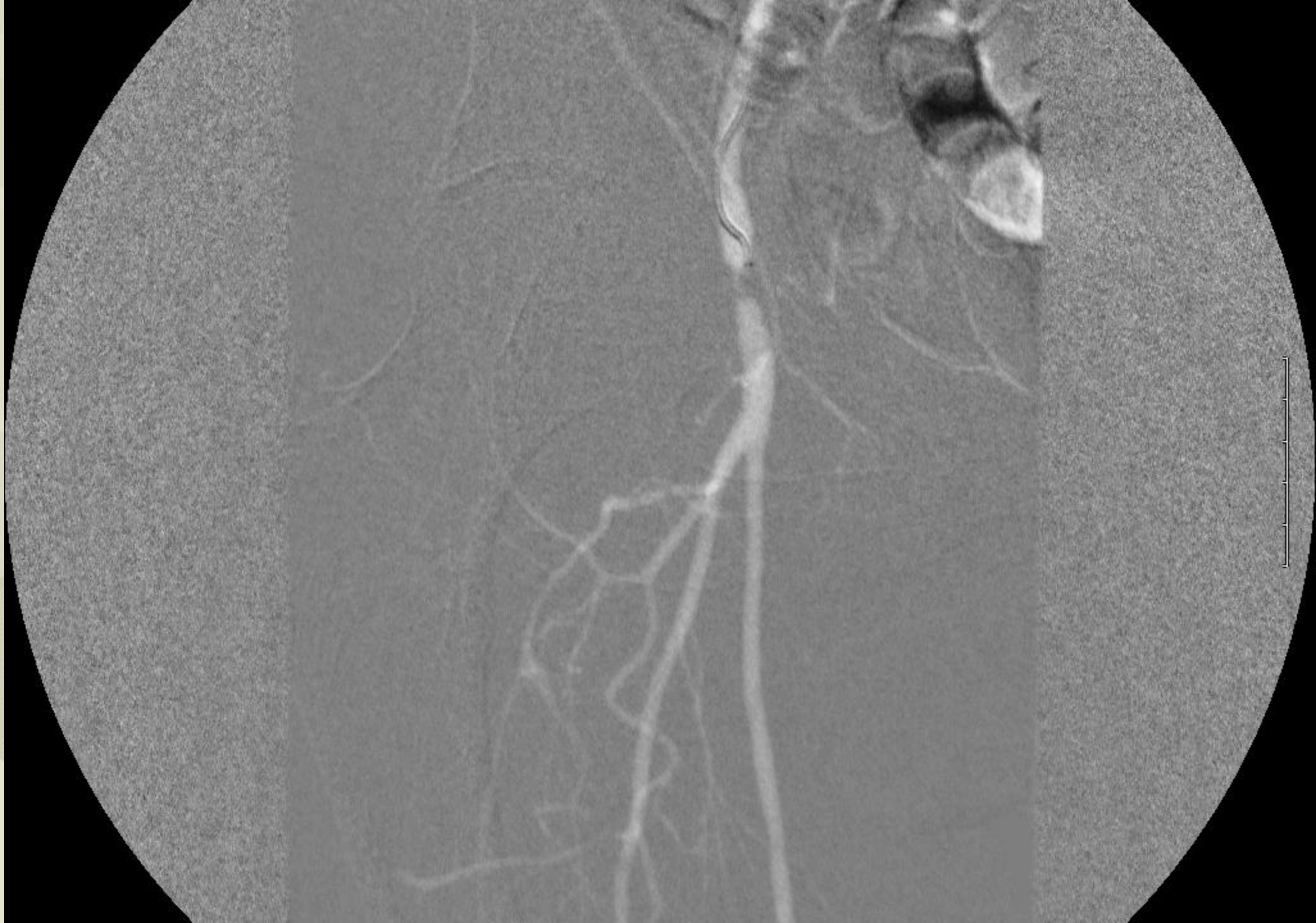

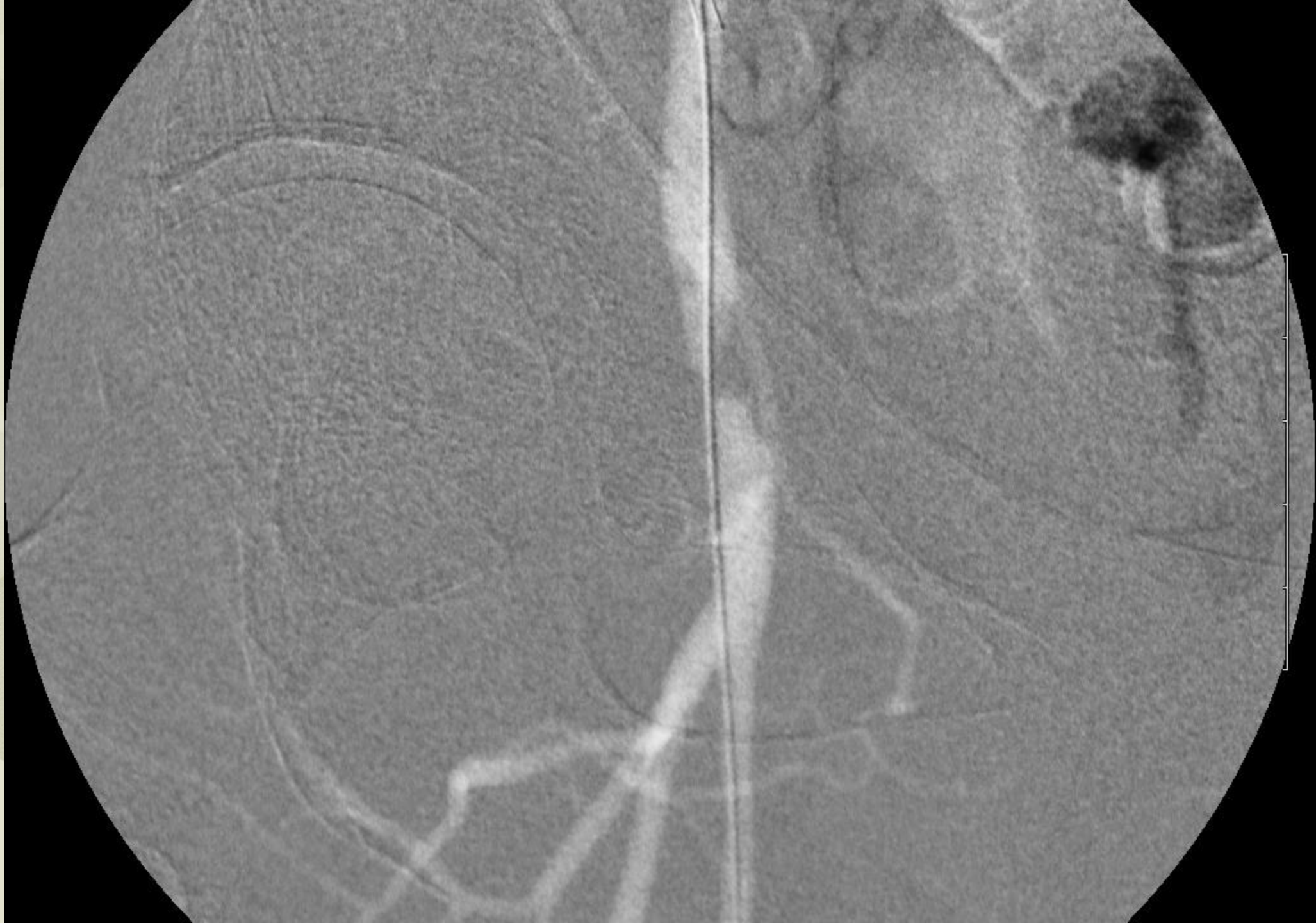# Atherectomy with angioplasty

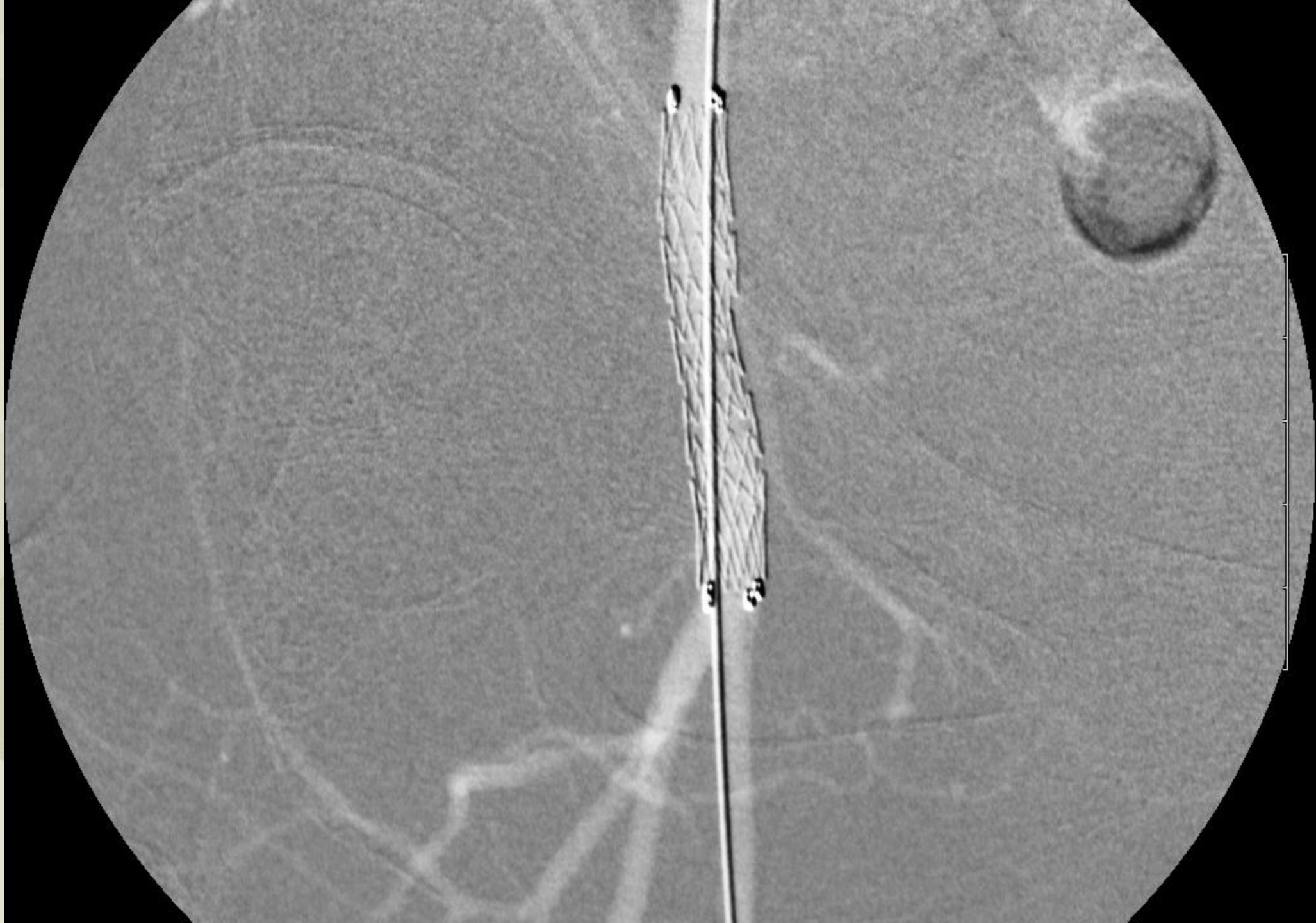


# 85 year old female

- Ischemic foot wounds
- Ischemic rest pain
- Stage III CKD





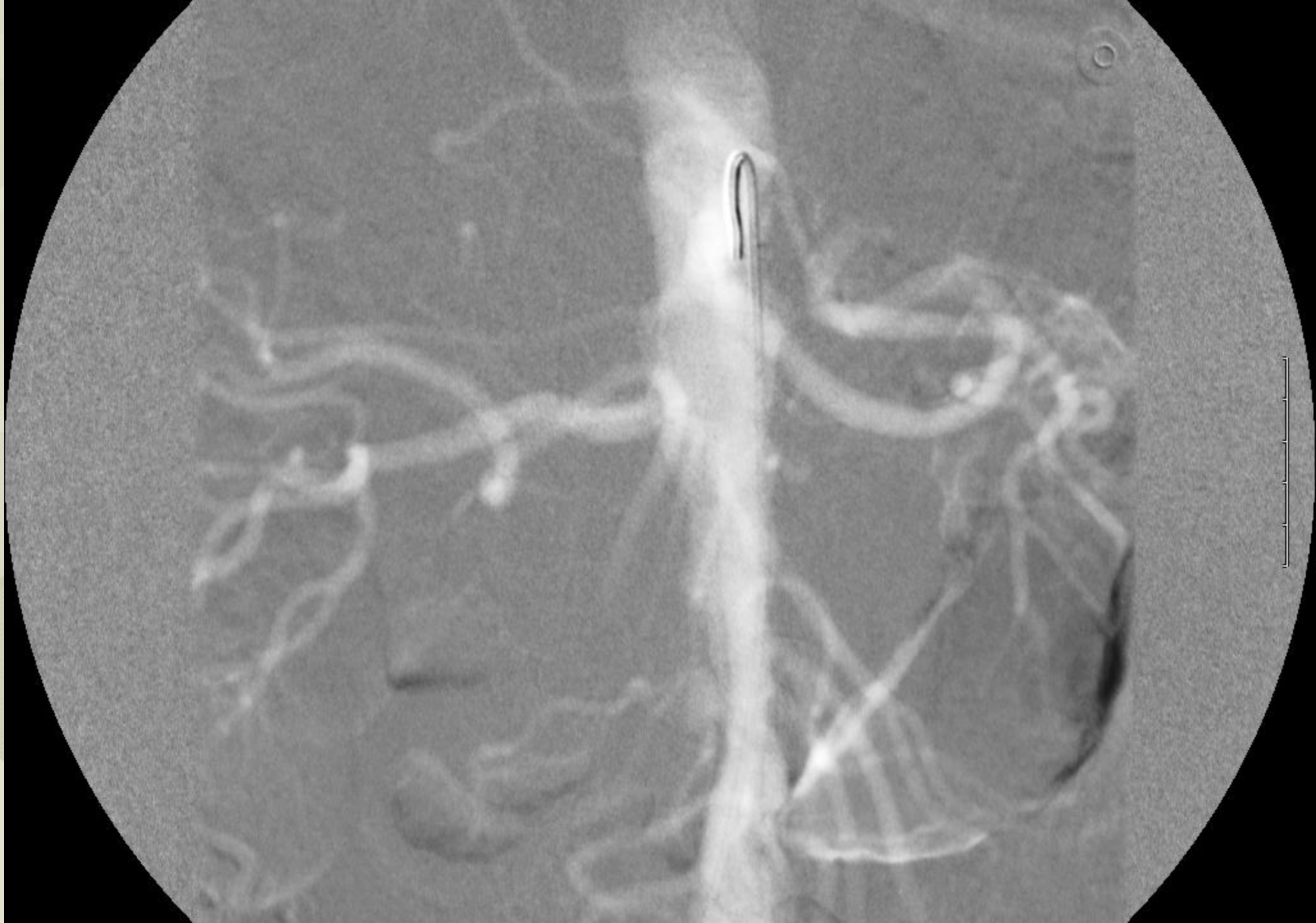

# Renal Failure Patient On Dialysis

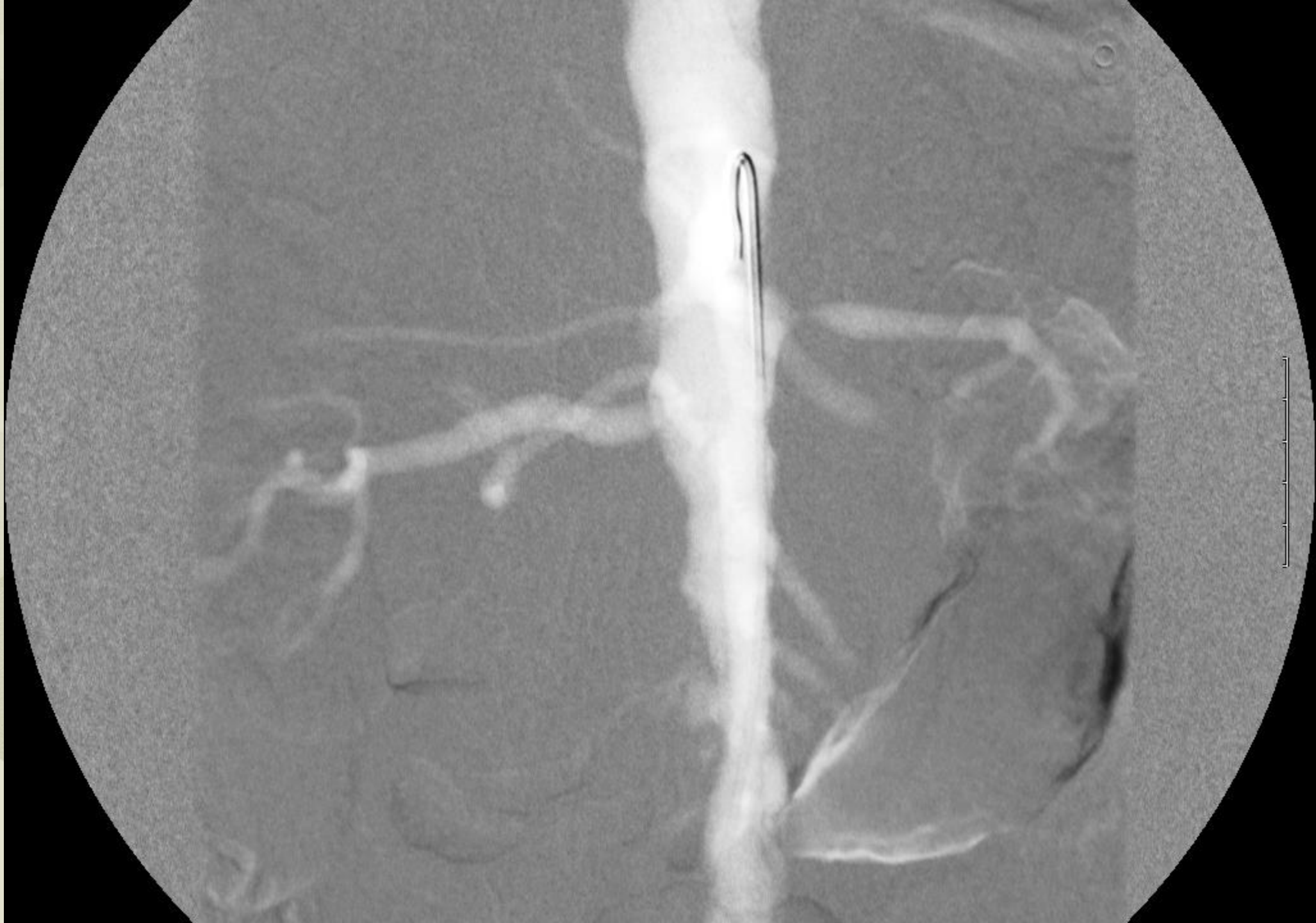- Advantage of maintaining of some renal function.
- Patients are much easier to manage from their renal failure if they have any kidney function maintained.
- If access is lost they tend to tolerate a missed dialysis much better.
- Fluid and potassium management is much easier in this group of patients.

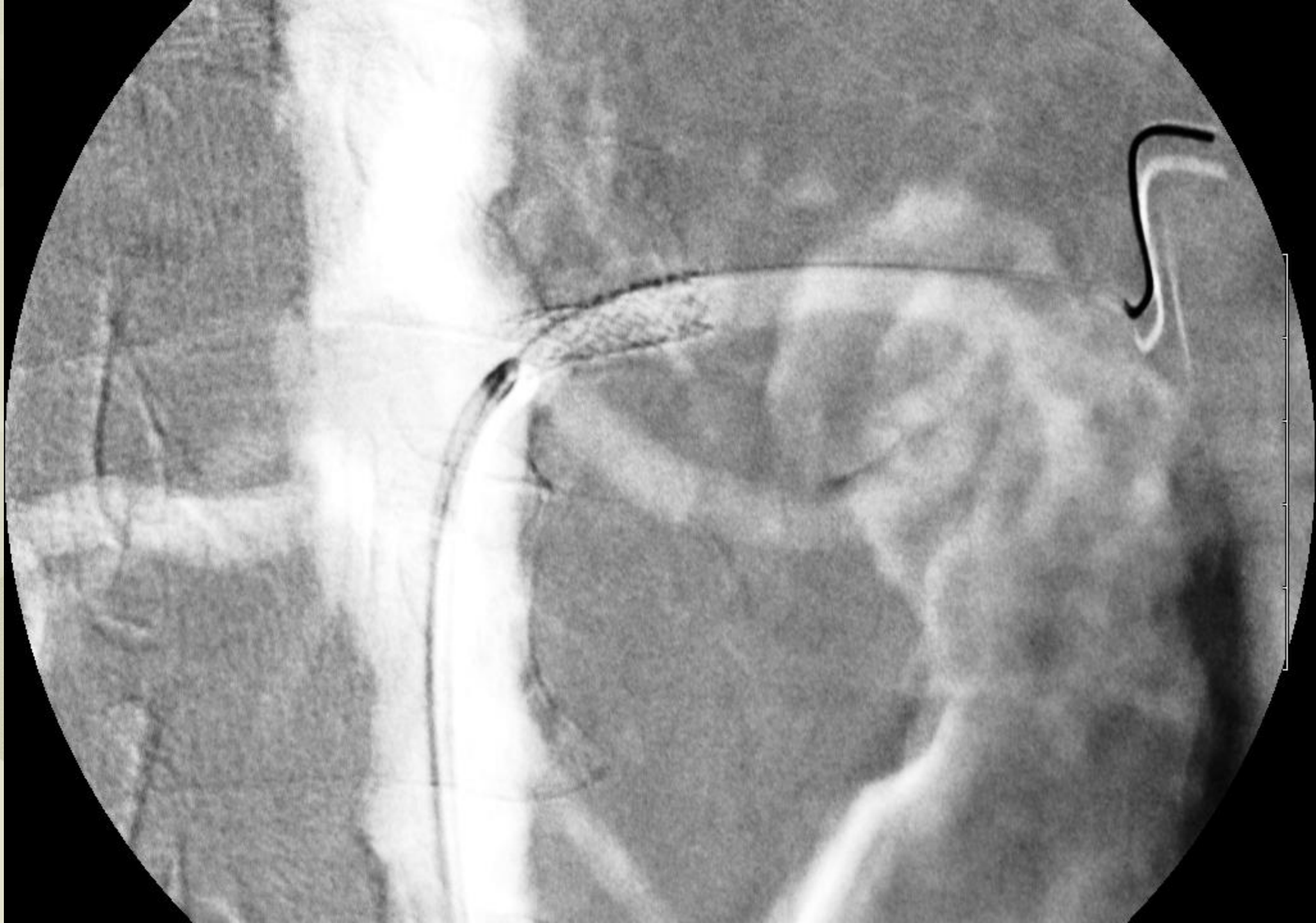
# 52 year old Black Female

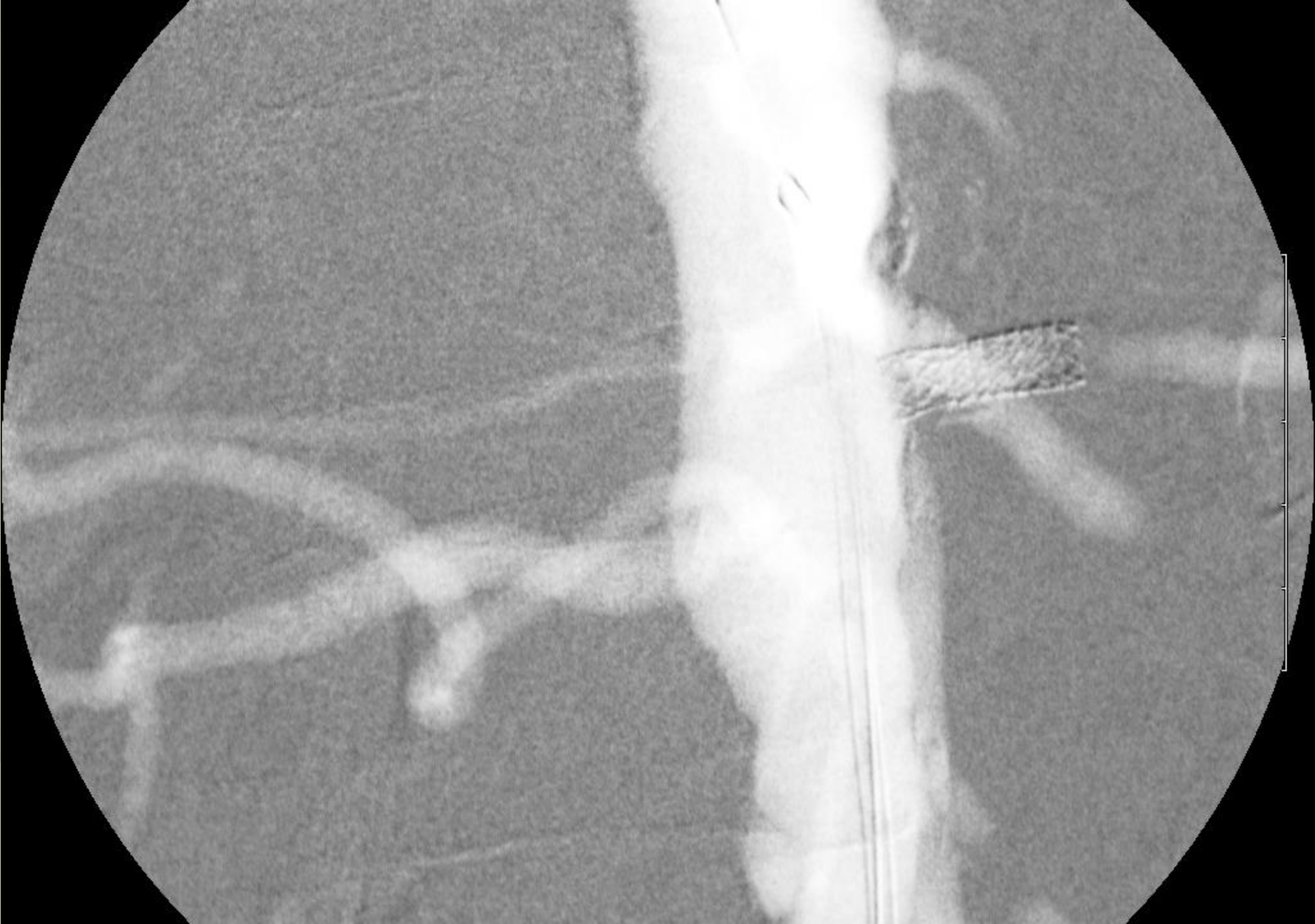- Had acute worsening of chronic renal failure. Now off dialysis.
- Duplex scan suggest severe bilateral renal artery stenosis.

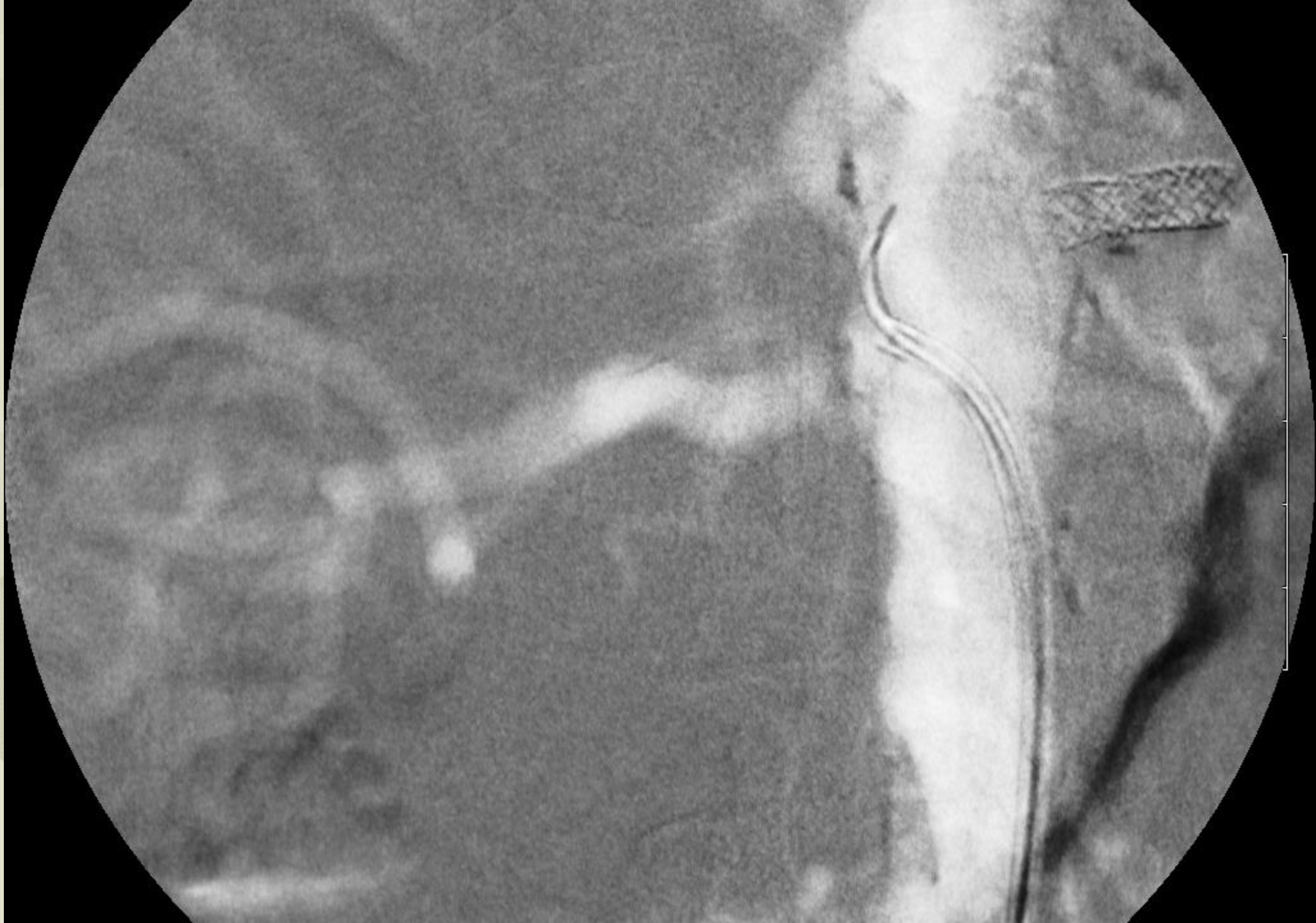


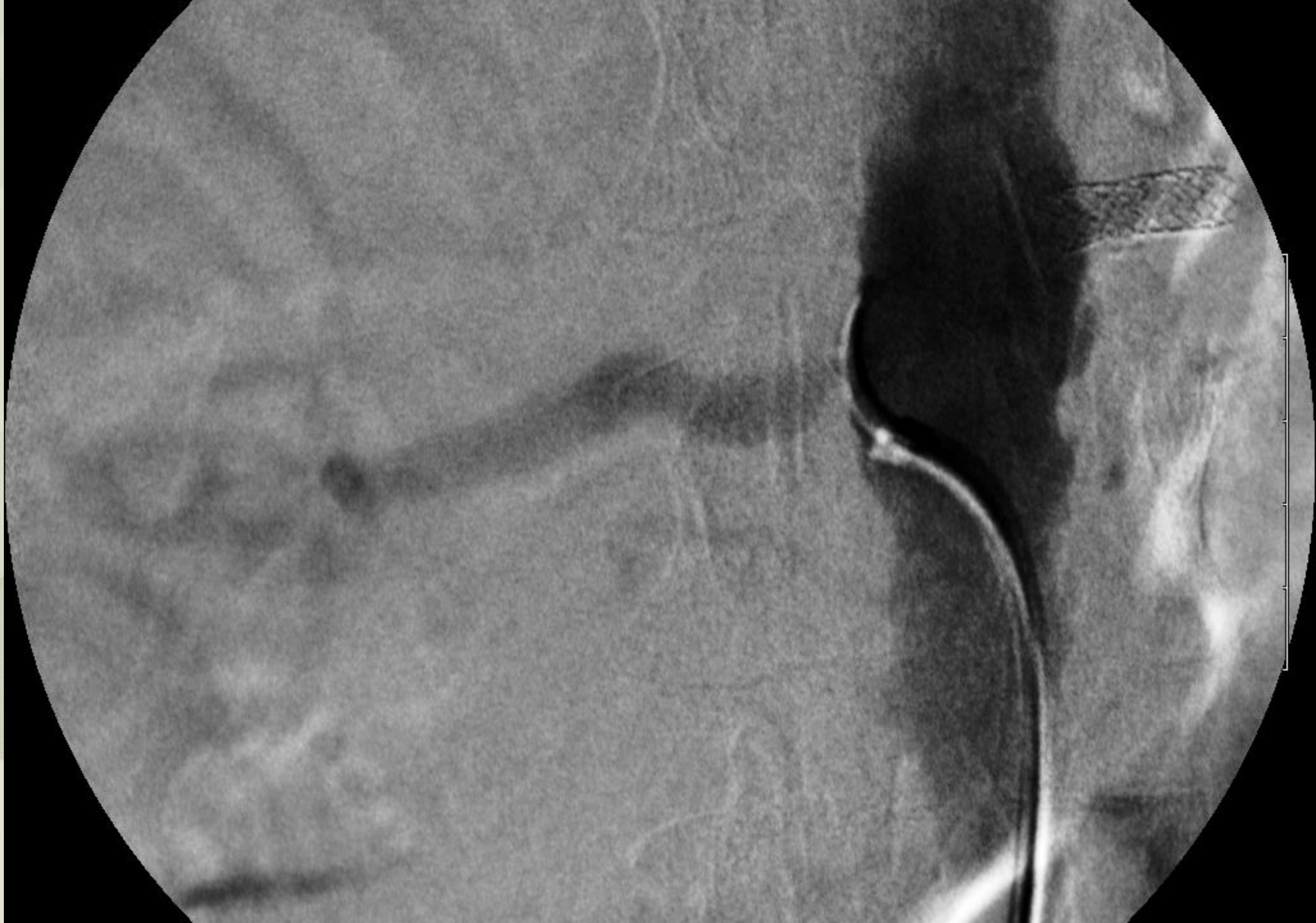


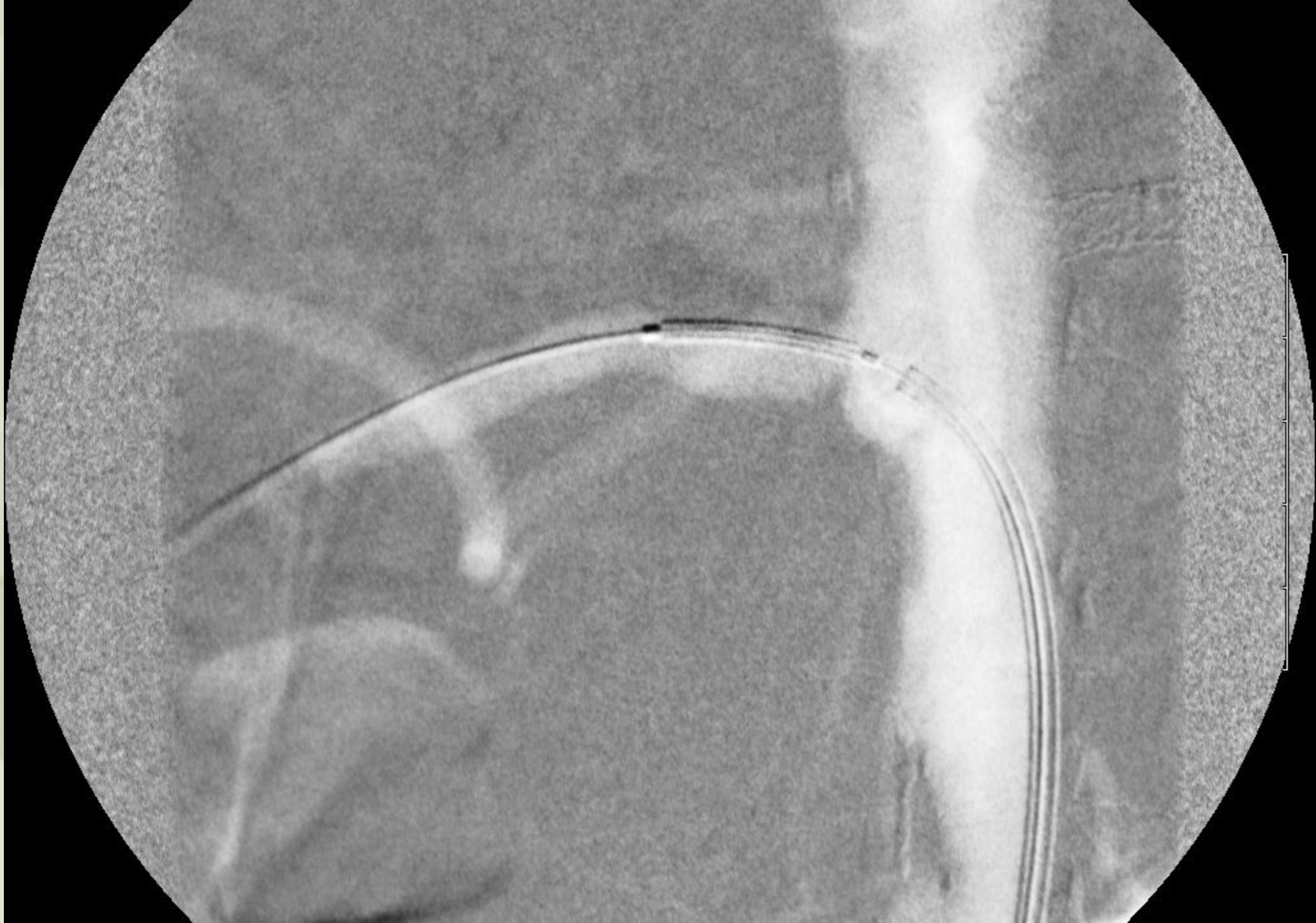


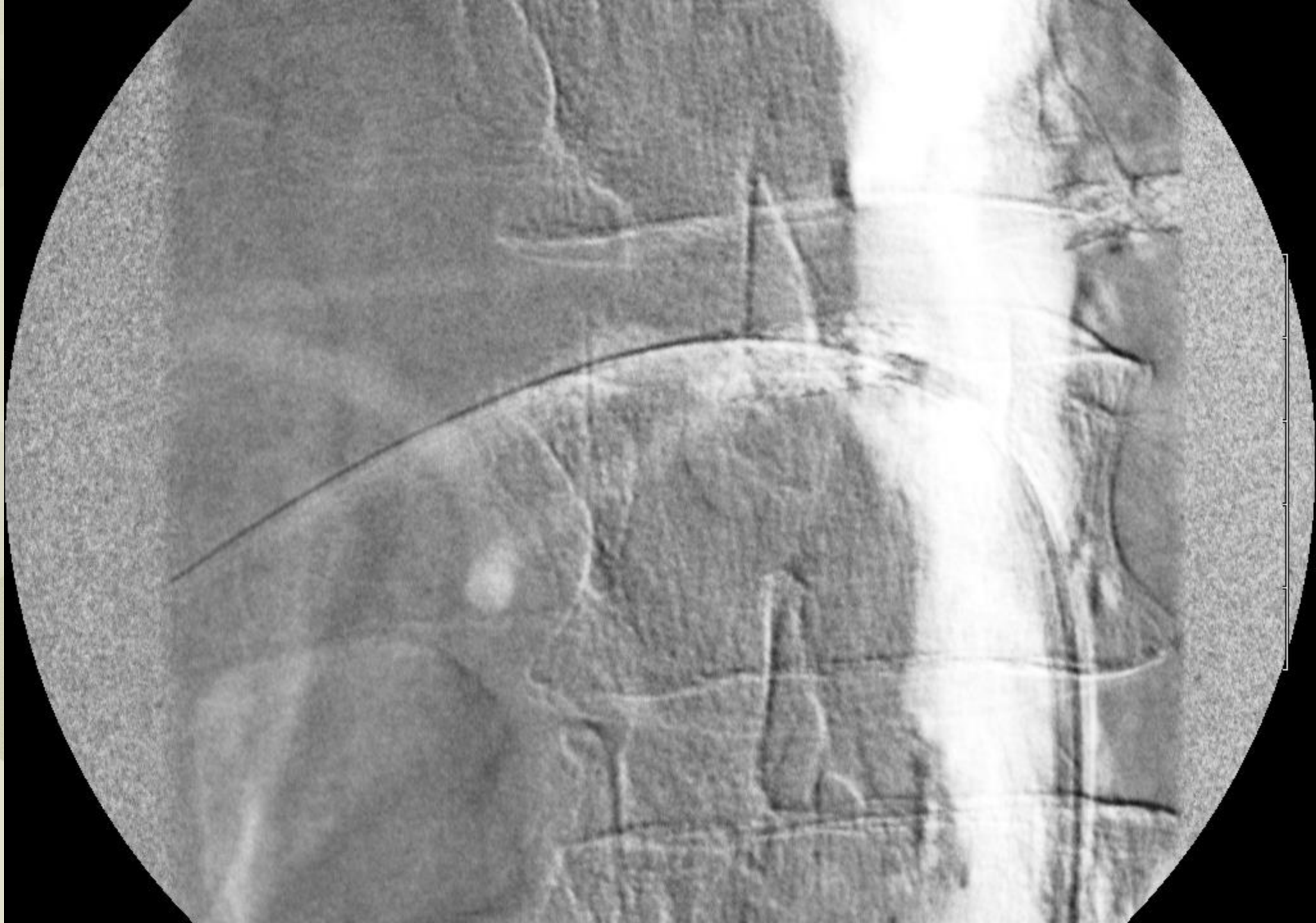












# Disclosures

- None



# Daily Routine Use Of CO2 to Minimize Contrast in an Office Based Lab

## Karl R Stark MD FACS

Midwest Aortic and Vascular Institute  
Kansas City, Kansas, USA

Associate Professor  
Surgery UMKC School of Medicine  
Kansas City, Kansas, USA



19th Annual Conference

2018  
May 30 - June 01

THE PERIPHERAL EVENT OF THE YEAR

