

---

# ANATOMY AND PATHOPHYSIOLOGY OF FACIAL AGING

*Marc S. Zimble, MD, Mimi S. Kokoska, MD,  
and J. Regan Thomas, MD*

Facial aesthetics begin with the marriage of hard and soft tissue integration; however, it is the changing balance of these elements that is the hallmark of the aging process. The major forces responsible for facial aging include gravity, soft tissue maturation, skeletal remodeling, muscular facial activity, and solar changes. Clearly, a person's age often is judged on the appearance of his or her skin (Fig. 1). Although much has been written on cutaneous gerontology, it is really the balance of skeletal structure, soft tissue, and skin that is responsible for the appearance of cutaneous senescence (Fig. 2). These observations reveal a major characteristic of facial aging, in that the primary changes in a person's three-dimensional skeletal contour can lead to secondary changes in the overlying soft tissue and skin. A youthful face therefore represents a point in time when a particular set of skeletal proportions are ideal for their soft tissue envelope.

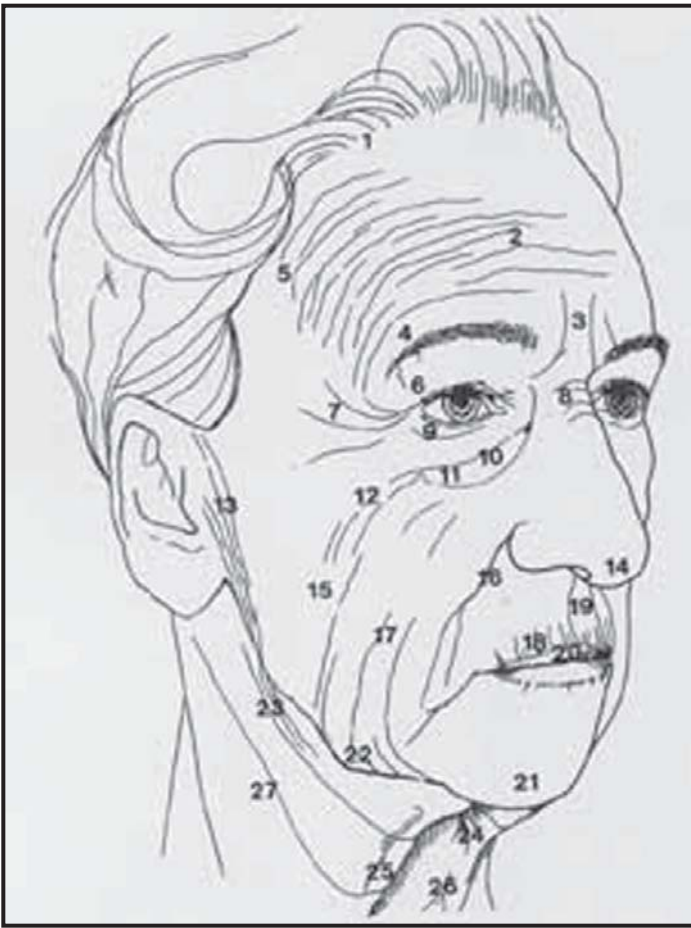
As we enter the 21st century, the aging of the baby-boomer generation remains one of the more interesting social phenomena to be revealed. As this group rounds their own half-century mark, the

problem of aging appearance has never been more in the forefront of consumer consciousness. Moreover, one of the most interesting medical conditions to affect this subgroup of the population is photoaging. Baby boomers spent their formative years outdoors and in the sun with the hope of obtaining a "healthy tan," without the benefit of today's sunscreens.

When the effects of aging on the face are addressed, what is really being discussed is wrinkles. Everything about the wrinkle seems elusive; even its terminology is unclear. Descriptive terminology in the literature is not uniform and includes wrinkles, rhytides, creases, lines, furrows, and folds. Facial wrinkles have been studied by light microscopy and found to have no distinguishing histologic features." Instead, wrinkles are a configuration change in the skin secondary to a variety of factors, without specific structural changes at the histologic level." Wrinkles originate from a wide variety of sources, which can include chronologic skin aging, environmental factors, photoaging, hyperdynamic facial expressions, and skin folding secondary to loss of underlying skeletal

---

*From the Department of Otolaryngology—Head and Neck Surgery, Division of Facial Plastic Surgery, Beth Israel Medical Center, New York, New York (MSZ); the Department of Otolaryngology—Head and Neck Surgery, Division of Facial Plastic Surgery, Saint Louis University Hospital, St. Louis, Missouri (MSK); and the Department of Otolaryngology—Head and Neck Surgery, Division of Facial Plastic Surgery, University of Illinois at Chicago School of Medicine, Chicago, Illinois (JRT)*



**Figure 1.** Typical aging skin changes. 1 = thinning hair and receding hairline; 2= forehead rhytids and ptosis; 3= glabellar rhytidosis; 4 = brow ptosis; 5 = temple rhytidosis and ptosis; 6= upper lid redundancy and ptosis; 7= lateral canthal rhytidosis; 8 = nasal root rhytidosis; 9 = lower lid redundancy and rhytidosis; 10 = lower lid fat pseudo-herniation; 11 = malar bag formation; 12 = cheek rhytidosis; 13 = preauricular rhytidosis; 14 = nasal tip ptosis and dependency; 15 = cheek sagging and fat atrophy changes; 16 = deepening nasolabial crease; 17= facial rhytidosis and sagging; 18 = perioral rhytidosis; 19= upper lip flattening and lengthening; 20 = thinning and atrophy of vermillion (red lip); 21 = chin pad ptosis and retraction; 22 = jowl formation; 23 = cervical rhytidosis; 24 = submental fat accumulation; 25 = platysmal banding; 26 = rhytidosis and midneck hollowing; 27= submaxillary gland ptosis.

and soft tissue support.

The anatomy and pathophysiology of the aging face are presented here. This article also defines the affects of the aging process on the skeletal structure, skin, and musculature and examines how these changes affect the upper, middle, and lower thirds of the aging face.

## SKELETAL STRUCTURE

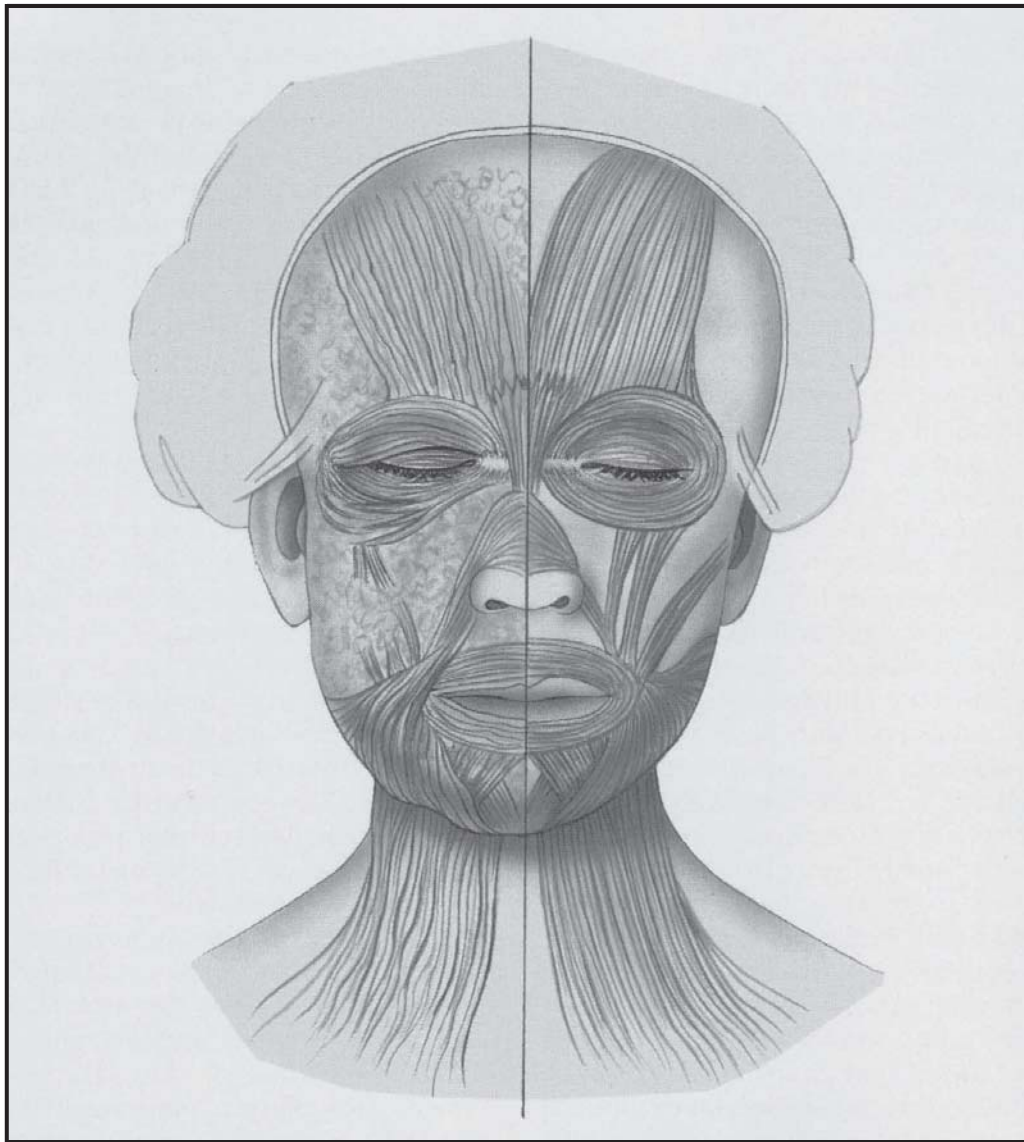
Contrary to popular belief, craniofacial bony aging is due to a relative change in bone expansion and loss and is not merely the result of atrophy.<sup>1</sup> Appreciable

reduction in facial height, most marked in the maxilla and mandible, cannot overcome the modest increases in facial width and depth. Because of remodeling, the overall distance between key skeletal structures can change and actually decrease over time. An example of this is seen in the maxilla, where, as the craniofacial skeleton ages, the orbits increase in size and the maxilla decreases in size. In effect, this process creates less available space for the overlying tissue, resulting in the inferior displacement of the cheek fat pad and skin, with deepening of the melolabial fold.<sup>1</sup> Moreover, pyriform remodeling and maxillary resorption can lead to excess soft tissue of the upper lip, contributing to perioral wrinkling. In regard to the mandible, tooth loss ultimately results in marked resorption of the alveolar ridge, whereas the chin's shape and its projection also change with age. Furthermore, with skeletal aging one sees a general coarsening of bony protuberances where masticatory muscles attach (e.g., gonial angle and the inferior edge of zygomatic eminence), whereas in regions where no such forces exist, a general softening occurs.

## SKIN

As in all other organ systems, the skin and its appendages undergo characteristic changes with advanced aging. Many of the changes on the face secondary to aging are the result of gravity's acting on skin that is becoming progressively thinner, drier, and less elastic. Genetic factors influence location and shape of facial wrinkles. Many of these changes are not the inevitable result of mere cutaneous senescence but are more likely a result of cumulative environmental insults.<sup>1</sup> Thus, one must differentiate changes that occur as a result of intrinsic aging versus photoaging. Chronic solar exposure is the major environmental insult that contributes to the clinical changes attributed to aging skin. This is accurately termed photoaging and is distinct from intrinsic or chronologic aging. Furthermore, the notion that photoaging alone accelerates chronologic aging is too simplistic.

Cellular manifestations in sun-protected skin demonstrate the strong correlation between age and the behavior of skin cell populations. These changes are most striking between newborn and adult but also can be detected between young adults and older adults. Studies reveal an inverse relationship between donor age and cumulative population doubling for all three cell types; keratinocytes, fibroblasts, and melanocytes.<sup>19</sup>



**Figure 2.** Changes beneath the skin are reflected in bone, muscle, and soft tissue.

As with intrinsic aging, photoaging is reflected at the cellular level. Compared with cultures from sun-protected sites, photoaged cultures for keratinocytes and dermal fibroblasts have shorter in-vitro lifespans.<sup>18</sup> Morphologic changes in old sun-protected skin consist primarily of laxity, fine wrinkling, and a variety of benign neoplasms. Clinical signs of cutaneous photoaging include changes in color, surface texture, and functional capacity. Color changes include dyschromia and lentiges, progressive sallow yellow pallor, loss of normal translucency or pink "glow," and the gradual appearance of telangiectasia and uneven purpura. The textural changes begin with a loss of palpable smoothness, progressing to the appearance of frank keratoses

and the parallel development of fine rhytides, followed by persistent deeper folds and creases.

In 1994,<sup>7</sup> clinically photoaged skin was categorized into four subtypes by Golgau. Type I photodamaged patients have no wrinkles, even with animation. By the second to third decade of life, however, these patients begin to show evidence of photo-damage in the pigmentary system. The appearance of a slightly brownish cast with freckling marks some of the earliest changes, and as patients reach their midthirties to forties, wrinkles begin to appear when the face is in motion. Such patients are categorized as type II, wrinkles in motion. This type of patient has begun to demonstrate the discontinuity of the dermal elastic structure.

At the same time, although lentiginos are usually visible, epidermal atypia is now manifest only by a loss of smoothness to palpation. Female patients usually use makeup foundation to homogenize irregularities in skin color that result from chronic sun exposure. Type III patients have obvious wrinkles at rest, obvious visible keratoses, and also a sallow color to the skin that is the result of accumulated degenerated collagen and elastin in the upper dermis. By the fifth decade, expressive lines have now become permanent wrinkles. Makeup foundation can help to even the skin color; however, it tends to accentuate the appearance of deep rhytides. By the sixth and seventh decade, the wrinkles begin to cover most of the facial skin. These patients represent the extreme cases, in which there is such profound accumulation of solar elastin and collagen in the upper dermis that there is almost no pink tone seen in the skin at all. Many of these patients have already had one or more skin cancers. Makeup is of minimal benefit when applied to such uneven surfaces. These patients have no unlined skin on their face and are classified as type IV, wrinkles only.

Histologic changes associated with chronologically aged skin begin with a thinning of the viable epidermis, with flattening of the dermal-epidermal junction. This is associated with increased amounts of water loss, and studies have concluded that probably there is enhanced diffusion through appendageal shunts or loss of integrity of the stratum corneum with aging." Aside from thinning and flattening, chronologically aged epidermis contain basal cells with increased atypia. This is in direct contrast to photoaged skin, in which the epidermis is generally much thicker than in either young or aged skin.' Flattening of the dermal-epidermal junction appears in both photoaged and chronologically aged skin and should be considered as one of the telltale signs of aging. Because the physiologic consequence of this flattening is the increased susceptibility to shearing forces, the epidermis can be easily torn from the dermis.

The most profound differences between chronologically and photoaged skin can be seen in the dermis. There is atrophy of the dermis with both intrinsic aging and photoaging, but significant thinning in the sun-protected skin does not appear until the eighth decade. Chronologically aged dermis has diminished amounts of eosinophilic material, and the fibroblasts appear shrunken and small. Melanocytes are irregu-

larly dispersed along membranes, and Langerhan cells are markedly reduced.<sup>8</sup> In photoaged skin, the dermis has a wide band of eosinophilic material just beneath the epidermis, characterized by a mass of normal-appearing collagen fibers. This area reveals new collagen formation indicative of decades of repair resulting from ultraviolet (UV) injury. Fibroblasts are numerous, and hyperplastic and mast cells are abundant and degranulated." In short, photoaged skin is chronically inflamed, a condition called heliodermatitis.

Of all the dermal structural elements, elastic fibers most prominently display the sequelae of both chronologic and photodamaged skin. With chronologically aged skin, elastic fibers can be slightly increased in thickness. The most striking histologic feature of severely photo-damaged skin is the presence of massive quantities of thickened bundles of degraded elastic fibers or dermal elastosis. This elastotic material is postulated to result from UV-mediated damage to the extracellular matrix. UV damage to dermal fibroblasts produces abnormal elastin and chronic enzymatic degradation of the extracellular matrix.<sup>6</sup>

In contrast to the hypertrophy of elastin, the amount of mature collagen decreases in photodamaged skin. In infants, collagen is organized in small bundles, primarily parallel to the surface of skin. The entire dermis reveals this pattern, making distinctions between papillary and reticular dermis impossible. In young adults, collagen in the papillary dermis appears as a network of randomly oriented fine fibers and small bundles. The organization of collagen changes from individual, tightly packed bundles to more loosely woven straighter fibers, which translates into some of the age-related biochemical changes in skin.<sup>8</sup> The tensile strength of these looser fibers increases, resulting in skin that is less stretchable. Skin studies suggest that photoaged skin subjected to UV radiation increases the amount of type III collagen while concomitantly decreasing the amount of type I collagen.<sup>3</sup> Collagen can be enzymatically hydrolyzed by cells of the inflammatory infiltrate found in heliodermatitis. The final component of the dermal matrix affected is the ground substance. This substance, composed of proteoglycans, is moderately decreased in age-protected skin; however, it is greatly increased with photoaging.

With advanced age, there is regression and disorganization of capillaries and small



vessels, with a significant reduction in the number of venular cross-sections in the skin surface.<sup>7</sup> This attenuated microvasculature results in thinning hair and the pallor often associated with elderly skin. Furthermore, this results in a reduction in skin surface temperature. Diminished blood flow impacts percutaneous absorption rates and the rate in which substances are cleared from the dermis. The microvasculature also is profoundly altered by chronic sun exposure. Vessel walls are thickened as a result of massive deposition of basement membrane-like substances. Sun-exposed vessels often are surrounded by a distinctive infiltrate of inflammatory cells. Vessels become dilated and tortuous, producing visible telangiectasias.

As water-binding capacity and sebaceous gland activity decrease with age, the skin becomes drier. Changes in the adnexal structures contribute to the visible coarseness of the skin as sebaceous glands hypertrophy, the pores increase in size, and the hair changes from vellus to terminal hair in unwanted areas. Sebaceous gland activity is primarily related to androgen production; sebum production falls steadily in women after menopause but remains fairly stable in men until approximately age 70 years.<sup>1</sup>

The result of these various histologic rearrangements is aged skin that is less stretchable and less resilient. The loss of inherent elasticity results in skin that is more lax, with dependent draping that is prone to wrinkling from gravitational effects. There is also an increase in mechanical fragility and susceptibility to lateral shear stress, combined with significant changes in transepidermal water loss and barrier function, contributing to an increase in dryness and skin irritability.<sup>2</sup>

The question remains, however, whether these changes affect the wound-healing ability of aging skin. Results from dermabrasion healing time in more than 12,000 cases<sup>16</sup> revealed that epithelialization takes approximately twice as long for patients older than the age of 75 years compared with those at 25 years.

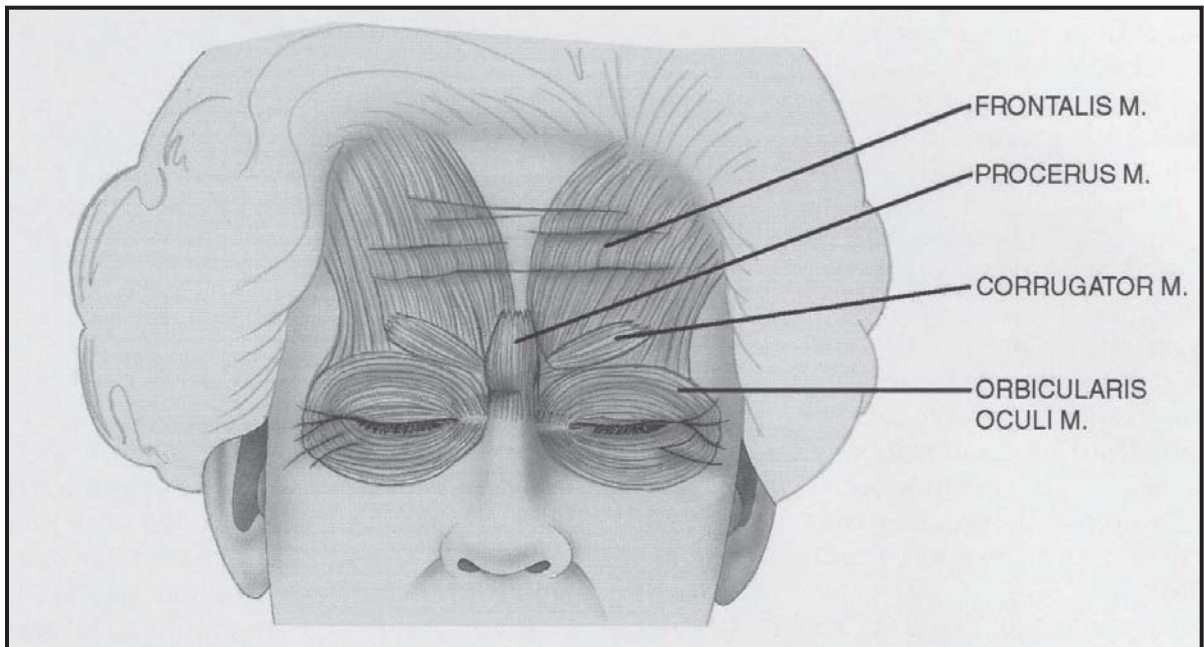
Although differences in age-associated wound healing surely exists, surgical experience clearly demonstrates that even patients over the age of 85 years can effectively repair extensive wounds.<sup>5</sup> Although such changes differ with age, these changes are qualitative. There are neither new events nor the absence of expected ones in the healing process with aging. The ability of the elderly to heal efficiently illustrates not

that their healing process is equal to that of the young, but rather that the healing capacity of younger patients is far in excess of what is needed. The predictably high success rate has tended to obscure substantial differences in wound repair; however, it should never be overlooked that medical complications are more numerous and risky in elderly patients.<sup>15</sup>

## **FACIAL MUSCULATURE AND HYPER-DYNAMIC FACIAL LINES**

The palpebral or orbital component of the orbicularis oculi muscle surrounds the pretarsal and preseptal aspects and functions essentially as the sphincter muscle of the eyelid, responsible for blinking and gentle eye closure.<sup>20</sup> Its direct antagonist is the levator palpebrae muscle. Some of the fibers of the superior-medial orbital component function as depressors of the medial eyebrow, whereas the superior lateral orbital orbicularis acts partly as a depressor of the lateral eyebrow. Forceful contraction of the orbital component induces concentric folds emanating from the lateral canthus, resulting in lateral canthal lines or "crow's feet." The corrugator supercilii lies deep to the frontalis muscle and has its origin on the frontal bone medial to the eyebrows near the superomedial orbital rim. It then passes through the galeal fat pad to insert into the dermis superior to the medial third of the brow. This muscle interdigitates with fibers of the frontalis and orbicularis muscles. The corrugator is a brow adductor and serves to draw the eyebrow inferiorly and medially. As such, it produces vertical glabellar frown lines. The procerus muscle originates on the lower part of the nasal bone and inserts into the skin overlying the nasion. The procerus muscle draws the medial eyebrow inferiorly, which creates transverse wrinkles over the bridge of the nose. The orbicularis, corrugator, and procerus muscles act in concert to close the eyes, creating transverse and oblique glabellar lines (Fig. 3). The main antagonist of the eyebrow depressors is the frontalis muscle, which is responsible for horizontal forehead creases. The frontalis originates from the galea aponeurotica and inserts onto the superciliary ridge, as well as interdigitating with fibers from the procerus, corrugator, and orbicularis oculi muscles.

The zygomaticus major muscle draws the angle of the mouth superiorly, laterally, and



**Figure 3.** Hyperdynamic facial lines, crow's feet, and glabellar furrows reflect underlying facial muscle anatomy.

posteriorly with such actions as laughing, smiling, and chewing. The zygomaticus minor muscle functions as one of the lip elevators, and in combination with the zygomaticus major muscle, contributes to the formation of the melolabial fold. Forceful contraction of the zygomaticus muscles in animation produces synergistic effects in the periorbital region, accentuated by the contraction of the orbital orbicularis muscle, thus enhancing the radially oriented folds at the lateral canthus. The levator labii superioris alaeque nasi muscle is another lip elevator and in some patients can result in obliquely oriented wrinkles along the nasal dorsum and sidewall, with forceful contraction. The orbicularis oris is responsible for forceful lip closure and serves as a sphincter for the mouth. Contraction of this muscle induces folds that radiate perpendicularly to the vermilion border. This muscle is partly an antagonist to the lip elevators. The lip depressors include the orbicularis oris, mentalis depressor anguli, depressor labii, and platysma. Furthermore, chin pad ptosis and mandibular resorption, combined with lip depressor muscle function, contribute to a prominent labiomental crease. The platysma muscle complex, which encompasses the anterolateral aspects of the neck, originates inferiorly from the pectoralis and deltoid fascia. The fibers ascend over the clavicle and extend above the mandible. Some of the fibers insert into the mandible and oral commissure. This layer then ascends above the mandible and is continuous with the

SMAS in the cheek region. In two thirds of all patients, the fibers decussate in the midline. The lateral bands of the platysma muscle facilitate facial expression by lowering the corners of the lip. The contraction, coupled with age-related degenerative changes, causes an inferior pull on the SMAS-platysma complex.

## FOREHEAD AND EYEBROW

The combination of gravity, loss of tissue elasticity, decreased subcutaneous tissue, and progressive bony resorption leads to the inevitable inferior displacement of the brow. With age, the eyebrow position steadily descends from well above the supra-orbital rim to a point at or below it. The excess of sagging skin and a weakened orbital septum allows intraorbital fat to herniate creating palpebral bags. This results in an excess accumulation of eyelid skin, which accentuates dermatochalasis and blunting of the lid creases. The ptotic brow is counteracted by the forehead, resulting in chronic frontalis contraction, contributing to deeper forehead creases. The frontalis muscle courses vertically and inserts into the galea aponeurotica, thus raising the eyebrows and producing transverse forehead furrows. This combination of ptotic brow, sharp brow nasal angle, and forehead and glabellar furrows portrays the tired facial expression characteristic of the aging upper third of the face.

## MIDFACE

The skin represents only the covering for the deeper anatomic elements that project the topography of the aging midface. In the aging midface, these elements have shifted but will always maintain their intimate relationship to one another. The periorbital soft tissue of youth is a shallow and narrow orbit, described as being an unbroken convex line from the lower eyelid to the cheek.<sup>10</sup> With progressive aging, those dimensions become wider and deeper as skeletization of the orbit normally occurs, beginning in the fourth decade. Ptotic cheek fat descends to become the melolabial fold, leaving behind a cheek depression that can be accentuated by buccal fat attenuation. As the orbicularis muscle becomes ptotic with aging, its inferior border becomes clinically apparent. This creates the malar crescent over the zygomatic eminence laterally, resulting medially in creation of the nasojugal fold (Fig. 4). With aging, orbital fat

(whether excessive or normal) under a distended septum orbitale creates an irregular contour and a more obvious bony orbital anatomy. This creates the double convex deformity of the lower eyelid and the appearance of a deeper orbit.

## NOSE

Aging alters the nasal skeleton, cartilaginous framework, and soft tissue covering.<sup>9</sup> As a consequence of aging, the middle portion of the forehead becomes flattened, and on lateral view results in a blunting of the nasofrontal angle, giving the illusion of increased nasal length. Progressive descent of the nasal tip causes attachments between the upper and lower lateral cartilages to weaken, thus lengthening and enlarging the nose. The appearance of a nasal dorsal hump can be deceiving and actually can represent a "pseudo-hump" as a consequence of loss of tip support

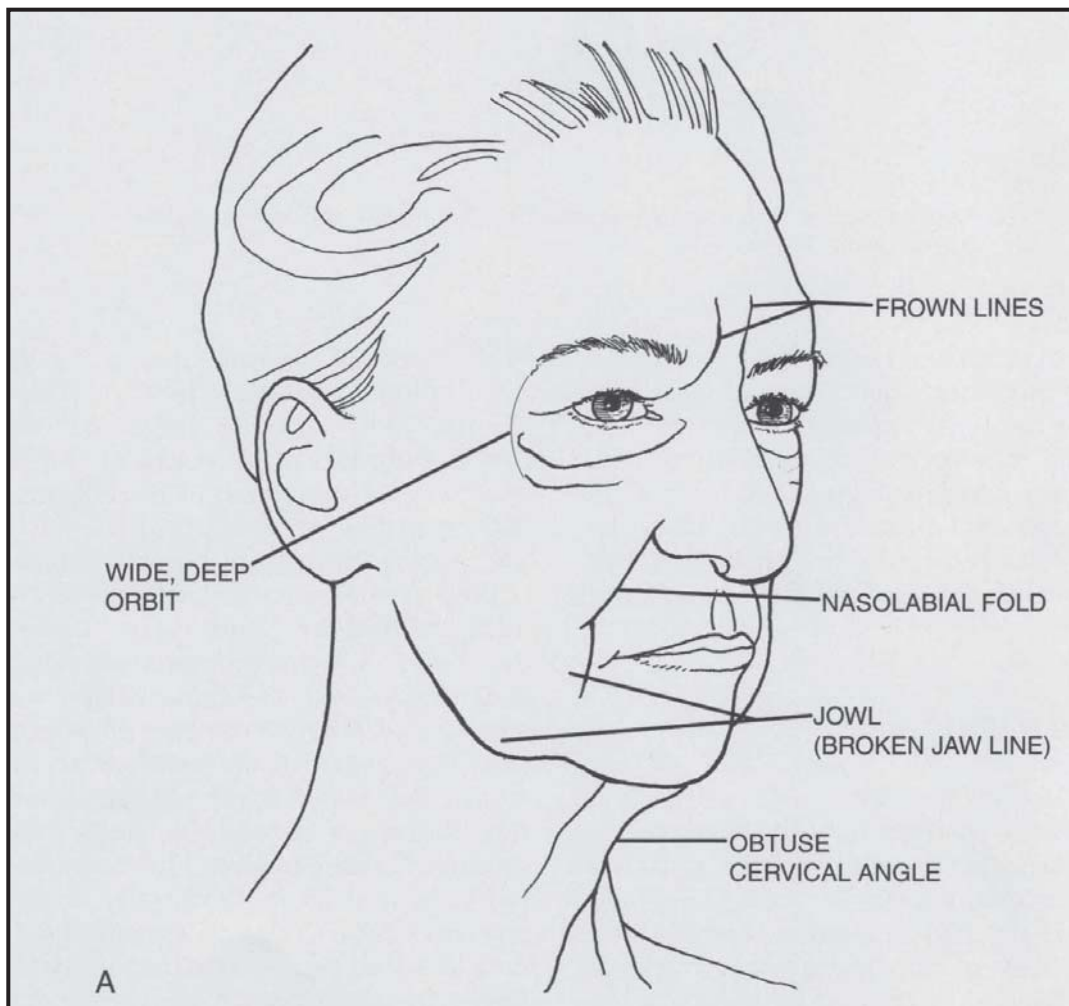


Figure 4. A, Topographic midface changes.

*Illustration continued on following page*



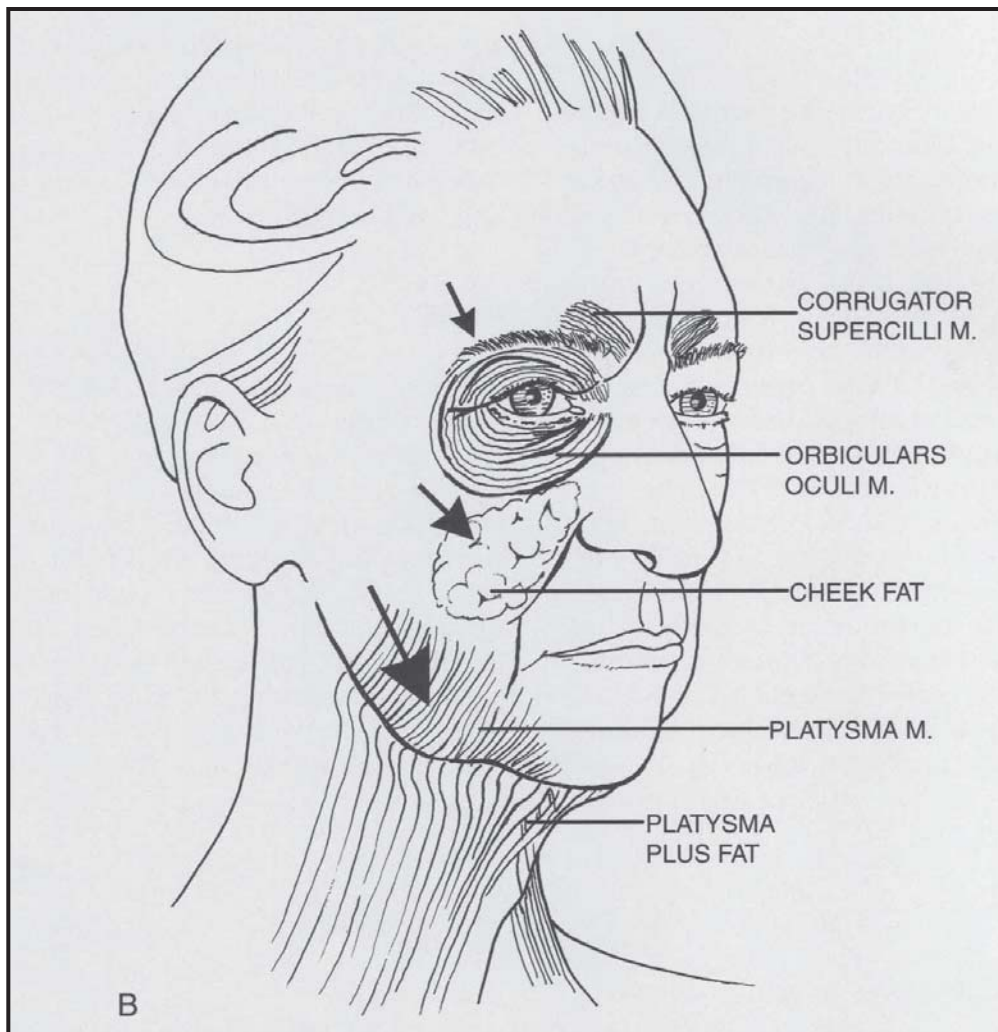


Figure 4 (Continued). B, Underlying muscle and soft tissue descent caused by gravitational changes.

structures. Pyriform remodeling affects the alar base, and in combination with upper maxillary resorption, results in superior repositioning, thus narrowing the nasolabial angle and further accentuating nasal tip ptosis. Chin pad ptosis secondary to bony resorption further contributes to the illusion of increased nasal projection and length.

## JOWL AND NECK

The cervical appearance with aging is a combination of changes in skin, fat distribution, the platysma muscle, and the underlying bony / cartilaginous framework. The downward pull of the platysma creates jowls, with loss of definition of chin and jawline. The jowl, or broken jawline, is created by ptosis of the facial portion of the platysma muscle. The skin of the neck can become lax over the platysma,

developing horizontal rhytides. The vertical fibrous bands on the neck are caused by contraction and prominence of the platysma muscle, partly because of the continual stimulation of having to support the deeper neck and floor of mouth structures. Anterior edges of the platysma separate and lose tone, thus creating the anterior banding, or "turkey neck," deformity. A large submental fat pad is situated deep to the platysma bands, whereas a smaller pad is situated more superficially. Age-related changes of the neck cause the larger submental fat pad to herniate between the two free borders of the muscle, further contributing to anterior banding. Furthermore, the hyoid bone and larynx gradually descend with age, making the larynx appear more prominent. It is the combination of these changes that results in loss or blunting of the cervico-mental angle.



## SUMMARY

The major forces responsible for facial aging include gravity, soft tissue maturation, skeletal remodeling, muscular facial activity, and solar changes. The aging process is a complex and diverse set of elements, each of which leaves a distinctive mark on the aging face. The authors have presented a three-dimensional picture in which each component is intimately connected to the other. Skeleton, muscle, soft tissue, and skin are affected individually by the aging process but act in concert to result in facial senescence.

## References

1. Bartlett SP, Grossman R, Linton A, et al: Age-related changes of the craniofacial skeleton: An anthropomorphic and histologic analysis. *Plast Reconstr Surg* 90:592, 1992
2. Bhawan J, Andersen W, Lee J, et al: Photoaging versus intrinsic aging: A morphologic assessment of facial skin. *J Cutan Pathol* 22:154, 1995
3. Braverman IM: Elastic fiber and microvascular abnormalities in aging skin. *Dermatol Clin* 4:391, 1986
4. Downing DT, Stewart ME, Strauss JS: Changes in sebum secretion and the sebaceous gland. *Dermatol Clin* 4:419, 1986
5. Eaglstein WH: Wound healing and aging. *Dermatol Clin* 4:481, 1986
6. Gilchrest BA: Skin aging and photoaging: An overview. *J Am Acad Dermatol* 21:610, 1989
7. Glogau RG: Chemical peeling and aging skin. *J Geriatr Dermatol* 2:5, 1994
8. Grove GL: Physiologic changes in older skin. *Dermatol Clin* 4:425, 1986
9. Guyuron B: The aging nose. *Dermatol Clin* 15:659, 1997
10. Hamra ST: The role of orbital fat preservation in facial aesthetic surgery. *Clin Plast Surg* 23:17, 1996
11. Kelly RI, Pearse R, Bull RH, et al: The effects of aging on the cutaneous microvasculature. *J Am Acad Dermatol* 33:749, 1995
12. Kligman LH: Photoaging: Manifestations, prevention and treatment. *Dermatol Clin* 4:517, 1986
13. Kligman AM, Zheng P, Lavker RM: The anatomy and pathogenesis of wrinkles. *Br J Dermatol* 113:37, 1985
14. Lavker RM, Zheng P, Dong G: Morphology of aged skin. *Dermatol Clin* 4:379, 1986
15. Mcguitt WF, Loery S, McCabe BF, et al: The risks of major head and neck surgery in the aged population. *Laryngoscope* 87:1378, 1977
16. Orentreich N, Selmanowitz VI: Levels of biological function with aging. *Trans NY Acad Sci* 2:992, 1969
17. Pessa JE, Zadoo VP, Yuan C, et al: Concertina effect and facial aging: Nonlinear aspects of youthfulness and skeletal remodeling and why perhaps infants have jowls. *Plast Reconstr Surg* 103:635, 1999
18. Uitto J: Connective tissue biochemistry of the aging dermis. *Dermatol Clin* 4:433, 1986
19. Yaar M, Gilchrest BA: Cellular and molecular mechanisms of cutaneous aging. *J Dermatol Surg Oncol* 16:915, 1990
20. Zide BM, Jelks GW: In *Surgical anatomy of the orbit*. New York, Raven Press, 1985, pp 13-32

*Address reprint requests to  
Marc S. Zimble, MD  
Department of Otolaryngology-Head and  
Neck Surgery  
Division of Facial Plastic Surgery  
10 Union Square East, Suite 4J  
New York, NY 10003  
e-mail: mzimble@bethisraelny.org*

For more information visit [www.marczimblemd.com](http://www.marczimblemd.com)