

Update on Facial Aging

Rebecca Fitzgerald, MD; Miles H. Graivier, MD; Michael Kane, MD;
Z. Paul Lorenc, MD, FACS; Danny Vleggaar, MD;
Wm. Philip Werschler, MD; and Jeffrey M. Kenkel, MD

Aesthetic Surgery Journal
30(Suppl 1) 11S-24S
© 2010 The American Society for
Aesthetic Plastic Surgery, Inc.
Reprints and permission:
[http://www.sagepub.com/
journalsPermissions.nav](http://www.sagepub.com/journalsPermissions.nav)
DOI: 10.1177/1090820X10378696
www.aestheticsurgeryjournal.com



Abstract

Facial aging was once thought to be the result of the relentless downward pull of gravity on skin and underlying fat. In turn, facial fat was believed to be a contiguous sheet of tissue. However, over the past four decades, a number of investigators have examined more closely the causes of facial aging, leading to a better understanding of age-related changes, and have confirmed and further explored the proposal by Gonzalez-Ulloa and Flores in 1965 that facial aging involves changes in muscle and bone, as well as skin and fat. Further, the recent work of Rohrich and Pessa (and other authors) has demonstrated that facial fat is not a sheet of tissue, but rather is compartmentalized throughout the face. This discovery has allowed the evolution of improved techniques for facial rejuvenation.

Keywords

skin, muscle, bone, fat, gaining, facial rejuvenation

In 1965, Gonzalez-Ulloa and Flores¹ published a landmark article on the “senility of the face,” perhaps the first comprehensive study of the elements of facial aging. These authors observed and described changes in external appearance over time, measuring and documenting facial skin thickness and changes in fat at different ages. They described the process of aging as resulting from the gradual absorption of fat, decreased thickness and elasticity of skin, decreased adherence between the skin and subcutaneous tissue, sagging of the soft tissues, weakening of the orbital muscle and septae, and the progressive decrease in the volume of the craniofacial skeleton. The major advancement that has contributed to our current knowledge of the anatomy of aging is research suggesting that the face does not age as one homogeneous object, but as many dynamic components that are best evaluated, modified, and augmented individually.² It is now recognized that changes that occur with facial aging may involve a complex, multidimensional interaction among the underlying bone, skin, and soft tissue position (as with facial fat descent and/or deflation), selective fat compartment deflation, and alterations in the associated support ligaments and septi.³ Gonzalez-Ulloa and Flores determined that all four structural tissue layers—skin, muscle, fat, and bone—should be considered in aging, concluding with the recommendation that “the phenomena originated by facial senility are multiple and its causes ought to be thoroughly considered for its adequate correction.” The general observations of Gonzalez-Ulloa and Flores have been confirmed

by numerous investigators over the past 45 years. Authors have studied and described the processes and manifestations of aging of the facial skin, from morphology to changes at the cellular level. The more recent literature has provided new insights into age-related changes in the skin, as well as in the underlying structures.

Structural changes in all tissues lead to morphologic changes in the topography, shape, and proportions of the aging face. The variability of facial shape from patient to patient, as well as variability in the pace of aging among patients (and, indeed, even between tissue layers in one individual patient), makes a uniform template for analysis and rejuvenation treatment difficult. However, some common themes can be observed. Stuzin⁴ pointed out that there seems to be a certain age at which there is just enough

Dr. Fitzgerald is a Dermatologist in private practice in Los Angeles, California. Dr. Graivier is a Plastic Surgeon in private practice in Atlanta, Georgia. Dr. Michael Kane is an Attending Plastic Surgeon in private practice in New York, New York. Dr. Lorenc is a Plastic Surgeon in private practice in New York, New York. Dr. Vleggaar is Head of Cosmetic Dermatology in private practice in Geneva, Switzerland. Dr. Werschler is Assistant Professor of Dermatology at the University of Washington, Seattle, Washington. Dr. Kenkel is Professor and Vice Chair of Plastic Surgery, University of Texas Southwestern Medical Center.

Corresponding Author:

Jeffrey M. Kenkel, MD, 1801 Inwood Drive, Dallas, TX 75390-9132, USA. E-mail: jeffrey.kenkel@utsouthwestern.edu



Figure 1. (A) Age 25. The youthful face is full of well-supported facial fat, typically located overlying the malar eminence and along the lateral cheek, overlying the parotid and masseter. This is associated with a concavity or depression overlying the buccal recess just anterior to the masseter. The combination of fullness in the malar region and lateral cheek associated with a concavity overlying the buccal recess accounts for the angular, tapered appearance of the youthful face. (B) Age 55. Thirty years later, the aesthetic effect of the descent of facial fat has become obvious, resulting in a change in facial shape. Typically, faces in middle age are square in their configuration, with little differential between malar highlight and midfacial fat. As facial fat is situated more inferiorly in the face, the face appears visually longer. The aesthetic consequences of a change in facial shape with aging are as important as the depth of the nasolabial fold and facial jowling. Reprinted with permission from Stuzin JM, Baker TJ, Baker TM. Refinements in face lifting: enhanced facial contour using Vicryl mesh incorporated into SMAS fixation. *Plast Reconstr Surg* 2000;105:290-301.

skeletal support for the overlying soft tissues (Figure 1). Research published by Pessa et al⁵ over a decade ago illustrated that this opportune time may be a point that we grow into from infancy and away from with age (Figure 2). The central role of volume loss and deflation in the aging face, rather than ptosis, was eloquently illustrated by Lambros⁶ in a longitudinal photographic analysis of more than 100 patients spanning an average period of 25 years. Recognizing where volume has been lost (or sometimes lacking in the first place) in each patient greatly enhances our ability to address it with site-specific corrections that result in optimal, natural-looking results.

FACTORS IN FACIAL AGING

Classic articles by Yaar and Gilchrest,⁷ El Domyati et al,⁸ and Rabe et al,⁹ among others, have described in detail the

histopathologic changes that result from both intrinsic and extrinsic aging. It has been demonstrated that intrinsic and extrinsic aging occur in all tissues of the body.

Intrinsic aging involves physiologic and histologic changes resulting from cellular apoptosis and other genetically determined processes. In the skin, examples of intrinsic aging include a number of changes: thinning epidermal tissue; a decrease in Langerhans cells and melanocytes; variability in the size and shape of epidermal cells; the appearance of atypical nuclei; a reduced number of fibroblasts, mast cells, and blood vessels; shortening of capillary loops; and abnormal morphology of nerve endings.⁷⁻⁹

Extrinsic aging results from long-term exposure to environmental insults, including dehydration, inadequate nutrition, temperature extremes, traumatic injuries, environmental toxins (such as cigarette smoke), and ultraviolet (UV) radiation.⁹ Photodamage, perhaps the most

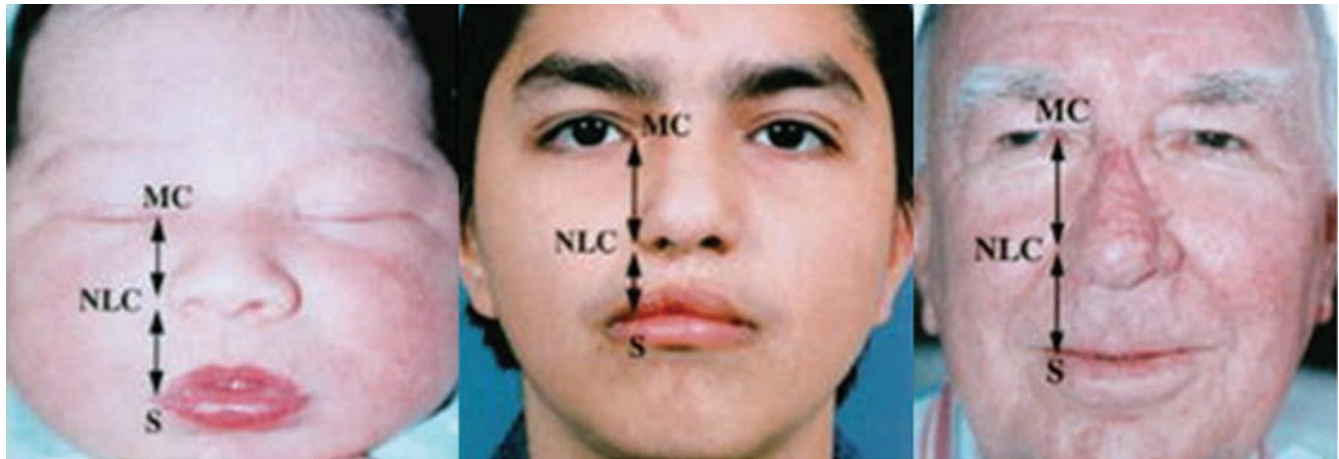


Figure 2. (A) On a frontal view, the ratio of medial canthus (MC) to nasolabial crease (NLC) and the NLC to the lips (S, stomion) in the infant is approximately 1:1. This ratio is attributable to lack of development in the maxilla from the pyriform to the orbital rim. (B) From infancy to youth, the maxilla grows at a disproportionately fast rate (differential growth), which results in the ratio becoming closer to 1.5:1 at the time of youth. (C) After this point, upward remodeling of pyriform, coupled with continued growth of the lower maxilla, again causes this ratio to revert back toward 1:1 in an older individual. It is of interest that, if the soft tissue contours of the 82-year-old man (C) were restored to those of a youthful person, the proportions would still be those of an older (or infant) face. The appearance of youth depends on contours and proportions as well as soft tissue signs of aging. Reprinted with permission from Pessa JE, Zadoo VP, Yuan C, et al. Concertina effect and facial aging: nonlinear aspects of youthfulness and skeletal remodeling, and why, perhaps, infants have jowls. *Plast Reconstr Surg* 1999;103:635-644.

common cause of extrinsic aging in the face, causes changes that include a thickened epidermis, a flattened dermoepidermal junction, and an increase in hyperplastic fibroblasts and inflammatory infiltrates.⁷⁻⁹

A recent study of monozygotic twins¹⁰ provided statistical evidence regarding some of the extrinsic factors that are known to contribute to facial aging. (The investigators chose monozygotic twins because of the inherent control for genetic influences.) Ten facial features were analyzed: overall perceived age for each twin, skin youthfulness, coarse and fine rhytides, soft tissue volume, hair quantity, hyperpigmentation, periborbital aging, brow ptosis, perioral changes, and malar descent. In this study, there were statistically-significant associations between facial aging and 10 factors. These were sun exposure, duration of cigarette smoking, body mass index, duration of hormone replacement, marital status, alcohol consumption, and a history of the following: skin cancer, outdoor activities and lack of sunscreen use, radiation therapy, and chemotherapy.

Other studies have been published further confirming the observation that the clinical signs of facial aging are associated with changes in all structural layers (ie, skin, fat, muscle, and bone). The following sections on these structural layers briefly review the most recent literature in which the results have a bearing on the understanding of the optimum use of injectable shaping agents. A short statement describing the implications of the studies concludes each of these sections.

SKIN

Skin appearance is a primary indicator of age. During the past decade, substantial progress has been made toward understanding underlying mechanisms of human skin aging. A major feature of aged skin is fragmentation of the dermal collagen matrix. This fragmentation results from actions of specific enzymes (matrix metalloproteinases) and can be observed in both intrinsic and extrinsic aging. Loss of this extracellular collagen is responsible for loss of structural integrity and subsequent impairment of fibroblast function¹¹ because fibroblasts that produce and organize the collagen matrix cannot attach to fragmented collagen. Loss of attachment prevents fibroblasts from receiving mechanical information from their support and they subsequently collapse. Although stretching is critical for normal, balanced production of collagen and collagen-degrading enzymes, in aged skin, the collapsed fibroblasts produce low levels of these. This imbalance advances the aging process in a self-perpetuating, never-ending deleterious cycle (Figure 3).

Because attachment of fibroblasts to new, undamaged collagen allows stretching, it in turn balances collagen production and degradation, thereby slowing the aging process. Therefore, treatments that stimulate production of new, nonfragmented collagen should provide substantial improvement to the appearance and health of aged skin. Skin improvement has been described with topicals such as retinoic acid, as well as with both ablative and nonablative laser treatments.

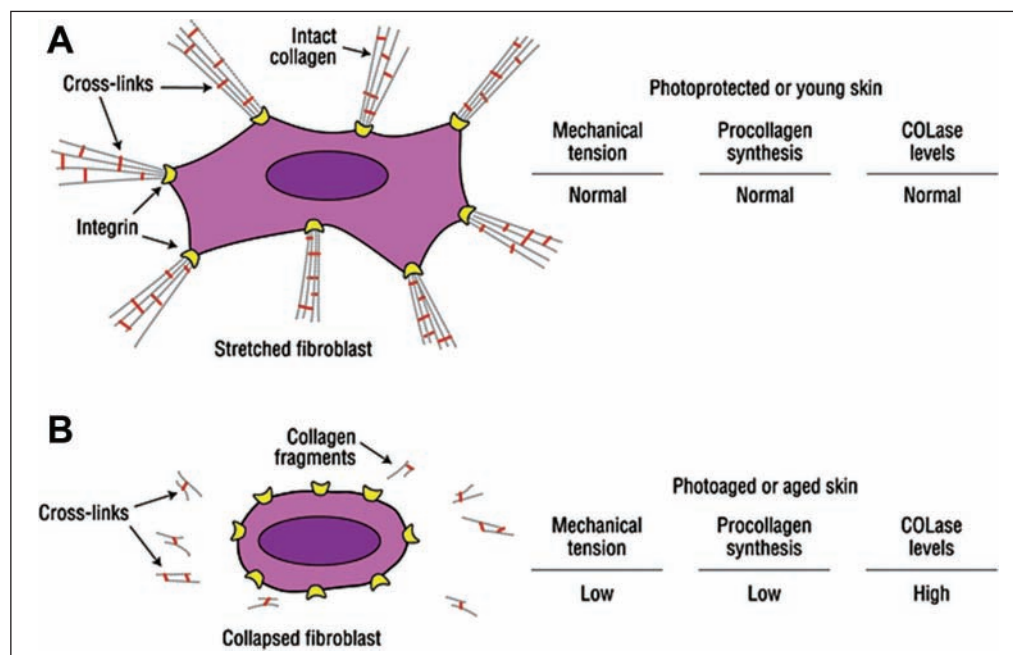


Figure 3. Fragmentation of collagen fibrils within the dermis of aged or photoaged skin causes the collapse of fibroblasts, which leads to low production of procollagen and high production of collagenase. Reprinted with permission from Fisher GJ, Varani V, Voorhees JJ. Looking older: fibroblast collapse and therapeutic implications. *Arch Dermatol* 2008;144:666-672. Copyright © 2008 American Medical Association. All rights reserved.

In terms of clinical implications, we must remember that both intrinsic and extrinsic aging affect the ability of the outer skin envelope to adjust to underlying volume loss. A very elastotic outer skin envelope is unlikely to “lift” significantly with fillers alone and may require treatment with multiple modalities such as surgical lifting, lasers, and deep chemical peels. Adequate “filling” of a face with very elastotic skin is challenging and may require an overwhelming amount of treatment time and product. Recently, new collagen production attributed to a stretching effect of intradermal hyaluronic acid was described.¹² It is interesting to speculate that because collagen stimulation may produce both direct (through fibroplasia) and indirect (through increased extracellular matrix and a stretching effect) stimulation of fibroblasts, treatments with these agents could both replace collagen and slow its loss.

FAT

The youthful face has an ample and evenly distributed amount of volume, which displays a smooth transition from one area to another and confers a well-rounded three-dimensional topography delineated by a series of arcs and convexities.¹³ Viewed frontally, the primary arc of the jaw line, convexities of the temples, and the smaller secondary arcs of the lips are evident.¹³ In profile, the lateral cheek projection (the ogee curve) extending as an unbroken convex line from the lower eyelid to the cheek, the arc of the jaw line, and the arc of the forehead are the most definitive features of youth.¹⁴ A cadaveric dissection study by Raskin

and LaTrenta¹⁵ in 2007 sought to document the subcutaneous fat mass both above and below the superficial musculoaponeurotic system (SMAS) and offered an interesting illustration of these contours. The face and neck were arbitrarily divided into subunits according to the aesthetic facial and neck subunit principle of Gonzales-Ulloa and Flores¹ (Figure 4). After a three-layer dissection in 10 fresh hemi cadavers, the authors found that 80% of total subcutaneous fat mass existed in the face and only 20% in the neck. In the face, 57% of the fat mass was found above the SMAS, with 43% below the SMAS.

Also in 2007, the first in a series of groundbreaking studies from Rohrich and Pessa¹⁶ demonstrated in the cadaver lab that facial fat exists as multiple well-delineated, independent compartments that have specific anatomic relationships to one another. The authors also noted that many of the retaining ligaments that support facial soft tissue originate within the septal barriers between these compartments.¹⁷ In the first of these experiments, methylene blue dye (chosen for its diffusion properties) was injected into adipose tissue in various regions of the face. The dye was noted to flow in distinctly partitioned patterns, departing from the traditional assumption that facial fat is a homogeneous confluent mass. This initial discovery has been followed by a large number of detailed anatomic cadaver studies defining these fat compartments and their relationships to one another.¹⁸⁻²¹ These separate fat compartments exist in both superficial and deep fat. Some superficial compartments overlap and the deep compartments are revealed only when the superficial compartments are stripped away. There is, of course, much still to learn, but several of the named superficial and deep

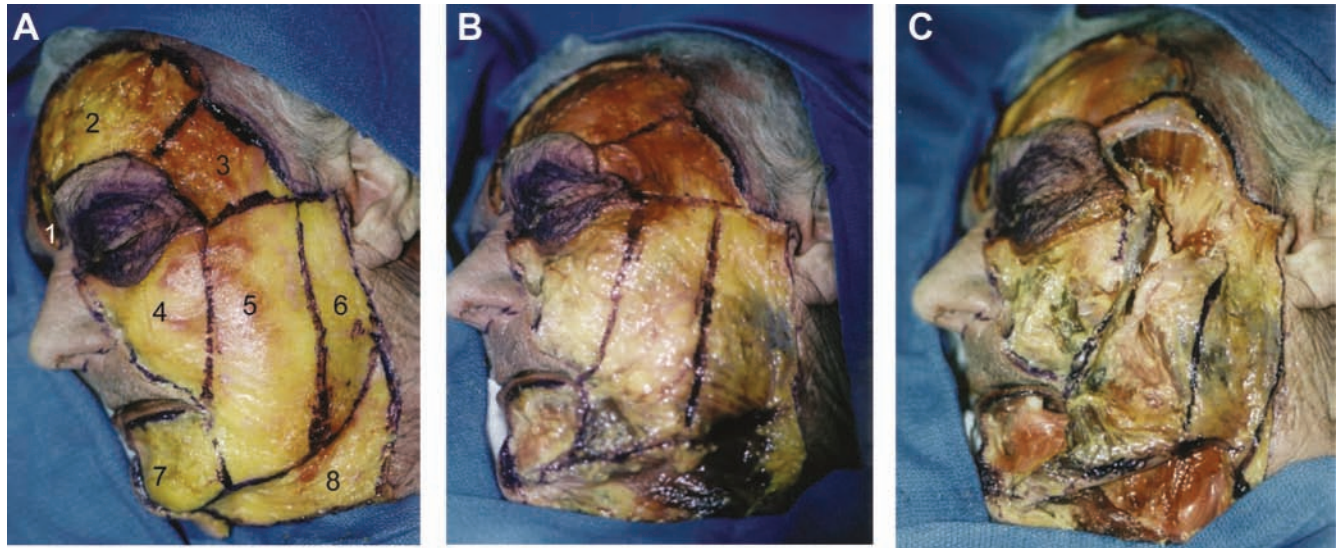


Figure 4. (A) Arbitrarily divided anatomic units of the face after the dermis has been dissected off the cadaver's face and neck include the following: (1) glabella, (2) forehead, (3) temporal, (4) anterior upper cheek, (5) middle cheek, (6) posterolateral cheek, (7) mental, and (8) anterior neck. (B) The skin, superficial fat, and SMAS have been dissected off the cadaver's face and neck, and the anatomic subunits have been redrawn on the discontinuous deep layer of fat. (C) The skin, SMAS, and superficial and deep layers of fat, including the fat pad of Bichat, have been dissected off the cadaver's face and neck, demonstrating the near-complete loss of contour in faces bereft of fat and SMAS. Reprinted with permission. This figure was published in *Atlas Aesthetic Face and Neck Surgery*, Philadelphia: Saunders; 2004. LaTrenta GS, p.2-67, Copyright Elsevier, 2004.

compartments have been elegantly described in the articles referenced above.

There is good clinical evidence that individual fat compartments age independently. This may have a cascade effect on adjacent areas, which has enormous influence on the techniques we select for facial filling. A working hypothesis of facial aging involves the concept that fat loss and/or ptosis in deep compartments leads to changes in shape, contour, and anterior projection. Folds, in contrast, occur at transition points between thick and thinner superficial fat compartments; these can be seen in the nasolabial fold, the labiomental fold, the submental crease, and the preauricular fold.¹⁸ This has led to the concept of “pseudoptosis”—namely, that loss of volume in one area may lead to the development of folds in a neighboring area.¹⁹ This is well-illustrated by the improvement demonstrated in the nasolabial fold and under-eye “v-shaped deformity” when the deep medial cheek fat pad is refilled with saline from a single injection point (Figure 5).¹⁹

Another example of how these anatomical observations further the goal of site-specific augmentation in facial rejuvenation is demonstrated in the lip region. The discovery of fat compartments in the cutaneous portion of the lips deep to the orbicularis oris muscle in an aged cadaver with full lips raised speculation that filling of this area (rather than the vermillion border) might restore a natural, youthful fullness and convexity to the lip (Figure 6).²⁰ This research has subsequently guided an evolution in the clinical placement of fillers in the labial area.

Around the eyes, researchers have found that suborbicularis oculi fat is composed of two distinct anatomical compartments: the medial suborbicularis oculi fat, which lies between the medial limbus and the lateral canthus, and lateral sub-orbicularis oculi fat, which extends from the lateral canthus to the lateral orbital thickening. The deep medial cheek fat is the most medial of the periorbital deep fat compartments (Figure 7).²¹ Because periorbital rejuvenation has increasingly relied on augmentation with fillers, knowledge of the exact anatomy of the suborbicularis oculi fat is important to accurately place filler material. Augmenting each area has a different effect and enables the clinician to tailor his or her treatment based on the individual's particular morphology.²¹ Pessa^{21,22} noted, for example, that some individuals develop a nasojugal crease during their early 20s. Augmentation of the medial or lateral suborbicularis oculi fat is unnecessary in these patients, and filler injected along the medial orbital rim alone, into the superior deep cheek fat, will improve this area.

This anatomical research, combined with Lambros's theory of age-related deflation,⁶ enables the clinician to approach facial rejuvenation in a site-specific manner. There is good clinical evidence that not all fat compartments behave identically as a patient ages and that a site-specific approach is valid, making universal treatment of the nasolabial folds and marionette lines in all patients a thing of the past. The relevance of new understanding of facial fat anatomy to facial rejuvenation techniques in

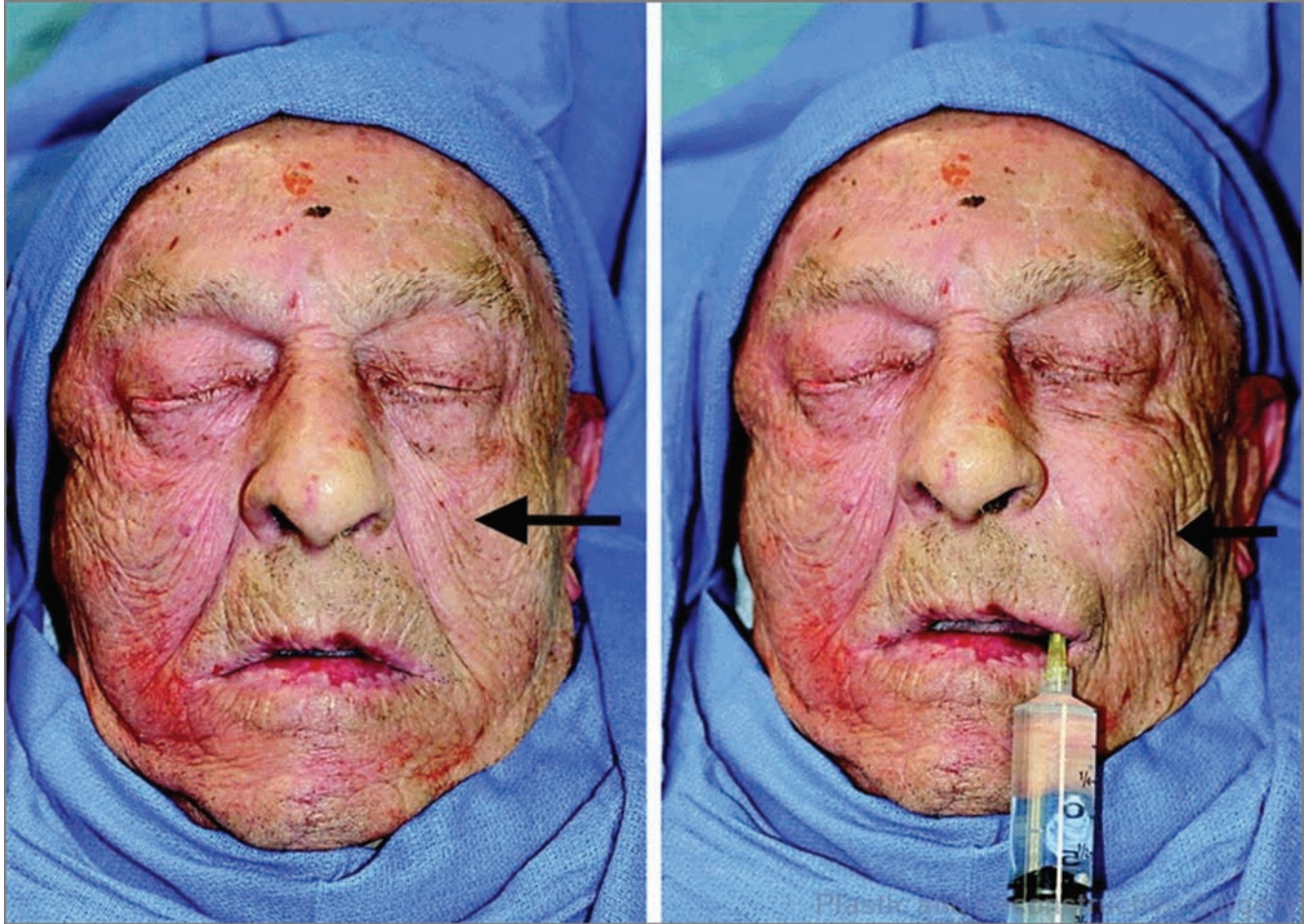

Figure 5. (A) Photograph of a deflated midface (arrow). (B) Saline injected specifically into the deep medial cheek fat restores anterior projection, diminishes the nasolabial fold, effaces the nasojugal trough, and improves the malar region. An interesting finding is the fact that the cheek has a natural appearance because the deep medial fat boundaries determine the anatomical position of the cheek. Reprinted with permission from Rohrich RJ, Pessa JE, Ristow B. The youthful cheek and the deep medial fat compartment. *Plast Reconstr Surg* 2008;121:2107-2112.

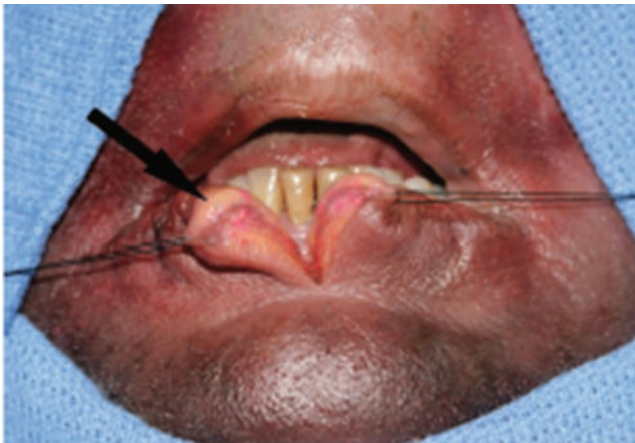

Figure 6. Vertical sectioning of the lower lip shows deep submuscular fat. Of particular note, this specimen's lower lip showed anterior projection and eversion similar to that seen in a much younger individual. The clinical impression from this research is that the volume of deep lip fat contributes significantly to the appearance of the youthful lip. Reprinted with permission from Rohrich RJ, Pessa JE. The anatomy and clinical implications of perioral submuscular fat. *Plast Reconstr Surg* 2009;124:266-271.

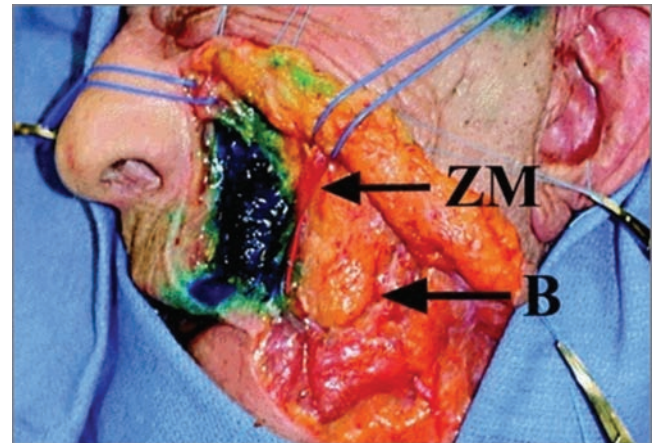


Figure 7. The deep medial cheek fat is stained with methylene blue. This fat lies beneath the superficial subcutaneous fat compartments. The zygomaticus major (ZM) and buccal fat (B) represent the lateral boundaries. Reprinted with permission from Rohrich RJ, Pessa JE, Ristow B. The youthful cheek and the deep medial fat compartment. *Plast Reconstr Surg* 2008;121:2107-2112.

general (and facial fillers in particular) is enormous. Sandoval et al² recently published a guide suggesting that these compartments serve as a “GPS” for the injection of facial fillers, noting that future studies at their institution will focus on the effect of fillers on the fat compartments and the visual changes created by their augmentation. It also suggests that some regions of the face may improve with what might be called “indirect treatment”—that is, treatment of one area can beneficially affect one or more adjacent areas.

MUSCLE

As mentioned previously, subcutaneous fat is positioned both above and below the facial mimetic muscles. At approximately the same time Rohrich and Pessa were conducting their cadaveric research, Le Louarn and colleagues²³ were working independently to define the nature and role of facial structures, resulting in the development of their “facial recurve concept.” Le Louarn’s group performed magnetic resonance imaging (MRI) studies on subjects of different ages and documented the differences in facial mimetic muscle contours, as well as in the superficial and deep fat pads overlying and underlying these muscles. These authors suggested that the shape and action of facial muscles are determined by the position of the underlying fat and that, over time, repeated contraction of the facial mimetic muscles contributes to changes in this fat distribution. They speculated that this mechanism leads to a loss of the youthful curvilinear contour and an increase in the resting tone of the muscles, thus changing the shape, morphology, and three-dimensional topography of the face (Figure 8). This is in contrast to the traditional concept that facial muscle laxity and weakness cause a downward displacement of soft tissue. Logically, however, we can question whether, if the commonly held belief were true, facial muscle paralysis would actually cause softening of the corrugator, nasolabial, periorbital, and labiomandibular creases and an improvement in senescent appearance. The authors also note that although this concept of increased muscle resting tone with age may appear counterintuitive at first, it would account for the well-appreciated clinical effects of botulinum toxin injection. They offer corresponding hypothesis that the crow’s feet wrinkles that develop with age can be seen as deriving from the persistence of orbicularis oculi contraction or a degree of increased resting tone in the face. As described earlier, Rohrich et al¹⁹ believe that the deep fat in some areas, such as the deep medial cheek fat in the midface, accounts for the anterior projection of the face seen in youth. The implication for treatment is that filler placed under the mimetic muscles may have a positive effect through more than one mechanism.

An additional (but unrelated) article on muscular structures is worth comment in this section. Levy²⁴ published his experience in 130 patients with a new technique using botulinum toxin A (VistabelH; Allergan, Irvine, California), up to 20 units per side, to drape the skin of the jawline contour and provide the visual effect of a “mini lift.” He reported that patient satisfaction was extremely high, and the specificity of his dosing

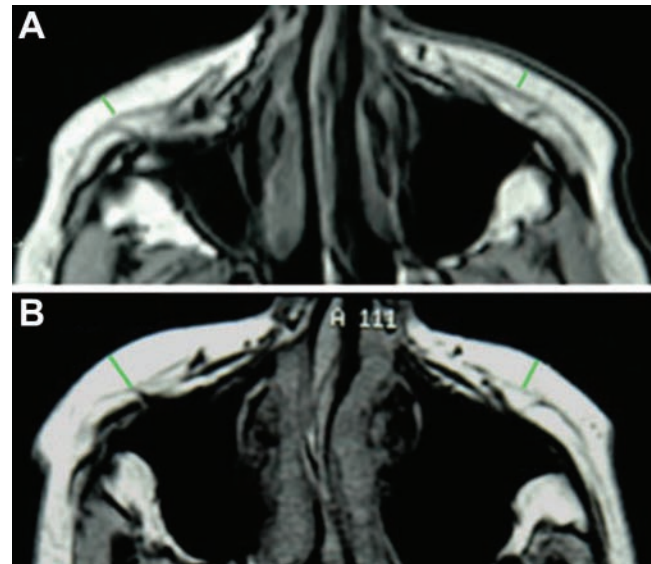


Figure 8. Le Louarn suggested that the shape and action of facial muscles is determined by the position of the underlying fat and that, over time, repeated contraction of the facial mimetic muscles contribute to changes in this fat distribution. With MRI studies, they documented a loss of the youthful curvilinear contour (A) and an increase in the resting tone of the muscles, thus changing the shape, morphology, and three-dimensional topography of the face as it ages (B). Reprinted with permission from Le Louarn CL, Buthiau D, Buis J. Structural aging: the facial recurve concept. *Aesthetic Plast Surg.* 2007;31:213-218.

and technique has led to a low incidence of adverse effects. He feels this so-called Nefertiti lift is a minimally invasive, effective, and acceptable alternative for patients seeking an effective way to delay surgery. Disappearance of the mandibular border with a forceful downward pull on the platysma at the corners of the mouth indicates the potential for successful treatment in this area. It is interesting to speculate whether the success of this technique is related to Rohrich and Pessa’s recent description of the osseous attachments of the platysma along the mandibular septum.

BONE

A review of the forensic science literature by Albert and colleagues²⁶ concerning the adult skull and face supported the contention that there are certain age-related bony and soft tissue changes that occur, causing (as the authors state) changes “in the shape, size, and configuration of individuals over the course of the adult lifespan.” Doual et al²⁷ reported that the most extensive changes in the appearance of the head, face, and neck attributable to underlying, age-related skeletal changes occur at about 50 years of age in both men and women.

Craniofacial bony remodeling is increasingly recognized as an important contributor to the facial aging process and multiple studies have demonstrated statistically significant craniofacial skeletal changes with age. Sharabi et al²⁸ recently reviewed and assembled this information in a

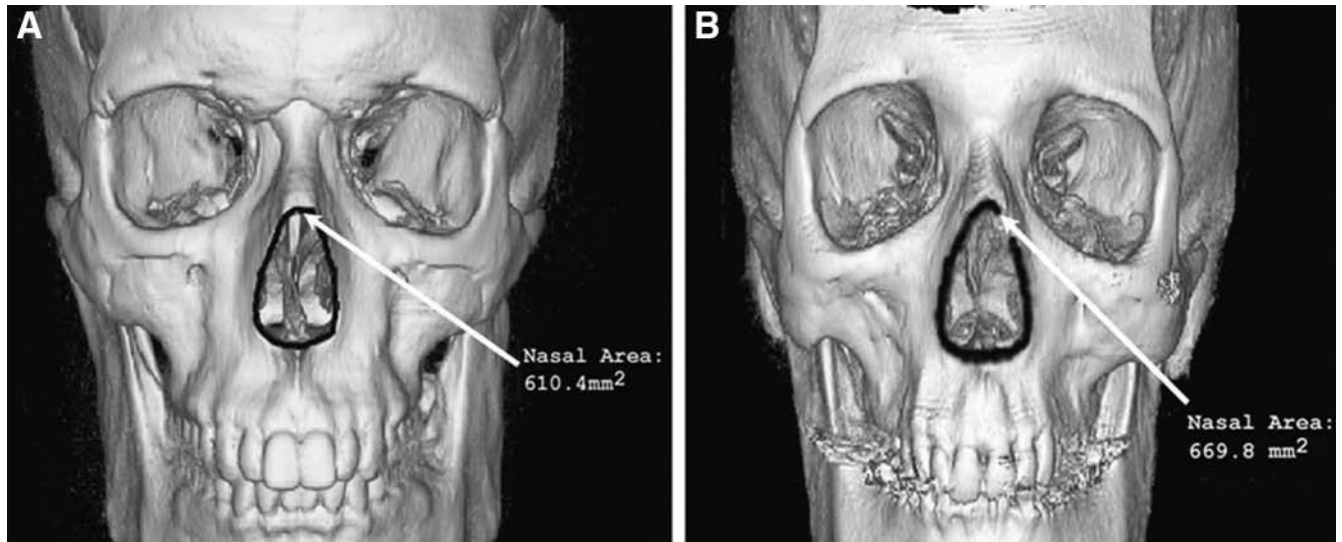


Figure 9. Sample computed tomographic scans of, A, a male subject in the young age group and, B, a male subject in the old age group, with mean pyriform aperture area applied. Reprinted with permission from Shaw RB Jr, Kahn DM. Aging of the midface bony elements: A three-dimensional computed tomographic study. *Plast Reconstr Surg.* 2007;119:675–681.

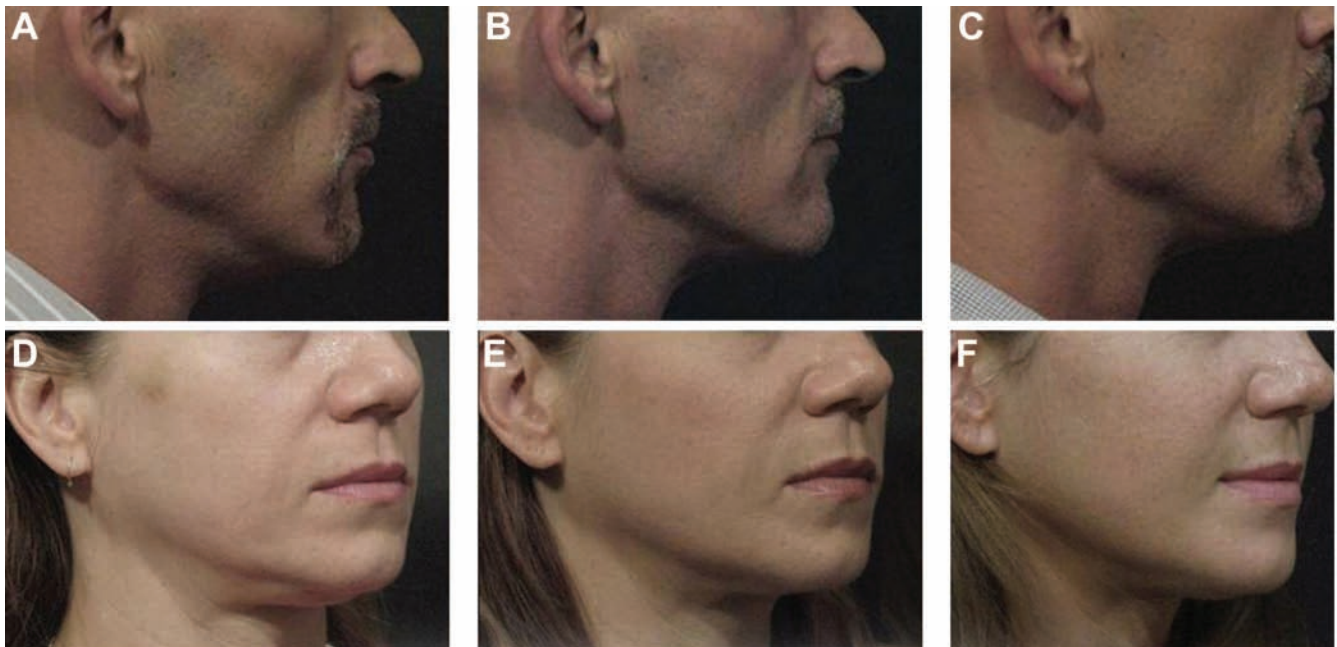

Figure 10. A, This 48-year-old man presented for treatment of facial lipoatrophy. This patient's loss of facial fat makes it easier to identify the convexities due to muscle and bone such as the zygomatic arch, the masseter, and the perioral muscular prominence. Note that the perioral muscular prominence is made visible by the loss of facial fat both above and below it. Note also that it is found in the same location that one would find a "marionette" fold. It is obvious that this will be improved not by "filling the fold," but by replacing the missing volume superior and inferior to the prominence. B, Midtreatment. He was treated with three vials of PLLA per session over three sessions spaced six weeks apart (for a total of nine vials). C, Three months after his last treatment. D, This 42-year-old woman presented for treatment of aging. E, Midtreatment. She was injected with two vials of PLLA per session over three sessions spaced four weeks apart (for a total of six vials). F, One year after her last treatment. She was treated in the same areas as the patient in parts A-C (temporal and lateral cheek fat pad, deep medial cheek fat pad, medial and middle cheek as well as submental fat pad), resulting in a nice improvement even in areas not treated directly, such as the tear trough, nasolabial and marionette folds, and the along the jawline. By virtue of what their anatomy and "empty" fat compartments reveal, severely lipoatrophic faces like these, may offer a "road map" of how to effectively treat younger faces or plumper faces with similar but less obvious changes. Perhaps this anatomy is obscured in fuller faces by the folds it creates (the concept of "pseudoptosis"). Photos courtesy of Rebecca Fitzgerald, MD. Reprinted with permission from Jones DH. *Injectable Fillers: Principles and Practice.* Wiley-Blackwell, London 2010.

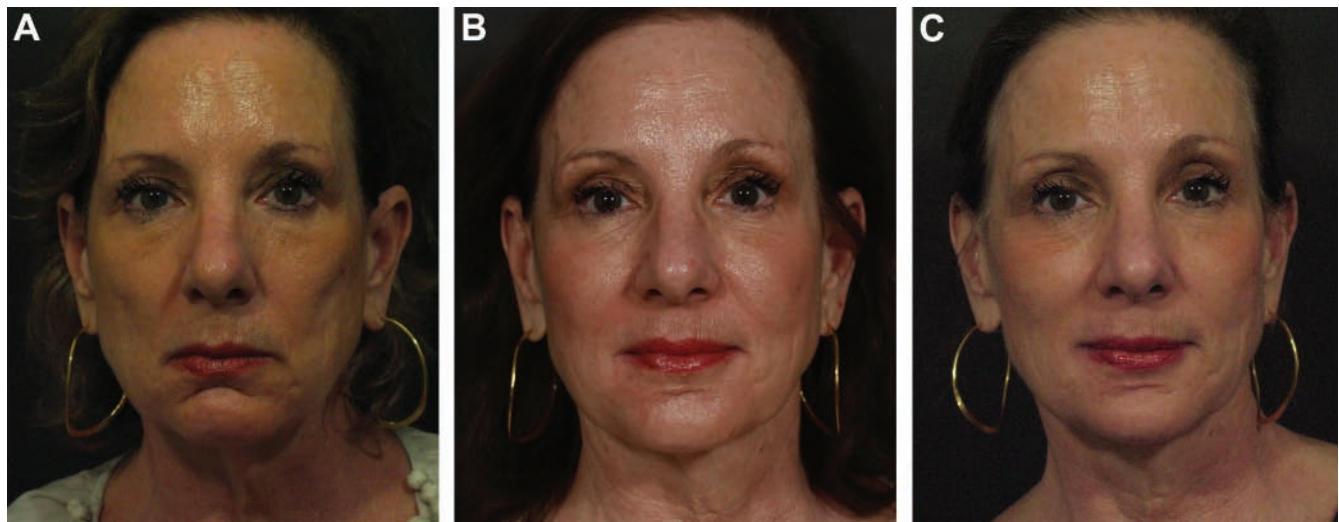


Figure 11. A, This 58-year-old woman presented for treatment of nasolabial folds. B, Midtreatment. C, Four months after the final treatment. This patient was injected two vials of PLLA per session over three sessions (for a total of six vials total) in the area of the temporal and lateral cheek compartment, the middle cheek compartment, and supraperiosteally along the maxilla and mandible. Note that treatment of the deep medial cheek fat pad improved the contour of the cheek, as well as indirectly softening the nasolabial fold and tear trough. Note also the change in facial shape brought about by this treatment. Photos courtesy of Rebecca Fitzgerald, MD. Reprinted with permission from Jones DH. *Injectable Fillers: Principles and Practice*. Wiley-Blackwell, London 2010.

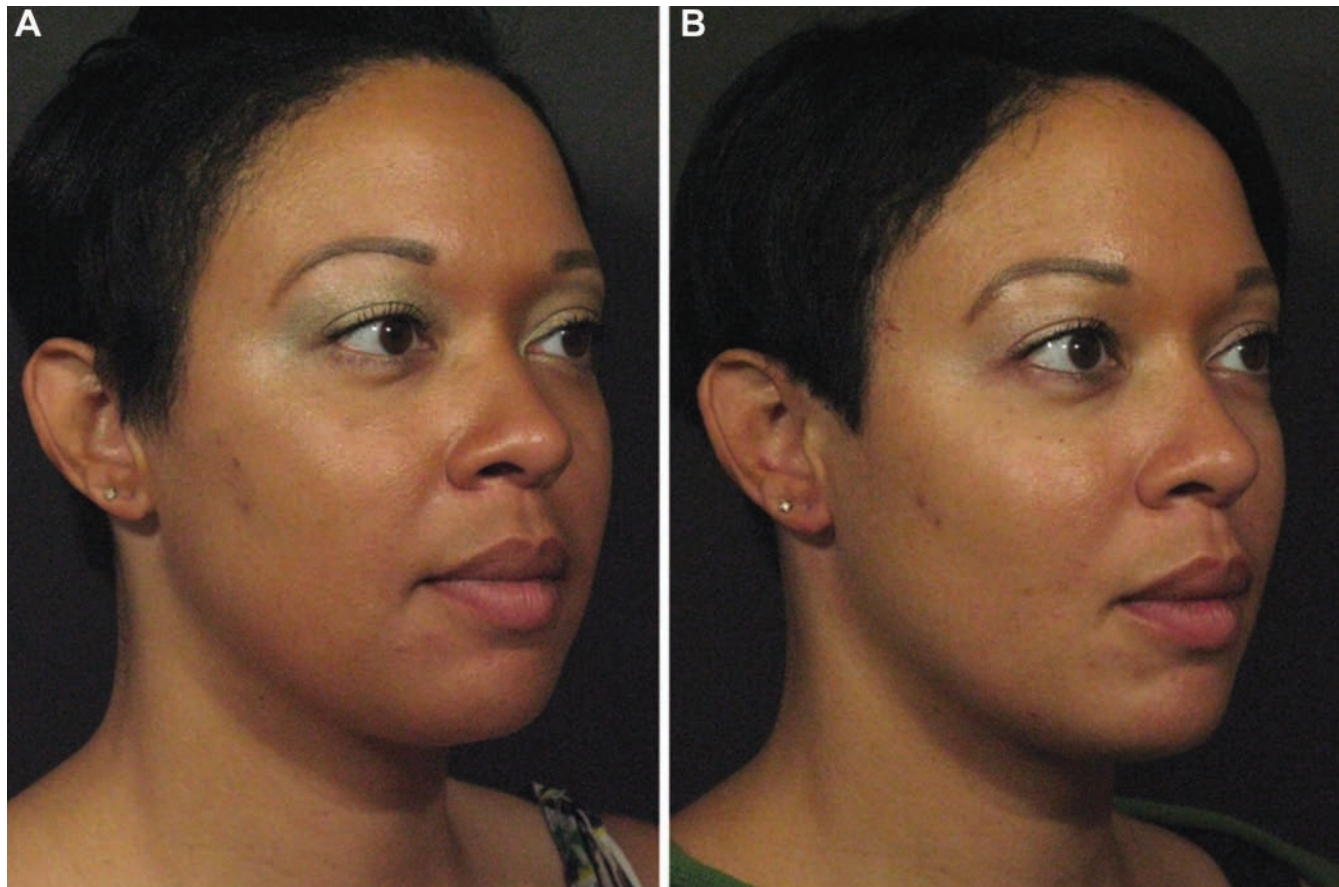

Figure 12. (A) This 35-year-old female presented for nasolabial fold treatment. (B) One month after treatment with one vial of poly-L-lactic acid (PLLA) injected in the area of the temporal and lateral cheek fat compartment, as well as the deep medial cheek fat pad. Note the improvement in anterior projection and contour of her cheek. Note also the subtle change in facial shape brought about by this treatment. Photos courtesy of Rebecca Fitzgerald, MD. Reprinted with permission from Jones DH. *Injectable Fillers: Principles and Practice*. Wiley-Blackwell, London 2010.

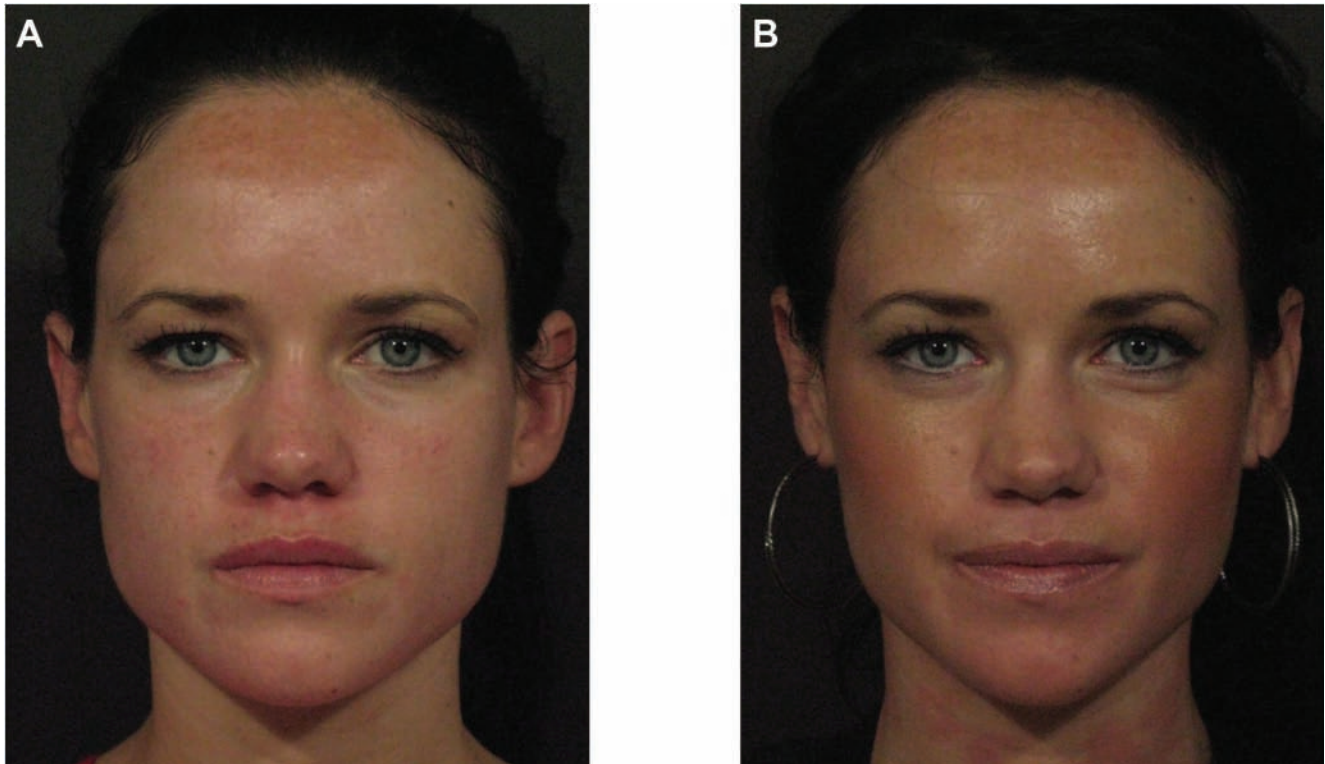

Figure 13. (A) This 28-year-old woman presented for subtle feminization of her facial shape. (B) Four months posttreatment. She was injected with one vial of poly-L-lactic acid (PLLA) to fill out her temples and cheeks, as well as 20 units of botulinum toxin type A in each masseter to provide a more oval shape to her face. Photos courtesy of Rebecca Fitzgerald, MD. Reprinted with permission from Jones DH. *Injectable Fillers: Principles and Practice*. Wiley-Blackwell, London 2010.

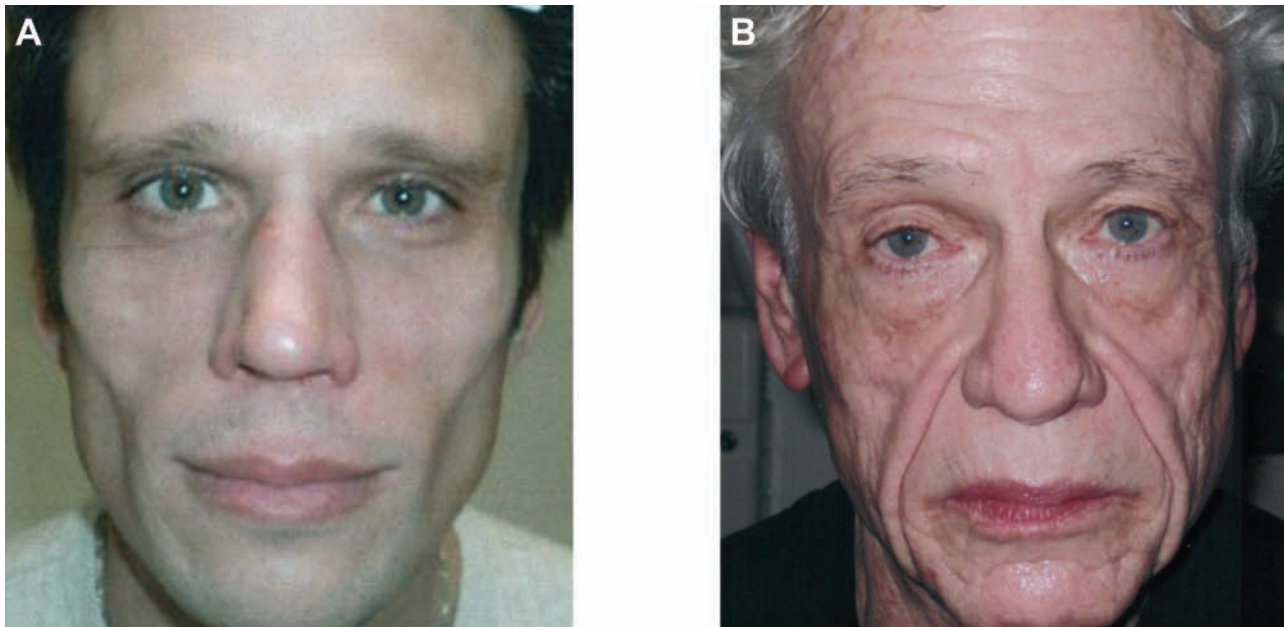


Figure 14. In these photographs of one 40-year-old man (A) and one 76-year-old man (B) with advanced lipoatrophy, the reader can easily observe the shape and proportions of the craniofacial skeleton under the skin. The orbital rim changes can be easily noted, as well as the change in the position of the nose and in the perioral ratios seen with aging. Photos courtesy of Rebecca Fitzgerald, MD. Reprinted with permission from Jones DH. *Injectable Fillers: Principles and Practice*. Wiley-Blackwell, London 2010.

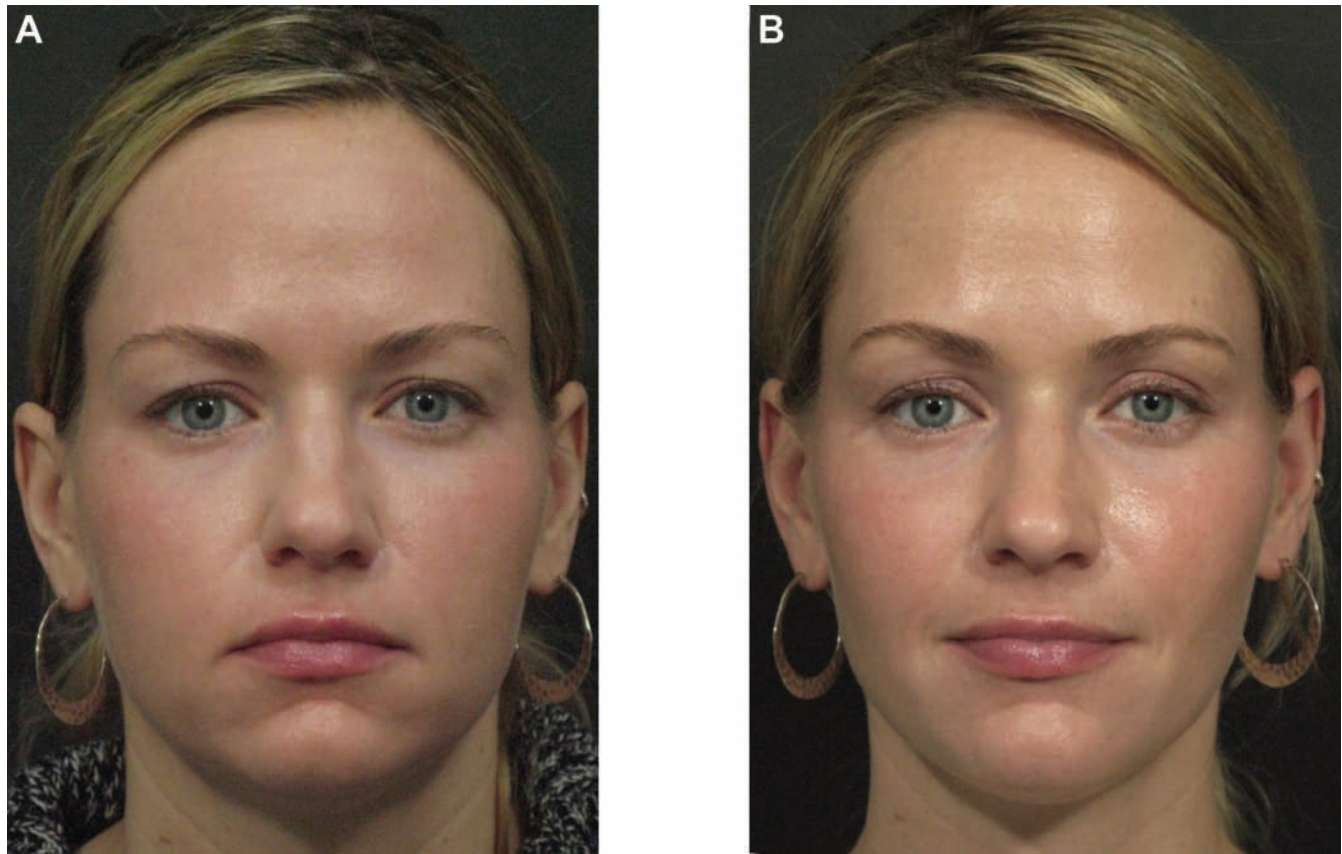

Figure 15. (A) This 30-year-old, “baby-faced” woman presented with poor craniofacial support. (B) Four months after her final treatment. She was injected with two vials of poly-L-lactic acid (PLLA) per session over two sessions spaced two months apart (for a total of four vials). The product was placed along her superior lateral orbital rim, lateral zygoma, anterior maxilla, canine fossa, and along the mandible in roughly the same area that would be treated with a solid implant. The patient received no other treatment. Note the brow elevation and change in the perioral area and facial shape with these treatments. Photos courtesy of Rebecca Fitzgerald, MD. Reprinted with permission from Jones DH. *Injectable Fillers: Principles and Practice*. Wiley-Blackwell, London 2010.

concise and cogent fashion. The results of their review of work from Bartlett et al,²⁹ Pessa,³⁰⁻³⁵ Levine et al,³⁶ Farkas et al,³⁷ Mendelson et al,³⁸ and Shaw and Kahn³⁹⁻⁴¹ indicate that significant and consistent changes occur as the craniofacial skeleton ages. The most consistent findings included a change in contour of the orbit (with superior medial and inferiolateral remodeling as described by Pessa over a decade ago⁴²), decreased midface vertical height in edentulous patients, and a decrease in the glabellar, pyriform, and maxillary angle.

In addition, a recently published retrospective review from Richard et al⁴³ of computed tomography (CT) scans of 100 consecutive patients at Duke University Medical Center included 50 men and 50 women from two age groups, younger (aged 18-30 years) and older (55-65 years). Those authors found similar changes in the glabellar, pyriform, and maxillary angle. They noted that their findings were in agreement with the early work of Enlow⁴⁴ and the “clockwise rotation” of the maxilla and mandible when viewed in profile, as hypothesized by Lambros and Pessa⁴⁵ over a decade ago. The study was in fact carried out to expand Pessa’s work by increasing the sample size, including measurements of the orbit, and examining the role of gender in such aging changes. A

gender dimorphism was revealed with regard to the absolute angular measurements, in that men demonstrated a trend toward more acute measurements in the upper face—specifically the glabellar and orbital angles—compared with women in the same age cohort. Women demonstrated a trend toward more acute angular measurements in the lower face—the maxillary and pyriform angles—compared with men in the same age cohort. Such differences between the genders might be expected when one considers that men are known to have more prominent foreheads and superior orbital rims than women, whereas women are known to have a more diminutive midface than men.

Although longitudinal studies would be ideal, the data described above were all found to be statistically significant. In Figure 9 (a CT image of patients from the younger and older age group of the study by Kahn and Shaw⁴⁰ illustrating the orbital, glabellar, maxillary, and pyriform changes), the shape and proportions of the younger and older craniofacial skeleton without any intervening fat can be seen. The orbital rim changes can be easily noted, as well as a change in the position of the nose.

Finally, age-related bony remodeling causes a decrease in the space available for the soft tissue in the midface;

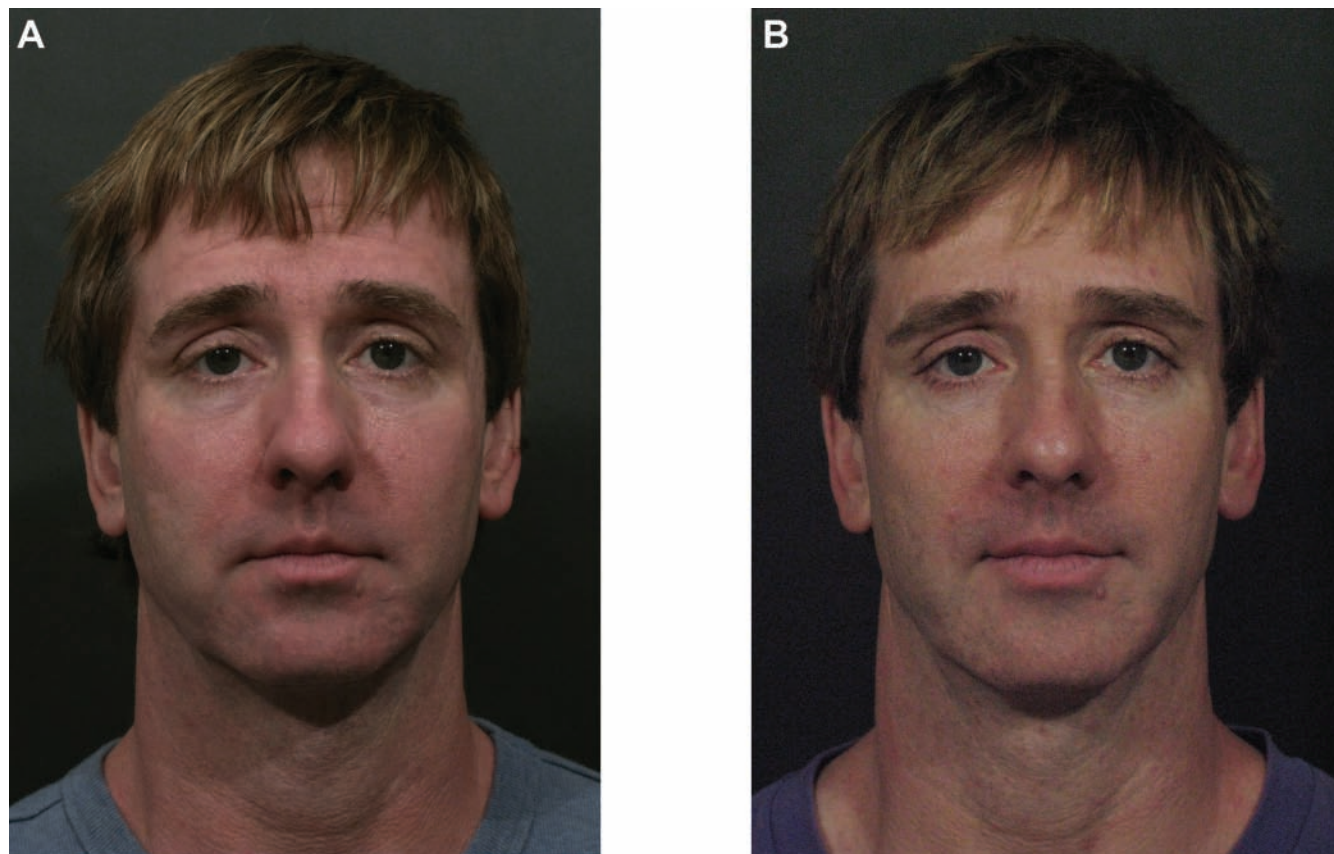


Figure 16. (A) This 50-year-old man presented for treatment of a “tired appearance.” (B) One year after final treatment. He was injected with one vial of poly-L-lactic acid (PLLA) per session for three sessions carried out several months apart (for a total of three vials). The product was placed along his lateral supraorbital rim, lateral zygoma, and canine fossa, as well as along the mandible to address bony remodeling. Note the improvement seen from a very subtle change in facial shape and proportions. Photos courtesy of Rebecca Fitzgerald, MD. Reprinted with permission from Jones DH. *Injectable Fillers: Principles and Practice*. Wiley-Blackwell, London 2010.

the result is a “folding in” of the soft tissue in a configuration that resembles an accordion, referred to by Pessa and colleagues⁵ as the “concertina effect.” The value of this work lies in its implications for treatment—that is, that an inadequate underlying bony structure may be augmented by solid implants or even by injectable shaping agents (such as polylactic acid [PLLA]), resulting in the restoration of soft tissue support and therefore a reversal, to some degree, of the concertina effect. A series of patient photos (Figures 10-17) demonstrate these concepts in clinical practice.

CONCLUSIONS

With an understanding of the facial aging process in the four structural planes—skeletal platform, muscle, fat, and skin—clinicians are better able to employ the available injectable shaping agents to improve a patient’s appearance, either with nonsurgical treatment only or as adjuncts to surgical correction. With this in mind, in the next section, we will address the importance of a careful aesthetic analysis.

Acknowledgments

The faculty acknowledge the writing assistance and editorial services including fact checking, referencing, and graphics

provided by Global Academy for Medical Education, LLC, an Elsevier company, and Joanne Still, medical writer in the development of this continuing medical educational supplement. These services and assistance were funded by grant support from sanofi-aventis.

Disclosures

Dr. Fitzgerald is a consultant for sanofi-aventis. Dr. Graivier is a consultant for Coapt Medical, Elemé Medical, and Evera Medical and is on the speaker’s bureau for Medicis and Sciton. He has stock interests in BioForm Medical. Dr. Kane is a consultant and/or speaker for Allergan, Canfield, Coapt, Galderma, Johnson & Johnson, Medicis, Mentor, QMed, Revanace, sanofi-aventis, Shire, and Stiefel. He has stock interests in Allergan and Medicis. Dr. Lorenc is a consultant for Johnson & Johnson. Dr. Vleggaar is a consultant for sanofi-aventis. Dr. Werschler is a consultant for and has received grant support from Allergan, Clarisonic, Galderma, Genentech, MyoScience, sanofi-aventis, and SkinMedica. He is also a speaker for and has stock interests in Allergan, BioForm, Clarismiz, Medicis, MyoScience, sanofi-aventis, and SkinMedica. Dr. Kenkel is a consultant for Ethicon, Ethicon Endo-Surgery, and UltraShape. He has received grant support and/or equipment for research from Eclipse, Lumenis, Sciton, and UltraShape.

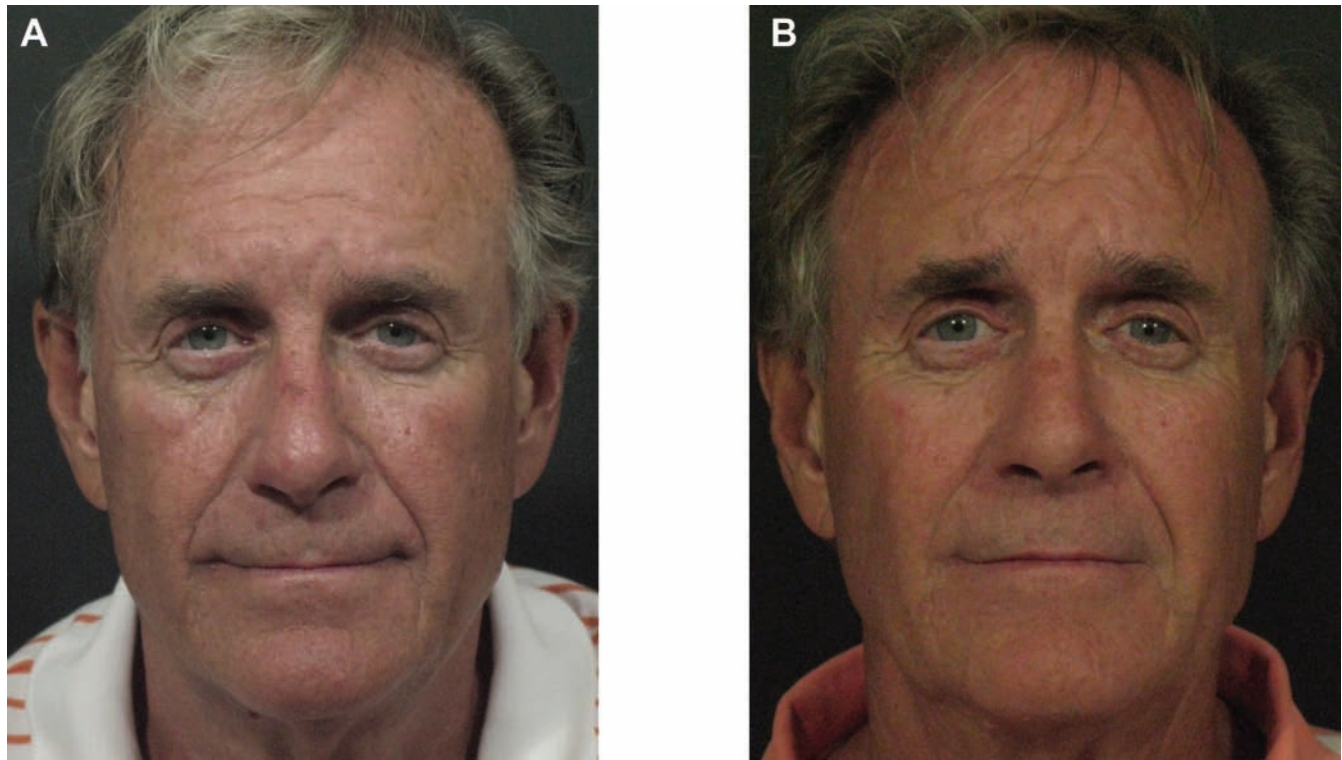


Figure 17. (A) This 60-year-old man presented for treatment of general facial aging. (B) Six months after the final touch-up treatment, which took place six months after the original injections. He was initially injected with two vials of poly-L-lactic acid (PLLA) per session for three sessions over six weeks. Touch-up treatment included two vials of PLLA and took place one year after the last initial treatment. The patient treated with supraperiosteal injections along the lateral supraorbital rim, lateral zygoma, anterior maxilla, canine fossa, and medial mandible, as well as in the temple and the deep medical cheek fat pad. The repositioning of his nose and eversion of his lips are clearly evident. Photos courtesy of Rebecca Fitzgerald, MD. Reprinted with permission from Jones DH. *Injectable Fillers: Principles and Practice*. Wiley-Blackwell, London 2010.

Funding

This CME activity is supported by an educational grant from sanofi-aventis. Funding was provided for the development and execution of an expert consensus roundtable and the editorial development, publication and accreditation of this continuing medical education supplement.

Statement of Peer Review

All supplement manuscripts submitted to *Aesthetic Surgery Journal* for publication are reviewed by the Guest Editor(s) of the supplement, by an outside peer reviewer who is independent of the supplement project, and by the Journal's Supplement Editor (who ensures that questions raised in peer review have been addressed appropriately and that the supplement has an educational focus that is of interest to our readership).

REFERENCES

- Gonzalez-Ulloa M, Flores ES. Senility of the face: basic study to understand its causes and effects. *Plast Reconstr Surg* 1965;36:239-246.
- Sandoval S, Cox J, Koshy J, et al. Facial fat compartments: a guide to filler placement. *Semin Plast Surg* 2009;23:283-287.
- Rohrich R, Ghavami A, Lemmon J, et al. The individualized component face lift: developing a systemic approach to facial rejuvenation. *Plast Reconstr Surg* 2009;123:1050-1062.
- Stuzin JM. Restoring facial shape in face lifting: the role of skeletal support in facial analysis and midface soft tissue repositioning. *Plast Reconstr Surg* 2007;119:362-376; discussion 377-378.
- Pessa JE, Zadoo VP, Yuan C, et al. Concertina effect and facial aging: nonlinear aspects of youthfulness and skeletal remodeling, and why, perhaps, infants have jowls. *Plast Reconstr Surg* 1999;103:635-644.
- Lambros V. Observations on periorbital and midface aging. *Plast Reconstr Surg* 2007;120:1367-1376; discussion 1377.
- Yaar M, Gilchrist BA. Skin aging: postulated mechanisms and consequent changes in structure and function. *Clin Geriatr Med* 2001;17:617-630.
- El Domyati M, Attia S, Saleh F, et al. Intrinsic aging vs. photoaging: a comparative histopathological, immunohistochemical, and ultrastructural study of skin. *Exp Dermatol* 2002;11:398-405.
- Rabe JH, Mamelak AJ, McElgunn PJ, Morison WL, Sauder DN. Photoaging: mechanisms and repair. *J Am Acad Dermatol* 2006;55:1-19.
- Guyuron B, Rowe DJ, Weinfeld AB, Eshraghi Y, Fathi A, Lamphongsai S. Factors contributing to the facial aging of identical twins. *Plast Reconstr Surg* 2009;123:1321-1331.

11. Fisher GJ, Varani V, Voorhees JJ. Looking older: fibroblast collapse and therapeutic implications. *Arch Dermatol* 2008;144:666-672.
12. Wang F, Garza LA, Kang S, et al. In vivo stimulation of de novo collagen production caused by cross-linked hyaluronic acid dermal filler injections in photodamaged human skin. *Arch Dermatol* 2007;143:155-163.
13. Donofrio LM. Fat distribution: a morphologic study of the aging face. *Dermatol Surg* 2000;26:1107-1112.
14. Coleman SR, Grover R. The anatomy of the aging face: volume loss and changes in 3-dimensional topography. *Aesthetic Plast Surg* 2006;26:S4-S9.
15. Raskin E, LaTrenta GS. Why do we age in our cheeks? *Aesthetic Surg J* 2007;27:19-28.
16. Rohrich RJ, Pessa JE. The fat compartments of the face: anatomy and clinical implications for cosmetic surgery. *Plast Reconstr Surg* 2007;119:2219-2227; discussion 2228-2231.
17. Schaverien MV, Pessa JE, Rohrich RJ. Vascularized membranes determine the anatomical boundaries of the subcutaneous fat compartments. *Plast Reconstr Surg* 2009;123:695-700.
18. Pessa J. The tear trough and lid/cheek junction: anatomy and implications for surgical correction. *Plast Reconstr Surg* 2009;123:1332-1340.
19. Rohrich RJ, Pessa JE, Ristow B. The youthful cheek and the deep medial fat compartment. *Plast Reconstr Surg* 2008;121:2107-2112.
20. Rohrich RJ, Pessa JE. The anatomy and clinical implications of perioral submuscular fat. *Plast Reconstr Surg* 2009;124:266-271.
21. Rohrich RJ, Arbiqum GM, Wong C, et al. The anatomy of suborbicularis fat: implications for periorbital rejuvenation. *Plast Reconstr Surg* 2009;124:946-951.
22. Lambros V. Models of facial aging and implications for treatment. *Clin Plast Surg* 2008;35:319-327; discussion 317.
23. Le Louarn CL, Buthiau D, Buis J. Structural aging: the facial recurve concept. *Aesthetic Plast Surg* 2007;31:213-218.
24. Levy PM. The 'Nefertiti lift': a new technique for specific re-contouring of the jawline. *J Cosmet Laser Ther* 2007;9:249-252.
25. Reece EM, Pessa JE, Rohrich RJ. The mandibular septum: anatomical observations of the jowls in aging—implications for facial rejuvenation. *Plast Reconstr Surg* 2008;121:1414-1420.
26. Albert AM, Ricanek K Jr, Patterson E. A review of the literature on the aging adult skull and face: implications for forensic science research and applications. *Forensic Sci Int* 2007;172:1-9.
27. Doual JM, Ferri J, Laude M. The influence of senescence on craniofacial and cervical morphology in humans. *Surg Radiol Anat* 1997;19:175-183.
28. Sharabi S, Hatf D, Koshy J. Mechanotransduction: the missing link in the facial aging puzzle? *Aesthetic Plast Surg* 2010 May 4. [Epub ahead of print]
29. Barlett SP, Grossman R, Whitaker LA. Age-related changes of the craniofacial skeleton: an anthropometric and histological analysis. *Plast Reconstr Surg* 1992;90:592-600.
30. Pessa JE, Zadoo VP, Mutimer KL, et al. Relative maxillary retrusion as a natural consequence of aging: combining skeletal and soft-tissue changes into an integrated model of midfacial aging. *Plast Reconstr Surg* 1998;102:205-212.
31. Pessa JE, Desvigne LD, Zadoo VP. The effect of skeletal remodeling on the nasal profile: considerations for rhinoplasty in the older patient. *Aesthetic Plast Surg* 1999;23:239-242.
32. Zadoo VP, Pessa JE. Biological arches and changes to the curvilinear form of the aging maxilla. *Plast Reconstr Surg* 2000;106:460-466.
33. Pessa JE. An algorithm of facial aging: verification of Lambros's theory by three-dimensional stereolithography, with reference to the pathogenesis of midfacial aging, scleral show, and the lateral suborbital trough deformity. *Plast Reconstr Surg* 2000;106:479-488.
34. Pessa JE, Chen Y. Curve analysis of the aging orbital aperture. *Plast Reconstr Surg* 2002;109:751-755.
35. Pessa JE, Slice DE, Hanz KR, Broadbend TH, Rohrich RJ. Aging and the shape of the mandible. *Plast Reconstr Surg* 2008;121:196-200.
36. Levine RA, Garza JR, Wang PT, Hurst CL, Dev VR. Adult facial growth: application to aesthetic surgery. *Aesthetic Plast Surg* 2003;7:265-283.
37. Farkas LG, Eiben OG, Sivkov S, Tompson B, Katic MJ, Forrest CR. Anthropometric measurements of the facial framework in adulthood: age-related changes in eight age categories in 600 healthy white North Americans of European ancestry from 16 to 90 years of age. *J Craniofac Surg* 2004;15:288-298.
38. Mendelson BC, Hartley W, Scott M, McNab A, Granzow JW. Age-related changes of the orbit and midcheek and the implications for facial rejuvenation. *Aesthetic Plast Surg* 2007;31:419-423.
39. Shaw RB Jr, Kahn DM. Aging of the midface bony elements: a three-dimensional computed tomographic study. *Plast Reconstr Surg* 2007;119:675-681.
40. Kahn DM, Shaw RB. Aging of the bony orbit: a three-dimensional computed tomographic study. *Aesthetic Surg J* 2008;28:258-264.
41. Shaw RB, Katzel EB, Koltz PF, Kahn DM, Giroto JA, Langstein HN. Aging of the mandible and its aesthetic implications. *Plast Reconstr Surg* 2010;125:332-342.
42. Pessa JE, Chen Y. Curve analysis of the aging orbital aperture. *Plast Reconstr Surg* 2002;109:751-755; discussion 756-760.
43. Richard MJ, Morris C, Deen B, et al. Analysis of the anatomic changes of the aging facial skeleton using computer-assisted tomography. *Ophthalmol Plast Reconstr Surg* 2009;25:382-386.
44. Enlow DH. *Handbook of Facial Growth*. Philadelphia: Saunders; 1982.
45. Pessa JE. An algorithm of facial aging: verification of Lambros's theory by three-dimensional stereolithography, with reference to the pathogenesis of midfacial aging, scleral show, and the lateral suborbital trough deformity. *Plast Reconstr Surg* 2000;106:479-488.
46. Pessa JE, Zadoo VP, Mutimer KL, et al. Relative maxillary retrusion as a natural consequence of aging: combining skeletal and soft-tissue changes into an integrated model of midfacial aging. *Plast Reconstr Surg* 1998;102:205-212.