

A winning combination

In this complex combination case, screw-retained hybrids utilizing CAD/CAM MT bars, and an attached RPD supporting an obturator are used to restore a completely edentulous patient with a palatal defect caused by cancer.

By Thomas Wade, CDT. Information provided by Ivoclar Vivadent Inc.

In recent years, through the advent of CAD/CAM technologies and advanced material sciences, treatments for edentulism have greatly improved.¹ Contributing to their success, implant materials osseointegrate with the underlying bone to offer the retention, strength, esthetics and durability required.⁵ When used with a combination of innovative materials, including

CAD/CAM milled titanium frameworks, premium and durable denture teeth and strong, dense injected acrylics, dental implants now provide patients with prostheses that fit comfortably and appear lifelike. These advanced materials also can better withstand the rigors of the increased vertical and horizontal forces generated by implant prostheses.

Although CAD/CAM technologies and advanced materials have made treatment of edentulism more efficient, the complexities of many cases require an interdisciplinary approach.² Collaboration and constant communication between the oral surgeon, restorative dentist and laboratory technician helps guarantee the best results for the patient.^{2,3}



SR Ivocap

Features

- Highly shock and fracture resistant material for a stable denture base on implants
- Mixed to a clean homogeneous consistency in the Cap Vibrator
- Precision fit without vertical increase of occlusion
- Outstanding bond with resin teeth
- Excellent polishability
- Tried-and-tested injection technique

Ivoclar Vivadent

ivoclarvivadent.com
info@ivoclarvivadent.com

175 Pineview Drive
Amherst, NY 14228
800-533-6825



Fig. A A view of a CAM screenshot showing the virtually designed bar and threaded VKS 2.2 ball attachments.

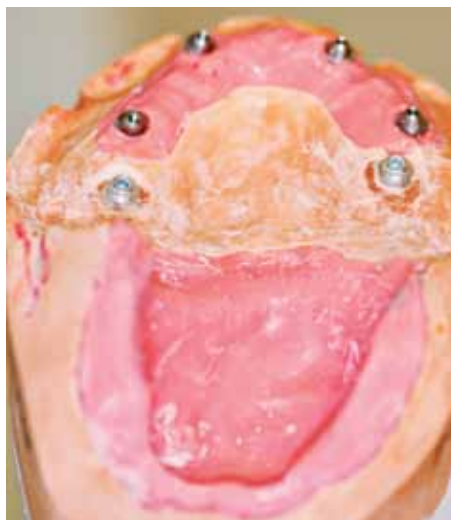

Fig. B The verified master cast of the case was received from the prosthodontist.

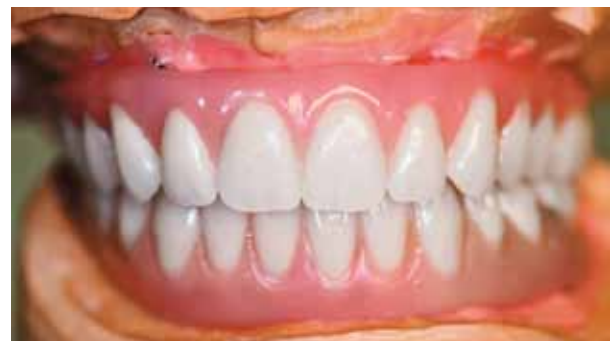

Fig. C Prior to scanning, the esthetics and occlusion of the full upper and lower set-up/wax-up were confirmed by the clinician and the patient.

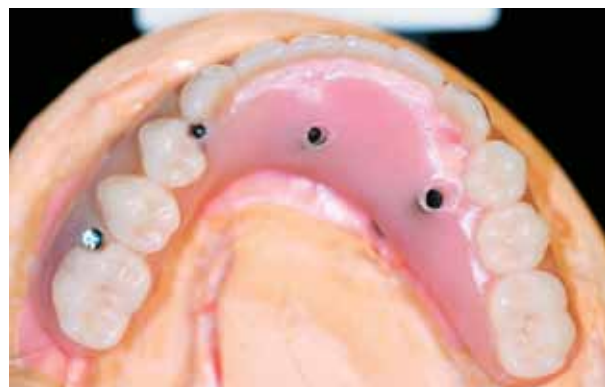

Fig. D The occlusal photograph of the mandibular screw-retained hybrid demonstrated the collapse of the TMJ caused by the cancer, and subsequent shift of the mandible.

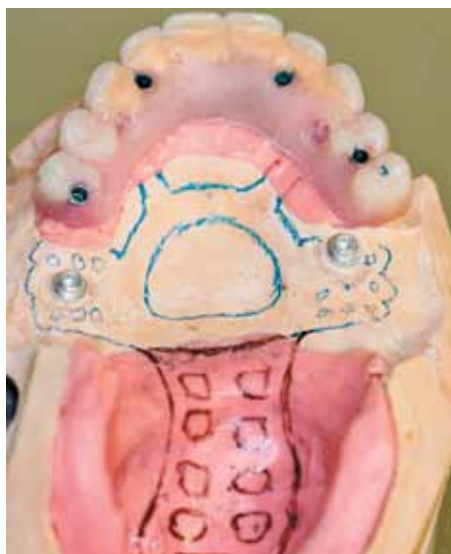

Fig. E Maxillary screw-retained hybrid (SRH) set and waxed with preliminary design of attached RPD supporting molars and obturator lattice mechanism.

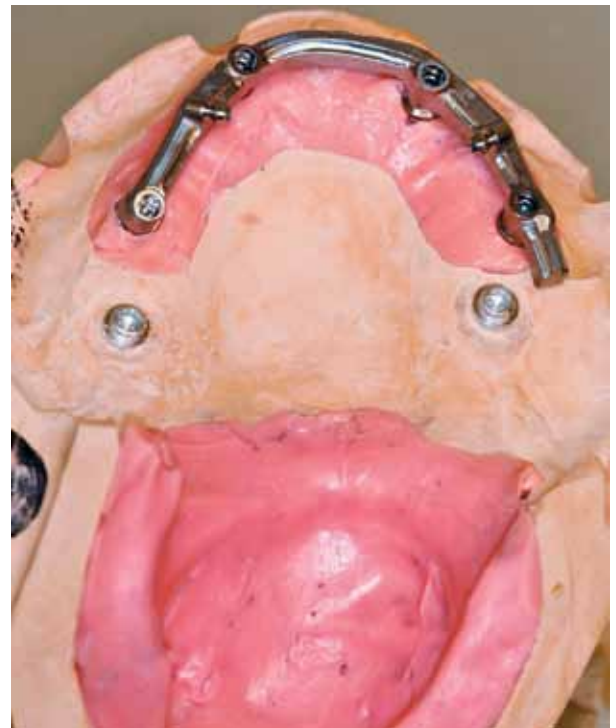


Fig. F Approved set-up scanned and milled titanium bar (Nobel Procera) in place on cast.

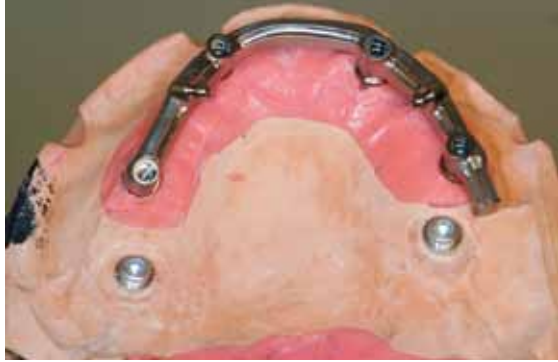

Fig. G A close-up of the milled titanium bar shows the Bredent VKS ball attachments threaded into place and two independent Locator abutments to allow four-point attachment.

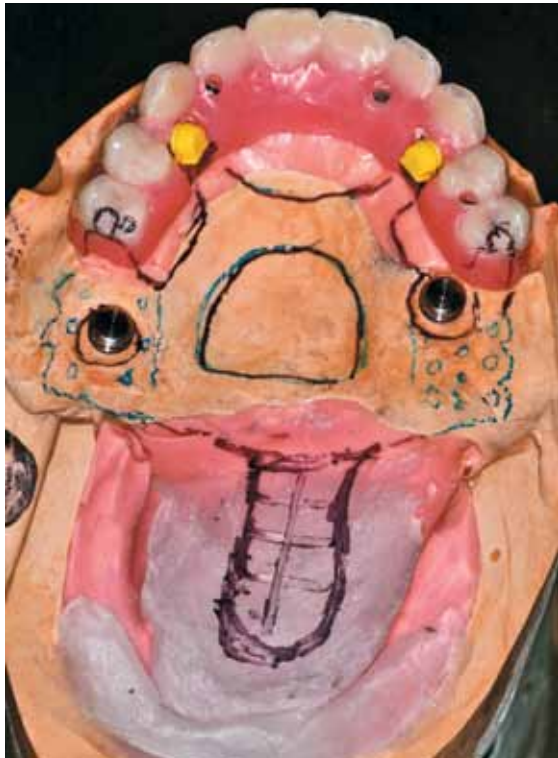

Fig. H The injection processed SRH with attachments placed and relief for obturator lattice ready for duplication for RPD fabrication.

MATERIAL CONSIDERATIONS

Of equal importance to the success of complex edentulous cases are the materials used during fabrication of the prostheses.⁴ Polymerization shrinkage has remained an area where improvement is desired with conventional press-packed or poured acrylic base materials. Further, denture base materials often do little to prevent accumulation of bacteria and plaque.⁵ Therefore, a material should be chosen that addresses these issues, while still offering comfort and esthetics to the patient.

Eliminating inaccuracies in fit and function caused by polymerization shrinkage, **SR Ivocap** injectable (Ivoclar Vivadent) features a controlled heat and pressure polymerization based system.⁶ Demonstrating a high degree of polymerization, it compensates for acrylic shrinkage by continuously flowing the exact amount of material needed into the flask.^{6,7} The material is distributed in capsule form, requiring no measuring and preventing direct contact of the material with the skin.¹²

Remaining unchanged throughout the entirety of the polymerization process, 6-bar pressure ensures the material is

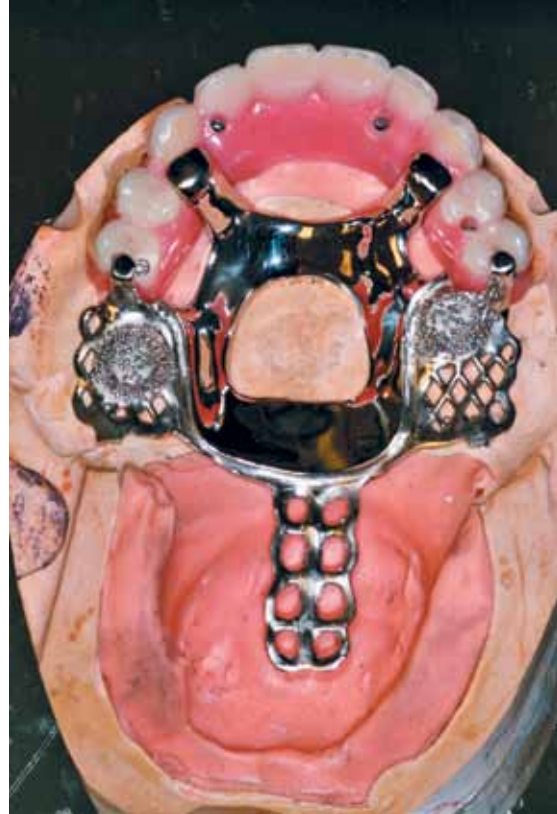


Fig. I Cast chrome framework completed and seated on cast/SRH.



Fig. J Topside of framework showing micro-bead retention on top of Locator housings.

continuously pressed into the flask.⁸ Additionally, the SR Ivocap polymerization system reduces the risk of system-induced increases in vertical dimension and spherical deformation.^{6,9} This eliminates the need for occlusal adjustments, promotes homogeneity and reduces the risk of fracture.⁶ The completed SR Ivocap injectable base is highly polishable and resistant to plaque accumulation.^{6,9} Further, the material offers excellent handling characteristics and enables a strong bond to resin teeth when proper preparation is observed.^{6,9}

REVERSE ENGINEERING

Compared to the techniques of the past, reverse engineering is now the accepted protocol for fabrication of dental prostheses when CAD/CAM titanium bars are incorporated.¹⁰ Unlike conventional step-by-step forward moving fabrication techniques, reverse engineering allows the laboratory technician to avoid problems with final assembly of all the components.

Beginning with a preliminary set-up and wax-up that's approved by the clinician and their patient with regard to



Fig. K The tissue side of framework illustrating chrome receptacles for VKS nylon inserts and relieved receptacles to allow cemented pick-up of Locator metal housings.

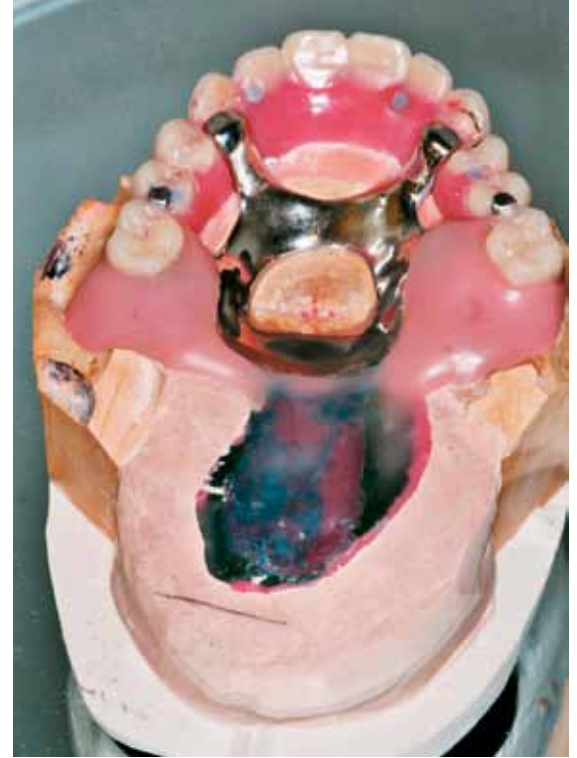

Fig. L The first molars were added and obturator bulb waxed to complete the upper arch prosthesis.

esthetics, bite/VDO, phonetic and hygienic considerations, it's then laser scanned and the MT bar is designed from within. Knowing the contours, as well as the screw access holes and shafts of the implants prior to fabricating the prosthesis, the laboratory technician can ensure that all components will be built within the parameters of the final contours of the device.

The process involves three separate scans (i.e., the implants, the tissues and the waxed set-up). After the entire device has been scanned, the images are then married using CAD/CAM software to create a three-dimensional image of the final prosthesis. The milled titanium bar, as well as attachments when indicated, can then be virtually designed within those parameters and an image or "screenshot" (Fig. A) may then be shown to the clinician if they are so inclined, allowing them to approve the design prior to milling. Eliminating concerns of components not fitting together in harmony, or in the case of screw-retained devices, having access holes in undesirable locations, reverse engineering enables laboratory technicians to complete cases more predictably and efficiently.

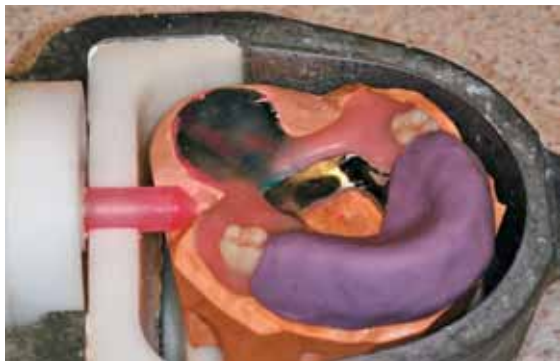

Fig. M The cast trimmed very tightly to barely fit within the Ivocap injection flask.

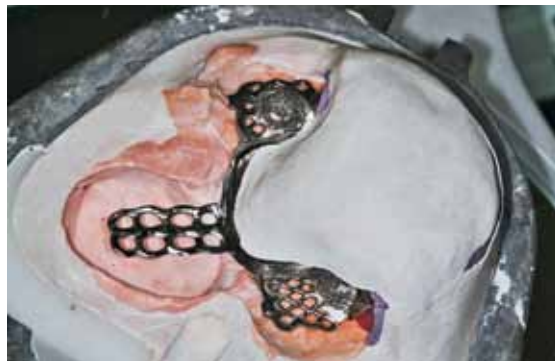

Fig. N The flask boiled out and prepared, ready to assemble and inject.

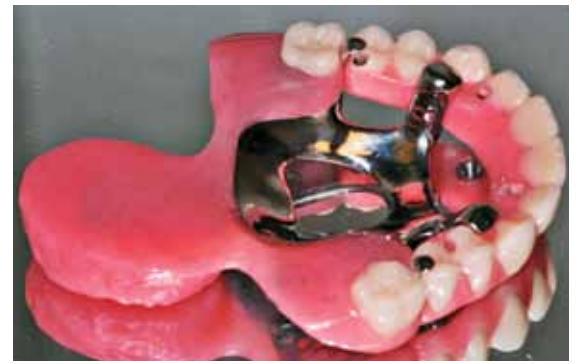

Fig. O The processed and finished RPD attached to SRH, occlusal view.

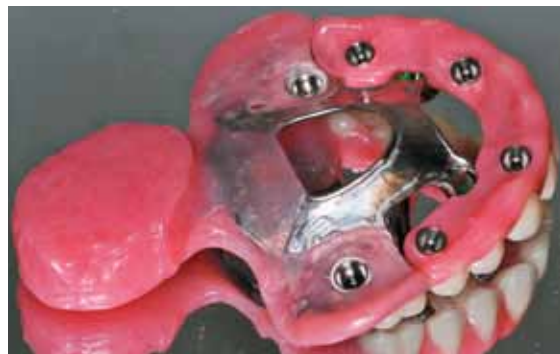

Fig. P The finished devices attached, intaglio surface. Note: intraorally picked up/cemented Locator housings.



Fig. Q The RPD/ obturator with green, light retention nylon inserts seated.

CASE STUDY

A completely edentulous patient presented for complete upper and lower arch restoration as a result of complex and compounding issues, including stage IV Squamous Cell cancer treatment 20 years prior that required removal of a large section of the soft palate near the back of the maxilla. Additionally, the cancer also required resection of the left condyle resulting in mal-alignment of the mandible.

A four-fixture screw-retained hybrid (SRH) was used to restore the mandibular arch. A two piece combination, screw-retained hybrid and removable partial denture (RPD) would be

used for the maxilla. The screw-retained prosthetic would be used to restore the dentition to the second bicuspid, while a removable cast partial framework—with four point attachment to both the hybrid device as well as the two most distal implants (Independent) with direct attached Locators—will support the first molars as well as the acrylic obturator that will fill the space that was opened when the soft palate was lost. This is required to allow the obturator to be removable by the patient to drain fluids that collect as well as to clean the device.

A Nobel Procera CAD/CAM milled titanium framework would be used, along with Bredent VKS ball and Locator

attachments, SR Ivocap injection denture base material, and premium, wear resistant denture teeth.

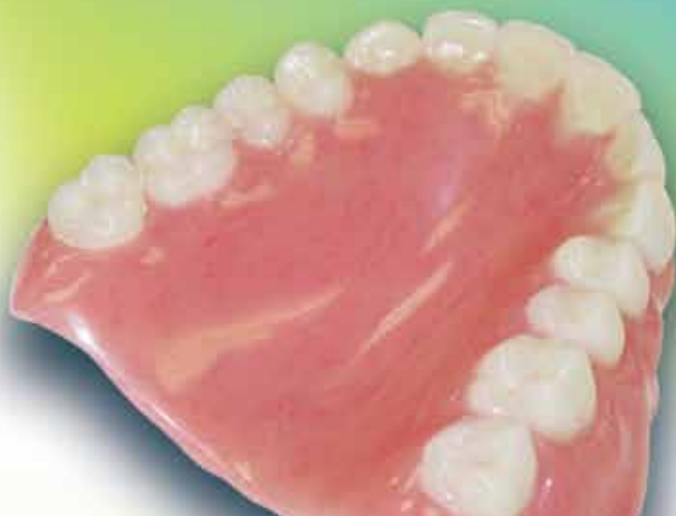LABORATORY TECHNIQUE

01 The maxillary master cast, presented to the laboratory by the prosthodontist, was determined to have a total of six implants, four with multi-unit abutments (Nobel Biocare) to support the screw-retained hybrid, and two with Locator abutments for direct attachment to the removable partial denture, (Fig. B).

02 However, prior to scanning, the case was set and waxed-up for esthetic and functional confirmation from the patient (Fig. C). The mandibular set-up clearly illustrates the shift of the mandible by the contrast of the arch form of the implants compared to the arch form of the teeth (Fig. D).

03 On the maxillary device, after the set-up and waxed tissue contours were approved by the doctor and patient, the preliminary design of the anticipated RPD was drawn on the cast and small divots were carved into the wax just lingual to the cuspid to indicate the strategic placement of the Bredent VKS balls, so they would transfer in the scan and assist in proper placement in virtual design of the bar (Fig. E).

This Denture is Reinforced. Invisibly.



It contains a highly resistant, virtually invisible reinforcement that bonds to any denture acrylic. FiBER FORCE® is ideal for all new dentures, denture repairs, and is especially suited for implant-supported dentures.



Call SYNCA today or visit our website
www.fiberforcedental.com
1-888-582-8115
 in Canada: 1-800-667-9622

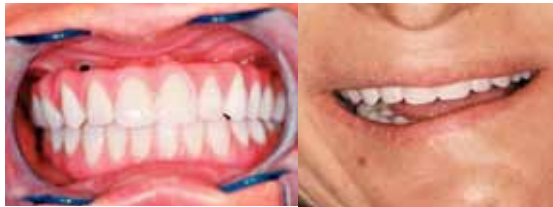

Fig. R Final seating of Maxillary combination SRH and attached RPD and Mandibular SRH.

Fig. S Photograph of seated devices illustrating collapse of left TMJ and subsequent mandible shift.

There are two basic design options for fabrication of a screw-retained hybrid or “fixed- detachable” device. One style commonly known as the “full wrap” places the bar several millimeters off the tissue and it’s completely wrapped so the intaglio surface is acrylic. This allows for adjusting the surface and its relation to the tissue by either adding or taking away acrylic. It’s required on immediate load cases where ongoing tissue management due to resorption or grafting issues might occur, or in maxillary arches where ongoing adjustments due to air escape (Phonetics) or lip/cheek support might be necessitated.

The second style is commonly known as “Montreal.” It incorporates a convex, mirror-polished titanium intaglio surface and is generally considered to be more hygienic, but not adjustable, as the entire intaglio surface, including the transition into the abutments is polished titanium, with the metal-acrylic junction being raised to a single buccal-lingual finish line.

In this case, both the maxillary and mandibular arches were determined to be full wrap by the doctor.

04 Upon completion and return from the milling center, the bar is returned to the cast and the mouth to confirm passivity. (Fig. F). Threaded receptacles were incorporated into the bar for the Bredent VKS balls to allow for easy replacement in the future due to wear (Fig. G).

05 Upon verification, the teeth were then injection processed onto the bar, finished and seated back on

cast. Female attachments were placed and final design of the desired cast chrome framework was drawn on cast (Fig. H).

06 This was then duplicated with reversible hydrocolloid and the framework fabricated and fit to the cast and SRH (Fig. I).

07 The framework itself provided the housings for the VKS nylon inserts as well as slightly relieved receptacles to allow for intraoral pick-up via cementing of the Locator metal housings, and a strong lattice support mechanism for the acrylic obturator bulb (Figs. J, K).

08 The molars were set and the saddles and obturator waxed up in preparation for final processing (Fig. L).

09 Due to the long span of the conventional arch of teeth combined with the extension of the obturator, it was necessary to trim the cast to the absolute minimum to get it into the flask (Fig. M).

10 After investment and boil-out, final preparation including using metal primer bonding agent (GC America) is completed prior to injection processing (Fig. N).

11 Upon successful completion of processing, the RPD was then finished, polished and final nylon females inserted. The two finished devices were then married for the first time to test the retention level (Figs. O, P).

12 With the medium retention VKS females (Yellow) combined with the two Locators, the retention proved to be a bit too much, so the yellow females were replaced with the green, light retention females, which were still very adequate (Fig. Q).

In many obturator cases, the bulbs are so large and heavy, and retention minimal, that they often need to be hollowed out to reduce weight and aid in seating stability.

However, in this case, the bulb was relatively small and the retention afforded by the four-point attachment was great enough that this step was unnecessary.

13 Using 10 implants, three devices with two milled titanium bars, a cast chrome framework and four attachments, the patient was able to have the full arch occlusion restored, mostly in a “fixed” manner, while simultaneously having a removable device to restore the palatal defect.

CONCLUSION

Although fully edentulous, multiple implant cases may be complex, they also present an opportunity for the dentist and laboratory technician to collaborate to ensure outstanding rehabilitation results for the patient. Using a combination of advanced CAD/CAM technologies and materials such as SR Ivocap, prosthetic devices now offer patients the support they need and the comfort and esthetics they demand.

Maintaining full communication throughout the fabrication of this prosthetic device and carefully considering all material selections, the dentist and technician in this case were able to provide the patient with a highly functioning, well-fitting, and esthetic prosthesis (Figs. R, S). **lab**


References available with online version.

ABOUT THE AUTHOR

Thomas Wade, CDT, has owned and operated New Horizons Dental Laboratory in Broomfield, Colo., since 1983 and has always specialized in the fabrication of removable and implant prosthetics. He is a published author and lectures on both clinical and laboratory aspects of multiple implant, full arch prostheses, with an emphasis on CAD/CAM milled titanium bar restorations. He is a 1976 graduate of the Dental Technology Program at the U.S. Air Force School of Health Care Sciences, Sheppard AFB, Wichita Falls, Texas.



The Solution for Stronger Dentures.



FIBER FORCE® is a system of pre-impregnated light-curable meshes, braids and UD fibers.



- Fast, easy and inexpensive
- Bonds to acrylic and adds no weight
- Esthetically pleasing

Call SYNCA today or visit our website
www.fiberforcedental.com

1-888-582-8115
 in Canada: 1-800-667-9622