

# All-on-4® Treatment Concept

## Restorative Quick Guide

Concept and arrangement: Thomas Wade, CDT  
Clinical work and photography: Andrew Bock, DDS  
Laboratory work and photography: Thomas Wade, CDT

The following step-by-step protocol is designed to provide clinicians with the information necessary to more effectively collaborate with laboratory partners in the proper fabrication and successful seating of a screw-retained hybrid implant bar and attached prosthesis, utilizing NobelProcera® CAD/CAM milled Titanium implant bars, prefabricated denture teeth, and appropriate denture acrylic (e.g. Methyl Methacrylate (MMA)).



In the presented case, four months after surgery, the patient is ready to receive the final implant bar restoration.  
This restoration will be seated on abutment level using Nobel Biocare Multi-unit Abutments.

The definite restoration can either be seated on Multi-unit abutments, e.g. in cases where a divergence between implants occurs, or can be seated directly on the implant interface.


Depending on this the selection of the appropriate impression copings is critical.

### For a restoration seated on Multi-unit Abutments:

- Open tray impression copings, Multi-unit

### For a restoration seated on the implant interface:

- Open tray impression copings, Bridge



### Components needed

#### For clinical impression taking:

- Open tray Multi-unit impression copings
- Implant replica, Multi-unit




#### For model fabrication:

- Temporary Coping Plastic, Multi-unit
- Lab Screw, Multi-unit
- Guide Pin, Multi-unit 20 mm
- Implant replica, Multi-unit



#### If the restoration should be seated directly on the implant connection, it is critical to use the corresponding impression copings:


- Open tray impression copings, Bridge



**Appointment 1 – clinician**

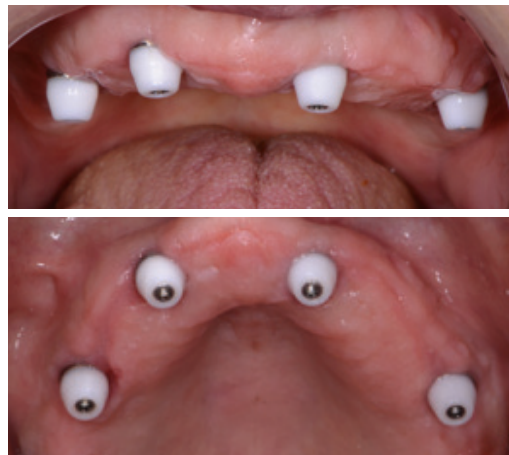
**Components needed:**

- Plastic stock impression tray
- Open tray Multi-unit impression copings



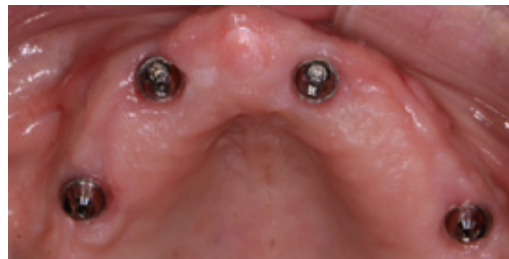**Starting situation after surgery**

Implants have been placed and Multi-unit Abutments have been connected to the implants after surgery. For the time of healing the Multi-unit Abutments have been covered with Healing Caps.

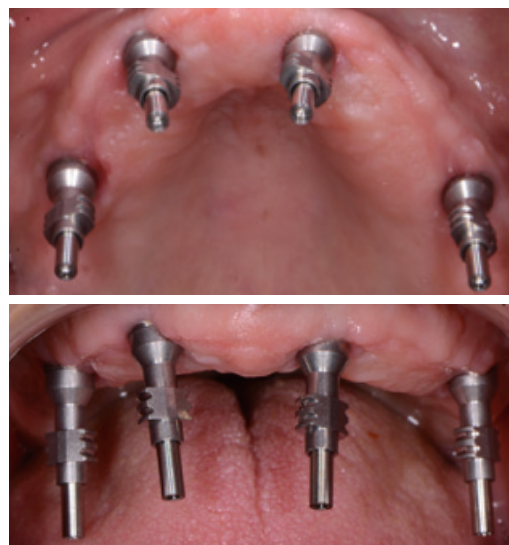

**The healing caps need to be removed for impression taking, the Multi-unit Abutments stay in place:**

Straight Multi-unit Abutments on the anterior implants, angled Multi-unit Abutments on the posterior implants



The Impression Copings, Multi-unit, are seated accurately on the Multi-unit Abutments and the screws are tightened.

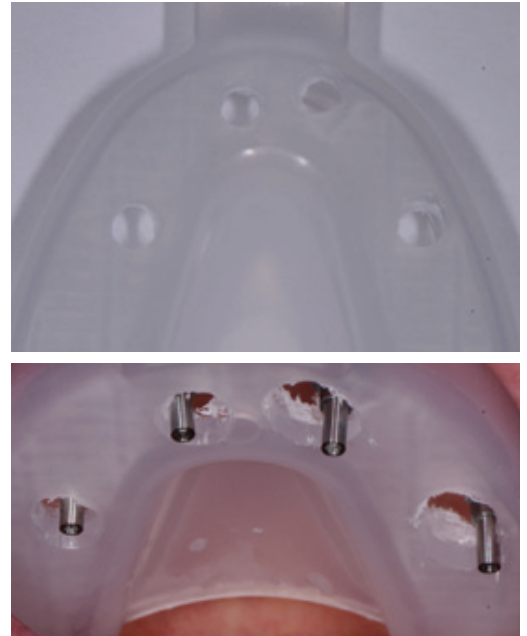


Mark the position of the impression copings and drill holes into plastic impression tray.



Check if the size and position of the holes fit the impression copings before applying impression material.

If position and size of holes for impression copings are fine, apply impression material and take an open tray impression.



Preliminary model, verification jig and individual impression tray

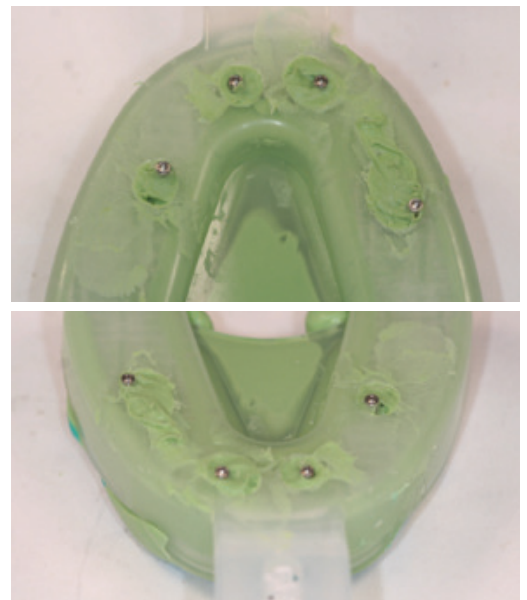
Courtesy of Andrew Bock, DDS (USA)

### Appointment 1 – technician

#### Components needed:

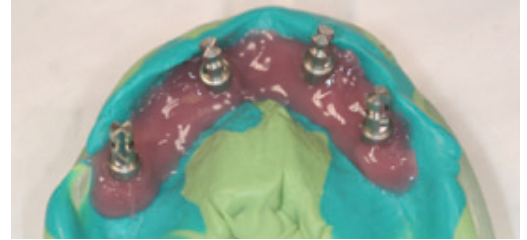
– Implant replica, Multi-unit

The impression tray arrives in the lab. The screws are free from impression material. Implant replica Multi-unit are carefully connected to the impression copings.



Courtesy of Thomas Wade, CDT (USA)

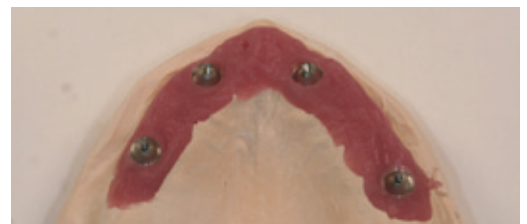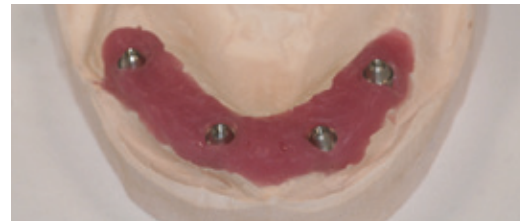Soft tissue material is applied around the implant replicas to create a gingiva mask following manufacturer's instructions.



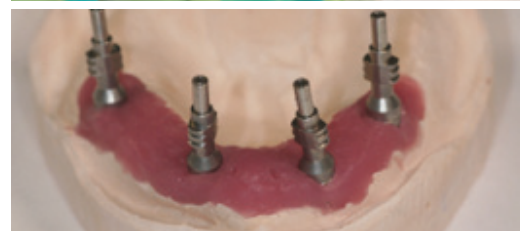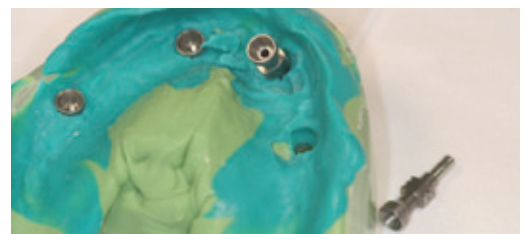The preliminary model is poured using Type IV stone (high strength stone) and following manufacturer's instructions during preparation, application and setting.



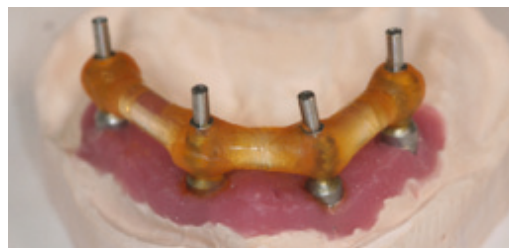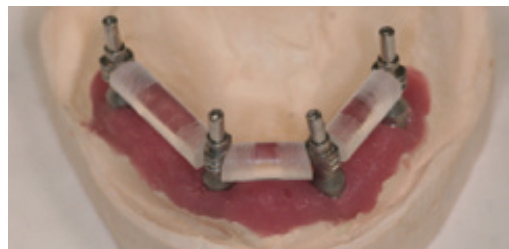After sufficient time for the stone to set, the screws are loosened and the impression tray is removed. The model is trimmed, cleaned and identified.



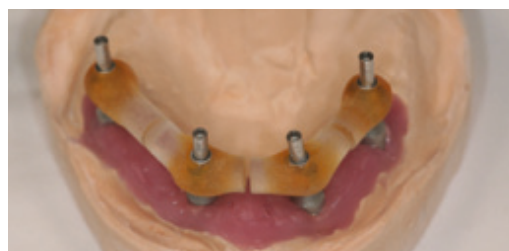
The impression copings can be taken from the impression, cleaned and reused. They are seated on the implant replicas in the preliminary model.



A jig is created using e.g. plastic sticks to connect the impression copings. Additionally they are connected with self-curing acrylic.



When sectioning the jig with separating discs the access of the clinician should be considered.



An individual impression tray is fabricated, fitting over the jig and providing access to the impression coping screws.

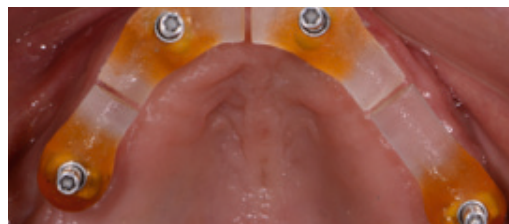
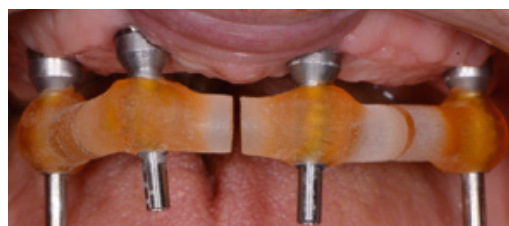

## Appointment 1 – clinician

### Components needed:

- Individual impression tray
- Individual, sectioned jig

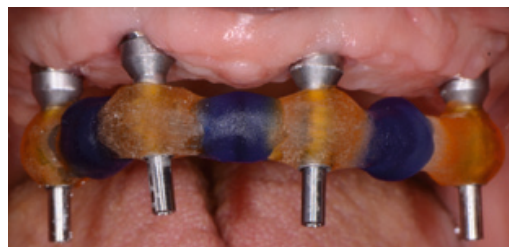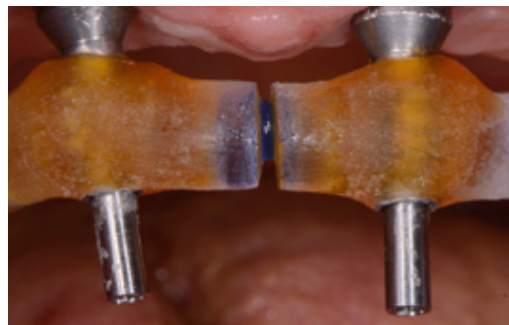
Carefully position the jig on the Multi-unit Abutments and tighten the screws. If any doubt about the correct seating of a section, verify by taking an x-ray.



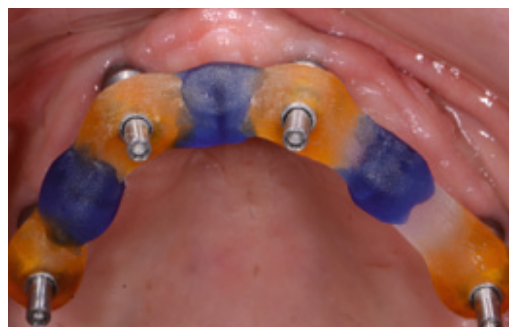Courtesy of Thomas Wade, CDT (USA)

Courtesy of Andrew Bock, DDS (USA)

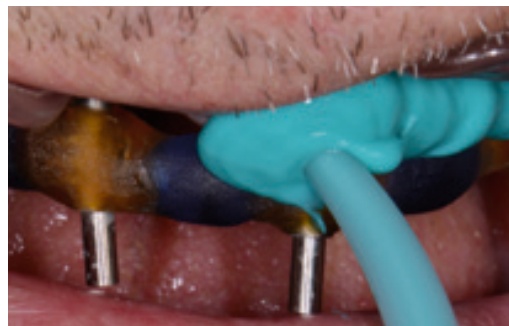Carefully connected the sectioned parts of the jig using acrylic material, e.g. Pattern Resin. Use acrylic which cures without expansion or shrinkage to avoid distortion of the sections.



After sufficient time for the acrylic to complete set, prepare the individual impression tray by applying polyether adhesive generously.



Start applying impression material by carefully applying it around the impression copings using a syringe. Then apply over the complete jig and into the impression tray.



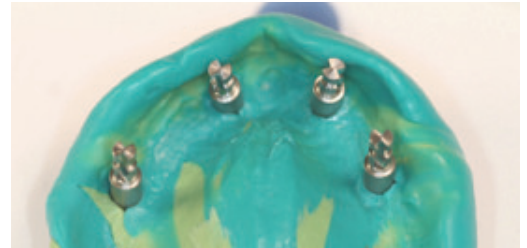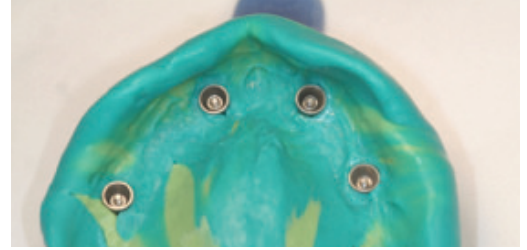## Appointment 2 – technician

---

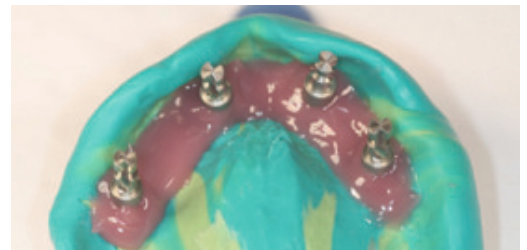### Components needed:

- Implant replica, Multi-unit

Place implant replicas, Multi-unit, carefully on the impression copings. Ensure not to turn the impression copings or carefully tighten the screws.



Apply soft tissue material around the implant replicas and follow manufacturer's instructions for setting time. Pour a master model using Type IV stone (high strength stone).



Courtesy of Thomas Wade, CDT (USA)

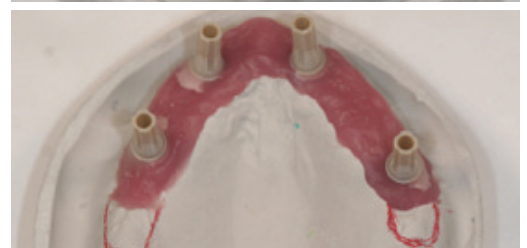
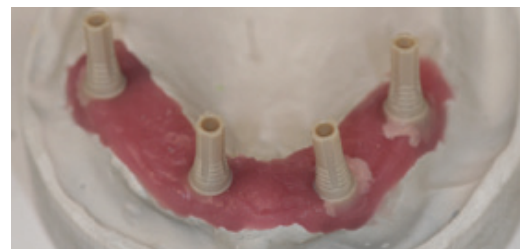
## Preparation for Appointment 3 (bite records and vertical dimension)

---

### Components needed:

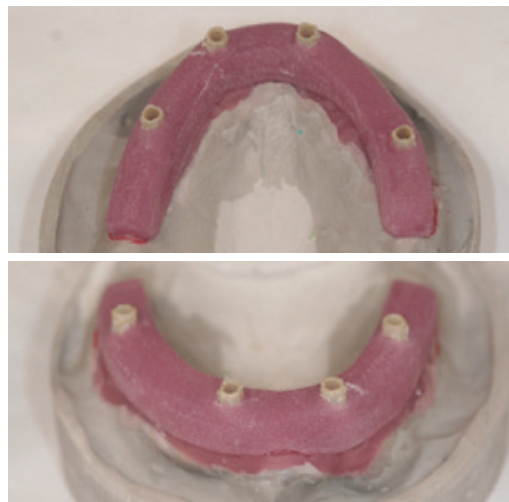
- Temporary Abutments, Plastic
- Abutment screws

The Temporary Abutments Plastic are placed on the model and connected with the abutment screws. The extension of the base for the definite restoration is defined and marked on the model.

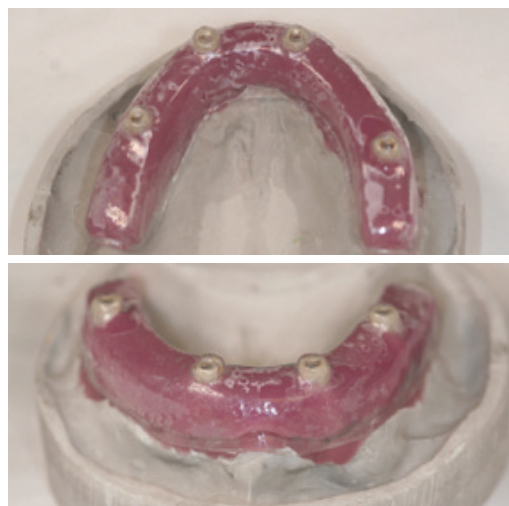

Courtesy of Thomas Wade, CDT (USA)

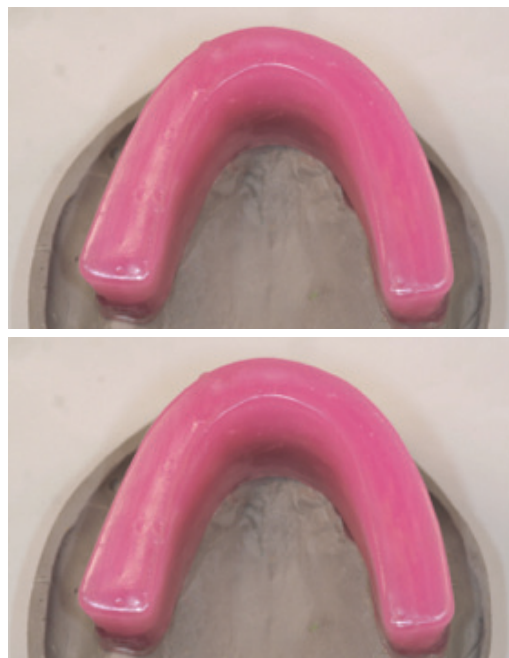Light-curing acrylic is used to create a stable base and connect the temporary abutments with each other. In order to keep the height of the base low, the abutments are cut to the necessary height.



Using a deep-drawing technique a base is created over the solid base. The second base should only have very small flanges (only to support a secured seat on the acrylic base).

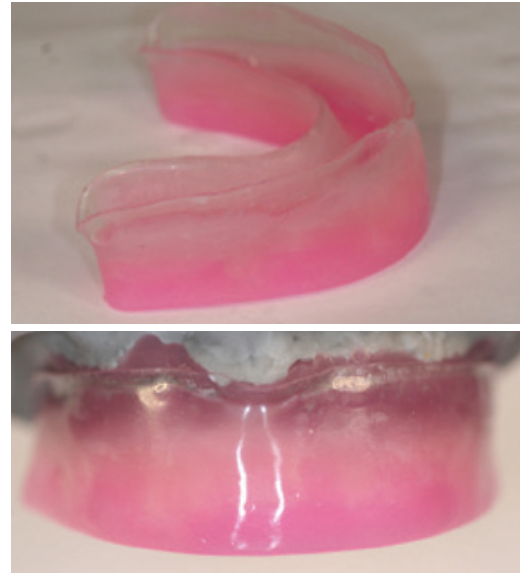


On top of the deep-drawn base a wax-bite-rim is fabricated.





It is important to smooth the edges of the wax bite-rim to ensure a good seat in the patient's mouth.



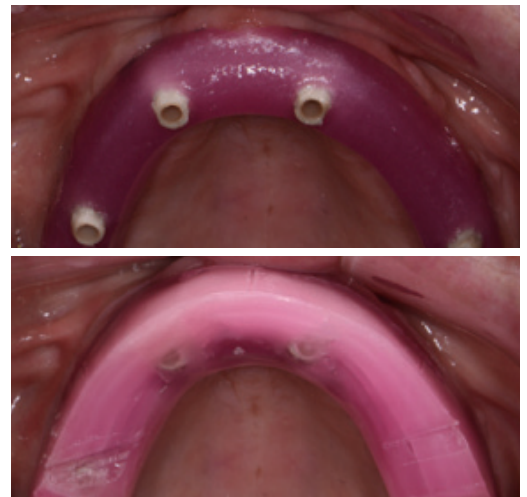
Courtesy of Thomas Wade, CDT (USA)

### Appointment 3 – clinician

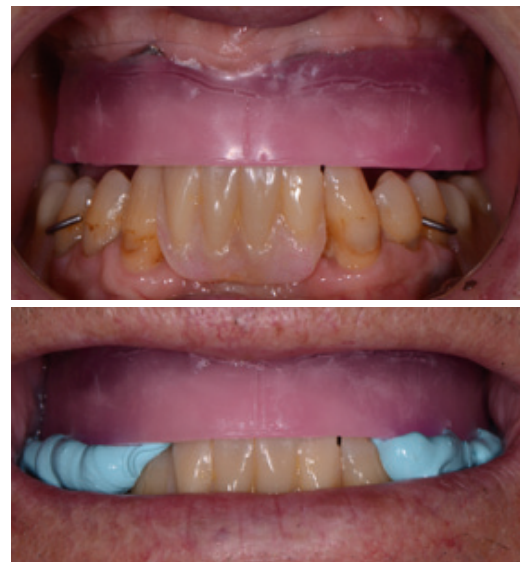#### Components needed:

- Acrylic base
- Wax bite-rim
- Abutment screws

Insert the acrylic base and connect it to the implant using the abutment screws. Adjust the wax bite-rim so it fits easily into the situation and the patient can close the mouth without difficulties.

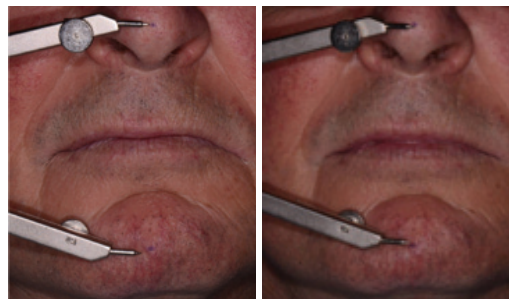

The patient closes the mouth and all important landmarks can be transferred to the wax bite-rim: middle line, canine position, lip closure line, lip position when smiling, etc. To ensure a correct repositioning of the wax bite-rim to the model a bite registration is taken.



Courtesy of Andrew Bock, DDS (USA)

Transfer of VDO accurately from provisional to wax rim.



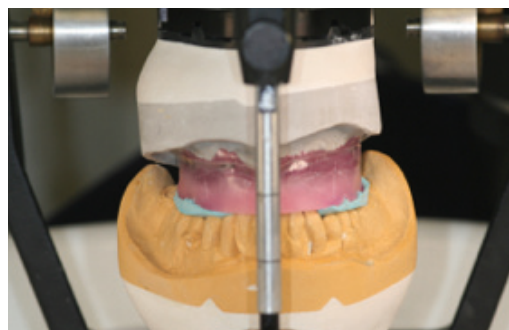
Courtesy of Andrew Bock, DDS (USA)

### Appointment 3 – technician

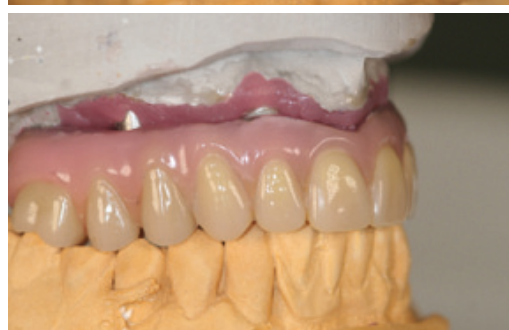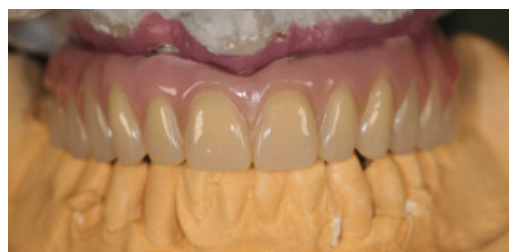#### Components needed:

-Denture teeth

Mount both stone models (master model for maxilla and model of opposing jaw) in an articulator using the wax bite-rim and the bite registration.

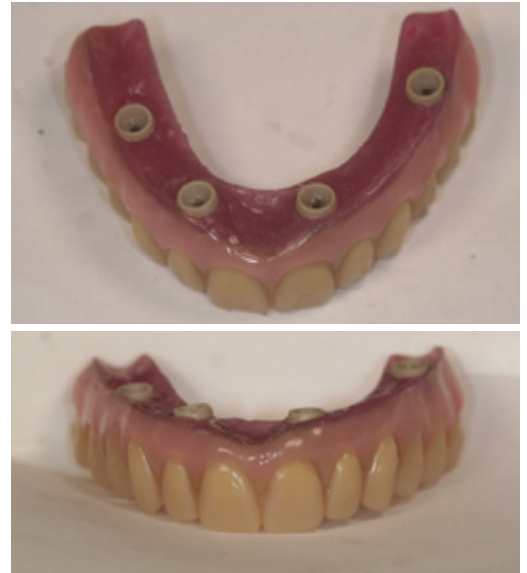

Set up of denture teeth for the final implant restoration.



Courtesy of Thomas Wade, CDT (USA)

The solid acrylic base serves as a stable base for the denture teeth. After finalizing the teeth set-up, the wax denture is prepared for a try-in: free access to the screw holes is important.

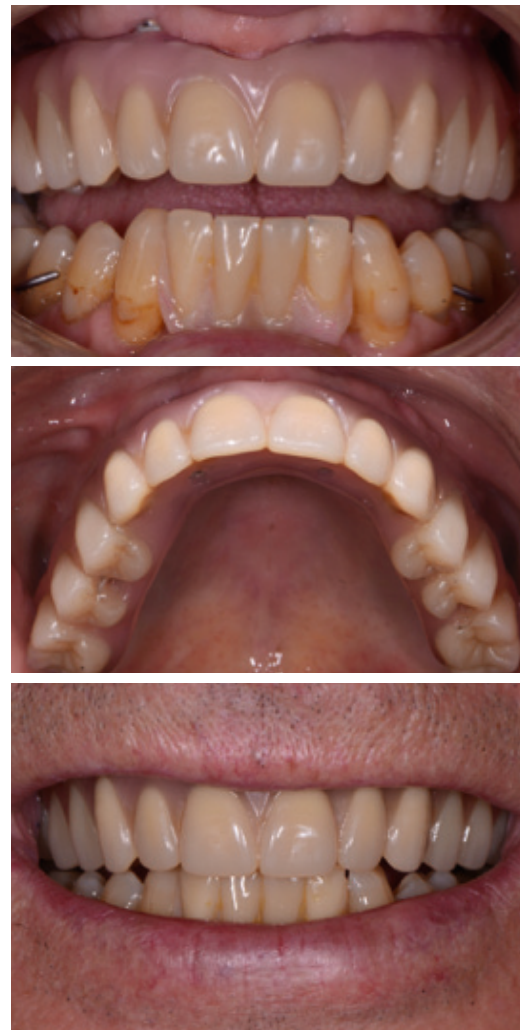

Courtesy of Thomas Wade, CDT (USA)

Diagnostic try-in

#### Appointment 4 – clinician

The diagnostic try-in is checked intra-orally for esthetics, function and phonetics. Also the lip and cheek support (extension of the denture base), the middle and smile line are controlled and adjusted if necessary.



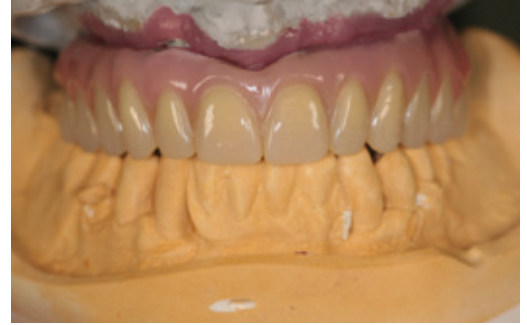Courtesy of Andrew Bock, DDS (USA)

## Appointment 4 – technician

---

After the completion of the diagnostic try-in, the lab scans the model and the diagnostic tooth set-up using the NobelProcera scanner. Within the NobelProcera CAD software the dental technician designs the implant bar to ideally support the tooth structure but also serving as a solid structure for the complete restoration. The design is send for production and a Titanium milled implant bar is returned to the lab.

The teeth set-up is transferred onto the bar structure and send to the dental office. Alternatively the implant bar framework can also be send without a teeth set-up to the dental office to check the passive fit and tension-free seating.



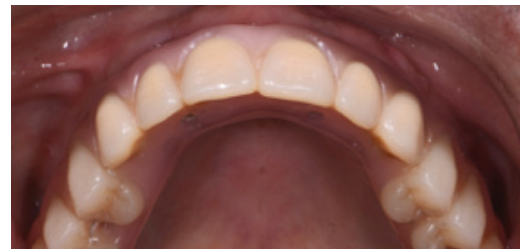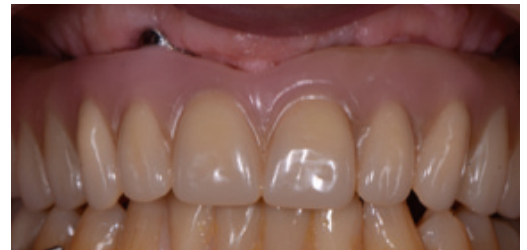Courtesy of Thomas Wade, CDT (USA)

Try-in of framework

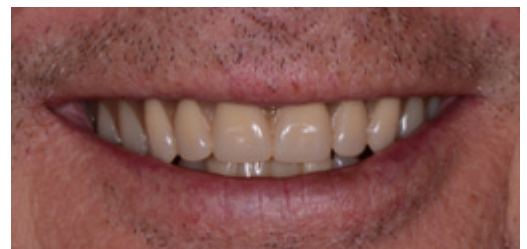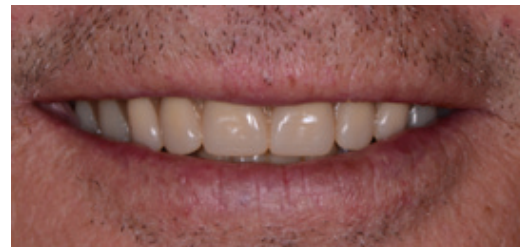## Appointment 5 – clinician

---

The passive fit of the framework is checked as well as a tension-free seat of the framework.

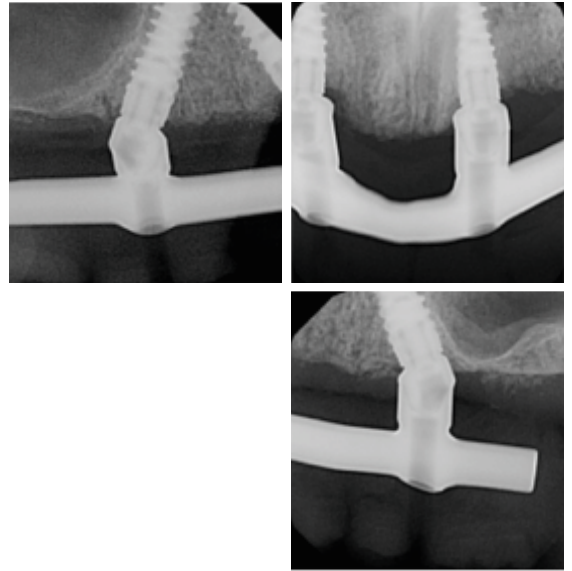


The final appearance of the tooth set-up is checked for esthetics, Function and phonetics.



Courtesy of Andrew Bock, DDS (USA)

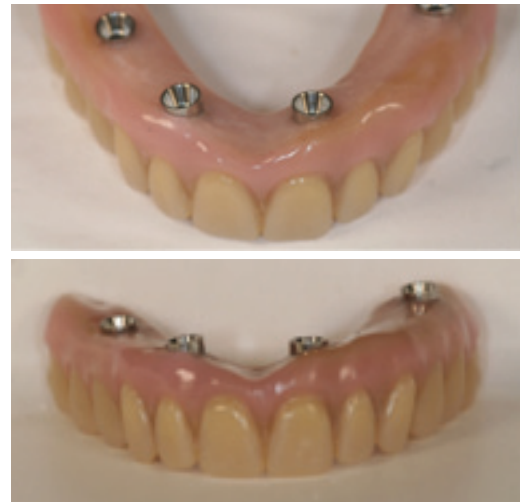Radiographic confirmation of passivity utilizing single-screw test.



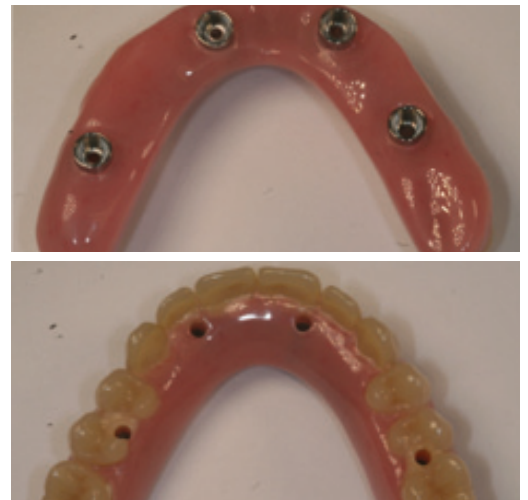Courtesy of Andrew Bock, DDS (USA)

#### Appointment 4 – technician

Case approved and returned to laboratory for final processing and finishing. Set-up removed from master cast for fabrication of processing cast.

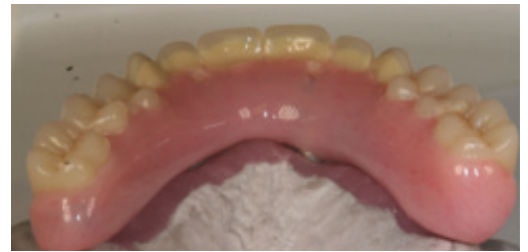
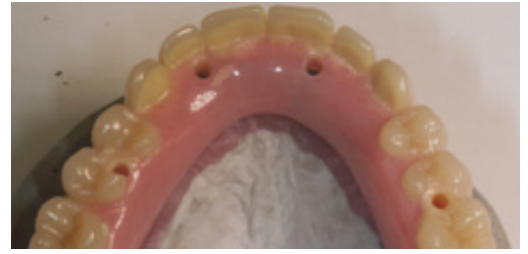
Case is finished to a hygienic, high-luster finish with attention to intaglio surface and round cylinders.

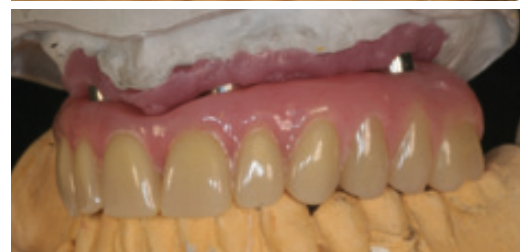
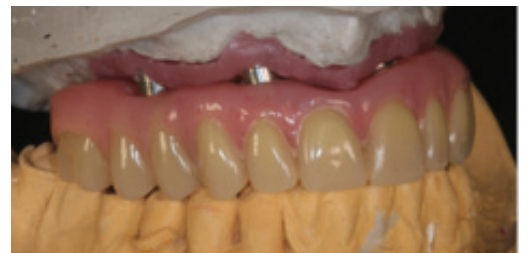
Courtesy of Thomas Wade, CDT (USA)

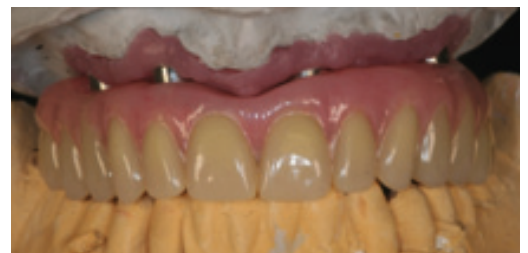Occlusal/lingual view.



Labial view.



Case successfully processed, returned to master cast for final adjustments, finished, and polished.

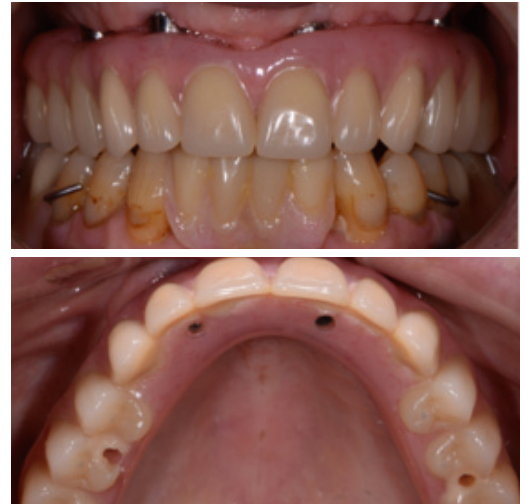

Courtesy of Thomas Wade, CDT (USA)

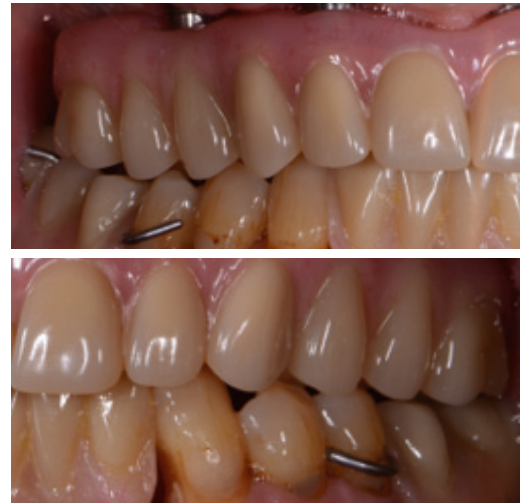Final seating

### Appointment 6 – clinician

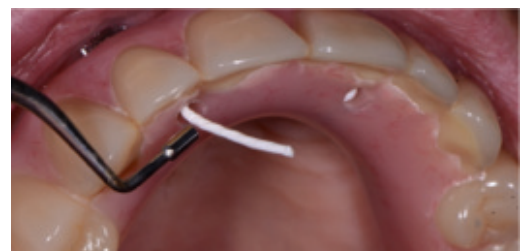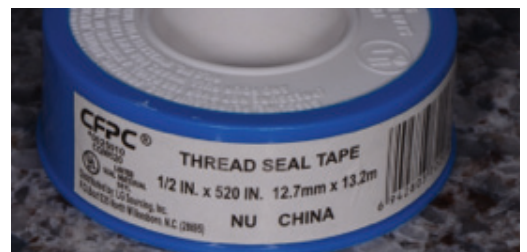Final prosthesis inserted with four new clinical prosthetic screws. Occlusion checked and equilibrated with hygiene access and phonetics verified.



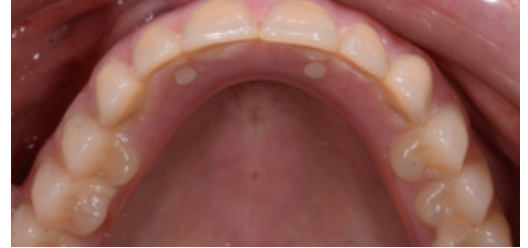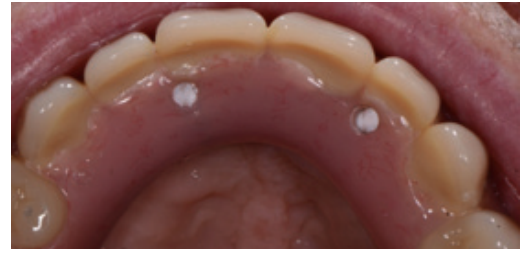Final prosthesis with soft tissue seal for proper phonetics and hygiene access.



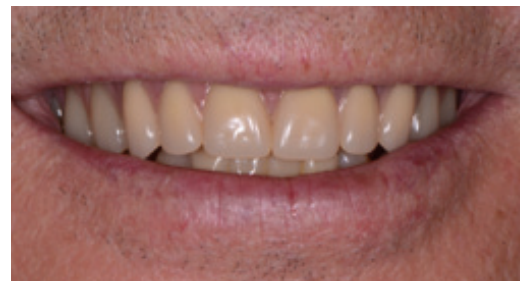Use of Teflon thread seal tape to fill majority of screw access channel minimizes bacterial contamination and growth. Densely compacted with condenser instrument and trimmed to within 2 mm of prosthesis surface.



Teflon screw access fillings in place and final shade-matched composite resin fillings, contoured and polished.



Completed prosthesis successfully seated.



Courtesy of Andrew Bock, DDS (USA)



