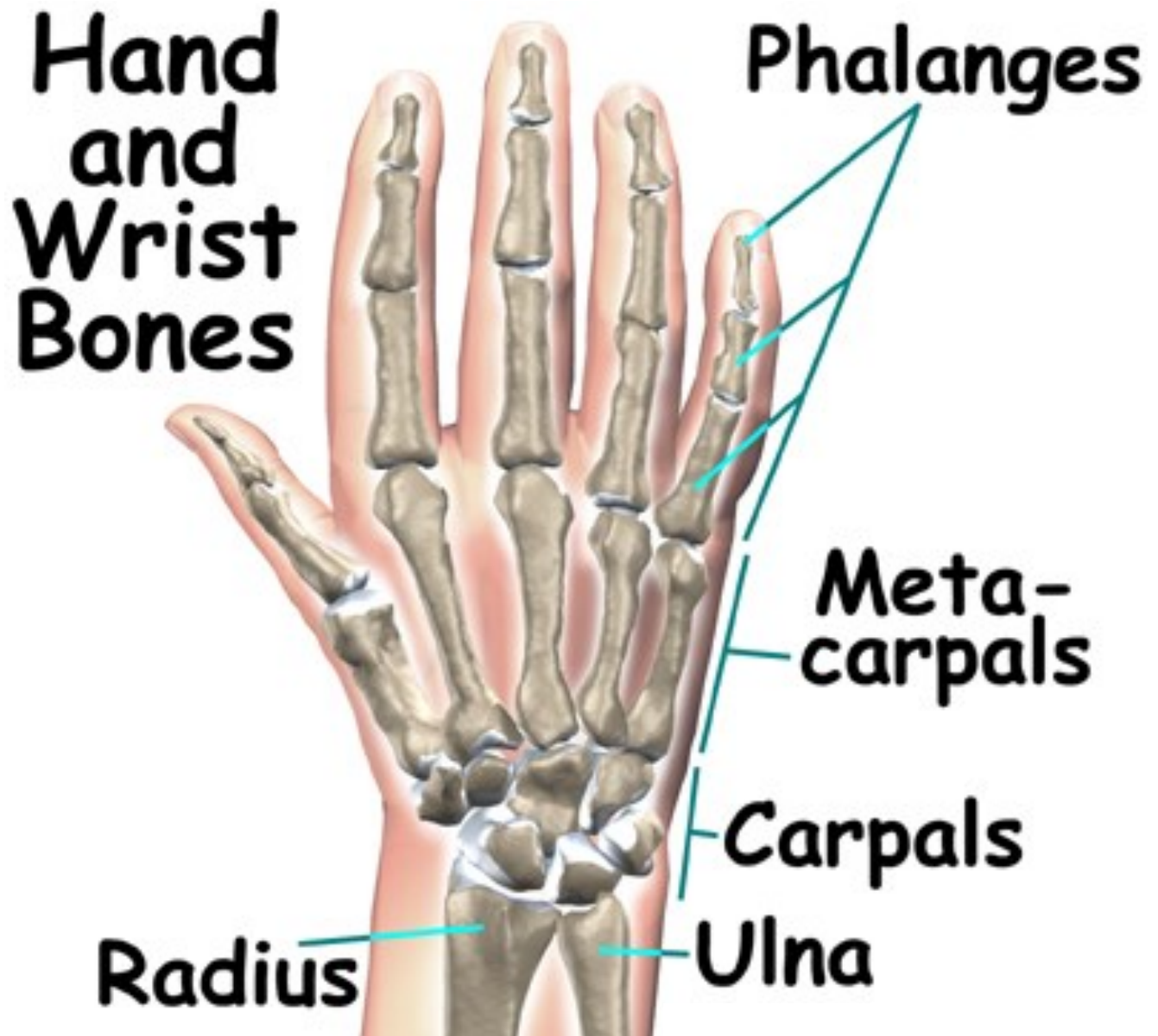

The  RAY Academy  
*of Texas*

# Unit II

## Radiographic Positioning and Procedures

# Hand and Wrist



# PA Hand

(posteroanterior)

- *Tabletop*
- *40" S.I.D*
- *8x10 Image Receptor*
- *Lengthwise*
- *54 kVp*
- *Suspended Respiration*

## Body Position:

Seated at the end of the table with the elbow flexed 90 degrees with the arm down flat.

## Part Position:

Hand open, fingers extended with the palm down flat against the IR, fingers slightly separated.

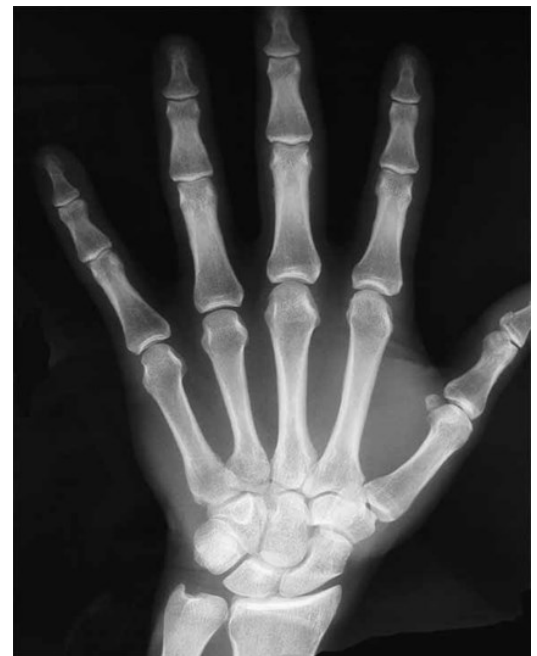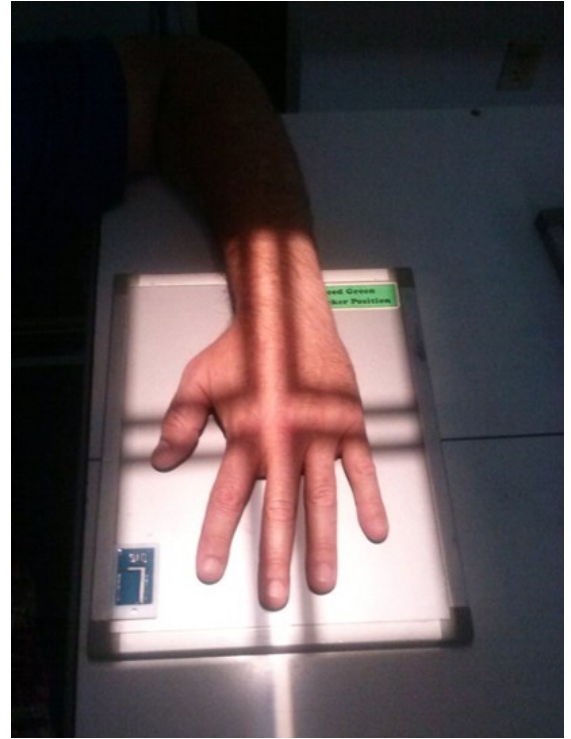## Central Ray:

Perpendicular and directed to the base of the 3<sup>rd</sup> metacarpal.

## \*Shield Reproductive Organs

### Evaluation Criteria:

- Entire hand including fingertips, carpals and distal radius and ulna
- No overlap of metacarpals or digits
- Soft tissue
- Boney trabeculation
- Collimation
- Correct side marker visible



# PA Oblique Hand

- *Tabletop*
- *40" S.I.D*
- *10x12 Image Receptor (1/2)*
- *Crosswise*
- *54 kVp*
- *Suspended Respiration*

## **Body Position:**

Seated at the end of the table with the elbow flexed 90 degrees with the arm down flat.

## **Part Position:**

Rotate the hand laterally 45 degrees. This can be accomplished by asking your patient to make the "OK" sign with their hand and placing it on the IR

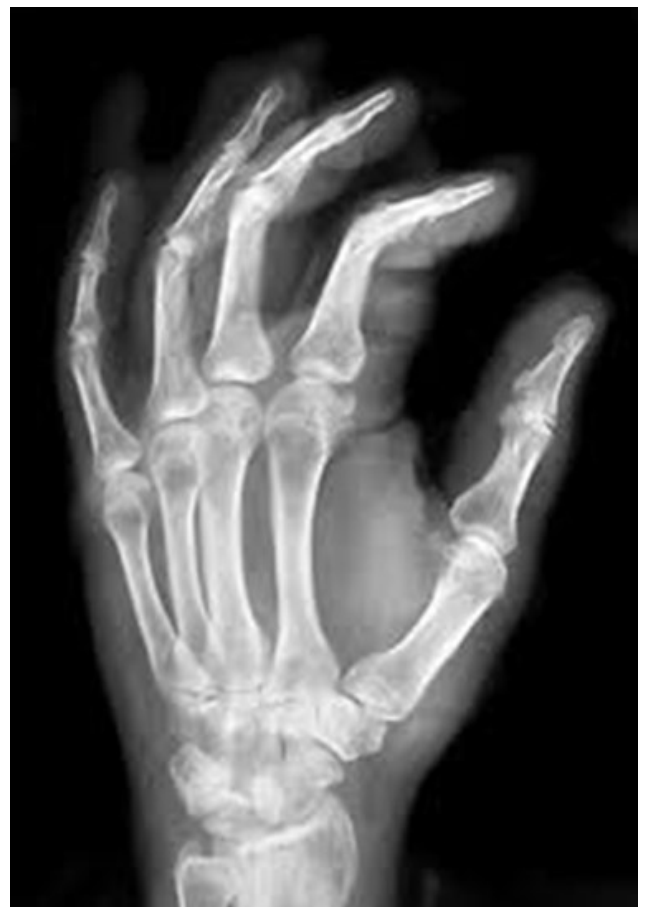## **\*Shield Reproductive Organs**

## **Central Ray:**

Perpendicular and directed to the base of the 3<sup>rd</sup> metacarpal.

## **Evaluation Criteria:**

- Little or no superimpositions of metacarpals.
- Slight superimposition of metacarpal heads and bases
- Open IP joint spaces
- Soft tissue
- Boney trabeculation
- Collimation
- Correct side marker visible



# Lateral Hand

- *Tabletop*
- *40" S.I.D*
- *8x10 Image Receptor*
- *Lengthwise*
- *54 kVp*
- *Suspended Respiration*

## Body Position:

Seated at the end of the table with the elbow flexed 90 degrees with the arm down flat.

## Part Position:

Medial aspect of the hand in contact with the IR. Hand perpendicular to the IR. 5<sup>th</sup> digit (thumb) slightly anterior so it is not superimposed over the metacarpals.

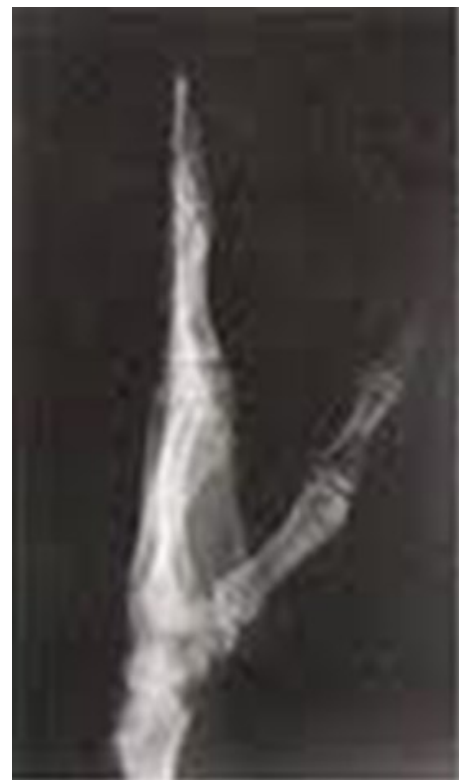## \*Shield Reproductive Organs

## Central Ray:

Perpendicular and directed to the base of the 3<sup>rd</sup> metacarpal.

## Evaluation Criteria:

- Superimposition of the 2<sup>nd</sup> through 5<sup>th</sup> metacarpals and phalanges
- The thumb is seen away from the metacarpals
- Soft tissue
- Boney trabeculation
- Collimation
- Correct side marker visible



# PA Wrist

## (posteroanterior)

- *Tabletop*
- *40" S.I.D*
- *10x12 Image Receptor (1/3)*
- *Crosswise*
- *60 kVp*
- *Suspended Respiration*

### **Body Position:**

Seated at the end of the table with the elbow flexed 90 degrees with the arm down flat.

### **Part Position:**

Anterior surface of the wrist in contact with the IR. Fingers curled under the hand.

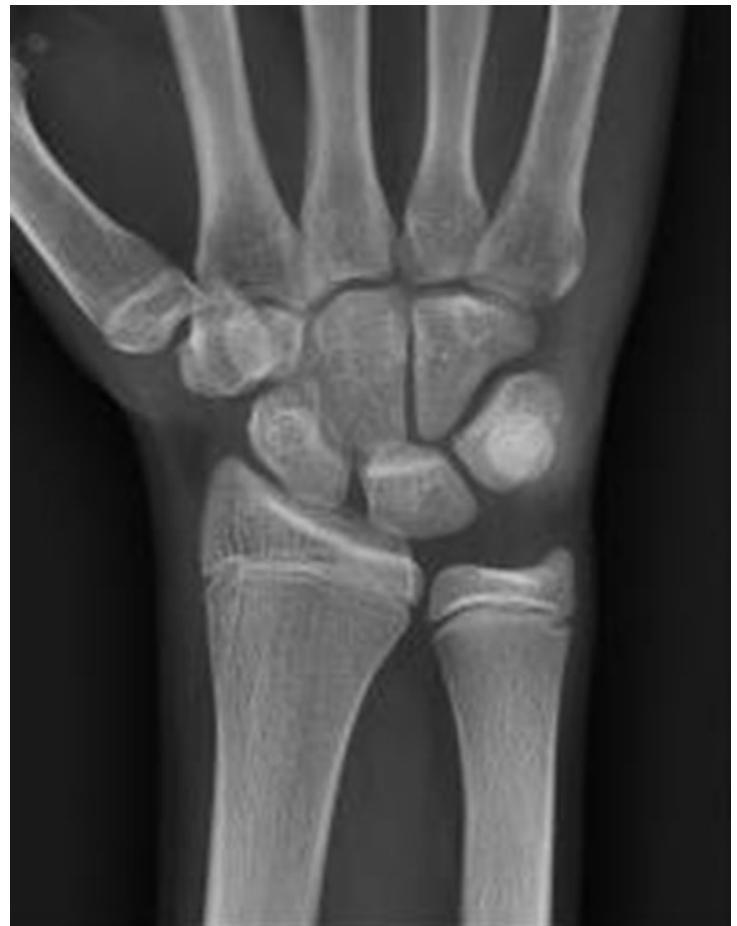### **Central Ray:**

Perpendicular to the mid-metacarpal area.

**\*Shield Reproductive Organs**

### **Evaluation Criteria:**

- Distal radius and ulna, carpal bones and proximal metacarpals.
- Soft tissue
- Boney trabeculation
- Collimation
- Correct side marker visible



# PA Oblique Wrist

- *Tabletop*
- *40" S.I.D*
- *10x12 Image Receptor (1/3)*
- *Crosswise*
- *60 kVp*
- *Suspended Respiration*

## **Body Position:**

Seated at the end of the table with the elbow flexed 90 degrees with the arm down flat.

## **Part Position:**

Anteromedial surface of the wrist in contact with the IR so that the coronal plane of the wrist forms a 45 degree angle.

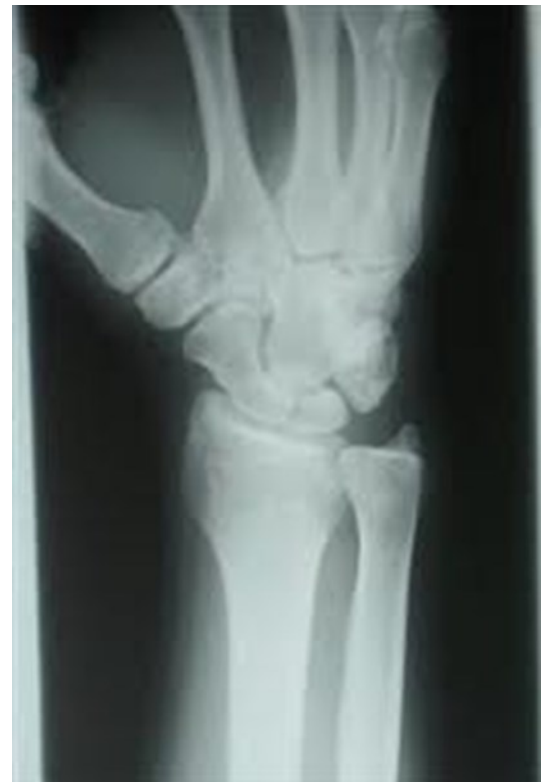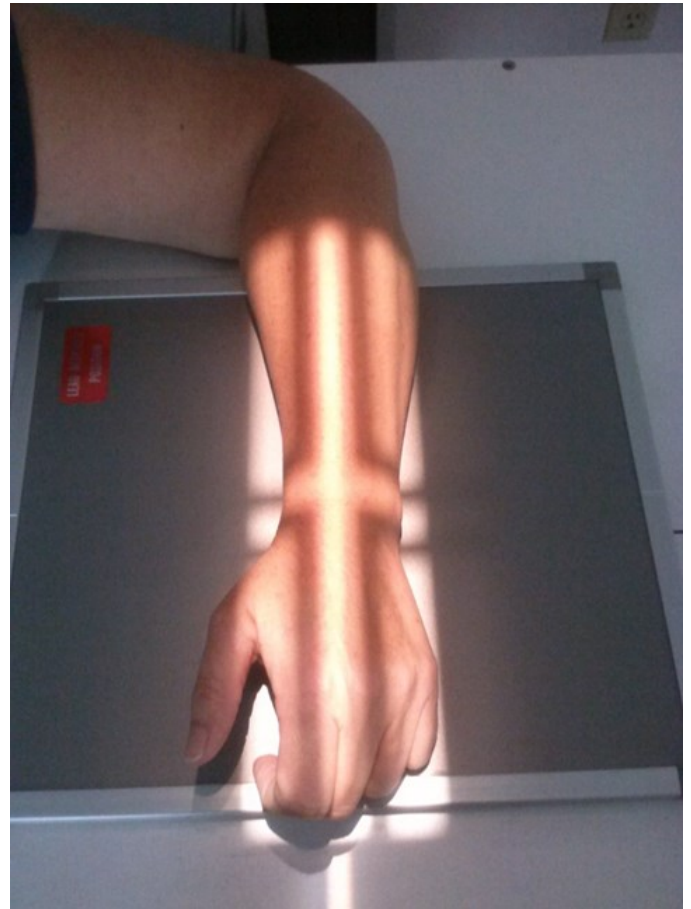
## **\*Shield Reproductive Organs**

## **Central Ray:**

Perpendicular to the mid-metacarpal area.

## **Evaluation Criteria:**

- Distal radius and ulna, carpal bones and proximal metacarpals.
- Trapezium at distal end of scaphoid with defined joint space
- Slight overlap of distal radius and ulna
- Soft tissue
- Boney trabeculation
- Collimation
- Correct side marker visible



# Lateral Wrist

- *Tabletop*
- *40" S.I.D*
- *10x12 Image Receptor (1/3)*
- *Crosswise*
- *60 kVp*
- *Suspended Respiration*

## **Body Position:**

Seated at the end of the table with the elbow flexed 90 degrees with the arm down flat.

## **Part Position:**

Anteromedial surface of the wrist in contact with the IR so that the coronal plane of the wrist forms a 90 degree angle.

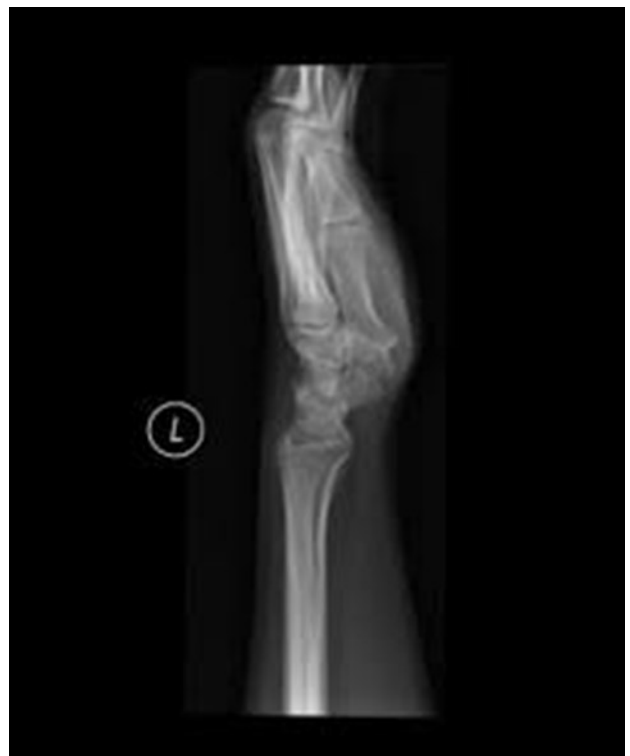
## **Central Ray:**

Perpendicular to the mid-metacarpal area.

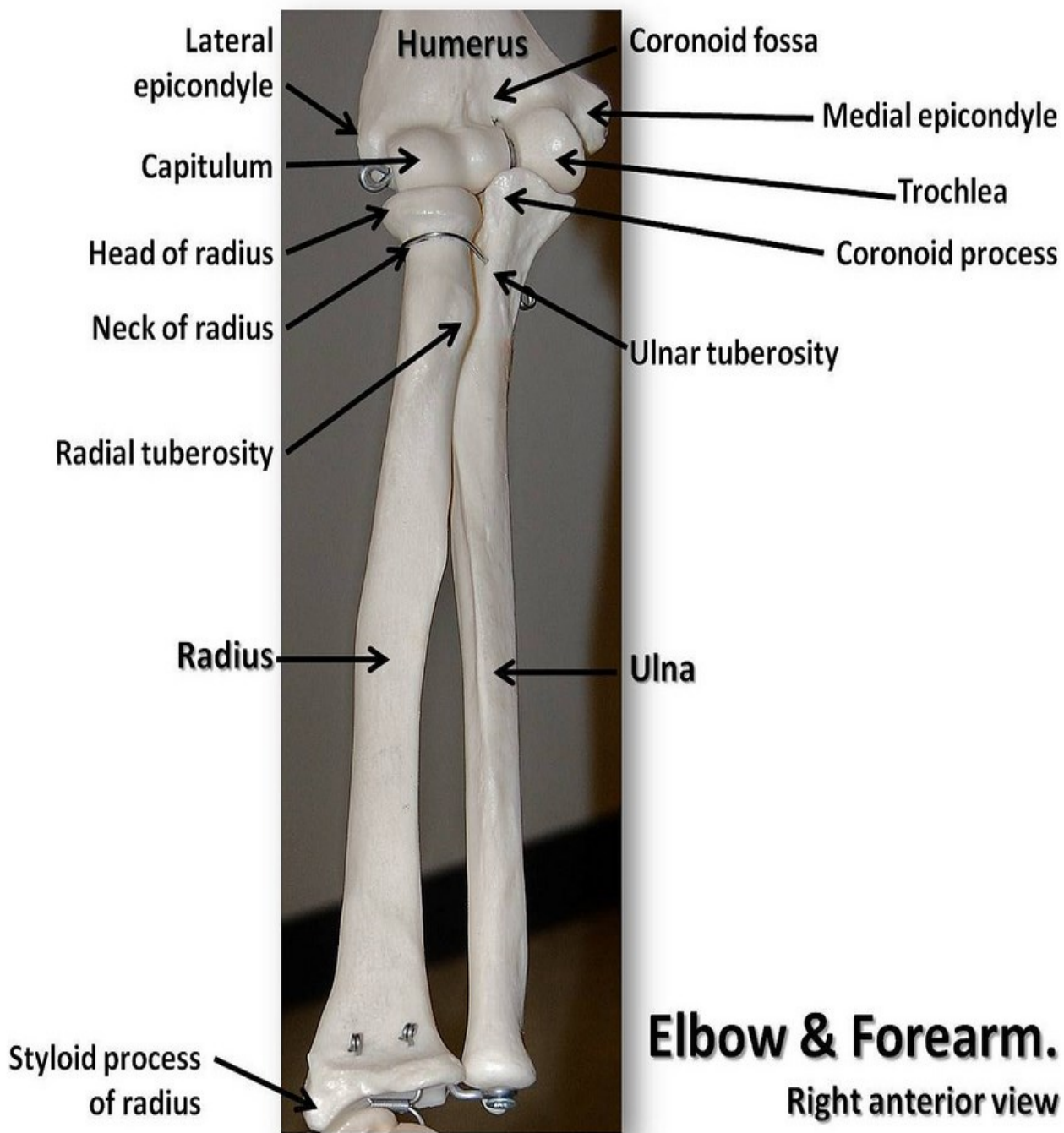
## **\*Shield Reproductive Organs**

## **Evaluation Criteria:**

- Distal radius and ulna, carpal bones and proximal metacarpals.
- Superimposed distal radius and ulna
- Superimposed distal radius and metacarpals
- Soft tissue
- Boney trabeculation
- Collimation
- Correct side marker visible



# Forearm and Elbow



# AP Forearm

- *Tabletop*
- *40" S.I.D*
- *14x17 Image Receptor (1/2)*
- *lengthwise*
- *60 kVp*
- *Suspended Respiration*

## **Body Position:**

**Seat the patient seated facing the table and low enough that the entire arm is in the same plane**

## **Part Position:**

**Supinate the hand, extend the elbow and make sure the elbow and wrist are both included.**

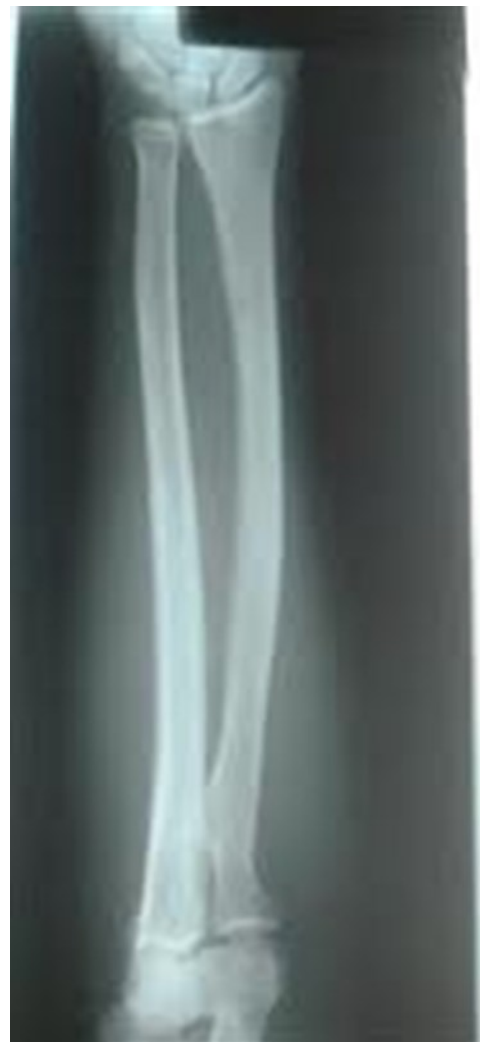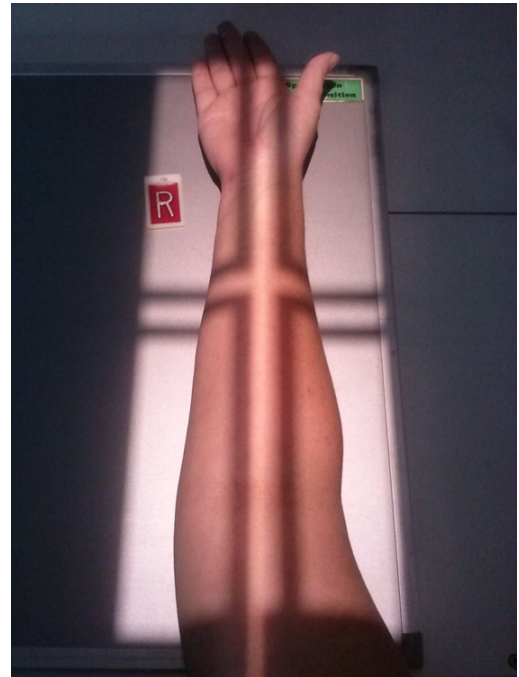
## **Central Ray:**

**Perpendicular to the midpoint of the forearm**

## **\*Shield Reproductive Organs**

## **Evaluation Criteria:**

- **Show Collimation**
- **Wrist and elbow**
- **Slight superimposition of radial head, neck and tuberosity over distal ulna**
- **No shape distortion of humeral epicondyles**
- **Open elbow joint if shoulder is placed in the same plane**
- **Open radioulnar space**
- **Even density throughout**



# Lateral Forearm

- *Tabletop*
- *40" S.I.D*
- *14x17 Image Receptor (1/2)*
- *lengthwise*
- *60 kVp*
- *Suspended Respiration*

## Body Position:

- **Seat the patient seated facing the table and low enough that the entire arm is in the same plane**

## Part Position:

- **Flex elbow 90 degrees and place forearm over the correct half of the image receptor. Ensure entire wrist and elbow are included. Place hand in true lateral position with the thumb up.**

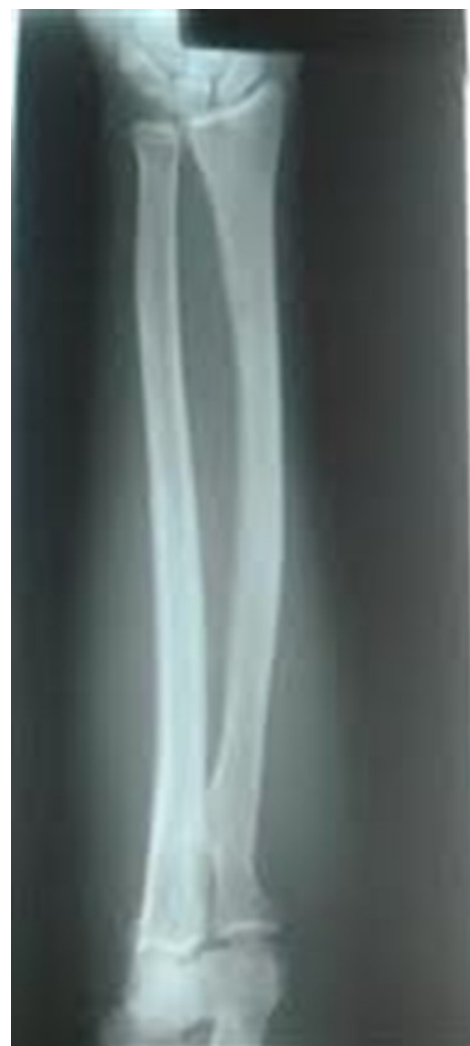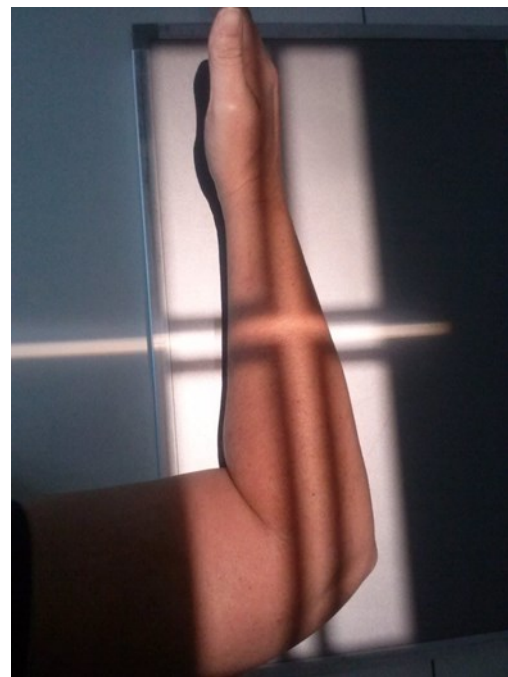
## Central Ray:

- **Perpendicular to the midpoint of the forearm**

## \*Shield Reproductive Organs

## Evaluation Criteria:

- **Show Collimation**
- **Wrist and elbow**
- **Superimposition of distal radius and ulna**
- **Superimposition of radial head and corinoid process**
- **Elbow flexed 90 degrees**
- **Open elbow joint if shoulder is placed in the same plane**
- **Radial tuberosity facing anteriorly**
- **Superimposed humeral epicondyles**
- **Soft tissue and boney tabeculation**
- **Correct side marker visible**



# AP Elbow

- *Tabletop*
- *40" S.I.D*
- *10x12 Image Receptor (1/2)*
- *Crosswise*
- *60 kVp*
- *Suspended Respiration*

## Body Position:

- **Seat the patient seated facing the table and low enough that the entire arm is in the same plane**

## Part Position:

**Supinate the hand, extend the elbow**



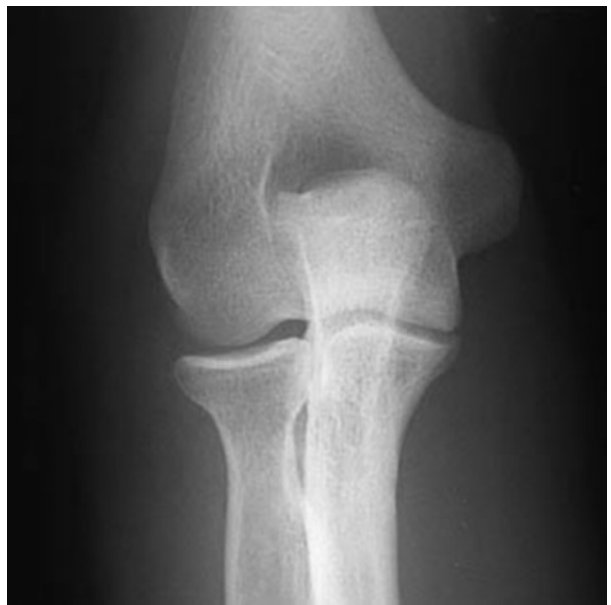## Central Ray:

**Perpendicular to the elbow joint**

**\*Shield Reproductive Organs**

## Evaluation Criteria:

- **Collimation**
- **Radial head, neck and tuberosity slightly superimposed over the proximal ulna**
- **Elbow joint open and centered**
- **No rotation**
- **Soft tissue and boney trabeculation**
- **Demonstration of correct side marker**



# Lateral Elbow

- *Tabletop*
- *40" S.I.D*
- *10x12 Image Receptor (1/2)*
- *Crosswise*
- *60 kVp*
- *Suspended Respiration*

## Body Position:

- **Seat the patient seated facing the table and low enough that the entire arm is in the same plane**

## Part Position:

- **Flex elbow 90 degrees and place forearm over the correct half of the image receptor. Place hand in true lateral position with the thumb up.**

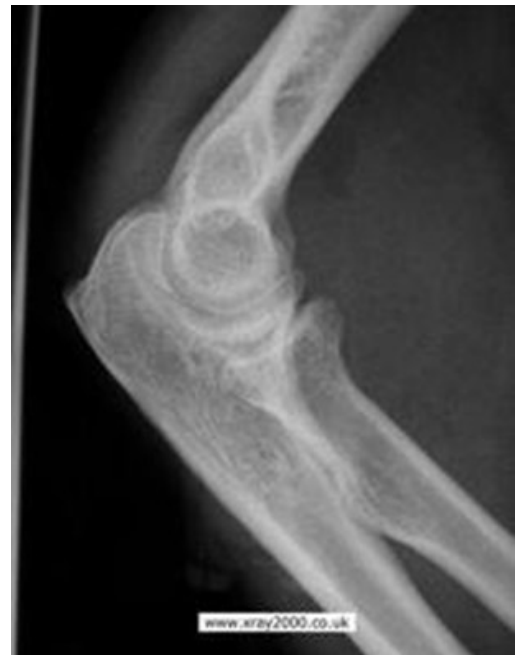## Central Ray:

**Perpendicular to the elbow joint**

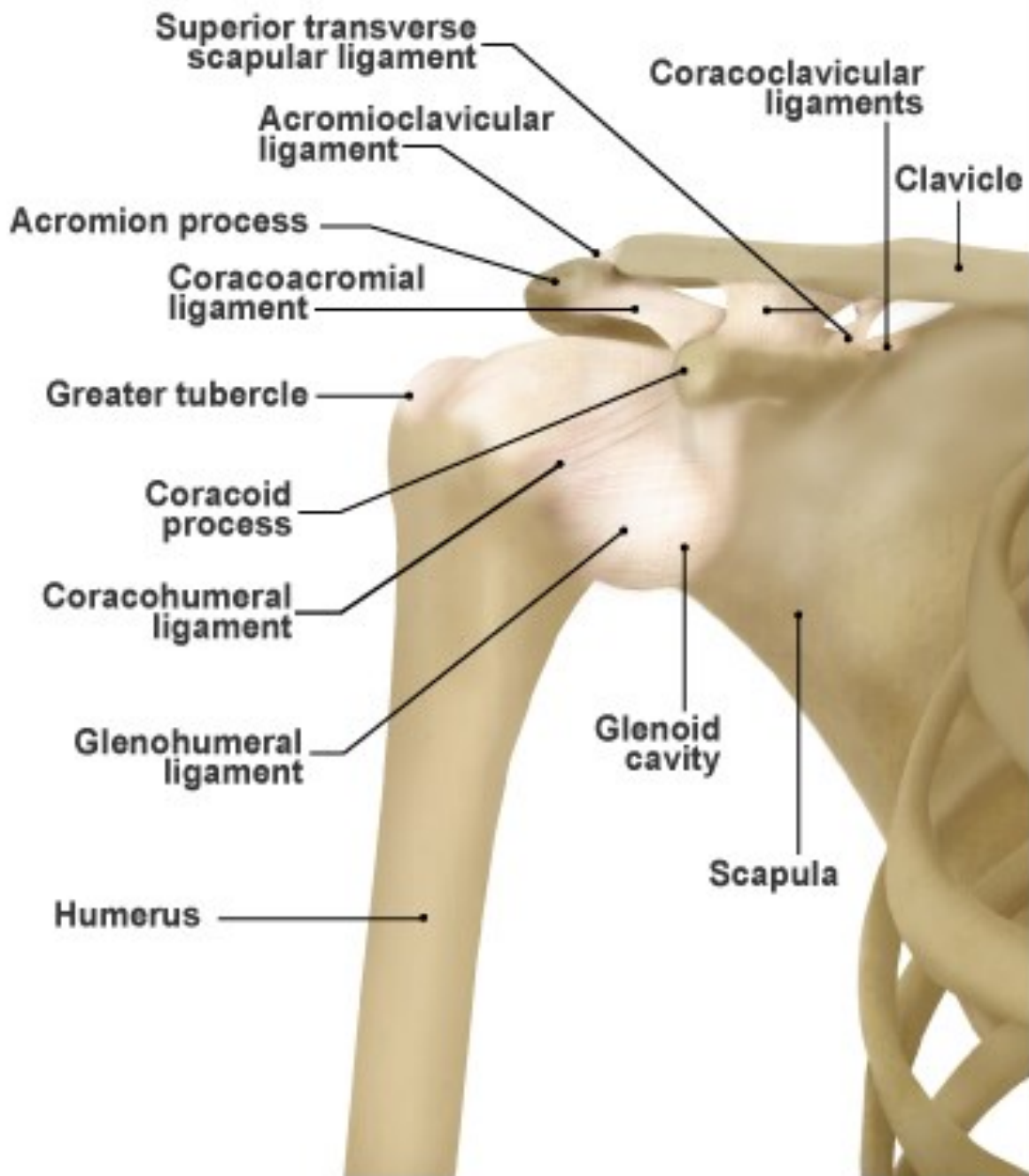
**\*Shield Reproductive Organs**

## Evaluation Criteria:

- **Collimation**
- **Open and centered elbow joint**
- **Elbow flexed 90 degrees**
- **Superimposed Humeral epicondyles**
- **Anterior radial tuberosity**
- **Radial head partially superimposing the coronoid process**
- **Olecranon process in profile**
- **Soft tissue and boney trabeculation**
- **Visualized correct side marker**



# Skeletal Anatomy of the Shoulder



# AP Humerus

- *Bucky/Grid*
- *40" S.I.D*
- *14x17 Image Receptor*
- *Length wise*
- *70 kVp*
- *Suspended Respiration*

## Patient Position:

Pt. upright facing the x-ray tube.

## Part Position:

Top margin of the image receptor about an inch and a half above the humeral head. Abduct the arm slightly and supinate the hand. Humeral epicondyles parallel with the image receptor

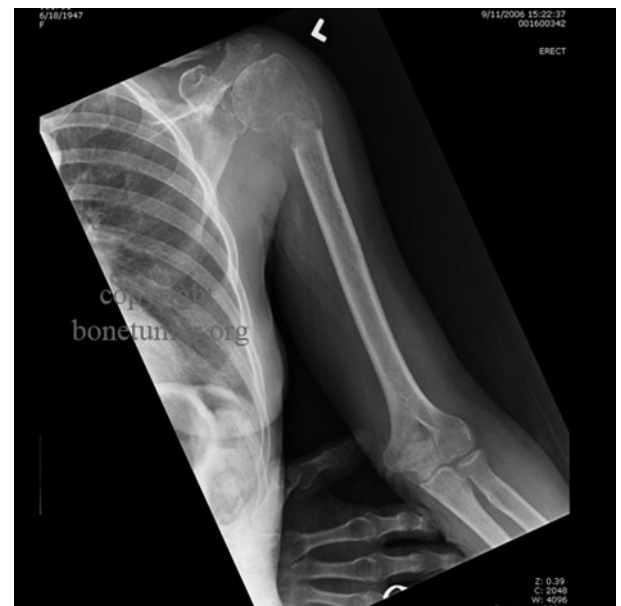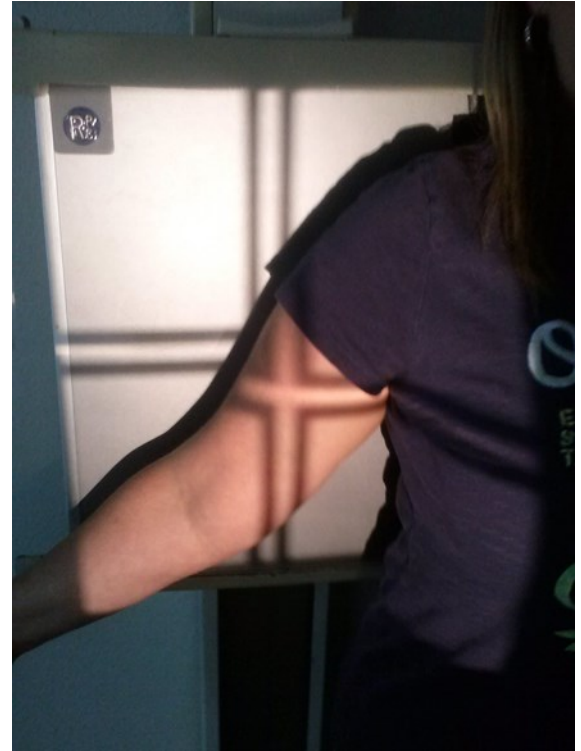
## Central ray:

Perpendicular to the mid portion of the humerus and the center of the IR.

**\* Shield reproductive organs**

## Evaluation Criteria:

- Collimation
- Elbow and shoulder joints
- No rotation of epicondyles
- Humeral head and greater tubercle in profile
- Shadow of lesser tubercle
- Equal density on entire radiograph
- Visibility of correct side marker



# Lateral Humerus

- *Bucky/Grid*
- *40" S.I.D*
- *14x17 Image Receptor*
- *Length wise*
- *70 kVp*
- *Suspended Respiration*

## Patient Position:

Pt. upright facing the x-ray tube.

## Part Position:

Top margin of the image receptor about an inch and a half above the humeral head. Flex arm about 90 degrees, place the back of the hand on the side of the patients hip. Humeral epicondyles perpendicular with the image receptor

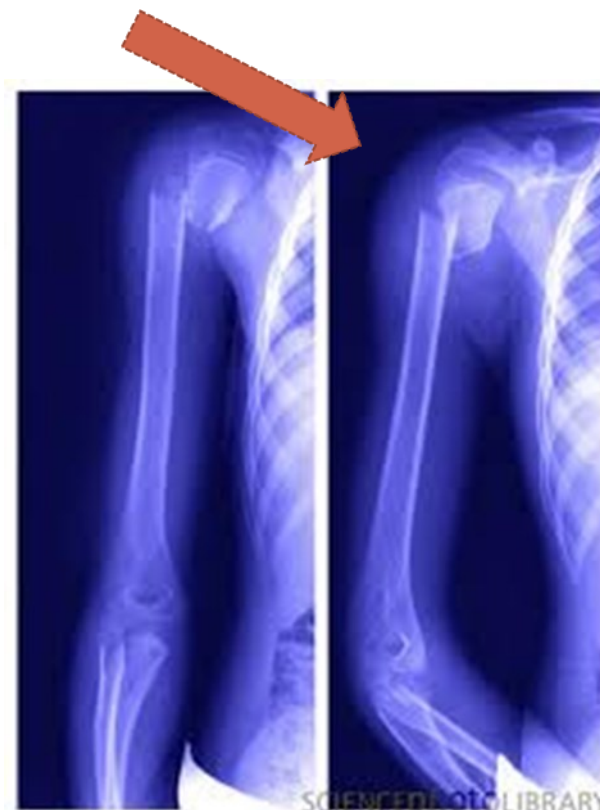## Central ray:

Perpendicular to the mid portion of the humerus and the center if the IR.

**\* Shield reproductive organs**

## Evaluation Criteria:

- Collimation
- Elbow and shoulder joints
- Superimposition of epicondyles
- Lesser tubercle in profile
- Shadow of lesser tubercle
- Equal density on entire radiograph
- Visibility of correct side marker



# AP External Rotation Shoulder

- *Bucky/Grid*
- *40" S.I.D*
- *10x12 Image Receptor*
- *Cross wise*
- *70 kVp*
- *Suspended Respiration*

## Patient Position:

Pt. upright or supine facing the x-ray tube.

## Part Position:

Center IR 1 inch inferior to the coracoid process, hand supinated and arm slightly abducted

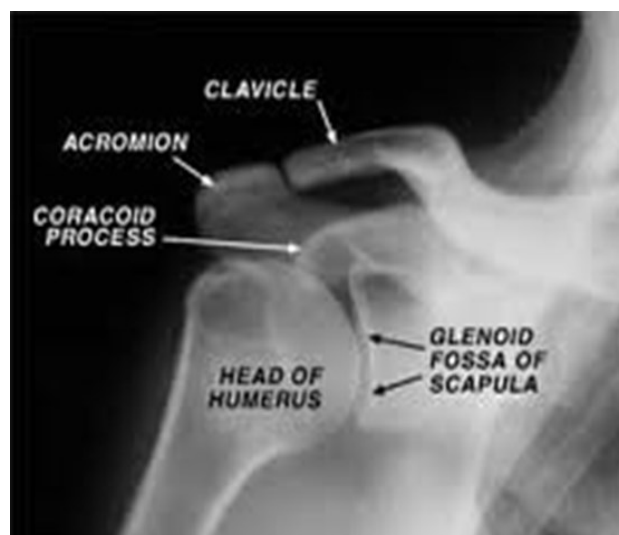## Central ray:

Perpendicular to a point 1 inch inferior to the coracoid process

**\* Shield reproductive organs**

## Evaluation Criteria:

- Humeral head in profile
- Greater tubercle in profile on lateral aspect of humerus
- Scapulohumeral joint with slight superimposition
- Superior scapula, lateral half of clavicle and proximal humerus
- Outline of lesser tubercle between humeral head and greater tubercle
- Collimation
- Equal density on entire radiograph
- Visibility of correct side marker



# AP Internal Rotation Shoulder

- *Bucky/Grid*
- *40" S.I.D*
- *10x12 Image Receptor*
- *Cross wise*
- *70 kVp*
- *Suspended Respiration*

## Patient Position:

Pt. upright or supine facing the x-ray tube.

## Part Position:

Center IR 1 inch inferior to the coracoid process, arm rotated with the back of the hand on the side of the hip.

## Central ray:

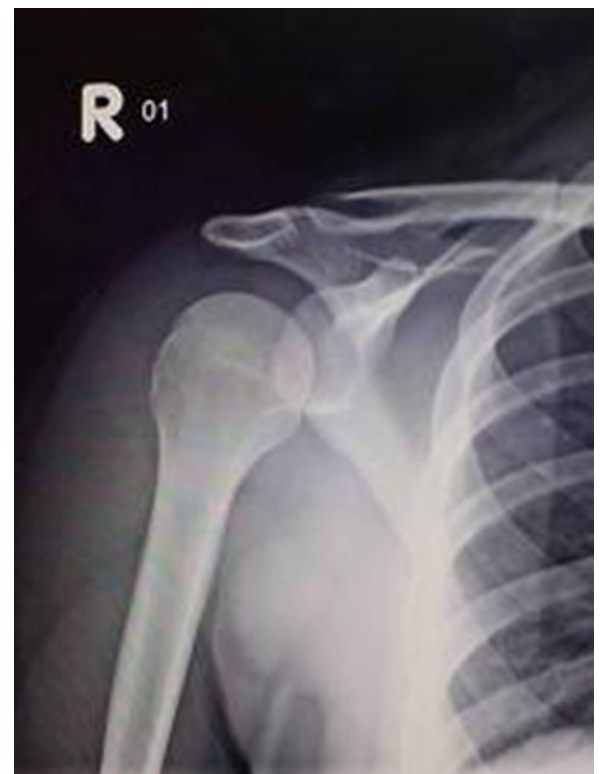Perpendicular to a point 1 inch inferior to the coracoid process

**\* Shield reproductive organs**



## Evaluation Criteria:

- Lesser tubercle in profile pointing medially
- Outline of greater tubercle superimposing humeral head
- More superimposition of the glenoid cavity than the external rotation
- Superior scapula, lateral half of clavicle and proximal humerus
- Collimation
- Equal density on entire radiograph
- Visibility of correct side marker



# AP Shoulder Scapular "Y"

- *Bucky/Grid*
- *40" S.I.D*
- *10x12 Image Receptor*
- *Length wise*
- *80 kVp*
- *Suspended Respiration*

## Patient Position:

Radiograph the patient in the upright body position.

## Part Position:

With the anterior surface of the affected shoulder against the IR rotate the patient 45-60 degrees so that the scapula is perpendicular to the IR. Place the center of the IR at the scapulohumeral joint

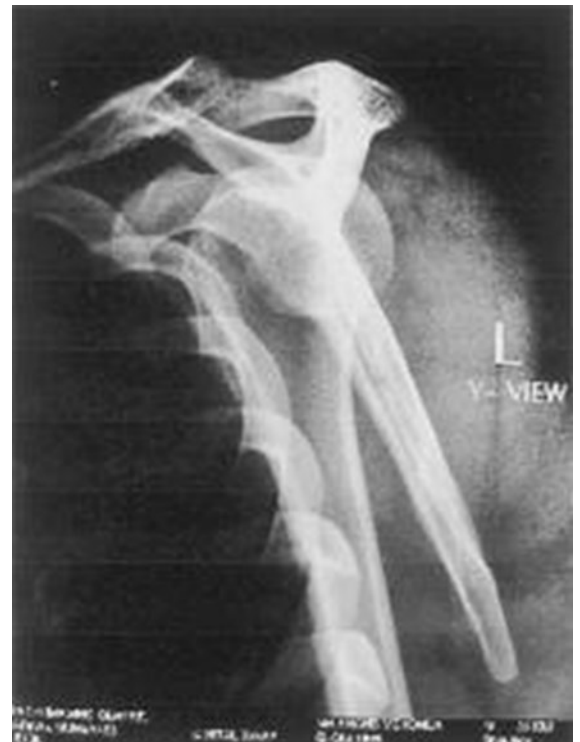## Central ray:

Perpendicular to the scapulohumeral joint

**\* Shield reproductive organs**

## Evaluation Criteria:

- Humeral head and glenoid cavity superimposed
- Humeral shaft and scapular body superimposed
- No superimposition of the scapular body over the thorax
- Acromion projected laterally and free of superimposition
- Acromion superimposed or inferior to the clavicle
- Collimation
- Equal density on entire radiograph
- Visibility of correct side marker



# AP Clavicle

- *Bucky/Grid*
- *40" S.I.D*
- *10x12 Image Receptor*
- *Cross wise*
- *70 kVp*
- *Suspended Respiration*

## Patient Position:

Pt. upright or supine facing the x-ray tube.

## Part Position:

Center clavicle to midline of the IR. Allow the arms to hang freely so that the shoulders are level.

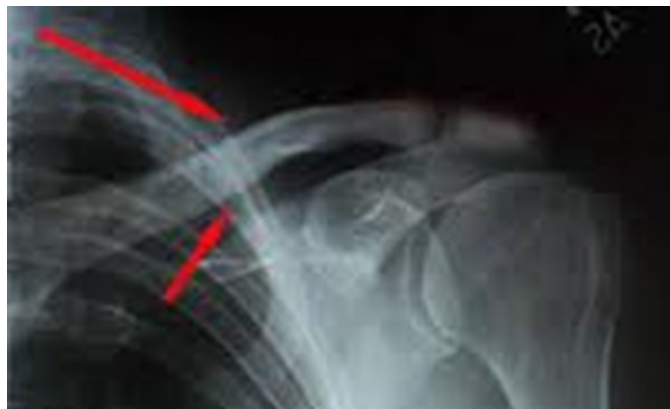
## Central ray:

Perpendicular to the midshaft of the clavicle.  
Collimate to approximately 12" wide by 8 " high

**\* Shield reproductive organs**

## Evaluation Criteria:

- Entire clavicle centered on image
- Lateral half of the clavicle above the scapula, with the medial half superimposing the thorax
- Collimation
- Equal density on entire radiograph
- Visibility of correct side marker



# AP Axial Clavicle

- *Bucky/Grid*
- *40" S.I.D*
- *10x12 Image Receptor*
- *Cross wise*
- *70 kVp*
- *Suspended Respiration*

## **Patient Position:**

Pt. upright or supine facing the x-ray tube.

## **Part Position:**

Center clavicle to midline of the IR. Allow the arms to hang freely so that the shoulders are level.

## **Central ray:**

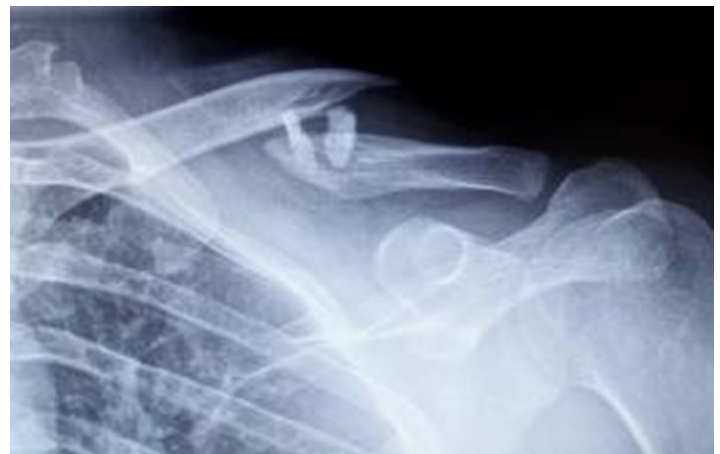15-30 degree cephalic angulation directed to the midshaft of the clavicle

**\* Shield reproductive organs**

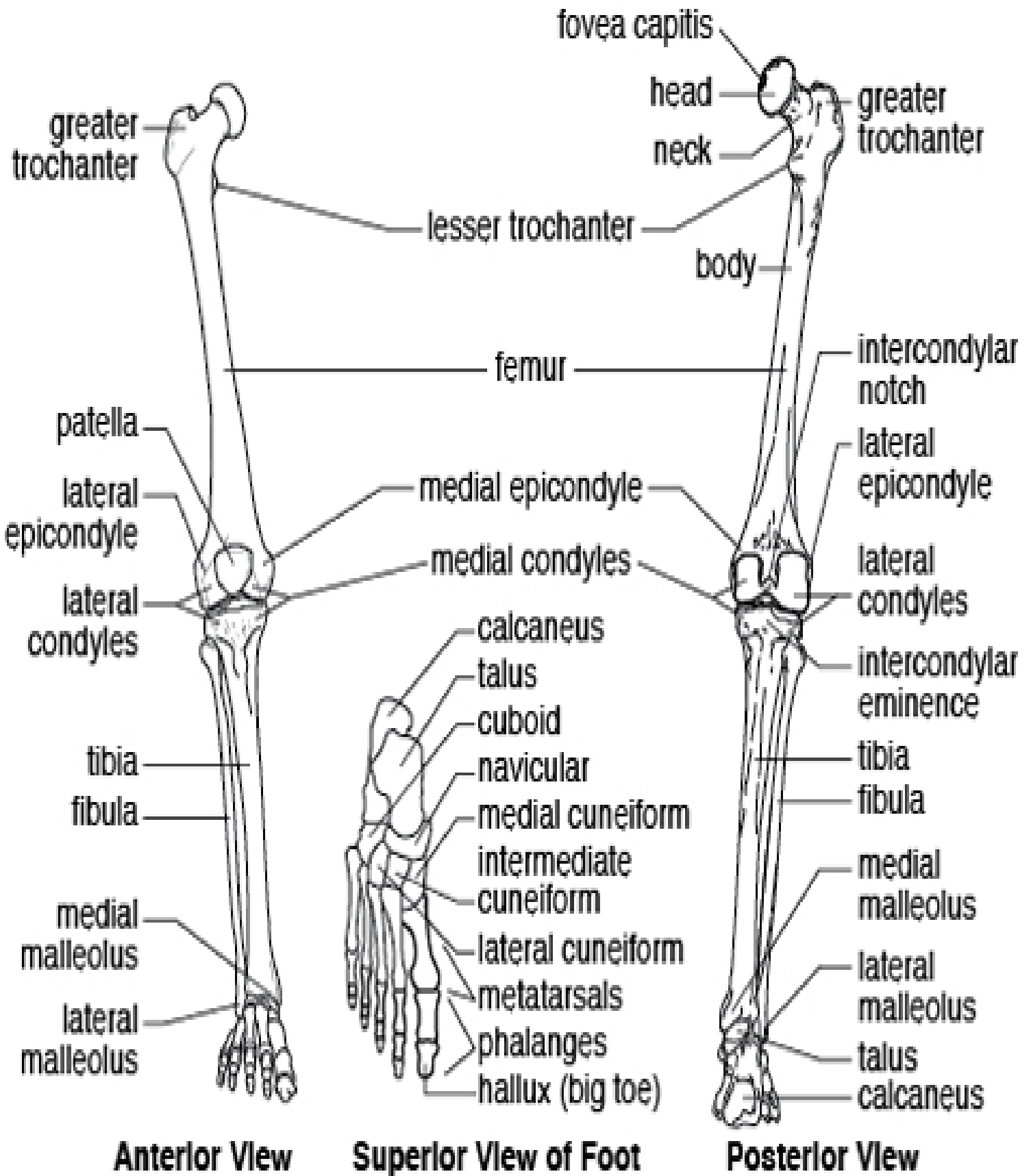


## **Evaluation Criteria:**

- Most of the clavicle projected above the ribs and scapula with the medial end overlapping the first or second rib
- Clavicle horizontal in placement
- Entire clavicle with AC and SC joints
- Collimation
- Equal density on entire radiograph
- Visibility of correct side marker




# Lower Extremities



# AP Axial Foot

- *Table top*
- *40" S.I.D*
- *10x12 Image Receptor(1/2)*
- *Length wise*
- *60 kVp*
- *Suspended*



## Body Position:

Patient seated or supine on the x-ray table with the knee flexed and the plantar surface of the foot flat on the table.

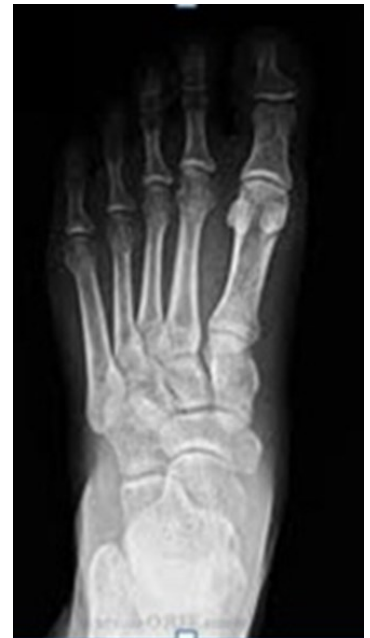## Part Position:

Place the long axis of the foot along the long axis of the unmasked axis of the image receptor, centered to the base of the 3<sup>rd</sup> metatarsal.

## Central Ray:

10 degrees toward the heel entering at the base of the third metatarsal.

**\*Shield the reproductive organs**

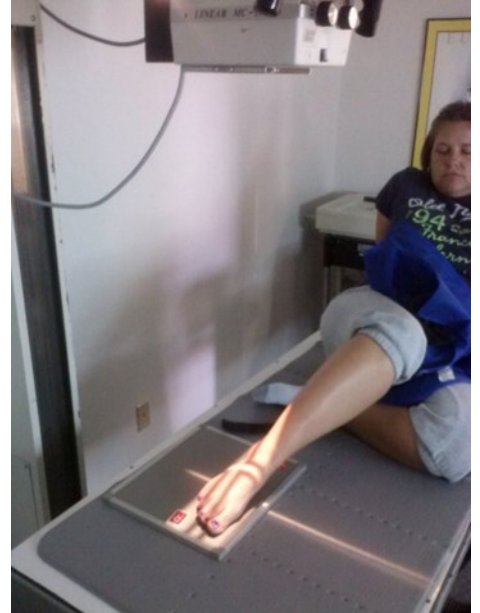

## Evaluation Criteria:

- No rotation
- Equal amount of space between the adjacent midshafts between the second through fourth metacarpals.
- Overlap the second through fifth metacarpal bases
- Demonstration of the phalanges, tarsal distal to the talus, metatarsals, cuneiforms, cuboid and navicular.
- Boney trabeculation
- Collimation
- Correct side marker visible

# Oblique Foot

- *Table top*
- *40" S.I.D*
- *10x12 Image Receptor*
- *cross wise*
- *60 kVp*
- *Suspended*



## **Body Position:**

Patient seated or supine on the x-ray table with the knee flexed. Rotate the foot medially until the plantar surface of the foot forms a thirty degree angle with the image receptor.

## **Part Position:**

Place the long axis of the foot along the long axis of the unmasked axis of the image receptor, centered to the base of the 5th metatarsal.

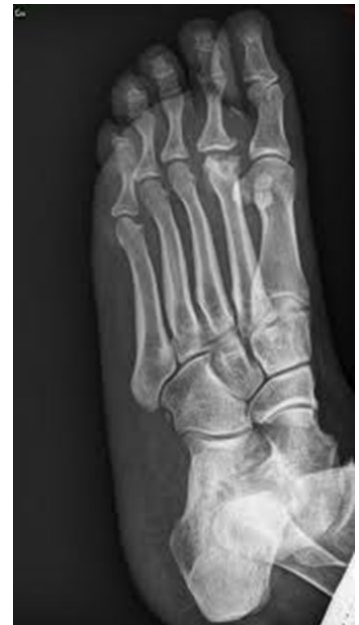## **Central Ray:**

Perpendicular to the base of the 3<sup>rd</sup> metatarsal

**\*Shield the reproductive organs**

## **Evaluation Criteria:**

- Separate bases of the 1<sup>st</sup> and 2<sup>nd</sup> metatarsals
- No superimposition of the medial and intermediate cuneiforms
- Clearly demonstrated navicular
- Phalanges, metatarsals and tarsals
- Bony trabeculation
- Collimation
- Correct side marker



# Lateral Foot

- *Table top*
- *40" S.I.D*
- *10x12 Image Receptor*
- *Cross wise*
- *60 kVp*
- *Suspended*

## **Body Position:**

Lateral recumbent toward the affected side.

## **Part Position:**

Elevate the knee enough to place the plantar surface of the foot perpendicular to the IR.

Dorsiflex the foot to place it at a 90 degree angle to the lower leg. Adjust the IR to include the entire foot from the toes to the calcaneus and including the distal tib/fib.

## **Central Ray:**

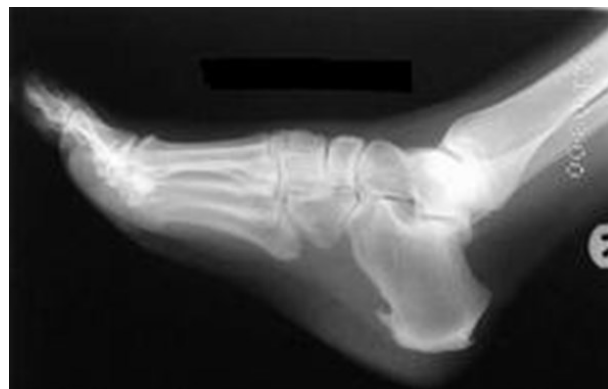Perpendicular to the base of the first metatarsal

**\*Shield the reproductive organs**



## **Evaluation Criteria:**

- Separate bases of the 1<sup>st</sup> and 2<sup>nd</sup> metatarsals
- Metatarsals nearly all superimposed
- Distal tib/fib superimposed
- Tibiotalar joint
- Uniform adequate density
- Boney trabeculation
- Collimation
- Correct side marker



# AP Ankle

- *Table top*
- *40" S.I.D*
- *10x12 Image Receptor (1/2)*
- *Cross wise*
- *60 kVp*
- *Cross wise*

## **Body Position:**

Supine with affected leg fully extended.

## **Part Position:**

Dorsiflex the foot so that plantar surface of the foot forms a 90 degree angle with the lower leg with the toes pointing straight up. Center the ankle joint to the center of the unmasked portion of the IR.

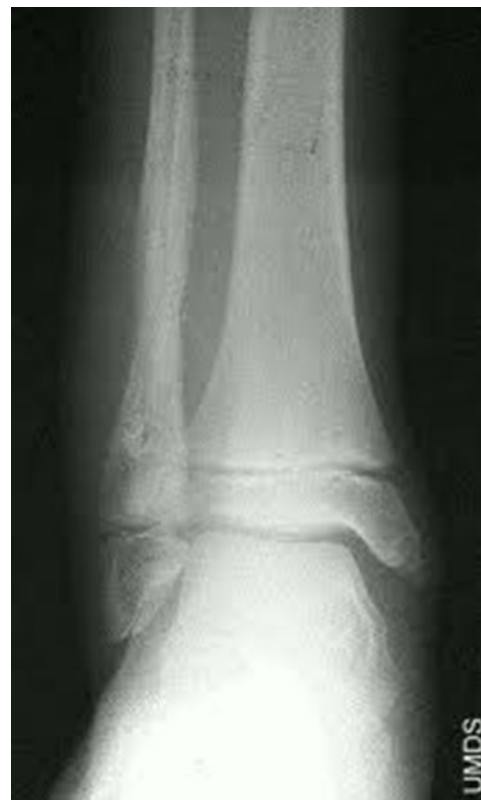
## **Central Ray:**

Perpendicular through the ankle joint centered between the malleoli.

**\*Shield the reproductive organs.**

## **Evaluation Criteria:**

- Collimation
- Tibiotalar joint space
- Ankle joint centered to exposure area
- Medial malleolus free of superimposition
- Lateral malleolus slightly superimposed over the talus
- Boney trabeculation
- Visualization of correct side marker



# Oblique Ankle

- *Table top*
- *40" S.I.D*
- *10x12 Image Receptor (1/2)*
- *Cross wise*
- *60 kVp*
- *Cross wise*

## **Body Position:**

Supine with affected leg fully extended.

## **Part Position:**

Dorsiflex the foot so that plantar surface of the foot forms a 90 degree angle with the lower leg.

Internally rotate the entire foot and leg from the hip about 45 degrees. Center the ankle joint to the center of the unmasked portion of the IR.

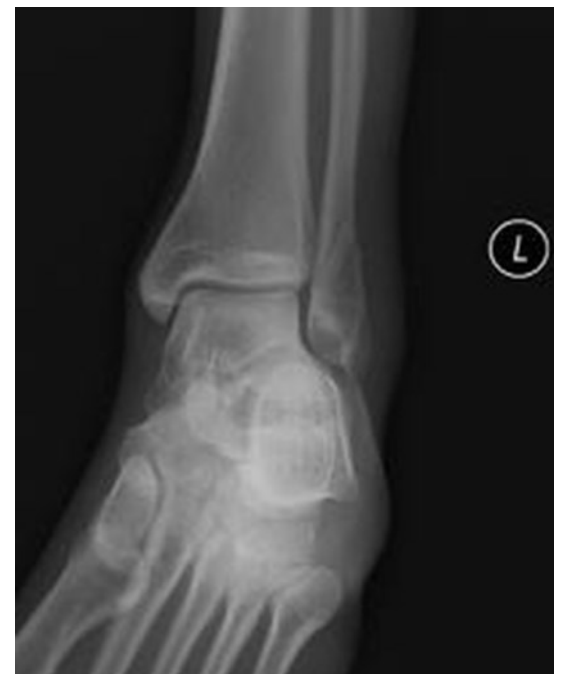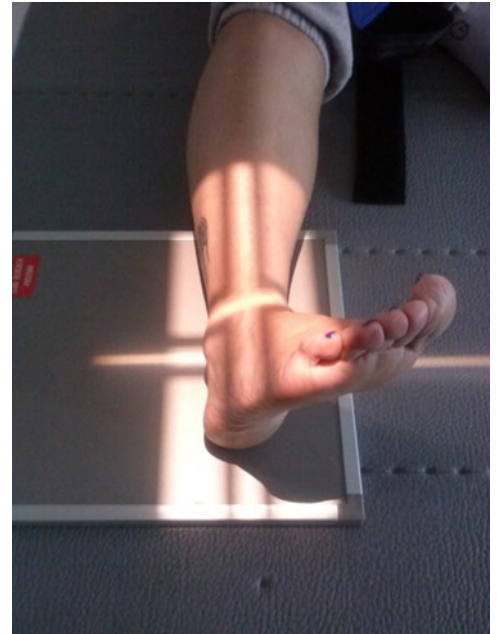## **Central Ray:**

Perpendicular through the ankle joint centered between the malleoli.

**\*Shield the reproductive organs.**

## **Evaluation Criteria:**

- Collimation
- Distal tibia fibula and talus
- Distal tibia and fibula overlap some of the talus
- Distal tibia fibula and talus demonstrating adequate penetration
- Tibiofibular articulation
- Boney trabeculation
- Visualization of correct side marker



# Lateral Ankle

- *Table top*
- *40" S.I.D*
- *10x12 Image Receptor*
- *length wise*
- *60 kVp*
- *Suspended Respiration*

## **Body Position:**

Lateral recumbent on the affected side

## **Part Position:**

Long axis of the lower leg parallel to the long axis of the IR, centered to the medial malleolus.

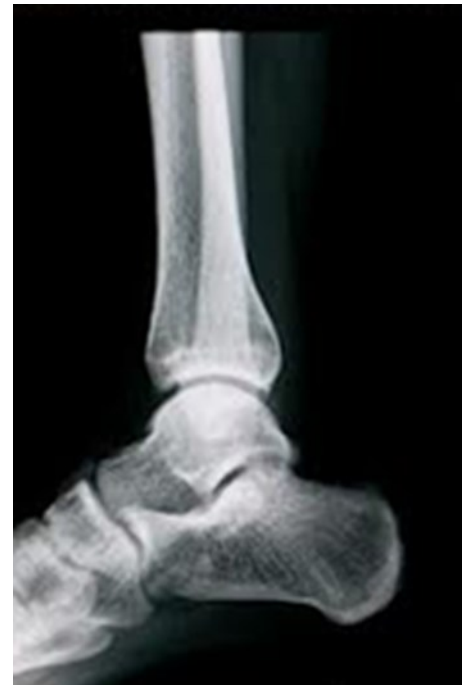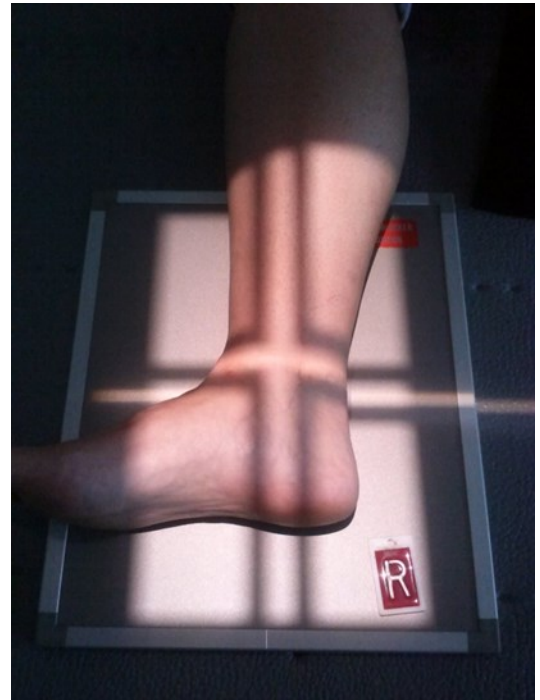## **Central Ray:**

Perpendicular to the medial malleolus

**\*Shield the reproductive organs**


## **Evaluation Criteria:**

- Collimation
- Tibiotalar joint well visualized with no superimposition of the domes.
- Fibula superimposed over posterior tibia
- Distal tibia fibula and adjacent tarsals
- Boney trabeculation
- Visualization of correct side marker



# AP Tib/Fib

- *Table Top*
- *40" S.I.D*
- *14x17 Image Receptor*
- *Corner to corner*
- *63 kVp*
- *Suspended Respiration*



## **Body Position:**

Place patient in the supine position

## **Part Position:**

Long axis of the lower leg parallel to the long axis of the IR, centered to the midpoint of the leg. Place the leg so that the femoral condyles are parallel with the IR. Dorsiflex the ankle to a 90 degree angle.

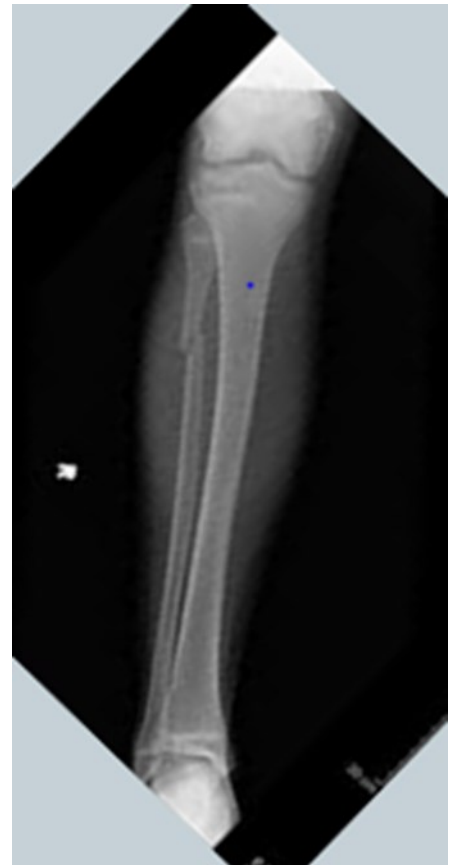## **Central Ray:**

Perpendicular to the lower leg

**\*Shield reproductive organs**

## **Evaluation Criteria:**

- Collimation
- Ankle and knee joints in their entirety
- No evidence of rotation
- Boney trabeculation and soft tissue
- Even density throughout
- Demonstration of correct side marker



# Lateral Tib/Fib

- *Table top*
- *40" S.I.D*
- *14x17 Image Receptor*
- *Catty corner*
- *60 kVp*
- *Suspended Respiration*



## **Body Position:**

Lateral recumbent on the affected side

## **Part Position:**

Rotate the patient so that the patella and the femoral condyles are perpendicular to the IR. Place the long axis of the tib/fib parallel to the IR.

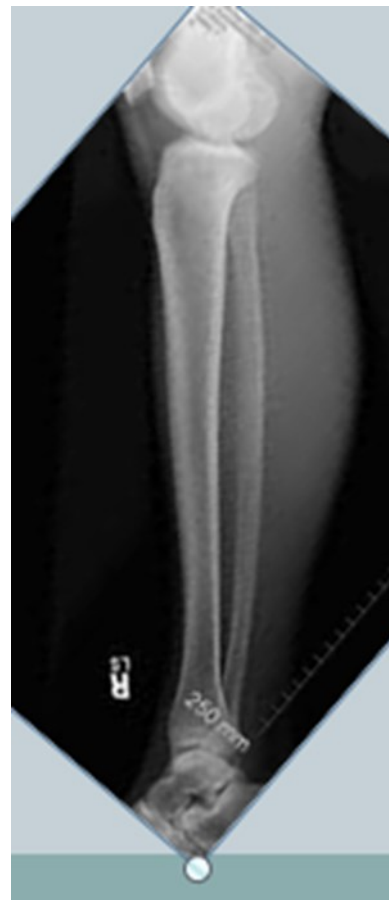## **Central Ray:**

Perpendicular to the mid point of the leg.

**\*Shield the reproductive organs**

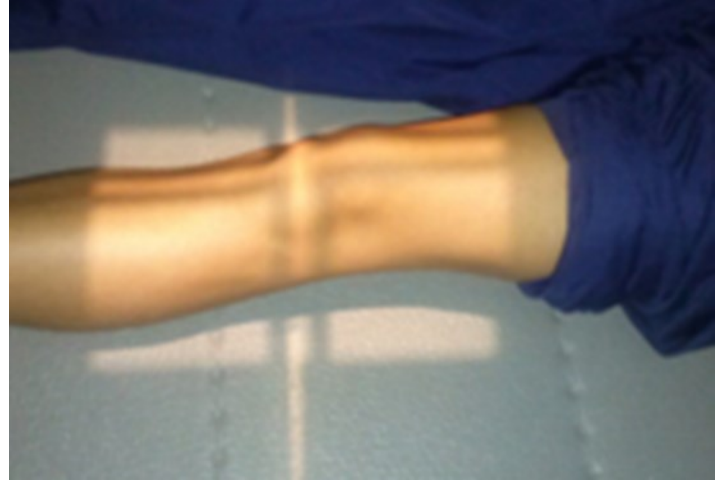## **Evaluation Criteria:**

- Collimation
- Ankle and knee joints in their entirety
- Distal fibula superimposing posterior distal tibia
- No rotation
- No evidence of rotation
- Boney trabeculation and soft tissue
- Even density throughout
- Demonstration of correct side marker



# AP Knee

- *Bucky/Grid*
- *40" S.I.D*
- *10x12 Image Receptor*
- *length wise*
- *65 kVp*
- *Suspended*



## Body Position:

Supine, without rotation

## Part Position:

Center the IR to a point 1/2" distal to the apex of the patella.

## Central Ray:

Directed to a point 1/2" distal to the apex of the patella.

## Angled as follows:

4 degrees caudal for patients with a thin pelvis (<19cm)

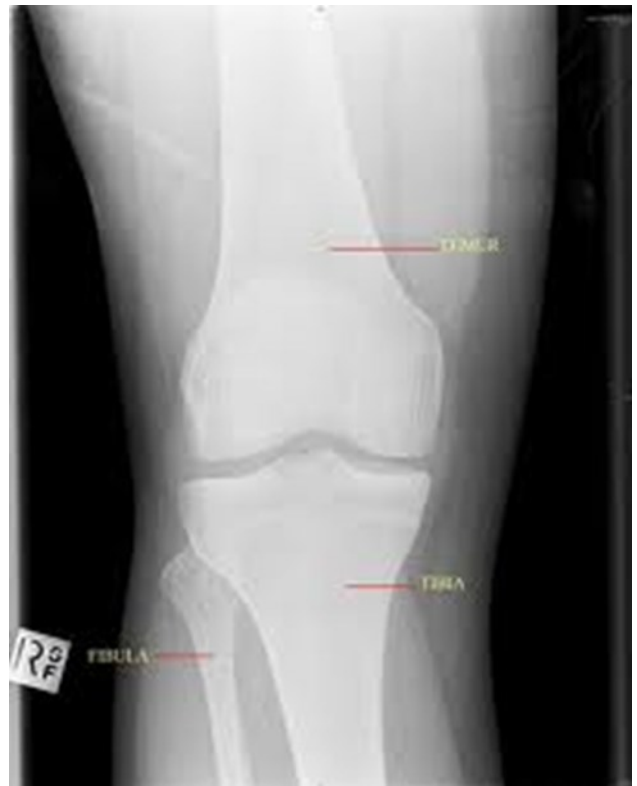4 degrees cephalic for patients with a thick pelvis

No tilt for average pelvis

## \*Shield reproductive organs

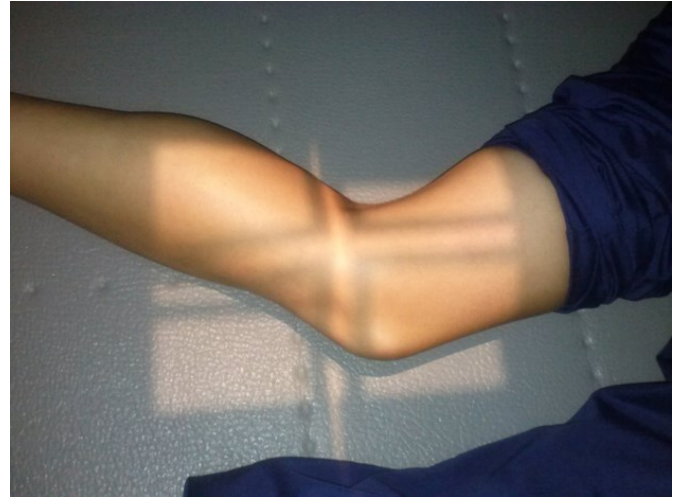## Evaluation Criteria:

- Collimation
- Open and equal femorotibial joint
- Patella superimposed and centered on femur
- No rotation
- Soft tissue
- Boney trabeculation
- Correct side marker visualized



# Lateral Knee

- *Bucky/Grid*
- *40" S.I.D*
- *10x12 Image Receptor*
- *length wise*
- *65 kVp*
- *Suspended*



## Body Position:

- Lateral recumbent on the affected side

## Part Position:

- Knee flexed 20-30 degrees
- Ankle supported if necessary to place tib/fib parallel with the tabletop
- Epicondyles perpendicular to the IR

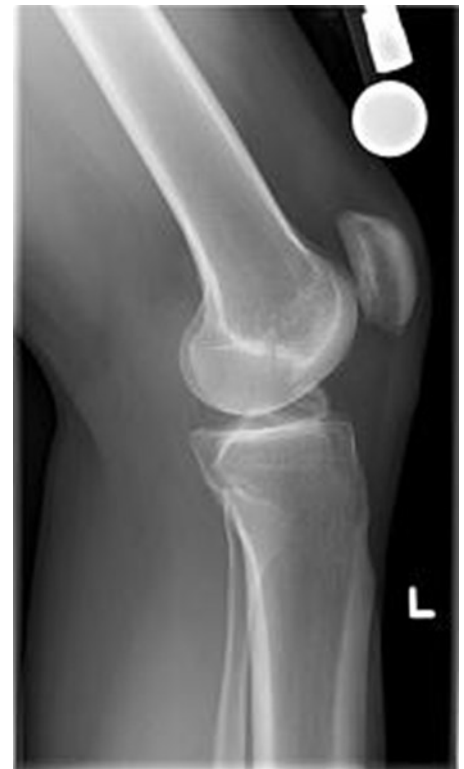## Central Ray:

- Directed to a point 1/2" inferior to the knee joint at a 5-7 degree cephalad angle.
- Center the IR to the central ray.

## \*Shield reproductive organs

## Evaluation Criteria:

- Collimation
- Superimposed femoral epicondyles
- Open knee joint space
- Patella in lateral profile
- Open patellofemoral joint space
- Slight superimposition of fibular head over posterior tibia
- Knee flexed 20-30 degrees
- Soft tissue
- Bony trabeculation
- Correct side marker visualized



# Sunrise Knee

- *Table top*
- *40" S.I.D*
- *10x12 Image Receptor*
- *Cross wise*
- *65 kVp*
- *Suspended*

## **Body Position:**

Seated on the radiographic table holding the IR securely against distal posterior femur.

## **Part Position:**

Flex knee approximately 90 degrees placing plantar surface of the foot flat on the table.

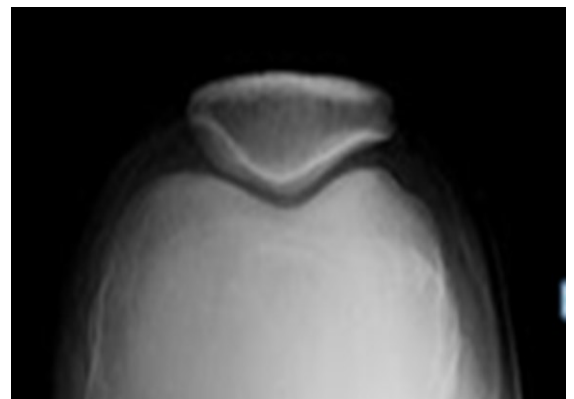
## **Central Ray:**

Directed to the patellofemoral joint space at not more than a 30 degree cephalic tilt.

**\*Shield reproductive organs**

## **Evaluation Criteria:**

- Collimation
- Patella in profile
- Open patellofemoral joint space
- Soft tissue
- Boney trabeculation
- Correct side marker visualized



# AP Femur

- *Bucky Tray/Grid*
- *40" S.I.D*
- *14x17 Image Receptor*
- *Length wise*
- *70 kVp*
- *Suspended Respiration*

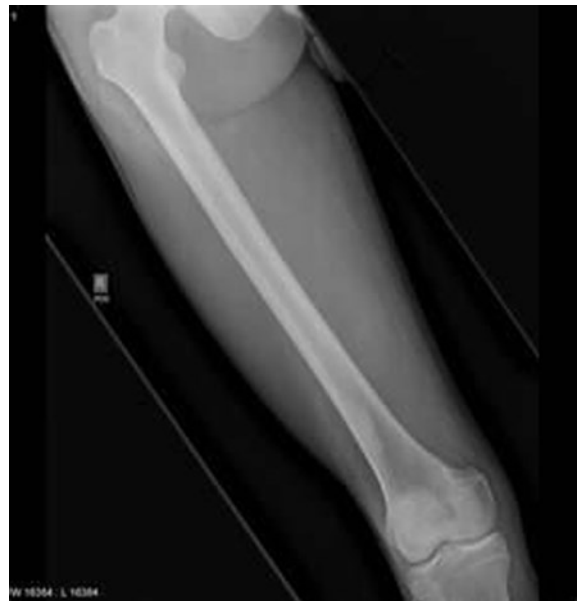

**Body Position:**

**Part Position:**

**Central Ray:**

**\*Shield reproductive organs**



# Lateral Femur

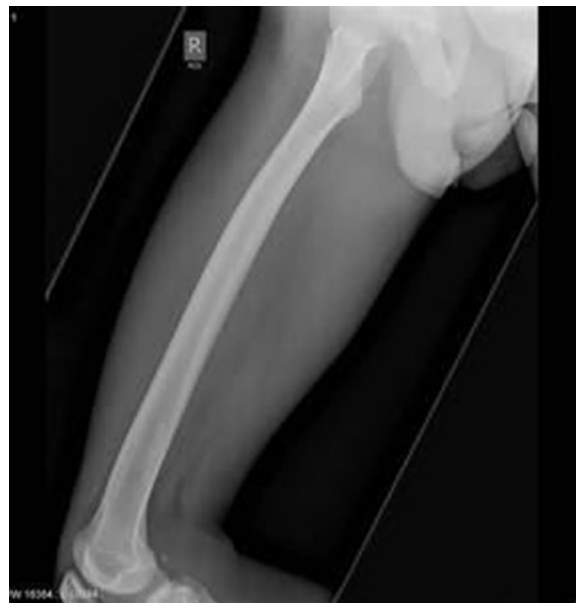- *Bucky Tray/Grid*
- *40" S.I.D*
- *14x17 Image Receptor*
- *Length wise*
- *70 kVp*
- *Suspended Respiration*

**Body Position:**

**Part Position:**

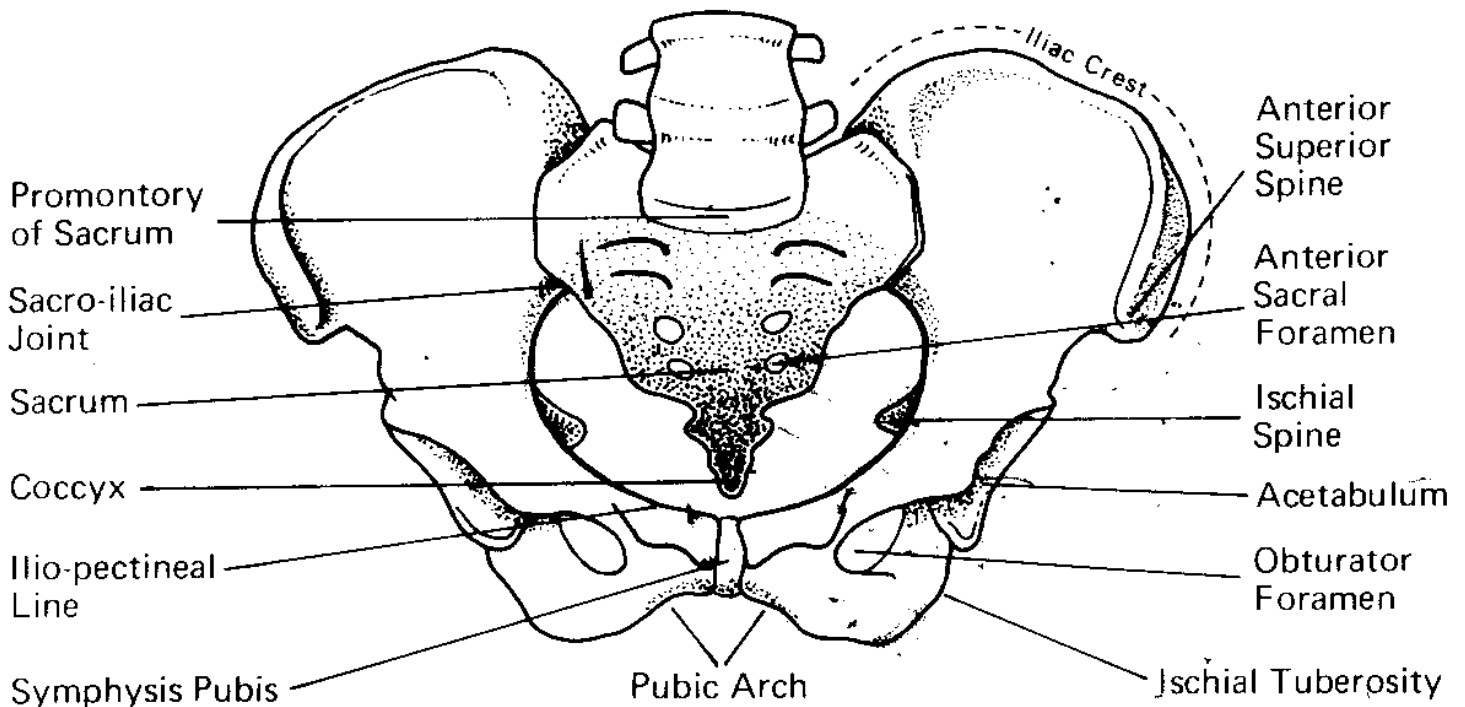
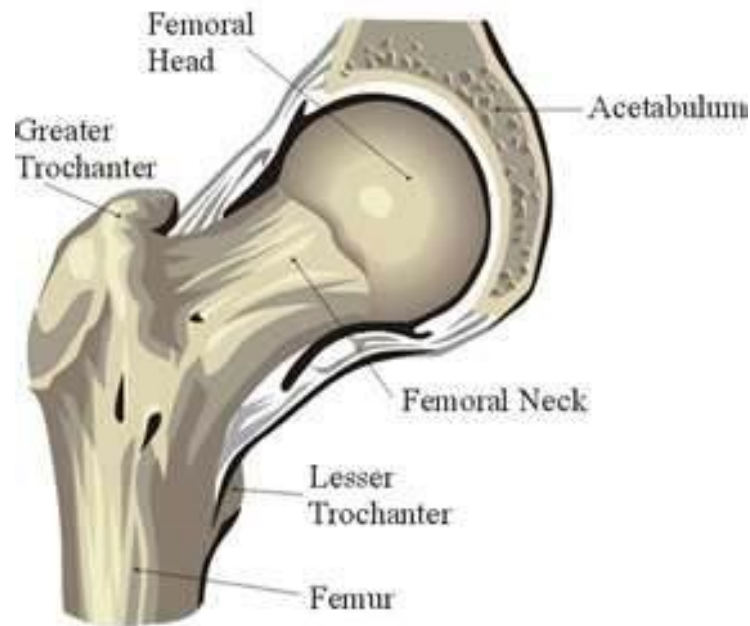**Central Ray:**

**\*Shield reproductive organs**



# Hip and Pelvis

## Anterior Femur



The pelvis.

# AP Hip

- *Bucky/Grid*
- *40" S.I.D*
- *10x12 Image Receptor*
- *Length wise*
- *65 kVp*
- *Suspended*

## Body Position:

- Supine without rotation

## Part Position:

- Medially rotate the lower limb on the affected side 15-20 degrees.

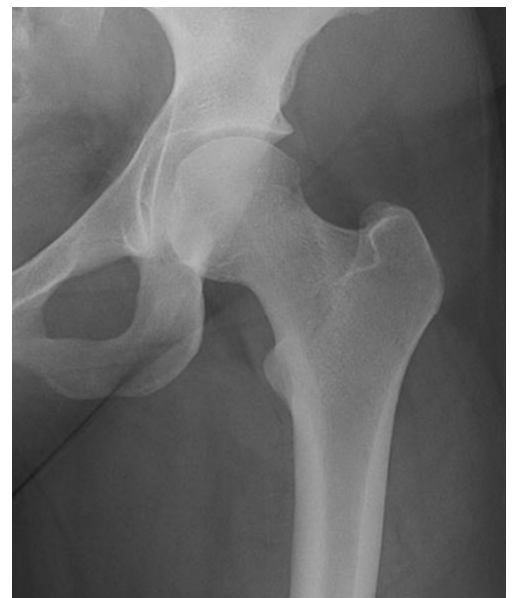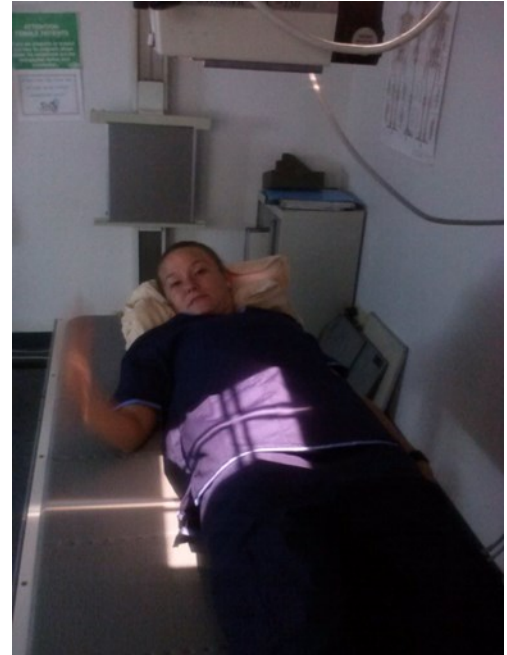## Central Ray:

- Perpendicular to the femoral neck, located by finding a point 1 and 1/2 inch distal to the midpoint of a line between the superior margin of the pubic symphysis and the ASIS.

**\*Shield reproductive organs**

## Evaluation Criteria:

- Collimation
- Femoral head visualized through the acetabulum
- Greater trochanter in profile
- No distortion of femoral neck
- Proximal femur
- Soft tissue
- Boney trabeculation
- Correct side marker visualized



# Frog leg Hip

- *Bucky/Grid*
- *40" S.I.D*
- *10x12 Image Receptor*
- *Cross wise*
- *65 kVp*
- *Suspended*

## **Body Position:**

- Supine without rotation

## **Part Position:**

- Adjust the ASIS to the midpoint of the IR
- Flex the hip and knee as much as possible

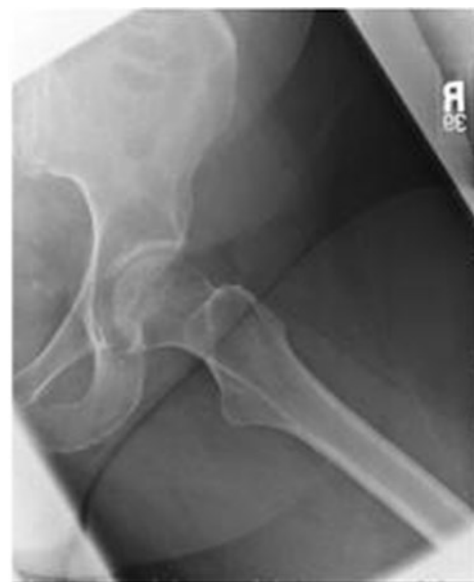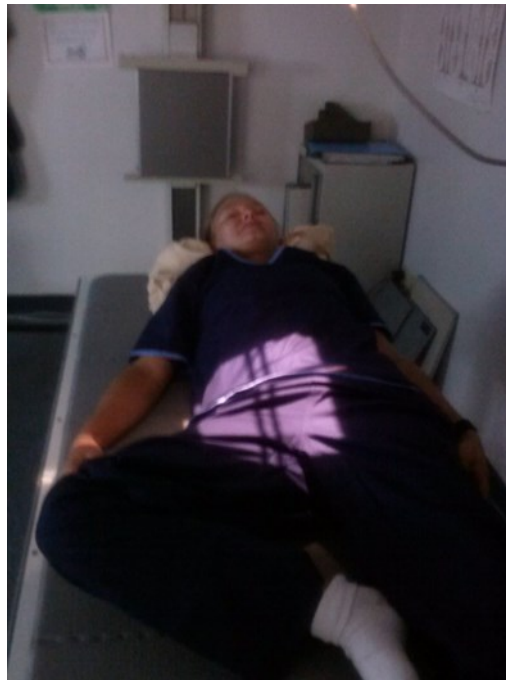## **Central Ray:**

Perpendicular to the femoral neck, located by finding a point 1 and 1/2 inch distal to the midpoint of a line between the superior margin of the pubic symphysis and the ASIS.

## **\*Shield reproductive organs**

## **Evaluation Criteria:**

- Collimation
- Femoral head visualized through the acetabulum
- Lesser trochanter in on medial side of the femur
- No distortion of femoral neck
- Proximal femur
- Soft tissue
- Boney trabeculation
- Correct side marker visualized



# AP Pelvis

- *Bucky/Grid*
- *40" S.I.D*
- *14x17 Image Receptor*
- *Cross wise*
- *75 kVp*
- *Suspended*

## Body Position:

- Supine without rotation

## Part Position:

- Center patient so that a point on the mid sagittal plane at the level of the iliac crest is 1 1/2" below the upper boarder of the image receptor.
- Rotate both lower extremities medially 15-20 degrees.

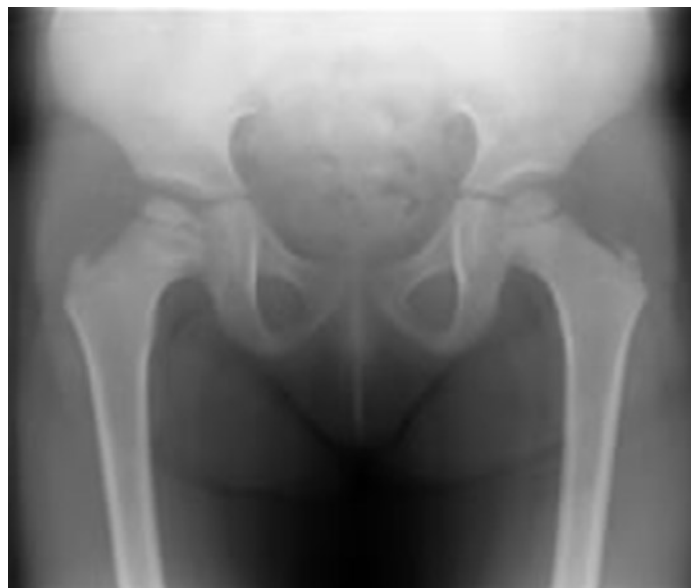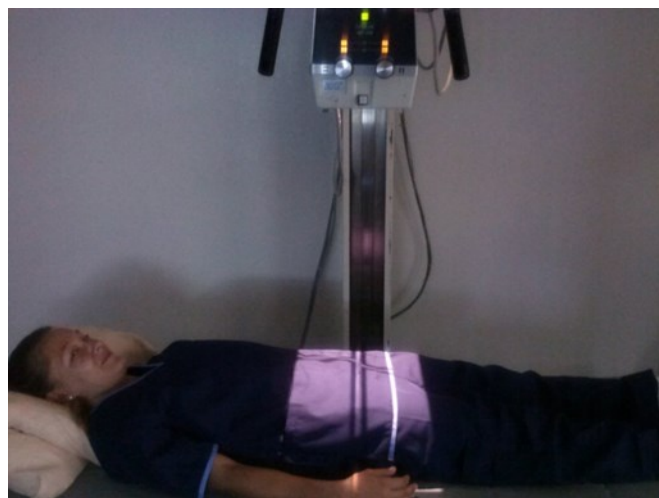## Central Ray:

- Perpendicular to the midpoint of the IR

## **\*Shield reproductive organs**

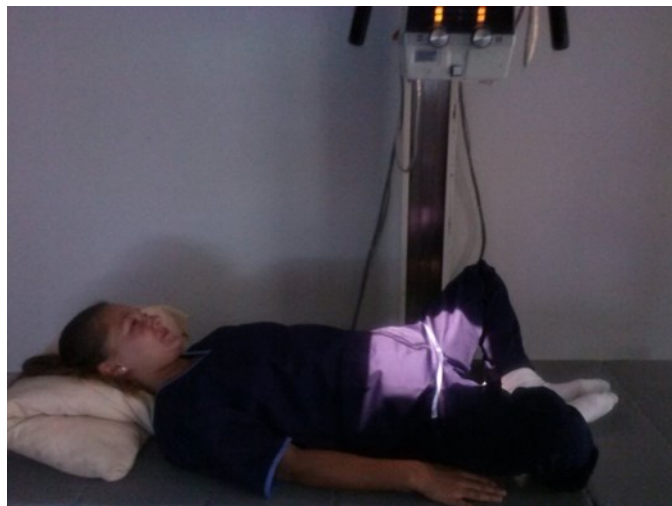## Evaluation Criteria:

- Collimation
- Femoral head visualized through the acetabulum
- Lesser trochanter in on medial side of the femur
- No distortion of femoral neck
- Proximal femur
- Soft tissue
- Boney trabeculation
- Correct side marker visualized



# Frog leg Pelvis

- *Bucky/Grid*
- *40" S.I.D*
- *14x17 Image Receptor*
- *Cross wise*
- *75 kVp*
- *Suspended*



## Body Position:

- Supine without rotation

## Part Position:

- Center patient so that a point on the mid sagittal plane at the level of the iliac crest is 1 1/2" below the upper boarder of the image receptor.
- Bend both knees and abduct both hips placing the soles of the feet together.

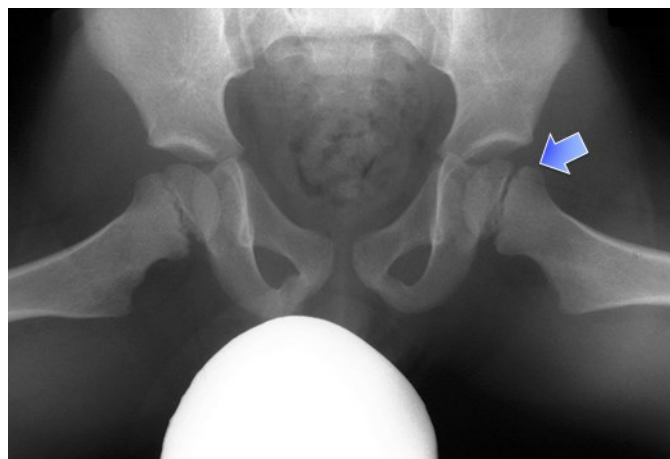
## Central Ray:

- Perpendicular to the midpoint of the IR

## \*Shield reproductive organs

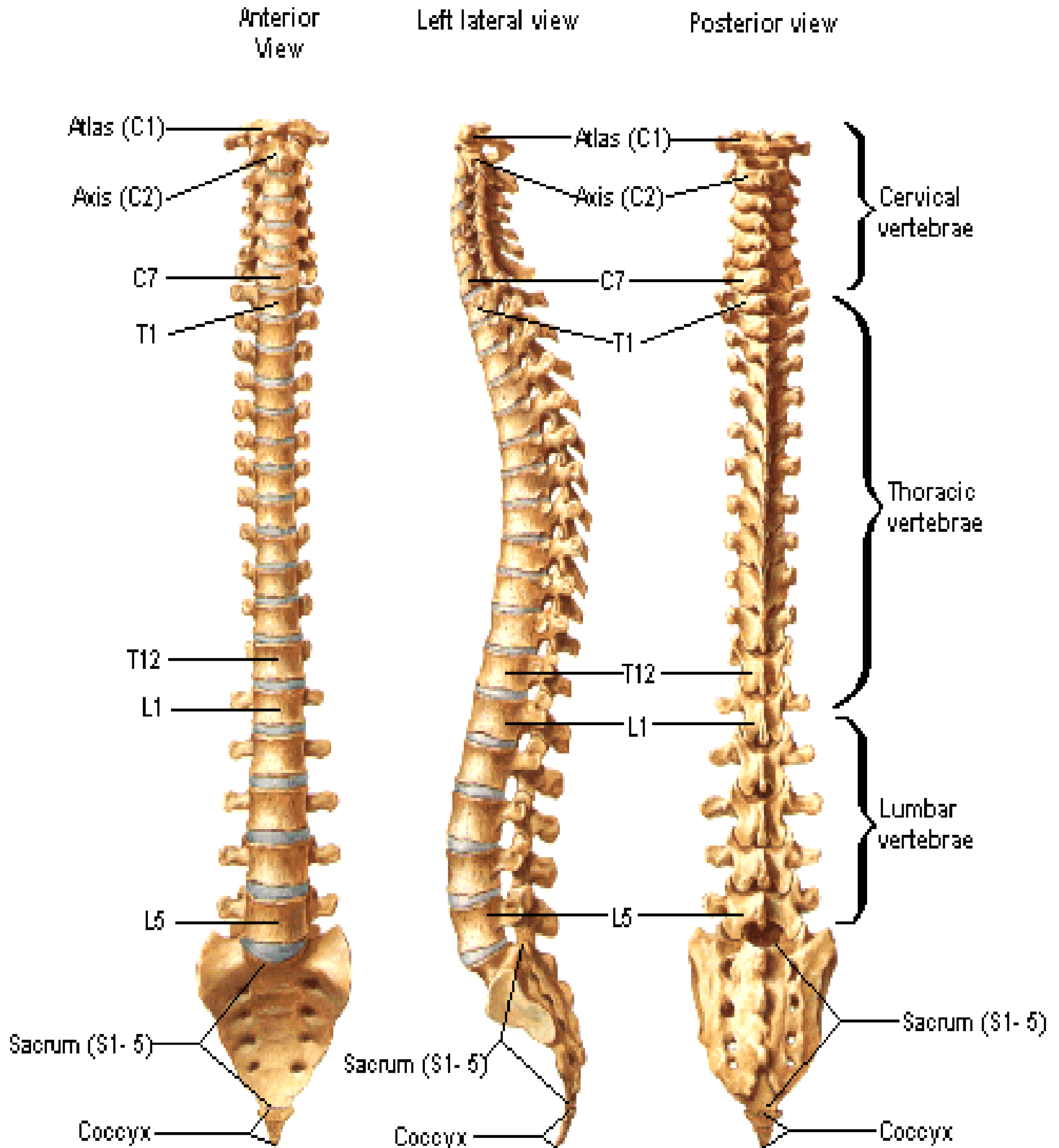
## Evaluation Criteria:

- Collimation
- Femoral head visualized through the acetabulum
- Lesser trochanter in on medial side of the femur
- No distortion of femoral neck
- Proximal femur
- Soft tissue
- Boney trabeculation
- Correct side marker visualized

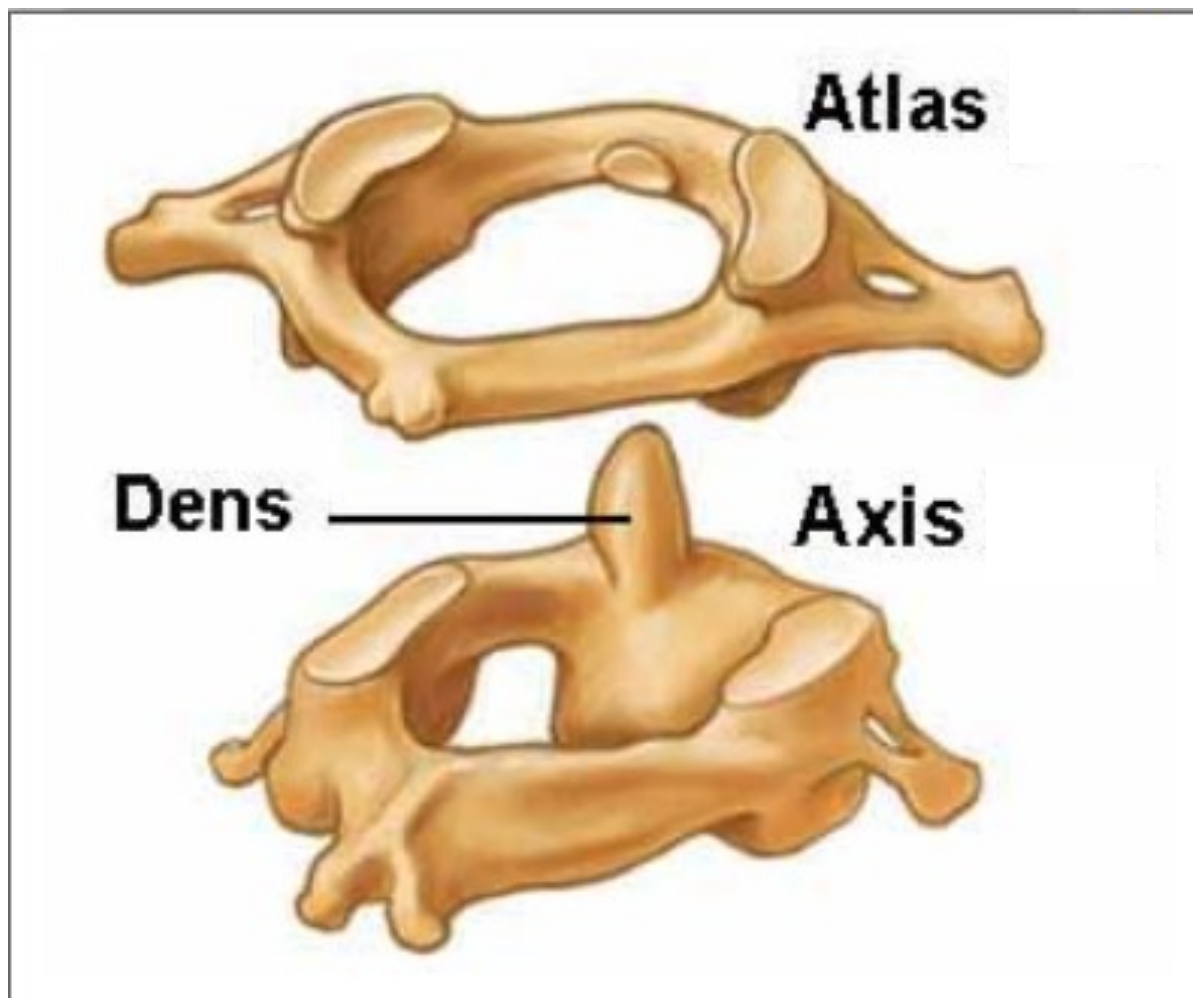
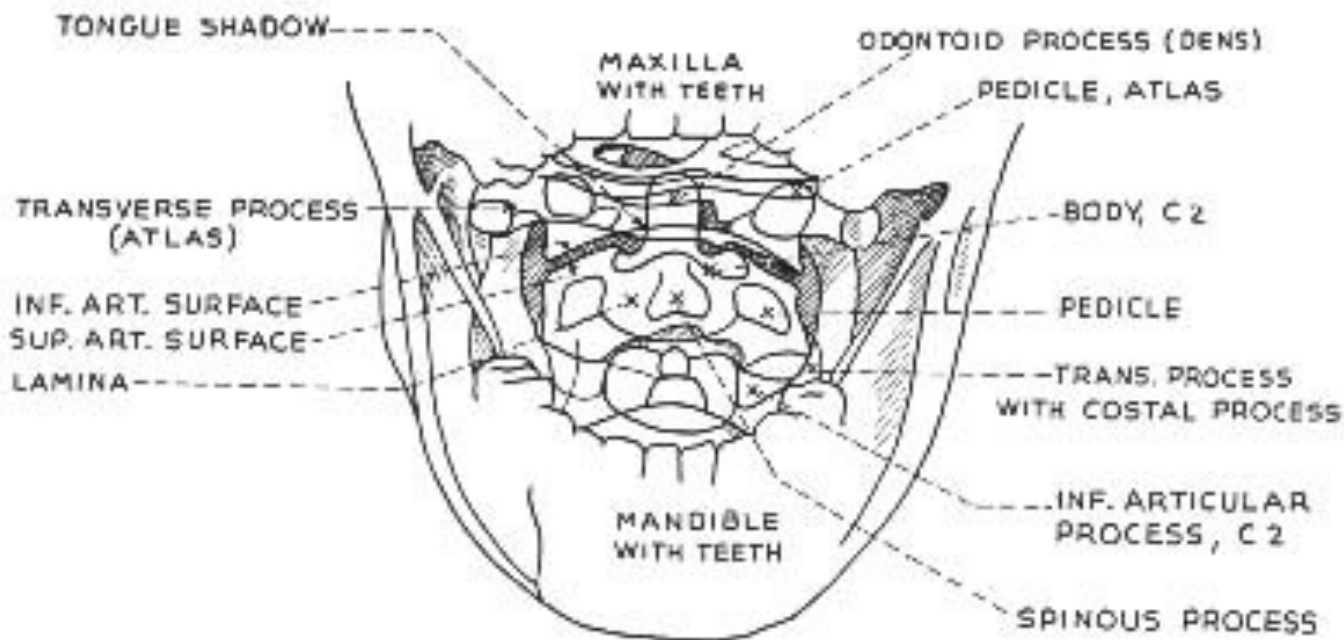


# Spine

## Vertebral Column



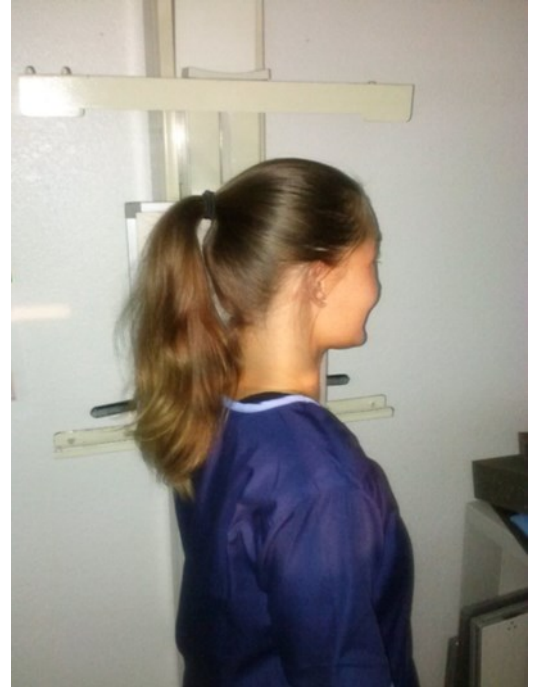# Atlas/Axis



# Lateral C-Spine

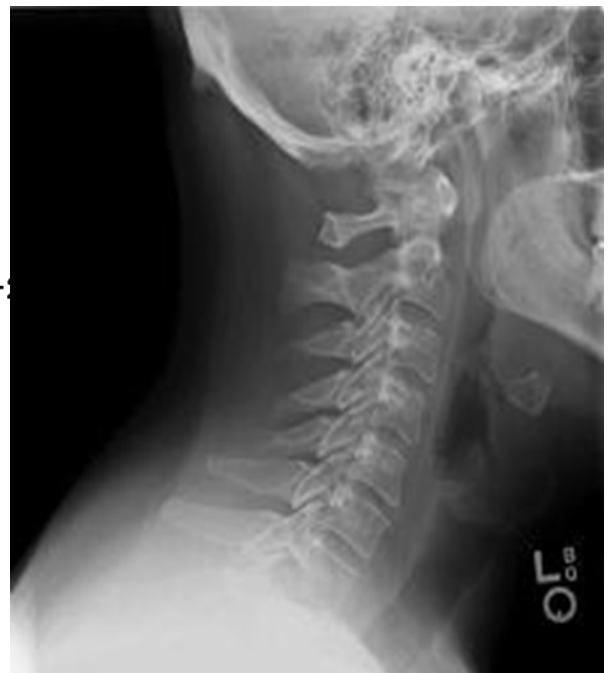- *Bucky/Grid*
- *72" S.I.D*
- *10x12 Image Receptor*
- *length wise*
- *75 kVp*
- *Full expiration*
- **Body Position: Upright in the lateral position**
- **Part Position: Center the coronal plane through the mastoid process to the IR. Shoulders level and perpendicular to the IR. Chin tilted up slightly and shoulders relaxed**
- **Central Ray: Perpendicular to C-4**

**\*Shield reproductive organs**



## Evaluation Criteria:

- Collimation
- All seven cervical vertebrae and top of T-1
- Mandible not superimposed over C-1 and C-2
- No tilt or rotation
- Spinous process in profile
- Soft tissue
- Correct side marker visualized



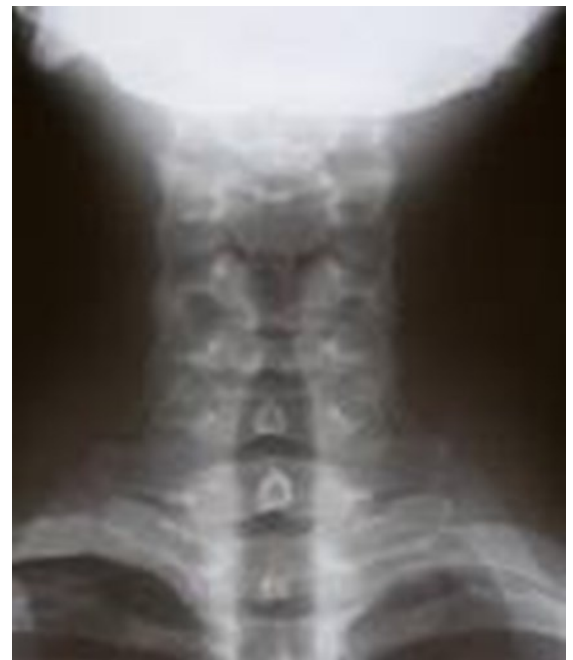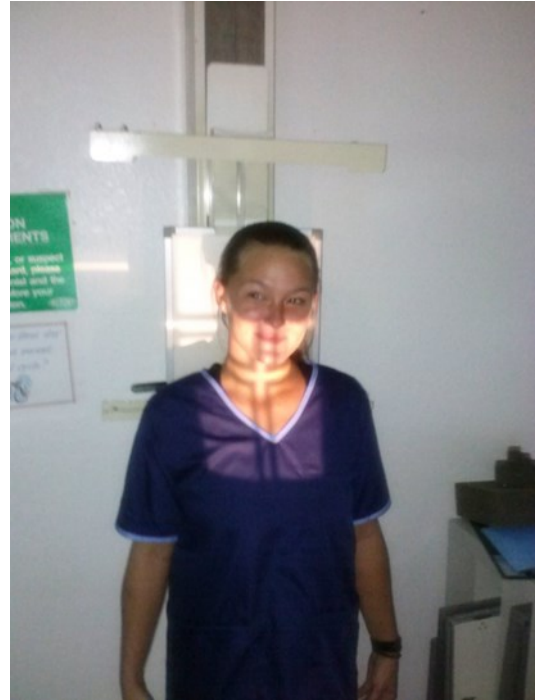
# AP Axial C-Spine

- *Bucky/Grid*
  - *40" S.I.D*
  - *10x12 Image Receptor*
  - *Length wise*
  - *75 kVp*
  - *Suspended*
- 
- **Body Position:** Upright with back against the IR.
  - **Part Position:** Midsagittal plane centered to the IR at the level of C-4. Shoulders level and chin extended.
  - **Central Ray:** Directed to C-4 at a cephalad angle of 15-20 degrees.

**\*Shield reproductive organs**

## **Evaluation Criteria:**

- Collimation
- C-3 through T2
- Open vertebral disk spaces
- No rotation
- Soft tissue
- Correct side marker visualized



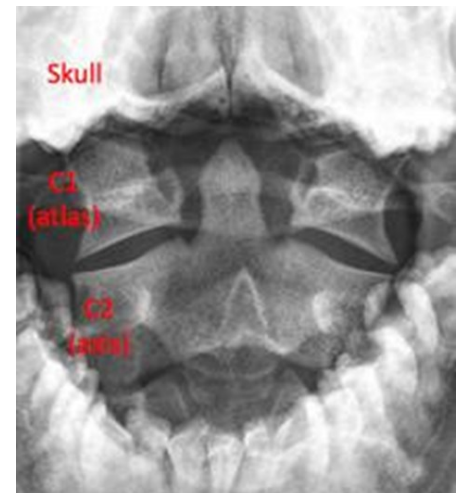
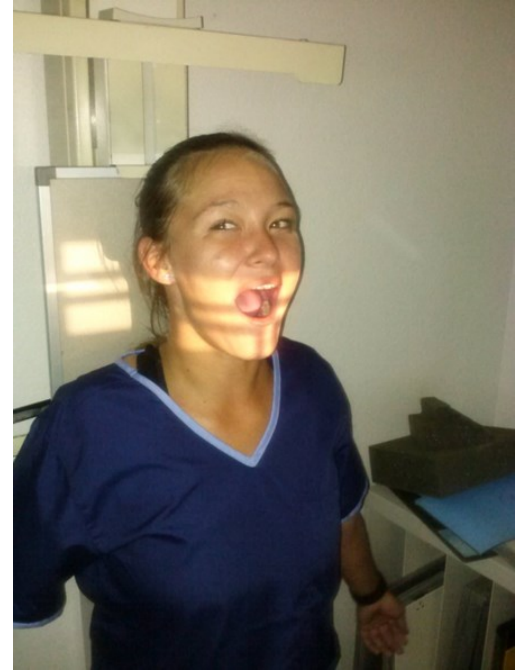
# APOM C-Spine

- *Bucky/Grid*
- *40" S.I.D*
- *8x10 Image Receptor*
- *Cross wise*
- *75 kVp*
- *Suspended*
- **Body Position: Supine centered to the midsagittal plane**
- **Part Position: IR centered to the midsagittal plane at the level of the axis. Place the mastoid process and the bottom of the top teeth in the same horizontal plane. Have patient open their mouth as wide as possible.**
- **Central Ray: Direct the perpendicular central ray through the open mouth.**

## \*Shield reproductive organs

### Evaluation Criteria:

- Collimation
- Odontoid C-1 and C-2
- Entire C-1 and C-2 joint space
- Base of skull superimposed over top teeth
- No rotation
- Soft tissue
- Correct side marker visualized



# Swimmers View

## Cervicothoracic Region Twining Method

- *Bucky/Grid*
- *40" S.I.D*
- *10x12 Image Receptor*
- *Length wise*
- *80 kVp*
- *Suspended*

**Body Position:** Lateral position against the grid device

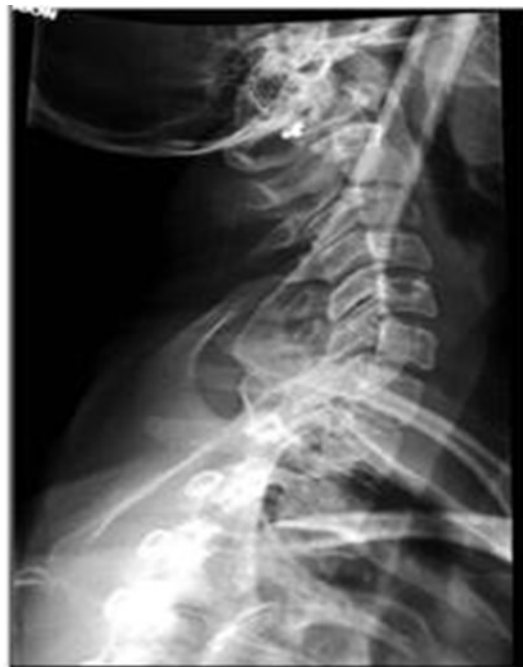**Part Position:** Midcoronal plane centered to the midline of the grid. Place the arm closest to the IR above the head. Depress the arm away from the IR. Center the IR to the level of the C-7 T-1 joint space.

**Central Ray:** Directed to the C-7 T-1 joint space with a 3-5 degree caudal tilt.

**\*Shield reproductive organs**

### Evaluation Criteria:

- Collimation
- Lower cervical and upper thoracic vertebrae
- No rotation
- Even penetration
- Visualization of correct side marker.



# AP T-Spine

- *Bucky/Grid*
- *40" S.I.D*
- *14x17*
- *Image Receptor*
- *Length wise*
- *80 kVp*
- *Suspended*

**Body Position:** Upright or supine

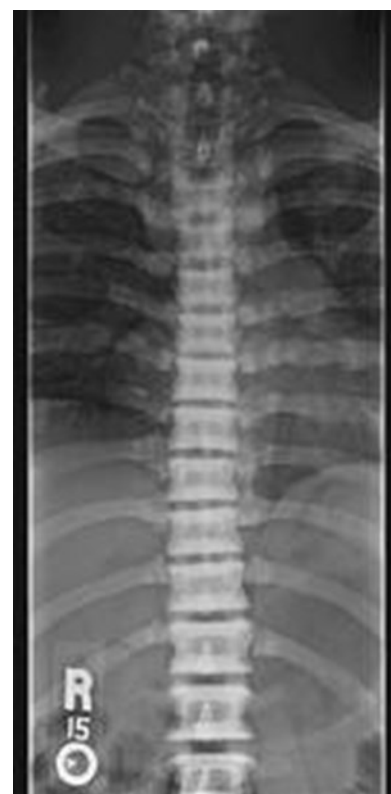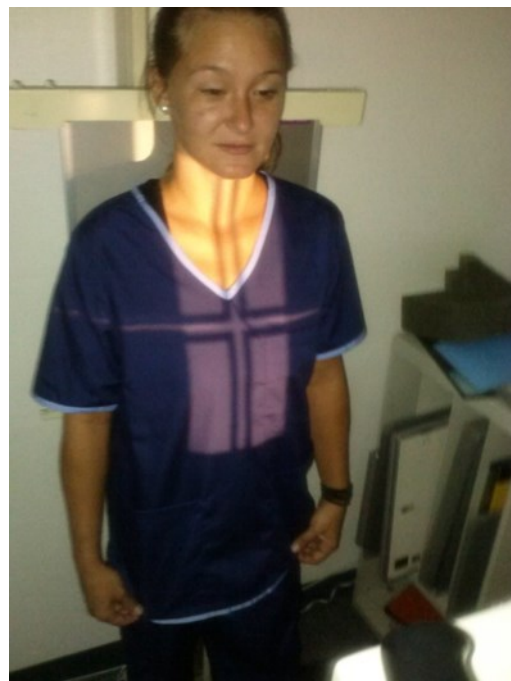
**Part Position:** Centered on the midsagittal plane with the top of the IR about 1 1/2 " above the top of the relaxed shoulders.

**Central Ray:** Perpendicular to the midsagittal plane at the level of C-7 Adjust the collimator to 7x17

**\*Shield reproductive organs**

## **Evaluation Criteria:**

- Collimation
- All 12 thoracic vertebrae
- Uniform penetration and density
- No rotation
- Correct side marker visualized



# Lateral T-Spine

- *Bucky/Grid*
- *40" S.I.D*
- *10x12 Image Receptor*
- *Length wise*
- *80 kVp*
- *Suspended*

**Body Position:** Lateral recumbent or erect

**Part Position:** Posterior half of the thorax centered to the midline of the bucky, with the top of the IR about 1 1/2 " above the top of the relaxed shoulders.

**Central Ray:** Perpendicular to the posterior half of the thorax at the level of T-7.

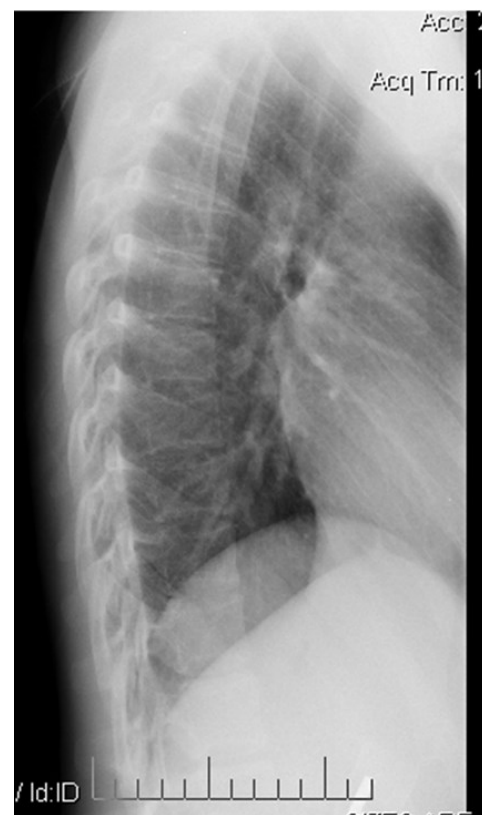**Collimate the primary beam to 7" x 17"**



**\*Shield reproductive organs**

## Evaluation Criteria:

- Collimation
- All 12 thoracic vertebrae well centered on the image.
- Uniform penetration and density
- No rotation as indicated by superimposition of the posterior ribs.
- T1 through T-3 may not be well visualized
- Open intervertebral disk spaces
- Correct side marker visualized



# AP L-Spine

- *Bucky/Grid*
- *40" S.I.D*
- *14x17 Image Receptor*
- *Length wise*
- *80 kVp*
- *Suspended*

**Body Position: Supine or Upright.**

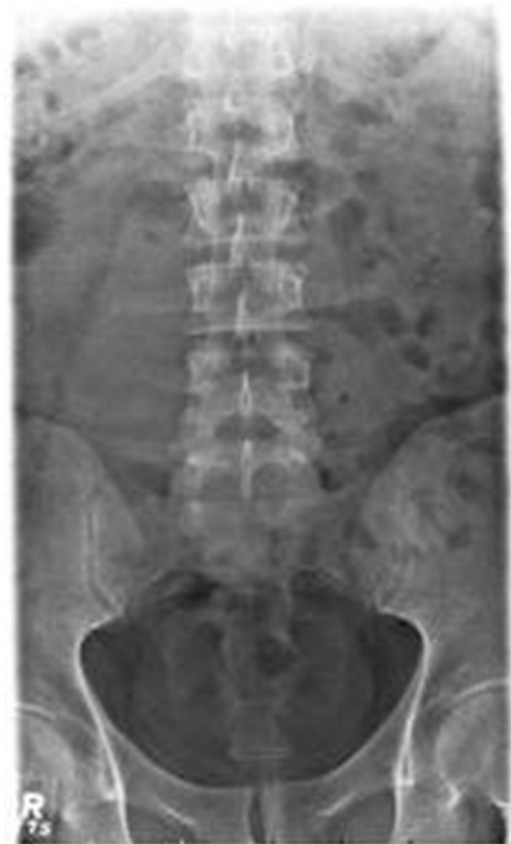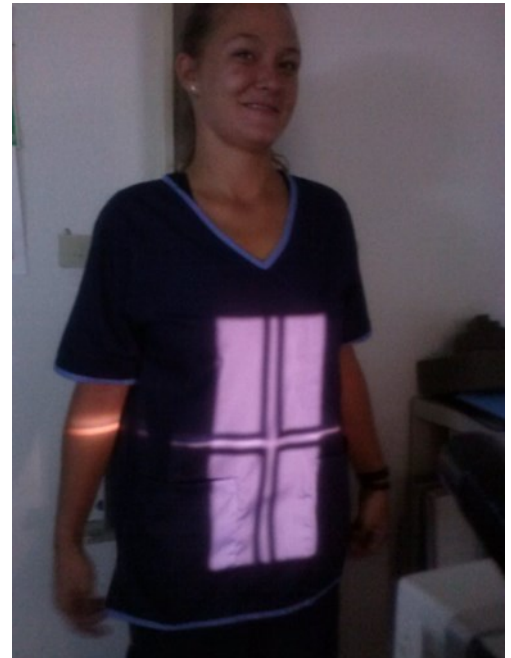**Part Position: Centered to the midsagittal plane at the level of the iliac crest**

**Central Ray: Perpendicular to the midsagittal plane at the level of the iliac crest**

**\*Shield reproductive organs**

## **Evaluation Criteria:**

- Collimation to include the psoas muscles
- From T-12 to the sacrum.
- Uniform penetration and density
- No rotation as indicated by superimposition of the posterior ribs.
- Open intervertebral disk spaces
- Correct side marker visualized



# Lateral L-Spine

- *Bucky/Grid*
- *40" S.I.D*
- *14x17 Image Receptor*
- *Length wise*
- *90 kVp*
- *Suspended*

**Body Position: Supine or upright**

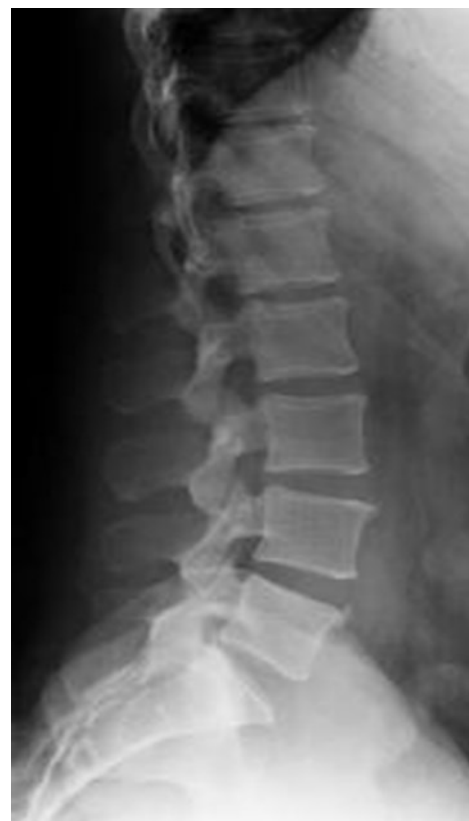
**Part Position: Center the IR to the midcoronal plane at the level of the iliac crest. Arms extended anteriorly hands together and elbows bent. If necessary place a support under the lower thorax in order to keep spine level**

**Central Ray: Perpendicular to the midcoronal plane at the level of the iliac crest.**

## **\*Shield reproductive organs**

### **Evaluation Criteria:**

- Collimation
- From T-12 to the coccyx.
- Superimposed posterior margins
- Spine centered on film
- Nearly superimposed iliac crests
- Spinous process in profile
- Uniform penetration and density
- No rotation as indicated by superimposition of the posterior ribs.
- Open intervertebral disk spaces
- Correct side marker visualized



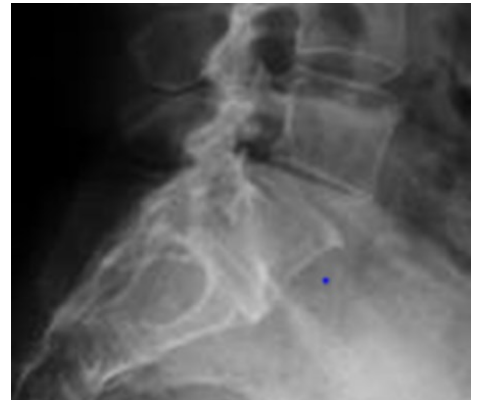
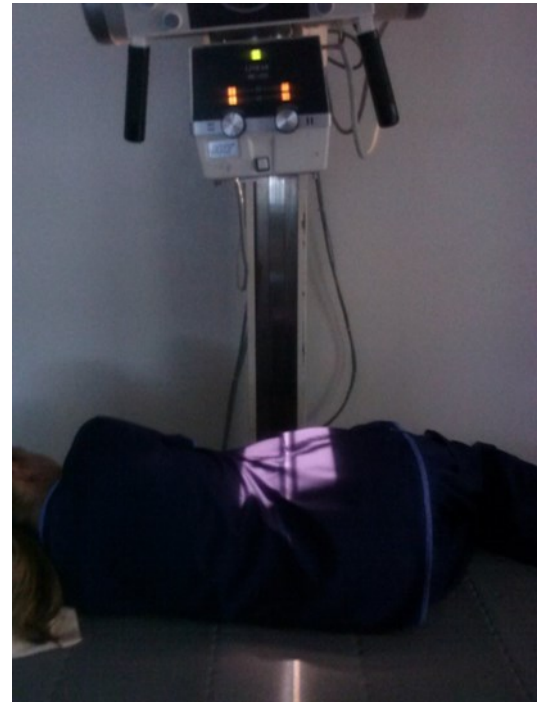
# L5/S1 Joint Space

- *Bucky/Grid*
- *40" S.I.D*
- *8x10 Image Receptor*
- *Length wise*
- *95 kVp*
- *Suspended*
- **Body Position: Place the patient in the lateral recumbent position.**
- **Part Position: With a pillow under the patients head and the midcoronal plane perpendicular to the IR extend the arms anteriorly place the hands together and bend the elbows. Superimpose the bent knees and place a pillow between them.**
- **Central Ray: Perpendicular to a coronal plane 2" posterior to the ASIS and 1 1/2" inferior to the iliac crest.**

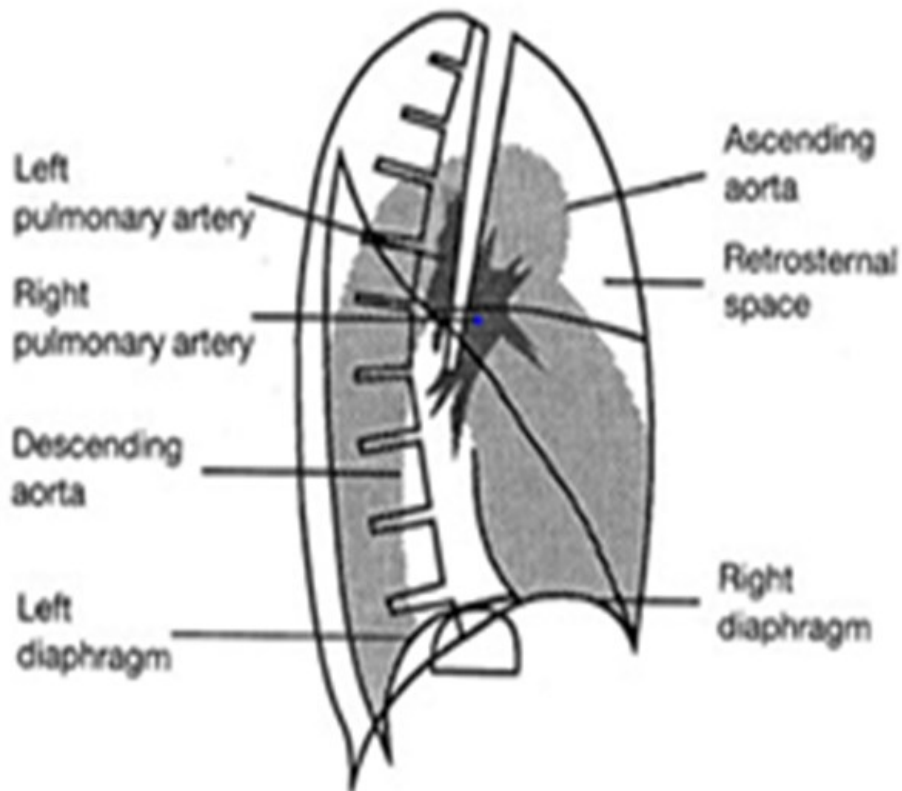
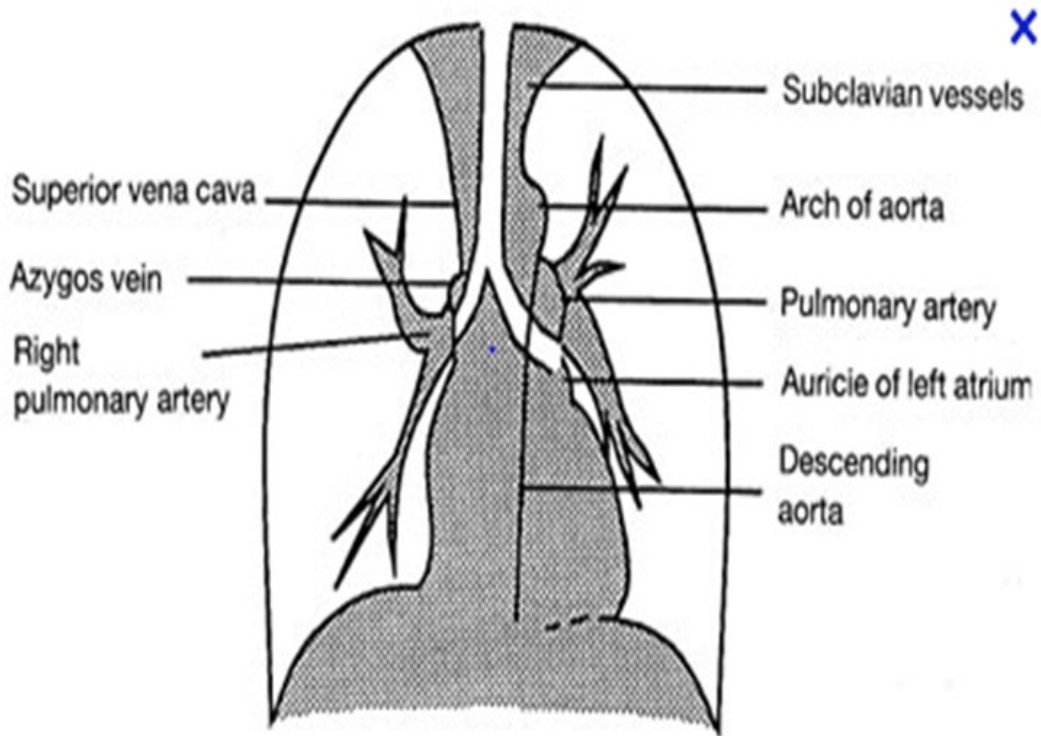
**\*Shield reproductive organs**

## **Evaluation Criteria:**

- Collimation to include all of L5 and the top of S1
- Open lumbosacral (L5, S1) joint space.
- Uniform penetration and density
- Image centered
- Iliac crests nearly superimposed
- Correct side marker visualized



# Chest



# PA Chest

- *Bucky/Grid*
- *72" S.I.D*
- *14x17 Image Receptor*
- *length wise*
- *110 kVp*
- *Full Inspiration*

## **Patient Position:**

Patient upright facing the image receptor.

## **Part Position:**

Place upper border of the IR about an inch and a half two inches above the tops of the shoulders, chin tilted up slightly. Place the backs of the hands on of the backs of the hips and roll the shoulders forward.

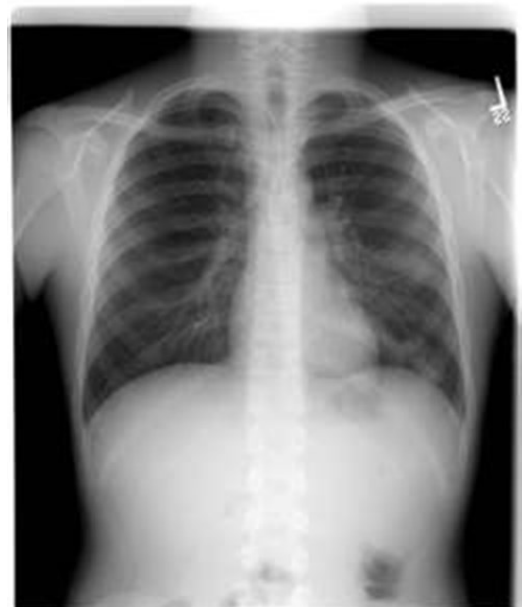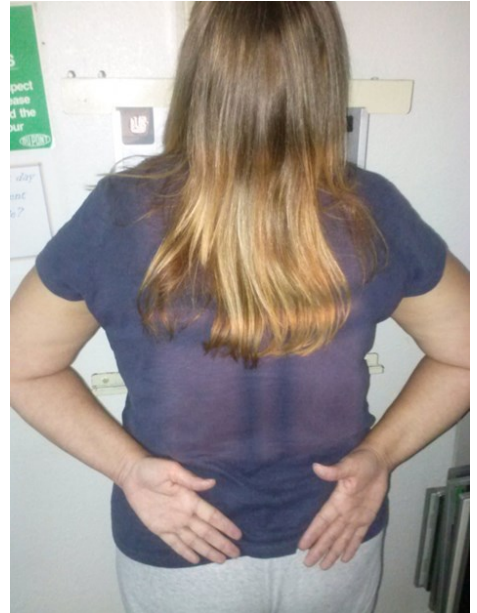
## **Central ray:**

Perpendicular to the center of the IR. CR should be at the midsagittal plane at the level of T7 (inferior boarder of the scapula).

**\* Shield reproductive organs**

## **Evaluation Criteria:**

- Entire lung field from apices to costophrenic angles
- No rotation ( Even SC Joints)
- Air filled trachea
- Scapula lateral to lung fields
- Ten pair of ribs superior to diaphragm
- Visibility of shadow of the heart
- Ribs and vertebrae visible through the shadow of the heart
- Visible lung markings
- Collimation
- Equal density on entire radiograph
- Visibility of correct side marker



# Lateral Chest

- *Bucky/Grid*
- *72" S.I.D*
- *14x17 Image Receptor*
- *length wise*
- *120 kVp*
- *Full Inspiration*

## **Patient Position:**

Patient upright with the left side in contact with the image receptor in a true lateral position..

## **Part Position:**

Place upper border of the IR about an inch and a half to two inches above the tops of the shoulders, chin tilted up slightly. Raise the patients hands above their head.

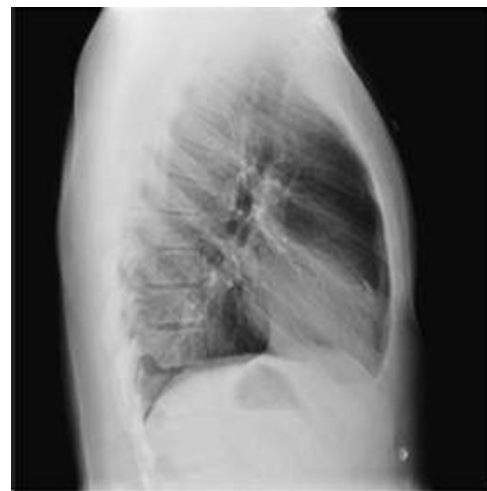
## **Central ray:**

Perpendicular to the center of the IR. CR should be at the midcoronal plane at the level of T7 (inferior boarder of the scapula).

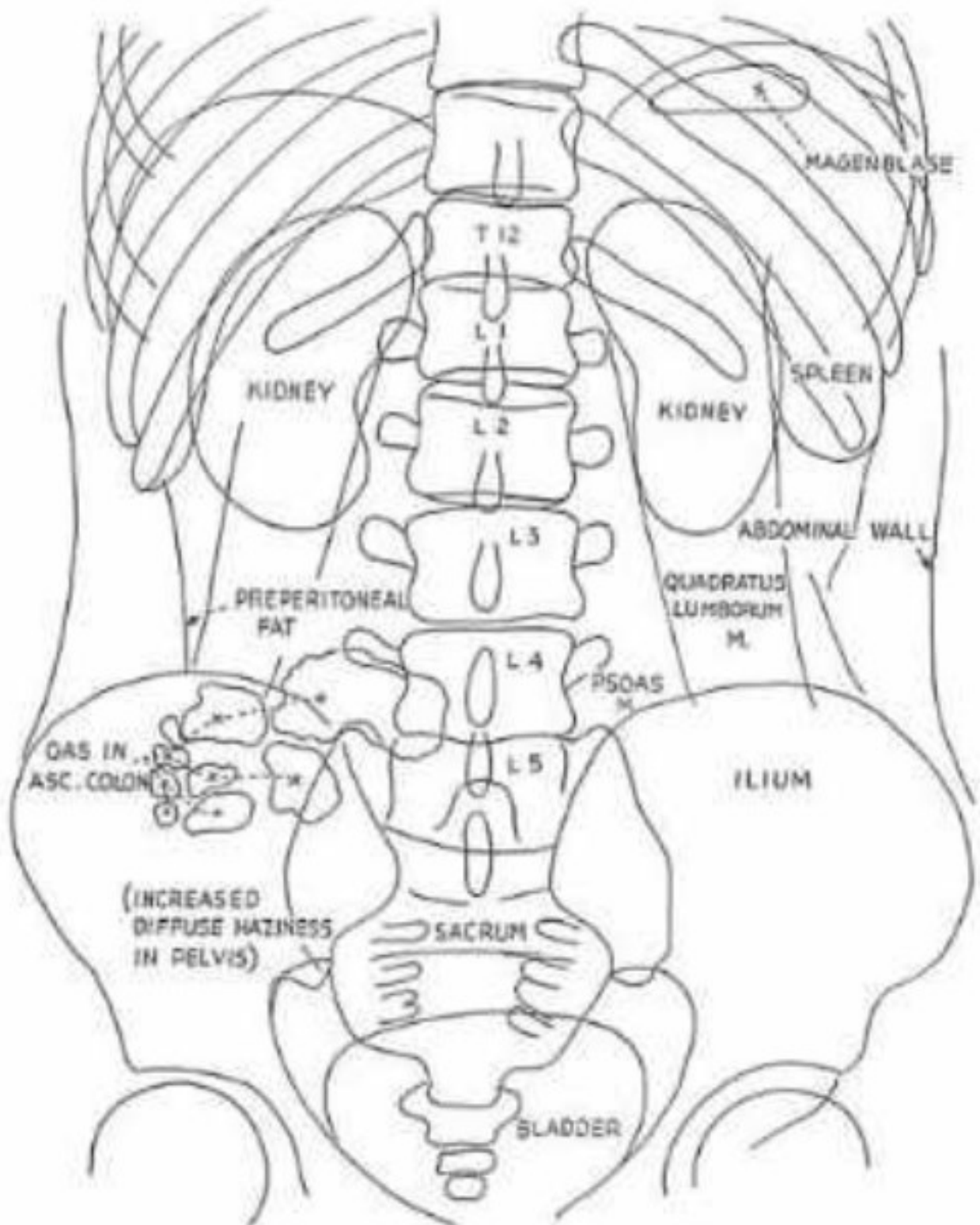
**\* Shield reproductive organs**

## **Evaluation Criteria:**

- Entire lung field from apices to costophrenic angles
- No rotation ( Even SC Joints)
- Superimposition of posterior ribs
- Arms or soft tissue not overlapping lung field
- Long axis of lung fields shown in vertical position
- Open thoracic intervertebral spaces
- Lateral sternum with no rotation
- Visible lung markings
- Collimation
- Equal density on entire radiograph
- Sharp outlines of heart and diaphragm
- Visibility of correct side marker



# Abdomen



**Anatomy of the Abdomen**

# AP Upright Abdomen

- *Bucky/Grid*
- *40" S.I.D*
- *14x17 Image Receptor*
- *length wise*
- *75 kVp*
- *Full Expiration*

## **Patient Position:**

Upright facing the x-ray tube

## **Part Position:**

IR centered to the midsagittal plane at a level 3 inches superior to the iliac crest.

## **Central ray:**

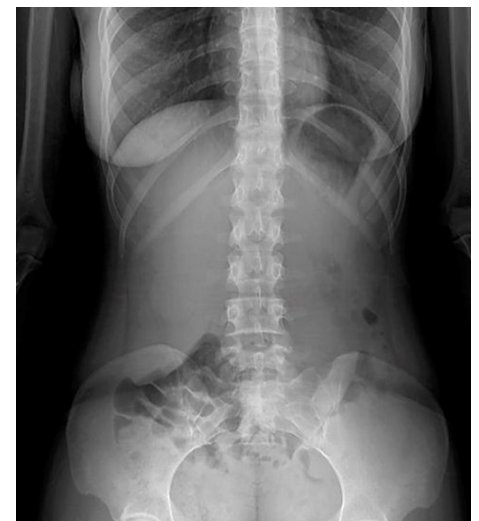Perpendicular to the midsagittal plane at the level 3 inches superior to the iliac crest.



## **\* Shield reproductive organs**

## **Evaluation Criteria:**

- Domes of the diaphragm included
- Vertebral column centered vertically
- No rotation of the hips or pelvis
- Psoas muscles visible bilaterally
- Shadow of lower margin of the liver
- Kidney shadows visible
- Collimation
- Inferior ribs visible
- Visibility of correct side marker
- Inferior margin of the shadow of the liver



# KUB (Kidneys, Ureters and Bladder)

- *Bucky/Grid*
- *40" S.I.D*
- *14x17 Image Receptor*
- *length wise*
- *75 kVp*
- *Full Expiration*

## Patient Position:

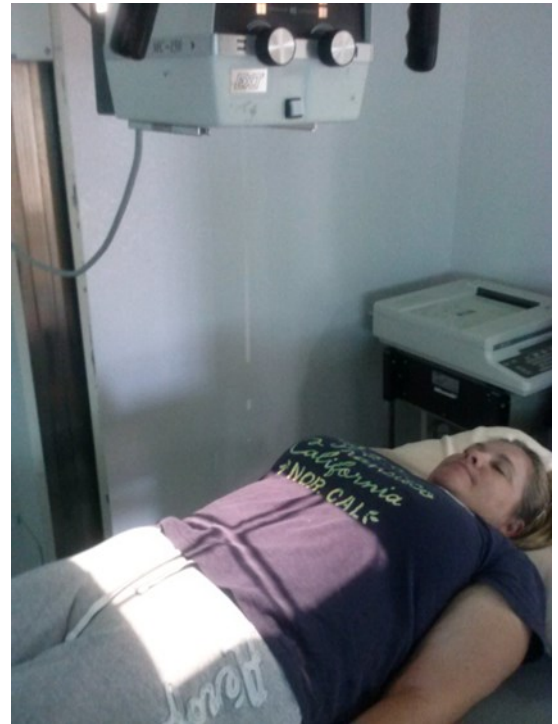Supine

## Part Position:

IR centered to the midsagittal plane at the level of the iliac crest.

## Central ray:

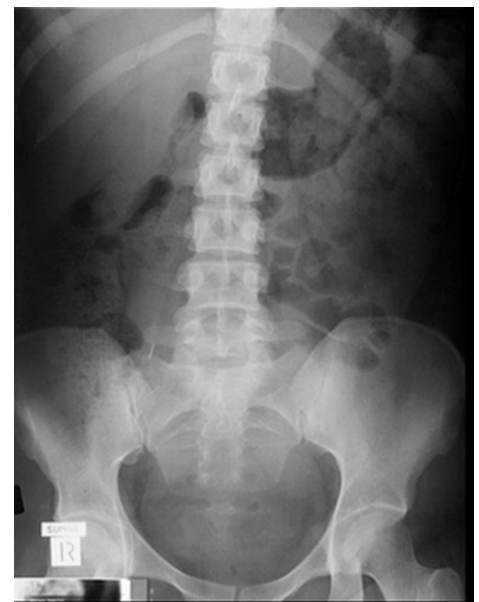Perpendicular to the midsagittal plane at the level of the iliac crest.



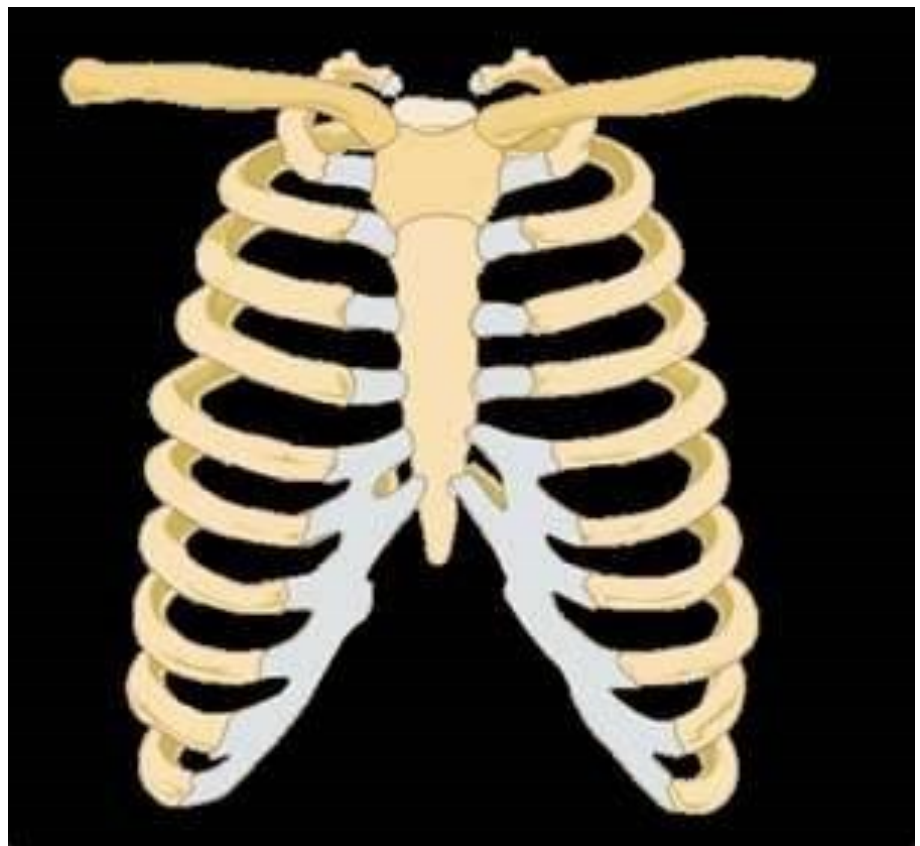
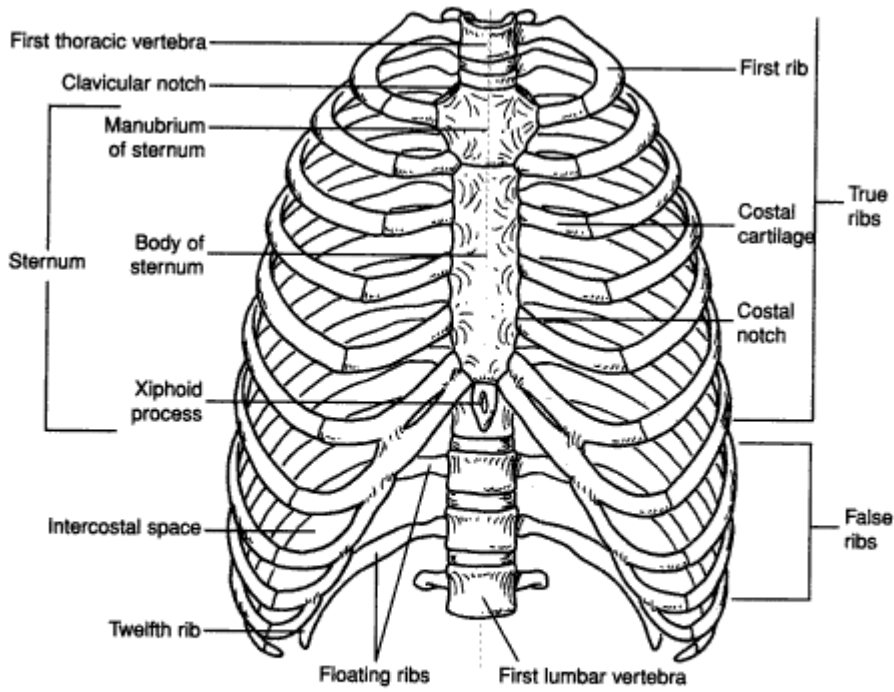
**\* Shield reproductive organs**

## Evaluation Criteria:

- Entire pubis symphysis included
- Domes of the diaphragm included
- Vertebral column centered vertically
- No rotation of the hips or pelvis
- Psoas muscles visible bilaterally
- Shadow of lower margin of the liver
- Kidney shadows visible
- Collimation
- Inferior ribs visible
- Visibility of correct side marker

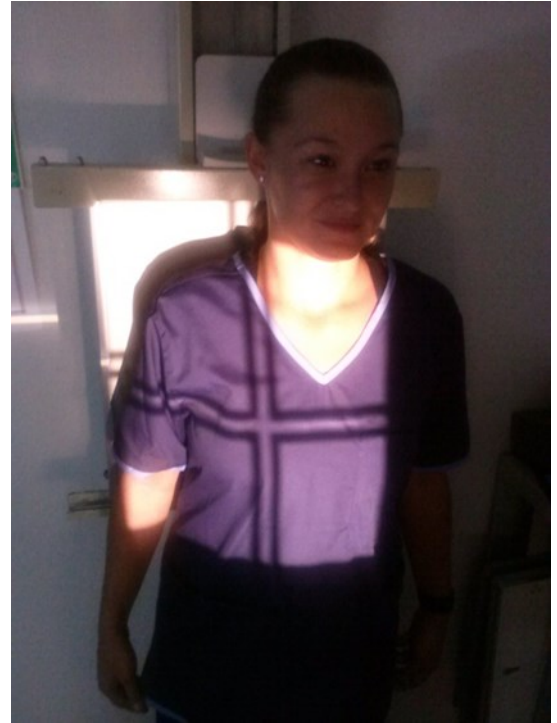

# Ribs



# AP Ribs(Upper)

- *Bucky/Grid*
- *40" S.I.D*
- *14x17 Image Receptor*
- *length wise*
- *60 kVp*
- *Full Inspiration*



## Body Position:

Upright facing the x-ray tube.

## Part Position:

Center the midpoint between the midsagittal plane and the lateral surface to the midline of the grid. Place the top of the image receptor one and one half inches above the top of the shoulders.

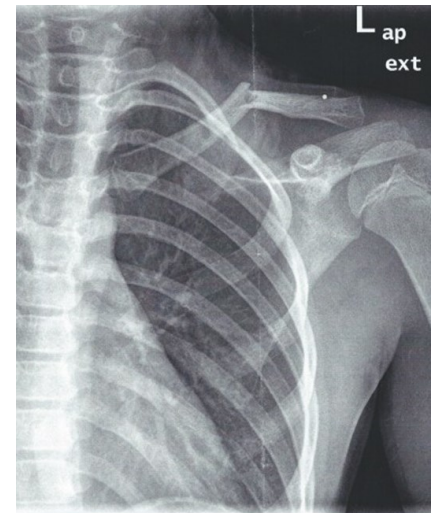## Central Ray:

Perpendicular to the center of the IR.

**\*Shield the reproductive organs**

## Evaluation Criteria:

- First ten ribs in their entirety
- Ribs visible through the lungs or abdomen
- Boney trabeculation
- Collimation
- Correct side marker visible



# Oblique Ribs(Upper)

- *Bucky/Grid*
- *40" S.I.D*
- *14x17 Image Receptor*
- *length wise*
- *60 kVp*
- *Full Inspiration*

## **Body Position:**

Upright facing the x-ray tube.

## **Part Position:**

Center the midpoint between the midsagittal plane and the lateral surface to the midline of the grid. Rotate the patient 45 degrees toward the affected side. Place the top of the image receptor one and one half inches above the top of the shoulders. Place the hand on the affected side on the patients head and the other hand on their hip.

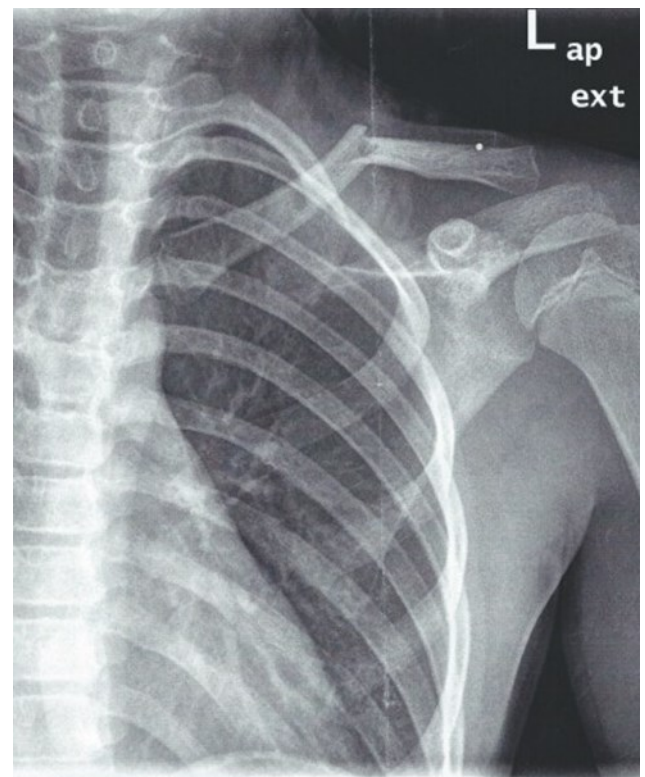
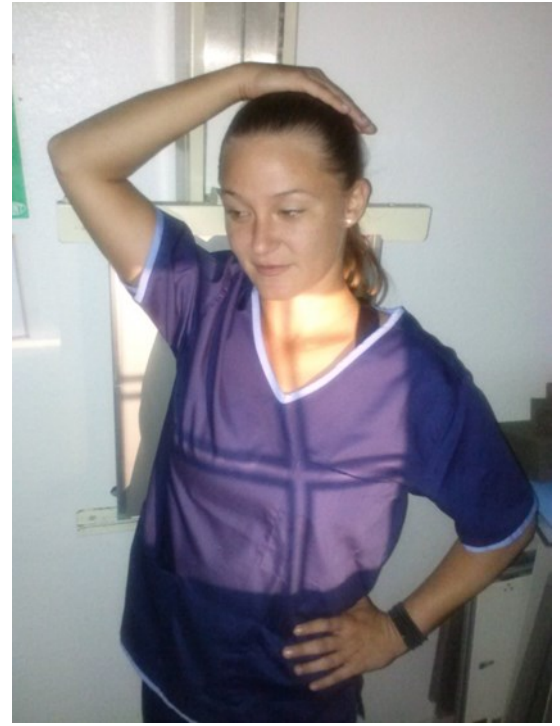
## **Central Ray:**

Perpendicular to the center of the image receptor.

**\* Shield the reproductive organs**

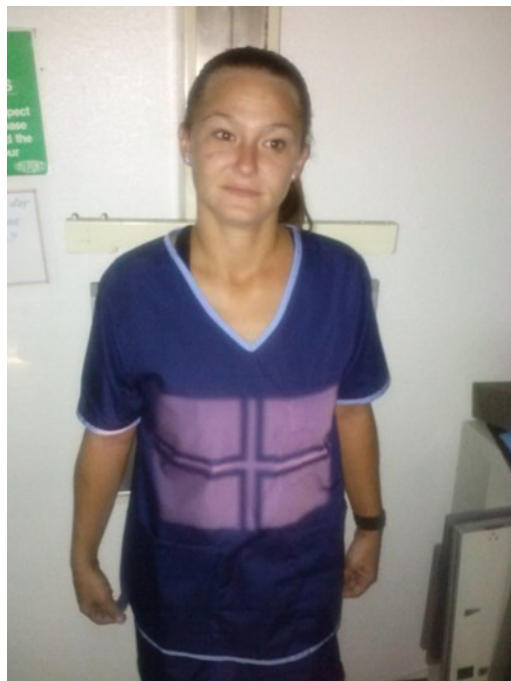## **Evaluation Criteria:**

- First ten ribs in their entirety
- Axillary portion of the ribs free of superimposition
- Ribs visible through the lungs or abdomen
- Boney trabeculation
- Collimation
- Correct side marker visible



# AP Ribs(Lower)

- *Bucky/Grid*
- *40" S.I.D*
- *14x17 Image Receptor*
- *length wise*
- *60 kVp*
- *Full Expiration*



## **Body Position:**

Upright facing the x-ray tube.

## **Part Position:**

Center the midsagittal plane to the midline of the grid. Place the lower margin of the IR to the level of the iliac crest.

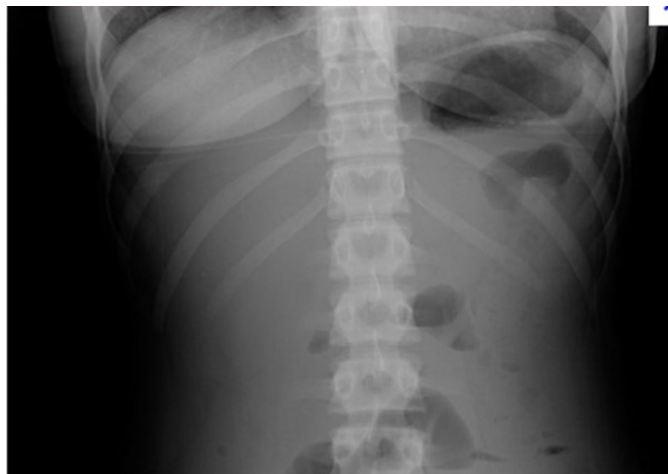
## **Central Ray:**

Perpendicular to the center of the IR.

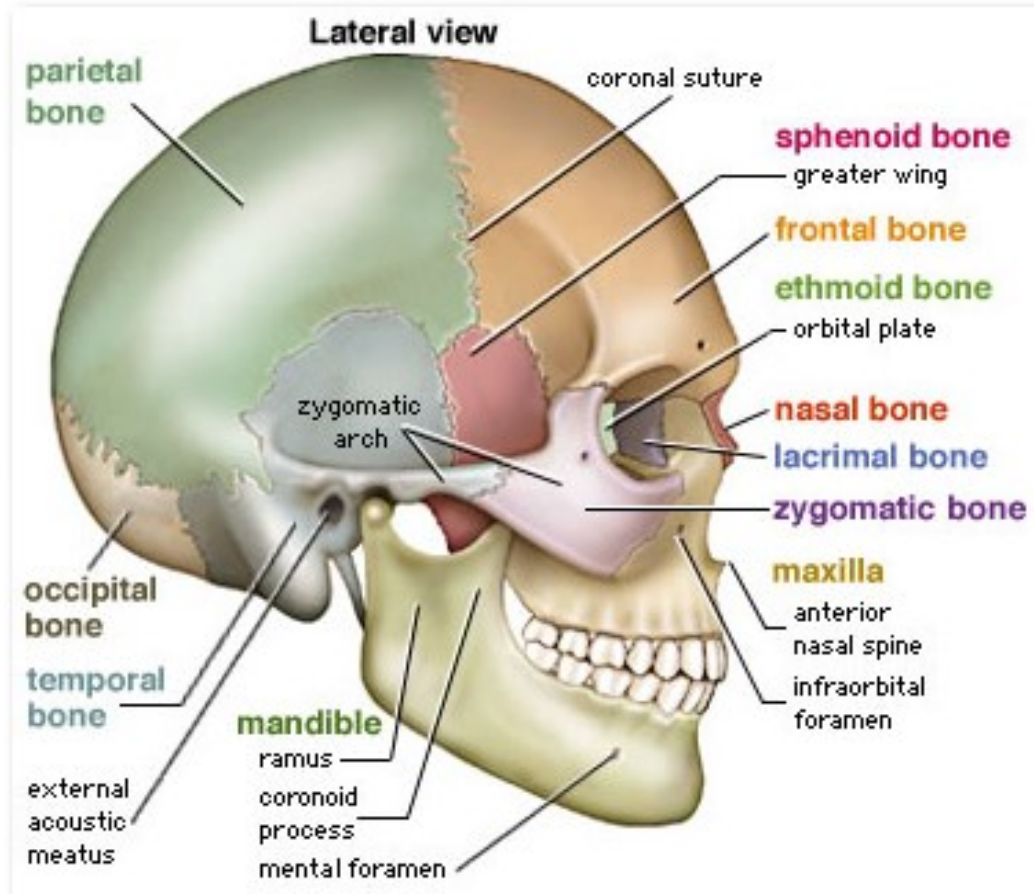
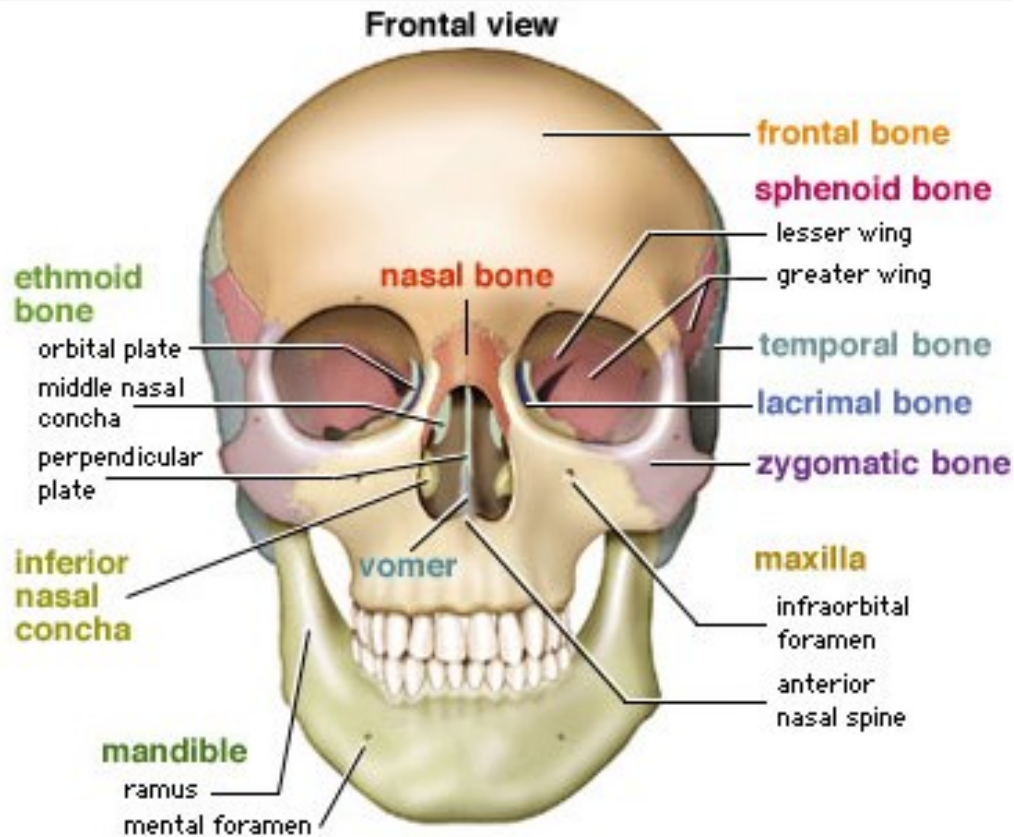
**\*Shield the reproductive organs**

## **Evaluation Criteria:**

- 8<sup>th</sup> through 12<sup>th</sup> ribs in their entirety on both sides
- Ribs visible through the lungs or abdomen
- Boney trabeculation
- Collimation
- Correct side marker visible




# Skull



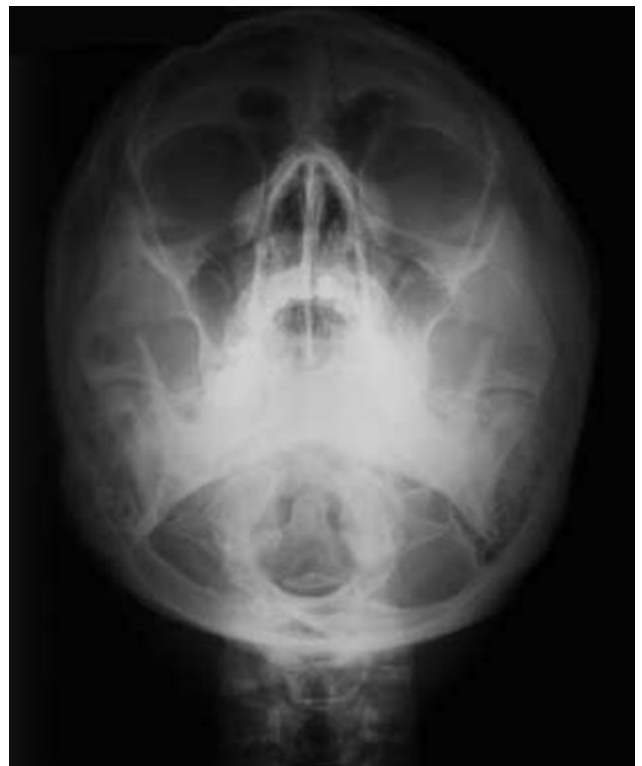# Waters View

- *Bucky/Grid*
- *40" S.I.D*
- *10x12 Image Receptor*
- *Length wise*
- *80 kVp*
- *Suspended*
- **Body Position: Upright facing the image receptor**
- **Part Position: Midsagittal plane perpendicular with the IR with the extended chin in contact with the IR and the nose approximately  $\frac{3}{4}$ " from the IR. IR centered to the midsagittal plane at the level of the acanthion.**
- **Central Ray: Perpendicular to the midsagittal plane at the level of the acanthion.**




## Evaluation Criteria:

- Petrous pyramids well below orbital shadows
- No rotation as demonstrated by symmetric visualization of the orbits
- Uniform penetration and density
- Image centered
- Close collimation
- Correct side marker visualized



# Caldwell View

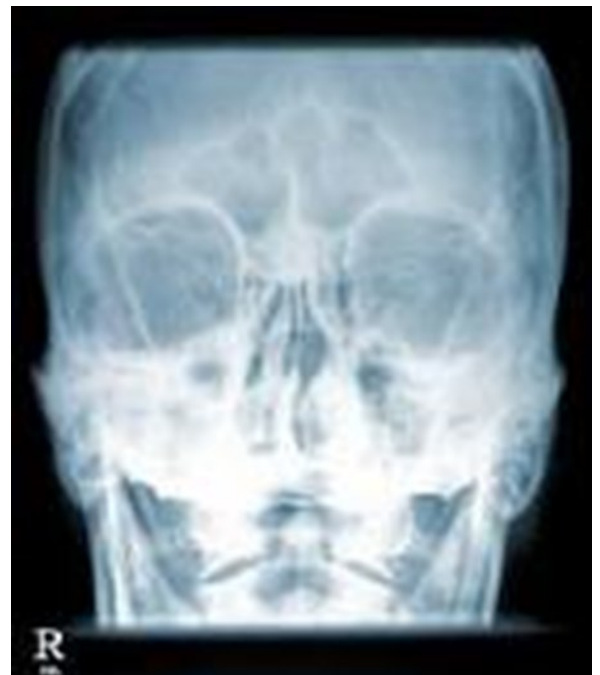- *Bucky/Grid*
- *40" S.I.D*
- *10x12 Image Receptor*
- *Length wise*
- *80 kVp*
- *Suspended*
- **Body Position: Upright facing the image receptor**
- **Part Position: Place the nose and forehead on the IR centering the midsagittal plane to the IR.**



**Central Ray: 15 degree caudal angle exiting at the nasion.**

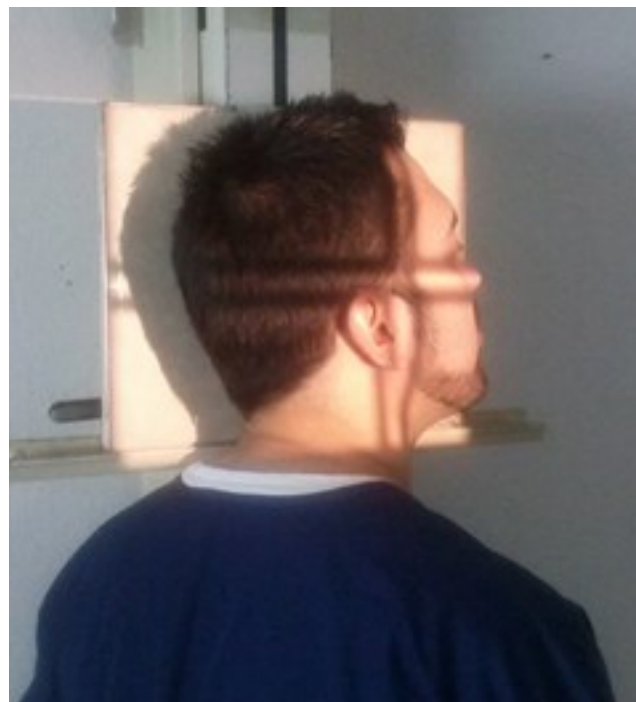
## **Evaluation Criteria:**

- Petrous pyramids in the lower third of the orbits
- No rotation as demonstrated by symmetric petrous ridges and equal distance from lateral boarder of the skull to the lateral boarder of the orbit.
- Uniform penetration and density
- Image centered
- Close collimation
- Correct side marker visualized



# Lateral Skull

- *Bucky/Grid*
- *40" S.I.D*
- *10x12 Image Receptor*
- *Length wise*
- *80 kVp*
- *Suspended*



**Body Position; Erect or lateral recumbent**

**Part Position: Midsagittal plane parallel to the IR**

**Central Ray: Perpendicular to a point 2" above the EAM and centered on the IR**

## **Evaluation Criteria:**

- No rotation or tilt
- Sella turcica in profile
- No overlap of c-spine by the mandible
- Superimposed TMJ's
- Superimposed mastoid and EAM
- Superimposed orbital roofs and greater wings of sphenoid
- Uniform penetration and density
- Image centered
- Close collimation
- Correct side marker visualized

