



Is 3-Dimensional Echocardiography Essential for Intraoperative Assessment of Mitral Regurgitation?

Three-dimensional Echocardiography Is Essential for Intraoperative Assessment of Mitral Regurgitation

Wendy Tsang, MD; Roberto M. Lang, MD

Since its introduction, 3-dimensional (3D) transesophageal echocardiography (TEE) has become widely adopted in operating rooms and cardiac catheterization laboratories worldwide. This is because the matrix-array 3D TEE probe allows acquisition of high-quality 3D images in real time with relatively little training. The rapid adoption of this technology has proven that this innovative imaging modality provides additional clinical information beyond that obtained from 2-dimensional (2D) TEE images. These developments have enabled medical centers to create integrated valve programs in which surgeons, interventionalists, and echocardiographers discuss cases and surgical approaches.

Response by McCarthy on p 652

In particular, 3D TEE has been proven to be superior to 2D TEE in the assessment of both mitral valve anatomy and mitral regurgitation, promoting its use in the operating room (Table 1).¹⁻³ One reason for this superiority is that 3D TEE allows the mitral valve to be displayed en face in an orientation identical to the surgeon's view of the mitral valve intraoperatively. This surgeon's view greatly facilitates communication with cardiac surgeons because they can easily interpret these images.

Here, we argue that the widespread acceptance and use of 3D TEE are attributable to the pivotal role this modality plays in the intraoperative assessment of mitral regurgitation. We believe that 3D TEE of the mitral valve is invaluable not only because of the realistic images it provides

but also because it improves: 1) lesion localization, 2) identification of the mechanisms causing mitral regurgitation, 3) quantification of the severity of mitral regurgitation, 4) selection of surgical intervention, 5) the choice of the surgeon whose expertise is best suited to perform the operation, 6) guidance of percutaneous mitral valve procedures, and 7) postoperative assessment.

3D Echocardiography of the Mitral Valve

Accurate preoperative assessment of the mitral valve is critical in the surgical management of patients with severe mitral regurgitation. This information determines whether the patient should undergo valve repair or replacement, which has implications in terms of timing of surgery and long-term morbidity and mortality.⁴ Traditionally, 2D TEE has been used to evaluate mitral valve anatomy. However, 2D TEE requires manual manipulation of the transducer in the esophagus and various degrees of flexion or antelexion of the probe to acquire the standard mid-esophageal views and to examine all leaflet scallops. Since 2D TEE only provides single plane images, the entire mitral annulus and leaflets are not displayed in a single en face view, making it difficult to identify specific scallops with precision. As well, because the mitral annulus is saddle shaped, distortions of mitral valve anatomy, mitral annular dilatation, or aortic root enlargement may change the orientation of the ultrasound plane in relation to mitral valve apparatus, resulting in scallop misidentification.

The opinions expressed in this article are not necessarily those of the editors or of the American Heart Association.

From Toronto General Hospital, University of Toronto, Toronto, ON, Canada (W.T.); University of Chicago Medical Center, Chicago, IL (R.M.L.).

This article is Part I of a 2-part article. Part II appears on p 653.

Correspondence to Roberto M. Lang, MD, 5841 S Maryland Ave, MC 5084, Chicago, IL 60637. E-mail rlang@medicine.bsd.uchicago.edu (*Circulation*. 2013;128:00-00.)

© 2013 American Heart Association, Inc.

Circulation is available at <http://circ.ahajournals.org>

DOI: 10.1161/CIRCULATIONAHA.112.120501

Table 1. Advantages of 3D Echocardiography in the Evaluation of Mitral Regurgitation in the Operating Room

Provides real-time, detailed, en-face 3D and multi-planar images of the mitral valve for assessment of anatomy.
Makes quantitative analysis of mitral valve anatomy, function, and motion more accurate and reproducible
Makes quantitative analysis of mitral regurgitation severity more accurate and reproducible
Improves the surgical strategy used to repair degenerative mitral valve disease
Provides mechanistic insight into the pathophysiology of ischemic mitral regurgitation and possible novel reparative strategies
Improves assessment and monitoring of catheter-based interventions for paravalvular and valvular mitral regurgitation

3D indicates 3-dimensional.

More significantly, correct identification of the location and extent of mitral valve pathology is highly dependent on experience because it requires the operator to be skilled at mentally reconstructing the mitral valve in 3D from multiple tomographic 2D TEE images. Three-dimensional TEE is less operator dependent because the entire mitral valve can be visualized in a single view, allowing simultaneous examination of both leaflets from either the left ventricular or the left atrial perspectives. This allows the identification of the location and extent of abnormal scallops while simultaneously providing information on the spatial relationship of the mitral valve apparatus with adjacent anatomic structures.

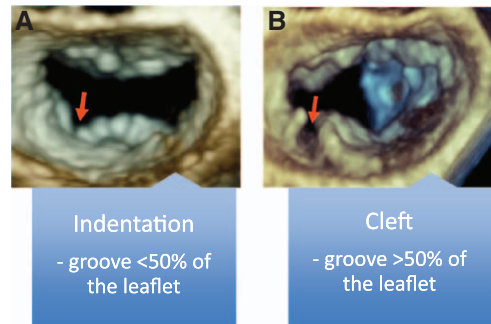


Figure 1. Recognition and differentiation of mitral valve indentations and clefts. Zoomed 3-dimensional transesophageal echocardiography images of the mitral valve, as seen from the left atrium with the anterior leaflet located at the 12 o'clock position, demonstrating a posterior leaflet indentation (**left**) and a posterior leaflet cleft (**right**).

3D Echocardiography Improves Lesion Localization and Quantification

Compared with 2D TEE, 3D TEE not only allows better identification of a single prolapsed scallop but also helps identify the dominant lesion in patients with complex prolapse resulting from multisegment involvement or commissural lesions.^{1-3,5-9} Importantly, the identification of commissural lesions has greatly improved with 3D TEE with published sensitivity, specificity and accuracy ranging from 89% to 92%, 95% to 99% and 93% to 97%, respectively. This is higher than the sensitivity (54%-66%), specificity (90% to 95%) and accuracy (82% to 89%) reported with 2D TEE.⁵ Beyond mitral valve prolapse, 3D TEE is superior in recognizing indentations and

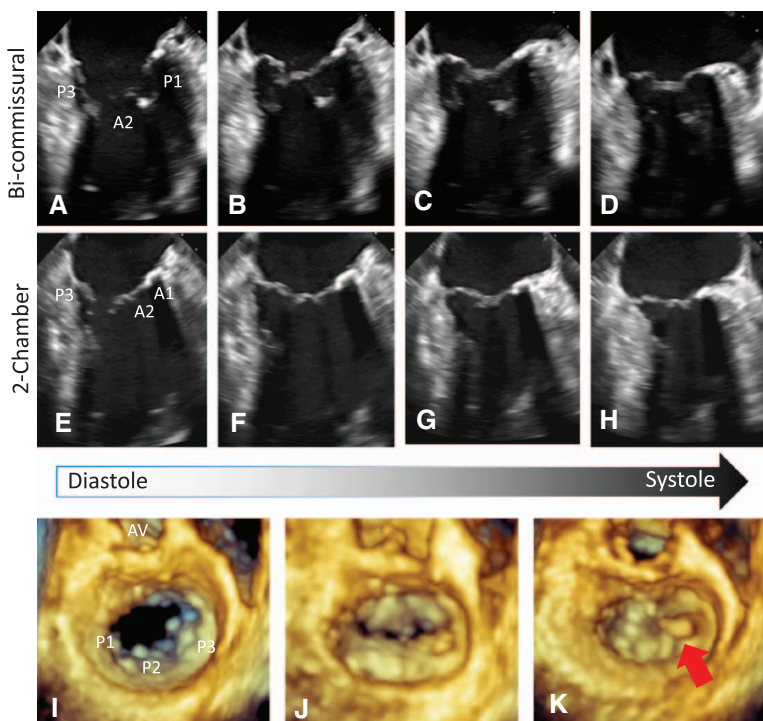



Figure 2. Commissural flail lesion images on 2- and 3-dimensional transesophageal echocardiography (TEE) from the same patient. Two-dimensional TEE images of the mitral valve from the bicommissural (**A-D**) and 2-chamber (**E-H**) views displayed as a series of still frames from ventricular diastole to systole (**I to K**). Note that the P3 scallop appears prolapsed. From the 3-dimensional TEE images of the same valve, oriented as viewed from the left atrium with the anterior leaflet located at the 12 o'clock position, demonstrating on the end-systolic image that the leaflet is flail, as demonstrated by a pointed scallop (red arrow). AV indicates aortic valve; A1, A1 segment; and A2, A2 segment.



clefts, which are grooves separating the posterior mitral valve leaflet scallops with depths that are <50% or >50% of the leaflet lengths, respectively (Figure 1).³ During surgical inspection while the heart is flaccid, these clefs and indentations are difficult to identify, especially when the scallops are diseased. Three-dimensional TEE examination of the mitral valve during ventricular systole improves identification of these leaflet abnormalities, which may be a source of residual postoperative mitral regurgitation (Figure 2). However, it must be noted that the proper diagnosis of mitral valve clefs on 3D TEE requires operators experienced in the acquisition and interpretation of 3D TEE because a reduction in gain settings causing dropout may result in over diagnoses.

3D TEE imaging also allows the measurement of new parameters quantifying mitral valve annular, leaflet, and subvalvular geometry throughout the cardiac cycle.^{10,11} These measurements have been found to be highly accurate when compared with direct intraoperative measurements and are highly reproducible, ensuring that changes in serial measurements reflect true changes and not differences in interpreter measurement techniques.^{3,8,12} In addition, these measurements provide considerable mechanistic insight into the complex annular alterations that occur in degenerative and ischemic mitral valve disease and the conformational changes that occur in both the mitral and aortic annuli with mitral valve repair.² For example, patients with degenerative mitral valve disease have significantly larger annular dimensions with abnormal function because these annuli fail to achieve saddle-shaped accentuation during ventricular systole. Additionally, these morphological changes result in significant intercommissural dilation and mitral regurgitation.

Paralleling the development of volumetric software capable of quantifying mitral valve anatomy has been the development of 3D parametric maps, which are 3D color-encoded topographical displays of the mitral valve in which color gradations indicate the degree of leaflet displacement into the left atrium relative to the mitral annular plane (Figure 3). These parametric maps have been shown to improve the accuracy of novice and intermediate interpreters in identifying mitral valve pathology.¹³ With measurements obtained from these parametric images, it has been shown that in degenerative mitral valve disease, prolapsing height and anterior leaflet surface area are the strongest predictors of surgical repair complexity, regardless of mitral regurgitation origin.⁸ Thus, parametric maps are useful to improve intraoperative diagnostic accuracy and to guide surgery, especially at centers with lower mitral valve repair volumes and lower success rates.¹⁴

3D Echocardiography Improves the Identification of Mechanisms of Degenerative Mitral Regurgitation

It cannot be emphasized enough that the type of degenerative mitral valve disease (ie, Barlow's versus fibroelastic deficiency disease) has significant surgical implications. First, the particular etiology will influence the type and complexity of lesions the surgeon will encounter at the time of surgery,

which in turn will influence the techniques required to achieve a successful repair. Second, different techniques require different levels of surgical expertise and experience, so understanding the mitral regurgitant mechanism has a direct impact on the choice of surgeon performing the operation. Therefore, it is imperative that 3D echocardiography be used as it has been shown to accurately predict repair complexity.¹⁵

Mitral valve disease complexity is best described by defining: 1) the origin of the disease (ie, primary/direct versus secondary/indirect), 2) the specific lesion caused by the disease, and 3) the dysfunction it creates on the mitral valve apparatus.¹⁶ Regardless of origin, each disease process frequently results in >1 lesion, which in turn leads to valve dysfunction. Historically, the Carpentier classification for mitral regurgitation lesions provided a systematic method to categorize the mechanisms of mitral regurgitation to determine the surgical strategy (Table 2). However, even with modifications, this classification system neglects to include papillary muscle motion abnormalities.¹⁷ For example, mitral papillary muscle traction, a phenomenon described in Barlow's disease, occurs when excess systolic loading on the chordae causes the tips of the papillary muscles to move toward the mitral annulus during systole, rather than toward the left ventricular apex, causing regurgitation.^{18,19} More significantly, 3D TEE provides in greater detail information on the pathomorphological changes in the mitral valve, allowing a tailored approach rather than a standard approach in which a pre-established operation is performed according to the Carpentier classification system. Indeed, in many patients, more than 1 single mechanism of mitral regurgitation is present, reducing the utility of the Carpentier classification system, especially when a detailed description from 3D TEE can be provided.

Compared with 2D TEE, 3D TEE is superior in identifying the mechanism of mitral regurgitation.^{15,20} For instance, in degenerative mitral valve disease, when the chordae are of normal length, even when leaflet billowing is present, the mitral valve will usually remain competent. Once lengthening of the chordae tendinae is present, leaflet prolapse or chordal rupture may occur, resulting in mitral regurgitation. Repair of these lesions may require complex leaflet reconstruction techniques such as sliding plasty, reduction of anterior leaflet height, or use of large-diameter annuloplasty rings.²¹ By quantifying leaflet billowing volumes and chordal length, 3D TEE assists the surgeon in determining target chordal lengths and the size of leaflet area to be resected for the repair.⁸ Finally, it must be recognized that if the chordae and leaflets are intact, mitral regurgitation can occur simply as a result of annular dilatation, which can be completely assessed with a single 3D TEE mitral valve dataset.

3D Echocardiography Improves the Identification of Mechanisms of Functional and Ischemic Mitral Regurgitation

Functional mitral regurgitation results from geometric ventricular remodeling with secondary valve leaflet pathology.

Typically, after myocardial infarction, there is left ventricular remodeling, which leads to a more globular-shaped left ventricle with diastolic papillary muscle tethering. This frequently results in an asymmetrical jet of mitral regurgitation originating from either the medial or lateral mitral commissure. Although the valve leaflets and chordae were believed to be normal in structure, recent 3D echocardiography studies indicate that the mitral valve leaflets are thickened, which on histology is attributable to an increase in the interstitium through endothelial-mesenchymal transdifferentiation.^{22,23} Additionally, 3D TEE studies have demonstrated that there is asymmetrical elongation of the papillary muscles, causing a reduction of the leaflet coaptation surface area and resulting in mitral regurgitation.²³ Symmetrical distortion of the mitral valve annulus has also been described. This not only enlarges but also flattens the annulus so that the saddle shape is lost, resulting in increased leaflet stress.

Historically, literature on ischemic mitral regurgitation postulated that the mechanism was attributable to posteromedial papillary muscle dysfunction caused by interrupted blood flow. However, 3D TEE studies have shown that the papillary muscle dysfunction is only one of the mechanisms responsible for ischemic mitral regurgitation. In fact, there is a wide spectrum of geometric distortions secondary to left ventricular remodeling that result in posteromedial papillary muscle displacement, causing this type of valve dysfunction.²⁴

It must be noted that although the description of ischemic mitral regurgitation is similar to that of functional mitral regurgitation, these 2 entities are distinctly different. Three-dimensional echocardiographic studies have demonstrated that ischemic mitral regurgitation is associated with an asymmetrical deformation of the mitral annulus, whereas nonischemic functional mitral regurgitation has a more symmetrical deformation.^{25,26} In addition, 3D TEE has demonstrated that the papillary muscle tethering lengths, which are the distances between the tips of the papillary muscle and the mitral annulus, are uneven in patients with ischemic mitral regurgitation.²⁰ Consequently, appreciation of mitral annular symmetry or lack of symmetry in ischemic and functional mitral regurgitation requires a 3D imaging technique. Ultimately, the differences in mitral and ventricular geometry suggest that surgical treatment would likely be more successful if asymmetrical geometric annular changes were treated with an asymmetrical annuloplasty ring and symmetrical annular changes were treated with a symmetrical annuloplasty ring.

3D Echocardiography Improves Quantification of Mitral Regurgitation Severity

Accurate quantification of mitral regurgitation severity plays an important role in patient management. Three-dimensional TEE is ideally suited to evaluate the complex geometry of both the mitral apparatus and the regurgitant jet in patients with mitral regurgitation. Direct assessment of the vena contracta by 3D echocardiography has revealed significant asymmetry

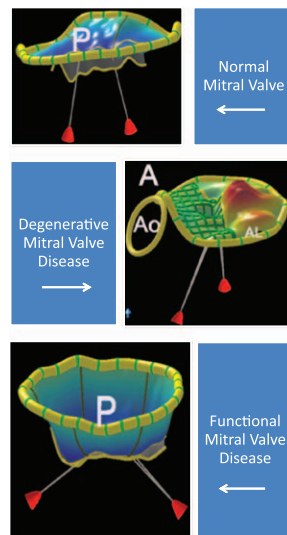


Figure 3. Peak systolic parametric mitral valve maps derived from 3-dimensional echocardiographic images. Parametric map of a normal mitral valve positioned to visualize the leaflet coaptation area and location of the papillary muscles below the valve annulus (**top row**). The color on the parametric maps indicates the degree of leaflet displacement into the left atrium from the mitral annulus. With degenerative mitral valve disease, the parametric map (**middle row**) demonstrates prolapse of the P1 and P2 scallops (orange color). With functional mitral regurgitation, the parametric map (**bottom row**) demonstrates a dilated annulus with loss of the normal saddle shape and tenting of the leaflets, preventing their motion back to the annular plane. AL indicates anterolateral; Ao, aortic annulus; and P, posterior.

in the vena contracta area in mitral regurgitation (Figure 4).²⁷ Recognition of this asymmetry challenges the notion that the proximal flow convergence region is hemispheric, highlighting the source of error in estimating effective regurgitant orifice area and thus mitral regurgitation severity from single-plane vena contracta width measurements.²⁸ Studies have shown that estimates of effective regurgitant orifice area are more accurate when an elliptical-based formula is used to calculate effective regurgitant orifice area rather than a hemispheric-based one.^{28,29} In fact, when fluid dynamic modeling is used, the shape of the flow convergence shell close to an irregular, nonplanar orifice results in an asymmetrical isovelocity shell, whereas farther from the orifice, it becomes more hemispheric.³⁰ This implies that although the proximal isovelocity surface area may appear symmetrical on single cut-plane 2D image, because of the hemispheric assumptions in the calculation, the accuracy of a proximal isovelocity surface area measurement derived from this image would be highly dependent on the distance of the measured radius from the regurgitant orifice.

Overall, 3D color Doppler assessment improves mitral regurgitation quantification by improving estimation of the effective regurgitant orifice area with direct 3D echocardiographic vena contracta area or proximal isovelocity surface area measurements. However, it must be noted that the use of 3D TEE color Doppler is still limited by low frame rate even with multibeat acquisitions and the need for breath hold

**Table 2. The Carpentier Functional Classification System for Mitral Valve Dysfunction With Modification***

Mitral Valve Dysfunction Type	Mechanism of Mitral Valve Dysfunction	
	Leaflet Motion	Mechanism of Regurgitation
I	Normal leaflet margin motion	Perforation Cleft valve Dilated annulus without leaflet tethering
II	Excessive leaflet motion	Flail leaflet (localized to one segment) Billowing prolapse Bileaflet prolapse with flail segment
IIIA	Restricted leaflet motion	Systolic and diastolic restriction (ie, rheumatic)
IIIB	Restricted systolic leaflet motion	Symmetrical systolic restriction from dilated annulus with leaflet tethering (ie, dilated cardiomyopathy) Asymmetrical systolic restriction (segmental ischemic dysfunction with focal tethering)
IV	SAM of the leaflets	Hypertrophic cardiomyopathy with SAM-related mitral regurgitation Post-mitral valve repair SAM Hemodynamic-induced SAM
V	Hybrid condition	Anterior leaflet prolapse with restricted posterior leaflet Posterior leaflet prolapse with SAM of the anterior leaflet Intrinsic leaflet pathology with infective endocarditis lesion

SAM indicates systolic anterior motion.

*from Shah and Raney.¹⁷

to minimize stitch artifacts. However, these issues are being addressed with new 3D TEE acquisition modes.

Research has also shown that estimation of mitral regurgitation severity is improved through increased accuracy in measuring the 3D anatomic regurgitant orifice area. Mitral regurgitant anatomic regurgitant orifice area has been shown to be inaccurate when measured from a single 2D echocardiography imaging plane because the majority of patients have complex, nonplanar, irregularly shaped orifices.^{30,31} With direct 3D TEE measurement of the anatomic regurgitant orifice area, the maximal area can be obtained, and in patients with multiple regurgitant orifices, areas of the different orifices can be planimetered and added together to obtain an accurate assessment of regurgitation severity.

One of the great strengths of 3D compared with 2D echocardiography is that it allows stroke volume quantification independently of geometric or flow profile assumptions or reliance on a single-plane measurement. Measurement of a region of interest from a 3D color Doppler data set permits the calculation of left ventricular outflow and mitral inflow stroke volume, which can be used to determine mitral regurgitant volume. Studies using this methodology have found that the quantification of mitral regurgitation is significantly more accurate and reproducible than that obtained with 2D echocardiography.^{32,33} Because this technique is automated, use in the operating room is extremely feasible to increase the accuracy of mitral regurgitation severity assessments.

3D Echocardiography Helps With Surgical Triage

The American College of Cardiology/American Heart Association guidelines recommend performing mitral valve

repair at experienced centers, assuming that the likelihood of repair is $\geq 90\%$.^{4,34} This high success rate, regardless of mitral regurgitation origin, can be seen in centers with reference mitral valve repair surgeons. Although no program exists for accreditation as a reference mitral valve repair surgeon, it has been suggested that surgeons should perform >25 repairs per year and hospitals >50 repairs per year.³⁴ It must also be noted that although volume is an important component of surgical outcome, the case-mix complexity must also be high to maintain high competency.³⁴

However, in the general cardiac surgical community, the success rate of mitral valve repair surgery is $\approx 50\%$.^{35,36} Reasons for this lower success rate include complex regurgitant lesions such as anterior or bileaflet multisegmental disease, significant annular calcification, and giant excess tissue, which require the use of more advanced surgical techniques to achieve a successful repair. Even in experienced hands, anterior leaflet prolapse is a predictor of reoperation, and patients with anterior or bileaflet prolapse are more likely to have postoperative recurrent moderate or severe mitral regurgitation (Figure 5).³⁷ Thus, surgeons performing <25 mitral repair cases per year with the majority of their operations for isolated P2 disease lack the expertise to operate on anterior or multisegment prolapse. Therefore, patients are better served if only patients with mitral regurgitation caused by isolated segmental prolapse of the posterior mitral leaflet are referred to nonreference surgeons because these repairs are technically straightforward and thus more often successful.³⁸

Given the relative importance of surgical expertise on mitral valve repair success rates, the perioperative 3D TEE study is crucial in determining whether a patient should be referred to a reference mitral valve repair surgeon. One reason is that quantitative analysis of mitral valve anatomy from 3D TEE

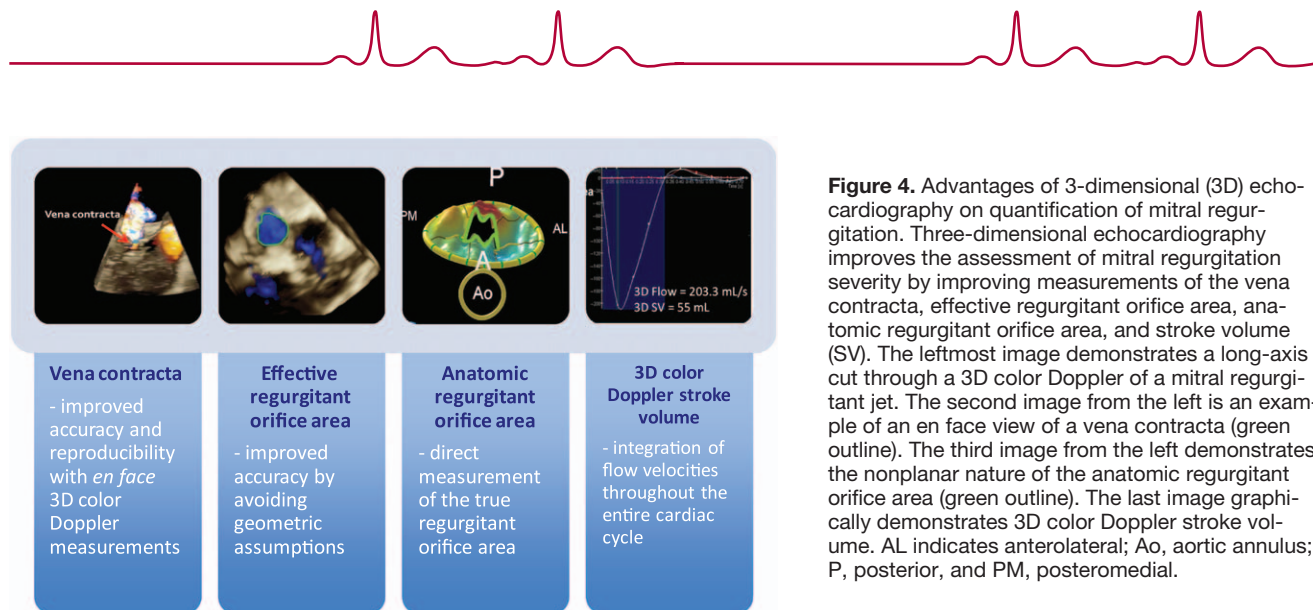


Figure 4. Advantages of 3-dimensional (3D) echocardiography on quantification of mitral regurgitation. Three-dimensional echocardiography improves the assessment of mitral regurgitation severity by improving measurements of the vena contracta, effective regurgitant orifice area, anatomic regurgitant orifice area, and stroke volume (SV). The leftmost image demonstrates a long-axis cut through a 3D color Doppler of a mitral regurgitant jet. The second image from the left is an example of an en face view of a vena contracta (green outline). The third image from the left demonstrates the nonplanar nature of the anatomic regurgitant orifice area (green outline). The last image graphically demonstrates 3D color Doppler stroke volume. AL indicates anterolateral; Ao, aortic annulus; P, posterior, and PM, posteromedial.

data has been shown to clearly differentiate Barlow's from fibroelastic deficiency disease.⁸ Chandra et al⁸ demonstrated that a 3D billowing volume of 1.15 mL can differentiate between these two entities. In addition, 3D TEE can identify subtle pathology unrecognized on 2D TEE studies such as a mitral valve cleft.^{3,5} Overall, the use of 3D TEE can accurately classify the mechanism and origin of mitral regurgitation and thus determine the type of repair and level of surgical expertise required.

3D Echocardiography Changes the Operation Performed

As discussed previously, in degenerative mitral regurgitation, mitral annular, leaflet, and subvalvular measurements from 3D TEE may modify the type of operation performed. Currently, there are 2 main surgical techniques performed for mitral valve repair: 1) the Carpentier technique, which involves leaflet resection to restore normal leaflet geometry and implantation of a rigid or semirigid annuloplasty ring; and 2) the American correction, in which the mitral valve leaflets are never resected, and instead artificial polytetrafluoroethylene chordae are used to correct localized leaflet prolapse, and a flexible annuloplasty ring is implanted. The American correction technique was developed to reduce post-operative leaflet and chordal stress and ultimately restore normal dynamic valve function. This technique has been shown to have a freedom from reoperation at 10 years of 90% and freedom from recurrent mitral regurgitation at 10 years of 94%.³⁹ This success is reflected by early post-operative 3D TEE studies that demonstrate preservation of dynamic changes in mitral annular structure during the cardiac cycle in patients who receive the American correction when compared with patients who received the Carpentier method.^{2,40,41} In particular, the use of a flexible annuloplasty ring has been shown to preserve physiological mitral annular folding dynamics, which may be important in long-term valve function and prevention of left ventricular outflow tract obstruction.⁴² Ultimately, the repair technique chosen by the surgeon will require great input from

the 3D TEE study because it has been shown that a nearly 100% repair rate can be achieved when a single technique is not used to repair all valves and that the surgeon adapts resectional and nonresectional techniques to the lesions seen in each valve.⁴³

Similarly, for ischemic mitral regurgitation, 3D TEE will play an increasing role because there is growing evidence that mitral valve repair at the time of revascularization is associated with improved outcomes.⁴⁴ Currently, regardless of the morphoanatomic mechanism of ischemic mitral regurgitation, the majority of surgeons intervene by reducing the mitral annular size with a downsized annuloplasty ring. This simplistic and uniform approach results in suboptimal results because a significant number of patients will experience recurrent mitral regurgitation after repair.⁴⁵ One reason for the recurrence of mitral regurgitation after annuloplasty is that although the annuloplasty ring shifts the posterior annulus and leaflet anteriorly, the anterior annulus remains fixed at the aortic root.^{46,47} This further exacerbates the apical tethering of the chordae and restricts posterior leaflet motion, resulting in recurrent mitral regurgitation, continued left ventricular remodeling, and ultimately poor patient outcome.⁴⁸

To improve surgical outcomes, an individualized surgical plan for each patient directed toward the predominant mechanism of the ischemic mitral regurgitation should be developed. For instance, 3D TEE studies have demonstrated that in patients with severe ischemic mitral regurgitation, the leaflet site where peak tenting occurs varies for each patient.⁴⁹ This suggests that different chordae are involved in the disease process and that treatment with an individualized approach geared toward chordal cutting is required. For this to become feasible, accurate intraoperative quantitative information is required that is best obtained with 3D TEE.

Overall, the 3 fundamental principles guiding mitral valve reconstruction are: 1) preserving or restoring normal leaflet motion, 2) creating a large surface of leaflet coaptation, and remodeling and 3) stabilizing the annulus.¹⁶ Three-dimensional TEE measurements can be used by the surgeon

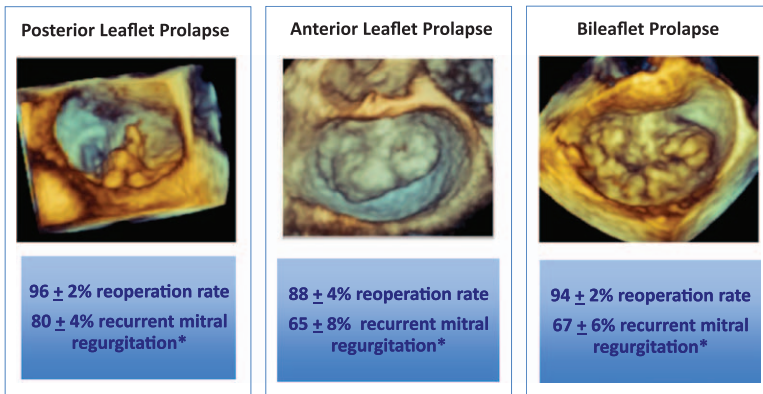


Figure 5. Freedom from reoperation and recurrent moderate or severe mitral regurgitation at 12 years by lesion type. Three-dimensional echocardiographic images demonstrating posterior, anterior, and bileaflet mitral valve prolapse (top, left to right). With increasingly complex mitral valve pathology ranging from posterior leaflet prolapse to anterior leaflet prolapse to bileaflet prolapse, 12-year freedom from reoperation and recurrent moderate or severe mitral regurgitation decreases, as demonstrated with data from David et al.³⁷

*Moderate or severe regurgitation. Source: David TE et al. A comparison of outcomes of mitral valve repair for degenerative disease with posterior, anterior, and bileaflet prolapse. *The Journal of thoracic and cardiovascular surgery*. 2005;130:1242-1249

to tailor surgical choices with respect to annuloplasty ring characteristics, ring size, the need for leaflet resection, and papillary neochord or chord-cutting implantation.^{45,50} For instance, quantitative 3D TEE measurements obtained before and after surgery of the mitral annular shape, height, and intercommissural diameter will help predict the likelihood of success, given how closely the postrepair mitral annulus is restored to its natural saddle shape and function. In turn, this knowledge might provide prognostic information on the durability of various approaches to mitral valve repair and may further improve surgical repair techniques. However, it must be noted that there are still immeasurable variables affecting leaflet position after annuloplasty. Some areas of prolapse may be resolved with placement of the annuloplasty ring, but others may appear, which increases the complexity and skill needed intraoperatively. Thus, mitral valve repairs require not only accurate intraoperative imaging but also an experienced surgeon.

3D Echocardiography Helps in the Hybrid Operating Room

The number of hybrid operating rooms is increasing worldwide because of the popularity of catheter-based treatments for mitral valvular and paravalvular regurgitation, which are frequently performed jointly by cardiac and vascular surgeons and cardiac interventionalists. Catheter-based edge-to-edge repair of mitral regurgitation with a clip device has recently been shown to reduce the total regurgitant orifice and to improve patient symptoms and functional capacity.⁵¹ Before this procedure, 3D TEE is useful in defining the mitral valve anatomy, identifying and localizing the lesion, and determining whether the mitral valve dysfunction is suitable for percutaneous repair. In addition, 3D TEE has become invaluable in guiding this procedure. Traditionally, fluoroscopy was used to guide percutaneous procedures; however, 3D TEE is clearly superior because it provides lifelike 3D images of the mitral valve anatomy and catheters during the procedure. In particular, during clip deployment, views available from 3D TEE such as the en face view allow visualization of both leaflets in

real time, which is useful for clip positioning, quantification of the coaptation surface lengths, and assessment of postdeployment mitral regurgitation. A second procedure gaining popularity is the use of percutaneous interventions for the treatment of paravalvular regurgitation. Three-dimensional TEE is superior for locating and quantifying the severity of the paravalvular leak and for monitoring the procedure and evaluating postprocedural complications.

Without exception, 3D TEE should be mandatory for these hybrid interventions because they improve en face visualization of the mitral valve and the position of the intracardiac catheters, resulting in decreased procedural time and radiation doses. Given these benefits, recent American Society of Echocardiography/European Association of Echocardiography

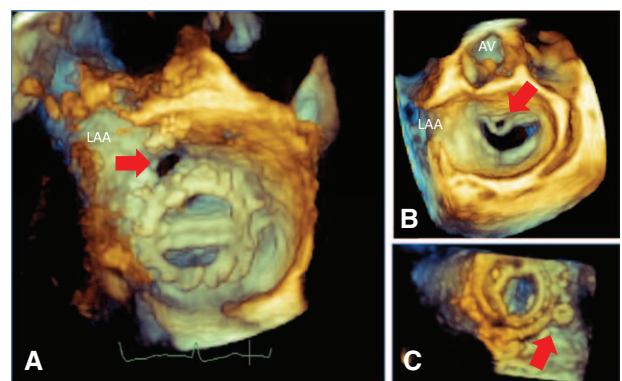


Figure 6. Examples of paravalvular and valvular regurgitation and percutaneous treatment. Three-dimensional transesophageal echocardiographic image of a bileaflet mechanical mitral valve, viewed en face from the left atrial perspective with the aortic valve located at the 12 o'clock position, demonstrating a paravalvular leak (red arrow, **A**). Three-dimensional transesophageal echocardiographic image of the mitral valve viewed en face from the left atrial perspective demonstrating an anterior leaflet perforation (red arrow, **B**). Three-dimensional transesophageal echocardiographic image of a tilting leaflet mechanical mitral valve viewed en face from the left atrial perspective demonstrating an occluder device in a paravalvular leak (red arrow, **C**). AV indicates aortic valve; and LAA, left atrial appendage.

3D echocardiography guidelines recommend the use of 3D TEE for the guidance of percutaneous procedures.⁵²

3D Echocardiography Improves Postoperative Assessment

Whether a patient undergoes valve replacement or repair, 3D TEE plays an important role in the postoperative assessment (Figure 6). This postoperative assessment always includes assessment of residual mitral regurgitation, mitral stenosis, and systolic anterior motion of the mitral valve.

Systolic anterior motion, in which the anterior leaflet of the mitral valve obstructs the left ventricular outflow tract and fails to coapt, causing postoperative mitral regurgitation, is a unique complication of mitral valve repair surgery affecting between 10% and 14% of patients.⁴⁵ It generally occurs when the postrepair leaflet coaptation line is located in the center of the mitral annulus instead of its normal posterior position. This results when the residual posterior leaflet is tall or the chosen annuloplasty ring size does not accommodate the enlarged myxomatous leaflets.⁵³ By preoperatively quantifying the extent of the excess length, surface area, and billowing volume of the anterior and posterior leaflets, 3D TEE analysis helps identify patients at risk for developing systolic anterior motion.^{54–58} Additionally, 3D TEE improves sizing of the mitral annuloplasty ring and may help identify possible interventional targets in patients with persistent mitral regurgitation from systolic anterior motion despite rerepair or myectomy for left ventricular obstruction. Overall, 3D TEE has improved our understanding of the relationship between the mitral apparatus and adjacent structures such as the aortic root, which is important because distortion of the left ventricular outflow tract from rigid mitral annuloplasty rings can play a role in systolic anterior motion.

Postoperative valvular and paravalvular mitral regurgitation must be assessed after the repair or replacement because residual moderate to severe mitral regurgitation is generally considered significant and may require reinitiation of cardiopulmonary bypass and exploration of the surgical repair. The en face 3D TEE views provides a rapid method for identifying valvular versus paravalvular regurgitation and quantifying severity.^{59,60}

Conclusions

Three-dimensional TEE is essential in the operative assessment of mitral regurgitation because accurate determination of origin, lesion localization, and severity is required to determine the surgical techniques and skill level needed to repair the valve. This in turn establishes the expertise of the surgeon to whom the patient should be referred for mitral valve repair. In addition, these initial findings allow postoperative prediction of long-term success and monitoring of complications that may occur.

With the increasing popularity of hybrid procedures in the treatment of mitral regurgitation, 3D TEE plays a critical role not only in the preprocedural and postprocedural mitral

regurgitation assessment but also in guiding the procedure. In addition, understanding the changes in the 3D anatomy of the mitral valve will improve the repair techniques used, leading to more sustainable long-term results.

One limitation of the current use of 3D TEE is the lack of large trials comparing the additive value of 3D over 2D imaging. Although these data exist in small, single-center studies, reproducibility and validation, especially with newly developed automated software, are still needed.

Finally, the promise of 3D TEE in the future is that it allows the entire mitral valve apparatus and the interacting cardiac structures to be accurately recorded and measured throughout the cardiac cycle. Before the development of 3D imaging, the importance of these supporting structures was poorly understood and underappreciated. Additionally, the effects of various mitral valve techniques on these structures were ignored. This ability to display to the surgeon changes above, below, and around the valve improves surgical understanding of these dynamic interactions and spurs the development of new techniques needed to reproduce normal mitral valve function postoperatively.

Disclosures


Dr Lang has received a small research grant from Philips Healthcare.


Sources of Funding

Dr Tsang received a research fellowship from the Canadian Institutes of Health Research.

References

1. Ahmed S, Nanda NC, Miller AP, Nekkanti R, Yousif AM, Pacifico AD, Kirklin JK, McGiffin DC. Usefulness of transesophageal three-dimensional echocardiography in the identification of individual segment/scallop prolapse of the mitral valve. *Echocardiography*. 2003;20:203–209.
2. Ben Zekry S, Nagueh SF, Little SH, Quinones MA, McCulloch ML, Karanbir S, Herrera EL, Lawrie GM, Zoghbi WA. Comparative accuracy of two- and three-dimensional transthoracic and transesophageal echocardiography in identifying mitral valve pathology in patients undergoing mitral valve repair: initial observations. *J Am Soc Echocardiogr*. 2011;24:1079–1085.
3. La Canna G, Arendar I, Maisano F, Monaco F, Collu E, Benussi S, De Bonis M, Castiglioni A, Alfieri O. Real-time three-dimensional transesophageal echocardiography for assessment of mitral valve functional anatomy in patients with prolapse-related regurgitation. *Am J Cardiol*. 2011;107:1365–1374.
4. Bonow RO, Carabello BA, Chatterjee K, de Leon AC Jr, Faxon DP, Freed MD, Gaasch WH, Lytle BW, Nishimura RA, O’Gara PT, O’Rourke RA, Otto CM, Shah PM, Shanewise JS. 2008 Focused update incorporated into the ACC/AHA 2006 guidelines for the management of patients with valvular heart disease: a report of the American College of Cardiology/American Heart Association Task Force on Practice Guidelines (Writing Committee to Revise the 1998 Guidelines for the Management of Patients With Valvular Heart Disease): endorsed by the Society of Cardiovascular Anesthesiologists, Society for Cardiovascular Angiography and Interventions, and Society of Thoracic Surgeons. *J Am Coll Cardiol*. 2008;52:e1–e142.
5. Pepi M, Tamborini G, Maltagliati A, Galli CA, Sisillo E, Salvi L, Naliato M, Porqueddu M, Parolari A, Zanobini M, Alamanni F. Head-to-head comparison of two- and three-dimensional transthoracic and transesophageal echocardiography in the localization of mitral valve prolapse. *J Am Coll Cardiol*. 2006;48:2524–2530.

- 
6. Gutiérrez-Chico JL, Zamorano Gómez JL, Rodrigo-López JL, Mataix L, Pérez de Isla L, Almería-Valera C, Aubele A, Macaya-Miguel C. Accuracy of real-time 3-dimensional echocardiography in the assessment of mitral prolapse. Is transesophageal echocardiography still mandatory? *Am Heart J*. 2008;155:694–698.
 7. Fabricius AM, Walther T, Falk V, Mohr FW. Three-dimensional echocardiography for planning of mitral valve surgery: current applicability? *Ann Thorac Surg*. 2004;78:575–578.
 8. Chandra S, Salgo IS, Sugeng L, Weinert L, Tsang W, Takeuchi M, Spencer KT, O'Connor A, Cardinale M, Settlemier S, Mor-Avi V, Lang RM. Characterization of degenerative mitral valve disease using morphologic analysis of real-time three-dimensional echocardiographic images: objective insight into complexity and planning of mitral valve repair. *Circ Cardiovasc Imaging*. 2011;4:24–32.
 9. Maffessanti F, Marsan NA, Tamborini G, Sugeng L, Caiani EG, Gripari P, Alamanni F, Jeevanandam V, Lang RM, Pepi M. Quantitative analysis of mitral valve apparatus in mitral valve prolapse before and after annuloplasty: a three-dimensional intraoperative transesophageal study. *J Am Soc Echocardiogr*. 2011;24:405–413.
 10. O'Gara P, Sugeng L, Lang R, Sarano M, Hung J, Raman S, Fischer G, Carabello B, Adams D, Vannan M. The role of imaging in chronic degenerative mitral regurgitation. *JACC Cardiovasc Imaging*. 2008;1:221–237.
 11. Berdajs D, Zünd G, Camenisch C, Schurr U, Turina MI, Genoni M. Annulus fibrosus of the mitral valve: reality or myth. *J Card Surg*. 2007;22:406–409.
 12. Grewal J, Suri R, Mankad S, Tanaka A, Mahoney DW, Schaff HV, Miller FA, Enriquez-Sarano M. Mitral annular dynamics in myxomatous valve disease: new insights with real-time 3-dimensional echocardiography. *Circulation*. 2010;121:1423–1431.
 13. Tsang W, Weinert L, Sugeng L, Chandra S, Ahmad H, Spencer K, Mor-Avi V, Lang RM. The value of three-dimensional echocardiography derived mitral valve parametric maps and the role of experience in the diagnosis of pathology. *J Am Soc Echocardiogr*. 2011;24:860–867.
 14. Gammie JS, O'Brien SM, Griffith BP, Ferguson TB, Peterson ED. Influence of hospital procedural volume on care process and mortality for patients undergoing elective surgery for mitral regurgitation. *Circulation*. 2007;115:881–887.
 15. Chikwe J, Adams DH, Su KN, Anyanwu AC, Lin HM, Goldstone AB, Lang RM, Fischer GW. Can three-dimensional echocardiography accurately predict complexity of mitral valve repair? *Eur J Cardiothorac Surg*. 2012;41:518–524.
 16. Carpentier A. *Pathophysiology, Preoperative Valve Analysis, and Surgical Indications*. Maryland, Heights, MO: Saunders-Elsevier; 2012.
 17. Shah PM, Raney AA. Echocardiography in mitral regurgitation with relevance to valve surgery. *J Am Soc Echocardiogr*. 2011;24:1086–1091.
 18. Sanfilippo AJ, Harrigan P, Popovic AD, Weyman AE, Levine RA. Papillary muscle traction in mitral valve prolapse: quantitation by two-dimensional echocardiography. *J Am Coll Cardiol*. 1992;19:564–571.
 19. Lee TM, Su SF, Huang TY, Chen MF, Liao CS, Lee YT. Excessive papillary muscle traction and dilated mitral annulus in mitral valve prolapse without mitral regurgitation. *Am J Cardiol*. 1996;78:482–485.
 20. Veronesi F, Corsi C, Sugeng L, Caiani EG, Weinert L, Mor-Avi V, Cerutti S, Lamberti C, Lang RM. Quantification of mitral apparatus dynamics in functional and ischemic mitral regurgitation using real-time 3-dimensional echocardiography. *J Am Soc Echocardiogr*. 2008;21:347–354.
 21. Quigley RL. Prevention of systolic anterior motion after repair of the severely myxomatous mitral valve with an anterior leaflet valvuloplasty. *Ann Thorac Surg*. 2005;80:179–182.
 22. Dal-Bianco JP, Aikawa E, Bischoff J, Guerrero JL, Handschumacher MD, Sullivan S, Johnson B, Titus JS, Iwamoto Y, Wylie-Sears J, Levine RA, Carpentier A. Active adaptation of the tethered mitral valve: insights into a compensatory mechanism for functional mitral regurgitation. *Circulation*. 2009;120:334–342.
 23. Saito K, Okura H, Watanabe N, Obase K, Tamada T, Koyama T, Hayashida A, Neishi Y, Kawamoto T, Yoshida K. Influence of chronic tethering of the mitral valve on mitral leaflet size and coaptation in functional mitral regurgitation. *JACC Cardiovasc Imaging*. 2012;5:337–345.
 24. Yosefy C, Beeri R, Guerrero JL, Vaturi M, Scherrer-Crosbie M, Handschumacher MD, Levine RA. Mitral regurgitation after antero-apical myocardial infarction: new mechanistic insights. *Circulation*. 2011;123:1529–1536.
 25. Otsuji Y, Handschumacher MD, Liel-Cohen N, Tanabe H, Jiang L, Schwammenthal E, Guerrero JL, Nicholls LA, Vlahakes GJ, Levine RA. Mechanism of ischemic mitral regurgitation with segmental left ventricular dysfunction: three-dimensional echocardiographic studies in models of acute and chronic progressive regurgitation. *J Am Coll Cardiol*. 2001;37:641–648.
 26. Vergnat M, Jassar AS, Jackson BM, Ryan LP, Eperjesi TJ, Pouch AM, Weiss SJ, Cheung AT, Acker MA, Gorman JH 3rd, Gorman RC. Ischemic mitral regurgitation: a quantitative three-dimensional echocardiographic analysis. *Ann Thorac Surg*. 2011;91:157–164.
 27. Kahlert P, Plicht B, Schenk IM, Janosi RA, Erbel R, Buck T. Direct assessment of size and shape of noncircular vena contracta area in functional versus organic mitral regurgitation using real-time three-dimensional echocardiography. *J Am Soc Echocardiogr*. 2008;21:912–921.
 28. Shiota T, Sinclair B, Ishii M, Zhou X, Ge S, Teien DE, Gharib M, Sahn DJ. Three-dimensional reconstruction of color Doppler flow convergence regions and regurgitant jets: an in vitro quantitative study. *J Am Coll Cardiol*. 1996;27:1511–1518.
 29. Matsumura Y, Saracino G, Sugioka K, Tran H, Greenberg NL, Wada N, Toyono M, Fukuda S, Hozumi T, Thomas JD, Yoshikawa J, Yoshiyama M, Shiota T. Determination of regurgitant orifice area with the use of a new three-dimensional flow convergence geometric assumption in functional mitral regurgitation. *J Am Soc Echocardiogr*. 2008;21:1251–1256.
 30. Chandra S, Salgo IS, Sugeng L, Weinert L, Settlemier SH, Mor-Avi V, Lang RM. A three-dimensional insight into the complexity of flow convergence in mitral regurgitation: adjunctive benefit of anatomic regurgitant orifice area. *Am J Physiol Heart Circ Physiol*. 2011;301:H1015–H1024.
 31. Yosefy C, Levine RA, Solis J, Vaturi M, Handschumacher MD, Hung J. Proximal flow convergence region as assessed by real-time 3-dimensional echocardiography: challenging the hemispheric assumption. *J Am Soc Echocardiogr*. 2007;20:389–396.
 32. Pemberton J, Jerosch-Herold M, Li X, Hui L, Silberbach M, Woodward W, Thiele K, Kenny A, Sahn DJ. Accuracy of real-time, three-dimensional Doppler echocardiography for stroke volume estimation compared with phase-encoded MRI: an in vivo study. *Heart*. 2008;94:1212–1213.
 33. Thavendiranathan P, Liu S, Datta S, Walls M, Nitinunu A, Van Houten T, Tomson NA, Vidmar L, Georgescu B, Wang Y, Srinivasan S, De Michelis N, Raman SV, Ryan T, Vannan MA. Automated quantification of mitral inflow and aortic outflow stroke volumes by three-dimensional real-time volume color-flow Doppler transthoracic echocardiography: comparison with pulsed-wave Doppler and cardiac magnetic resonance imaging. *J Am Soc Echocardiogr*. 2012;25:56–65.
 34. McCarthy PM. When is your surgeon good enough? When do you need a “referent surgeon”? *Curr Cardiol Rep*. 2009;11:107–113.
 35. Adams DH, Anyanwu AC. The cardiologist's role in increasing the rate of mitral valve repair in degenerative disease. *Curr Opin Cardiol*. 2008;23:105–110.
 36. Anyanwu AC, Bridgewater B, Adams DH. The lottery of mitral valve repair surgery. *Heart*. 2010;96:1964–1967.
 37. David TE, Ivanov J, Armstrong S, Christie D, Rakowski H. A comparison of outcomes of mitral valve repair for degenerative disease with posterior, anterior, and bileaflet prolapse. *J Thorac Cardiovasc Surg*. 2005;130:1242–1249.
 38. Adams DH, Anyanwu AC. Seeking a higher standard for degenerative mitral valve repair: begin with etiology. *J Thorac Cardiovasc Surg*. 2008;136:551–556.
 39. Lawrie GM, Earle EA, Earle N. Intermediate-term results of a nonresectional dynamic repair technique in 662 patients with mitral valve prolapse and mitral regurgitation. *J Thorac Cardiovasc Surg*. 2011;141:368–376.
 40. Ben Zekry S, Lang RM, Sugeng L, McCulloch ML, Weinert L, Raman J, Little SH, Xu J, Lawrie GM, Zoghbi WA. Mitral annulus dynamics early after valve repair: preliminary observations of the effect of resectional versus non-resectional approaches. *J Am Soc Echocardiogr*. 2011;24:1233–1242.
 41. Lawrie GM, Earle EA, Earle NR. Nonresectional repair of the Barlow mitral valve: importance of dynamic annular evaluation. *Ann Thorac Surg*. 2009;88:1191–1196.
 42. Dagum P, Timek T, Green GR, Daughters GT, Liang D, Ingels NB Jr, Miller DC. Three-dimensional geometric comparison of partial and complete flexible mitral annuloplasty rings. *J Thorac Cardiovasc Surg*. 2001;122:665–673.

- 
43. Castillo JG, Anyanwu AC, Fuster V, Adams DH. A near 100% repair rate for mitral valve prolapse is achievable in a reference center: implications for future guidelines. *J Thorac Cardiovasc Surg.* 2012;144:308–312.
44. Deja MA, Grayburn PA, Sun B, Rao V, She L, Krejca M, Jain AR, Leng Chua Y, Daly R, Senni M, Mokrzycki K, Menicanti L, Oh JK, Michler R, Wróbel K, Lamy A, Velazquez EJ, Lee KL, Jones RH. Influence of mitral regurgitation repair on survival in the surgical treatment for ischemic heart failure trial. *Circulation.* 2012;125:2639–2648.
45. Fedak PW, McCarthy PM, Bonow RO. Evolving concepts and technologies in mitral valve repair. *Circulation.* 2008;117:963–974.
46. Kuwahara E, Otsuji Y, Iguro Y, Ueno T, Zhu F, Mizukami N, Kubota K, Nakashiki K, Yuasa T, Yu B, Uemura T, Takasaki K, Miyata M, Hamasaki S, Kisanuki A, Levine RA, Sakata R, Tei C. Mechanism of recurrent/persistent ischemic/functional mitral regurgitation in the chronic phase after surgical annuloplasty: importance of augmented posterior leaflet tethering. *Circulation.* 2006;114(suppl):I529–I534.
47. Green GR, Dagum P, Glasson JR, Nistal JF, Daughters GT 2nd, Ingels NB Jr, Miller DC. Restricted posterior leaflet motion after mitral ring annuloplasty. *Ann Thorac Surg.* 1999;68:2100–2106.
48. Hung J, Chaput M, Guerrero JL, Handschumacher MD, Papakostas L, Sullivan S, Solis J, Levine RA. Persistent reduction of ischemic mitral regurgitation by papillary muscle repositioning: structural stabilization of the papillary muscle-ventricular wall complex. *Circulation.* 2007;116(suppl):I259–I263.
49. Watanabe N, Ogasawara Y, Yamaura Y, Wada N, Kawamoto T, Toyota E, Akasaka T, Yoshida K. Mitral annulus flattens in ischemic mitral regurgitation: geometric differences between inferior and anterior myocardial infarction: a real-time 3-dimensional echocardiographic study. *Circulation.* 2005;112(suppl):I458–I462.
50. Lang RM, Adams DH. 3D echocardiographic quantification in functional mitral regurgitation. *JACC Cardiovasc Imaging.* 2012;5:346–347.
51. Feldman T, Foster E, Glower DD, Glower DG, Kar S, Rinaldi MJ, Fail PS, Smalling RW, Siegel R, Rose GA, Engeron E, Loghin C, Trento A, Skipper ER, Fudge T, Letsou GV, Massaro JM, Mauri L; EVEREST II Investigators. Percutaneous repair or surgery for mitral regurgitation. *N Engl J Med.* 2011;364:1395–1406.
52. Lang RM, Badano LP, Tsang W, Adams DH, Agricola E, Buck T, Falettra FF, Franke A, Hung J, de Isla LP, Kamp O, Kasprzak JD, Lancellotti P, Marwick TH, McCulloch ML, Monaghan MJ, Nihoyannopoulos P, Pandian NG, Pellikka PA, Pepi M, Roberson DA, Sherman SK, Shirali GS, Sugeng L, Ten Cate FJ, Vannan MA, Zamorano JL, Zoghbi WA; American Society of Echocardiography; European Association of Echocardiography. EAE/ASE recommendations for image acquisition and display using three-dimensional echocardiography. *J Am Soc Echocardiogr.* 2012;25:3–46.
53. Mihaileanu S, Marino JP, Chauvaud S, Perier P, Forman J, Vissoat J, Julien J, Dreyfus G, Abastado P, Carpentier A. Left ventricular outflow obstruction after mitral valve repair (Carpentier's technique): proposed mechanisms of disease. *Circulation.* 1988;78(pt 2):I178–I184.
54. Jebara VA, Mihaileanu S, Acar C, Brizard C, Grare P, Latremouille C, Chauvaud S, Fabiani JN, Deloche A, Carpentier A. Left ventricular outflow tract obstruction after mitral valve repair: results of the sliding leaflet technique. *Circulation.* 1993;88(pt 2):II30–II34.
55. Lee KS, Stewart WJ, Lever HM, Underwood PL, Cosgrove DM. Mechanism of outflow tract obstruction causing failed mitral valve repair: anterior displacement of leaflet coaptation. *Circulation.* 1993;88(pt 2):II24–II29.
56. Kim DH, Handschumacher MD, Levine RA, Choi YS, Kim YJ, Yun SC, Song JM, Kang DH, Song JK. In vivo measurement of mitral leaflet surface area and subvalvular geometry in patients with asymmetrical septal hypertrophy: insights into the mechanism of outflow tract obstruction. *Circulation.* 2010;122:1298–1307.
57. Jungwirth B, Adams DB, Mathew JP, Swaminathan M, Glower DD, Mackensen GB. Mitral valve prolapse and systolic anterior motion illustrated by real time three-dimensional transesophageal echocardiography. *Anesth Analg.* 2008;107:1822–1824.
58. Hwang HJ, Choi EY, Kwan J, Kim SA, Shim CY, Ha JW, Rim SJ, Chung N, Kim SS. Dynamic change of mitral apparatus as potential cause of left ventricular outflow tract obstruction in hypertrophic cardiomyopathy. *Eur J Echocardiogr.* 2011;12:19–25.
59. Tsang W, Weinert L, Kronzon I, Lang RM. Three-dimensional echocardiography in the assessment of prosthetic valves. *Rev Esp Cardiol.* 2011;64:1–7.
60. Kronzon I, Sugeng L, Perk G, Hirsh D, Weinert L, Garcia Fernandez MA, Lang RM. Real-time 3-dimensional transesophageal echocardiography in the evaluation of post-operative mitral annuloplasty ring and prosthetic valve dehiscence. *J Am Coll Cardiol.* 2009;53:1543–1547.

Response to Tsang and Lang

Patrick M. McCarthy, MD

Drs Tsang and Lang provide an outstanding review of the benefits of 3-dimensional (3D) echocardiography. The questions to address however are: is it essential; and intraoperatively does this impact the surgical procedure? Before surgery, clinicians should already understand the mitral regurgitation mechanism(s), the lesions, and the severity because they affect decisions on the timing of surgery, choice of surgeon, and surgical approach. Intraoperatively, however, 3-dimensional echocardiography is not as valuable as the experience of the surgeon. An analogy would be the suggestion that perfect high-definition 3-dimensional photography makes plastic surgery simple and reproducible. We have seen results in Hollywood stars demonstrating that is not true. We have seen patients after mitral valve repair, even with the use of intraoperative 3-dimensional echocardiography, with a less-than-ideal outcome.

I am a fan of 3-dimensional echocardiography, and I use it routinely during mitral valve surgery. I am a proponent of surgeons evolving away from mitral valve repair as an artistic, plastic surgery-type procedure to create more predictable results provided by more cardiac surgeons. However, Drs Tsang and Lang point out that there are “still immeasurable variables” affecting the success of repair. Some may be subtle and not detected by 3-dimensional echocardiography such as prominent clefts between the scallops, small areas of prolapse, and the quality and height of valve tissue that affect surgical decision making in terms of adjusting leaflet height, selecting the size of the ring, and choosing a technique. Therefore, ultimately, I agree with Drs Tsang and Lang that ideal repairs require not only accurate imaging but also an experienced surgeon.