OXFORD

Revalidation FOR ANAESTHETISTS
RCA Revalidation matrix
Matrix reference 1A03, 2A12, 2C01, 3C00

BJA Education, 16 (2): 39–45 (2016)

doi: 10.1093/bjaceaccp/mkv012
Advance Access Publication Date: 18 June 2015

Practical approach to lung ultrasound

A Miller MBChB FRCA FFICM*

Consultant Intensivist, Anaesthetic Department, Royal Wolverhampton Hospitals, New Cross Hospital, Wolverhampton WV10 0QP, UK

*To whom correspondence should be addressed. Tel: +44 1902 307999. E-mail: ashleymiller@nhs.net

Key points

- Lung ultrasound (LU) relies on direct visualization of structures and artifact interpretation.
- A curvilinear probe is the best 'all-rounder'.
- LU has a very high diagnostic accuracy.
- A comprehensive point-of-care scan can be done in <5 min.
- A training structure and competencies specific to critical care in the UK have been developed.

Critically ill patients need rapid access to accurate and reproducible imaging techniques to diagnose pathology, implement, and monitor treatment. Point-of-care ultrasound (US) has become firmly established in acute and critical care settings (FAST, vascular access, echocardiography) and is now emerging as an important tool in the assessment of the lungs.

Lung ultrasound (LU) can be performed quickly and easily in critically ill patients. It has a higher diagnostic accuracy than physical examination and chest radiography combined.[1] It enhances safety by avoiding ionizing radiation and the need for potentially dangerous transfers within the hospital. LU can also be used to guide fluid management, weaning, and therapeutic procedures such as thoracocentesis.

LU is relatively quick to learn with a steep learning curve. By attaining competencies with appropriate training, the Intensivist can effectively utilize LU as a point-of-care investigation.

This article will take the reader through the physics and physiology of LU, outline how to perform a scan, describe the US appearances of normal and pathological lung conditions, and put these in the context of the intensive care setting.

Physics: air, water, and echoes

The appearances of LU are based on the relative amounts of air and fluid in the lung because of the phenomenon of acoustic impedance (Z). This is a measure of the resistance of particles in a medium to mechanical vibrations. Resistance increases in proportion to the density of the medium and the propagation velocity of US in the medium. When US hits a relatively large and flat boundary between mediums with different impedances, some of the sound is transmitted across the boundary and some is reflected (an echo). The greater the difference in Z, the greater the reflection. Fluid has a constant Z resulting in no echoes and so appears black. Soft tissues have very similar values of Z resulting in minimal reflection. Interfaces between bone and soft tissue reflect about 40% of US energy. Soft tissue and air reflect 99.9% rendering this interface virtually impenetrable to US.

This means structures below the pleura in an air filled lung cannot be visualized—only artifacts will be seen. LU relies on the interpretation of artifacts in conditions where the lung is predominantly aerated. These artifacts will vary depending on the ratio of air and fluid. If the lung is highly fluid filled, then it can be directly visualized. Pneumothorax consists of only air below the parietal pleura while a pleural effusion is only fluid. There is a range between these two extremes of normal lung (98% air), interstitial syndrome (IS; 95% air), alveolar syndrome (10% air), and atelectasis (5% air), all with different US appearances ranging from specific artifacts to true structure visualization.[1] It is important to remember that because of gravity fluid is usually dependent and air non-dependent.

Probe selection

US machines available in critical care settings are likely to have either a linear (vascular access probe), curvilinear (abdominal probe) or phased array (echo probe), or a combination. A great advantage of LU is that useful images can be obtained with each of these. Each probe has pros and cons.

© The Author 2015. Published by Oxford University Press on behalf of the British Journal of Anaesthesia. All rights reserved.
For Permissions, please email: journals.permissions@oup.com

Linear probe (8–12 MHz)

These high-frequency probes give good resolution of superficial structures. As the anterior pleura is relatively superficial, excellent images of the pleura and lung sliding can be obtained. The poor penetration of high-frequency US and the narrow sector width mean deeper structures are poorly imaged.

Curvilinear probe (3–5 MHz)

This is the best all-round probe for LU. Lung sliding can be easily visualized as can IS. Effusions, consolidated lung, and the diaphragm are also well imaged because of the good penetration and large sector width. The large footprint of the probe means some angulation is needed to avoid the ribs when scanning postero-laterally.

Phased array (3–4.5 MHz)

These probes have a useful footprint for getting in between the ribs. They can be used to demonstrate all the signs of LU but the clarity of the images is not as good.

General points

The clearest images are obtained by having the image as shallow as possible with the focus point at the level of interest. The frequency can be adjusted to enhance the image, depending on the depth. Increasing the frequency on a curvilinear probe will improve the appearance of lung sliding whilst worsening the appearance of a consolidated lung base.

How to perform a scan

US convention is that the left side of the image (as you look at it) should correspond with either the right side of the patient (if transverse) or cephalad (if longitudinal). A comprehensive examination can be performed on supine patients. There are several systems that have been described in the literature to examine the thorax. One is a 3-point examination of each lung.[1] This is quick and simple and there is convincing evidence that this technique yields a high diagnostic accuracy. It is therefore an excellent starting point for a novice.

Method

Apply two hands side by side (without your thumbs) over the anterior chest with your wrists in the anterior axillary line and your upper little finger resting along the clavicle. Your lower little finger will be aligned with the lower border of the lung (the phrenic line) (Fig. 1). For each point the probe should be placed at 90° to the skin, looking into the lung, with the left of the screen cephalad and the right caudad. All views are longitudinal and not transverse.

Upper anterior point

This corresponds to the base of the middle and ring fingers on the upper hand. It lies over the upper lobe.

Lower anterior point

This is the middle of the palm on the lower hand (close to the nipple in a man). It lies over the middle or lingular lobe. These points will miss the heart on the left.

Postero-lateral point

From the lower anterior point move laterally and posteriorly as far as possible behind the posterior axillary line (limited by the bed). It lies over the lower lobe. With a curvilinear probe rib shadows can then be minimized by rotating the probe slightly to lie between the ribs (cephalad will still be on the left of the image).

More comprehensive scanning techniques have also been described and are recommended for advanced practitioners.

Normal appearance

All signs in LU arise from the pleural line except for subcutaneous emphysema which will abolish it (as there is air above it). Rib shadows will be seen (as the sound is reflected back to the probe) and in between them the bright white pleural line about 0.5 cm below the rib line. Centre this in your image and you will see the 'bat sign' with the ribs as the wings (Fig. 2 online video).

Air below the pleural line reflects most US back to the transducer. This is itself a reflector, meaning some of the US waves will bounce back and forth between the pleura and transducer generating artifacts called *A lines*. They are horizontal lines below the pleura with the same spacing as the distance between

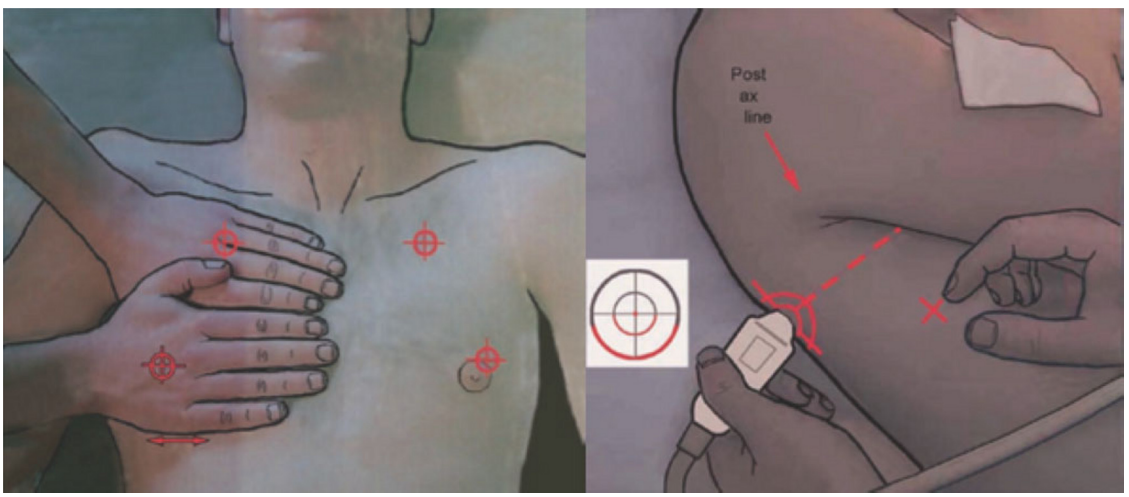

Fig 1 Probe positioning (reproduced from Whole Body Ultrasonography in the Critically Ill by D. Lichtenstein with kind permission from Springer.)

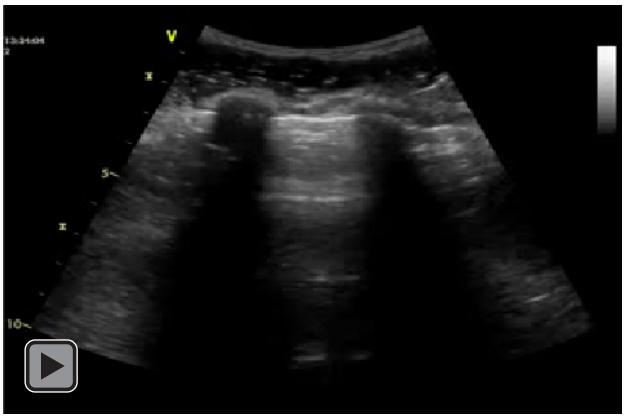

Fig 2 Online video The 'bat sign'. If reading the pdf online, click on the image to view the video.

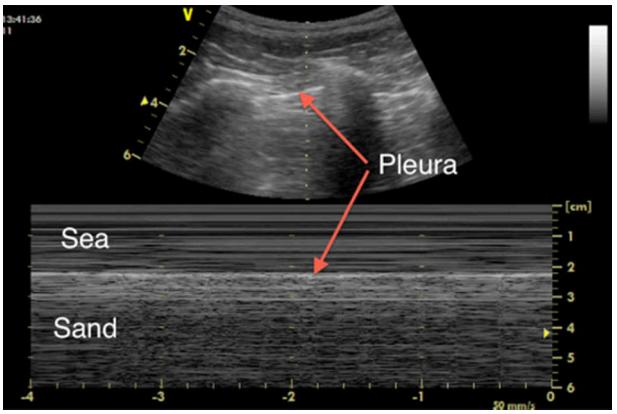

Fig 3 M-mode image of lung sliding (the 'seashore sign').

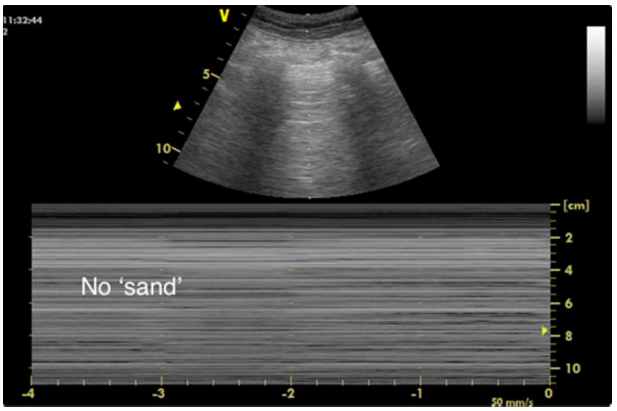

Fig 4 M-mode image of absent sliding (the 'stratosphere sign').

the probe and the pleural line. Because they demonstrate the presence of air below the pleura, they are present both in normal lungs and in pneumothorax. Turning the probe transversely will abolish the rib shadows so more of the pleural line can be seen. The danger of this is that an inexperienced user may interpret a rib as the pleural line and incorrectly diagnose absent lung sliding.

Lung sliding

The visceral and parietal pleura are normally closely opposed with a minute amount of fluid between them and slide over one another with respiration. The appearance of this is backwards and forwards movement of the pleura (often with little blebs appearing to move up and down the pleural line). Small artifacts (white or black lines) projecting a few millimetres below the pleural line move with sliding. These are more commonly seen with high-frequency probes and have no clinical significance. They are not B lines (see later). Any B lines present will move to and fro with lung sliding. The whole of the sub-pleural space between the ribs will shimmer (Fig. 2 online video).

An M-mode image (using a single scan line to demonstrate echoes plotted against time) with lung sliding present will show the 'seashore sign'. Subcutaneous tissue above the pleural line generates horizontal straight lines while there will be a sandy appearance below the pleural line created by the movement of lung sliding (Fig. 3).

Lung sliding will be reduced with low tidal volumes or in hyper-inflated lungs. It will be absent in any condition in which the pleura are either not directly opposed (pneumothorax, effusion), are stuck together (pneumonia, ARDS, pleurodesis), or in absent respiration (pneumonectomy, one lung intubation). The appearance of this on M-mode is horizontal straight lines—the 'stratosphere sign' (also termed barcode sign) (Fig. 4). It should not be necessary to use M-mode to demonstrate the presence or absence of sliding—2D is sufficient.

Interstitial syndrome

IS is a sonographic entity caused by

- Pulmonary oedema—either haemodynamic (fluid overload, cardiac failure) or permeability-induced (ALI/ARDS).
- Interstitial pneumonia or pneumonitis.
- Lung fibrosis.

Clinical examination and supine radiography have poor sensitivity for detecting interstitial oedema. The sensitivity and specificity of US approaches 100% when compared with CT. The US feature of IS is *B lines* (Fig. 5). These are artifacts generated by the juxtaposition of alveolar air and septal thickening (from fluid or fibrosis). Their characteristics are

- They arise from the pleural line.
- They are long, vertical hyperechoic lines which continue to the depths of the image.
- They look like comet tails (an old name for them).
- They erase A lines.
- They move with lung sliding.

Occasional B lines can be seen in normal lungs (especially at the bases). Up to two between two adjacent ribs can be considered normal. Three or more between rib spaces (or close together in a transverse image) are pathological. They can be localized, disseminated, homogenous, or non-homogenous depending on the pathology. They are present in any disease affecting the interstitium. The commonest cause is pulmonary oedema where they are the equivalent of Kerley B lines. When oedema becomes more severe (ground-glass appearance on CT) B lines become more numerous and closely spaced. Very severe oedema causes them to fuse with a hyperechoic confluent pattern that fills the space between two ribs (white lung). LU can distinguish between causes of IS.[2] A detailed explanation is beyond the scope of this article as it is not a core-level competence; however, Table 1 outlines the main features distinguishing cardiogenic from non-cardiogenic pulmonary oedema.

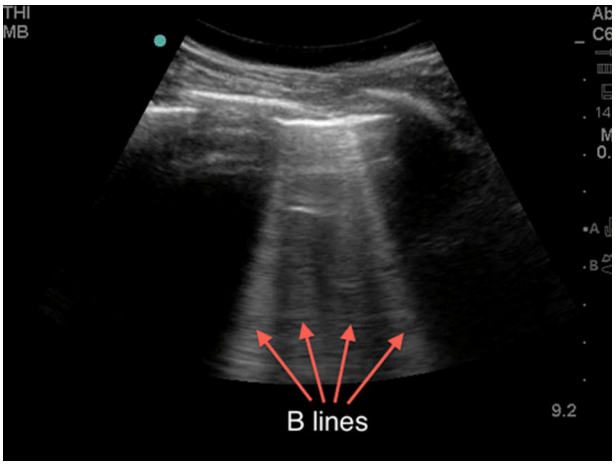

Fig 5 B lines demonstrating IS.

Table 1 Interstitial syndrome

Ultrasound features	Cardiogenic	ALI/ARDS
Lung sliding	Normal	Reduced or absent
Pleural line	Normal	Irregular, thickened, coarse. Often multiple small anterior subpleural consolidations
Distribution	Homogenous. Spread from postero-lateral to anterior with increasing severity. No spared areas.	Spared areas (normal pleura, no B lines). More severe in dependent areas
Consolidation	No consolidation	Dependent consolidation
Lung pulse	Absent	Present in areas of reduced sliding
Pleural Effusion	Common	Less common

Differentiating between cardiogenic and non-cardiogenic pulmonary oedema.

Pneumothorax

LU is nearly as good as CT for ruling a pneumothorax in or out. It takes less than a minute with US (Fig. 6).

The features of a pneumothorax are abolished sliding, absence of B lines, absence of the lung pulse, and presence of the lung point.[3] Air, being non-dependent, will collect anteriorly in a supine patient. Placing the probe on the highest point of the anterior chest and demonstrating lung sliding will rule out a pneumothorax in only a few seconds. The presence of any B lines means that the pleural layers are opposed at that point ruling out pneumothorax even if there is no sliding.

If there is no sliding and no B lines, then the 'lung point' should be sought. This is the point at which the two pleural layers rejoin one another. It will be more lateral with increasing pneumothorax size and so should be looked for by moving the probe laterally. This point will move with lung inflation and deflation resulting in an area at which sliding will appear and disappear (Supplementary data, Video).

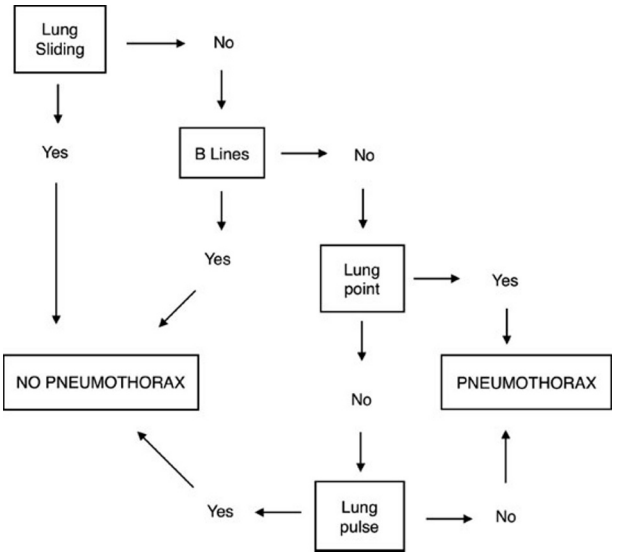

Fig 6 Flowchart to assess for a pneumothorax (adapted from a diagram with kind permission from Intensive Care Medicine.)

If the lung point cannot be found (it usually can) then the 'lung pulse' should be sought. If the pleural layers are still adjacent to one another, then cardiac pulsation will be transmitted to the pleura by the lung. This results in a very small amount of motion in 2D in time with the heartbeat. It is easier to see in M-mode where it produces *T lines*. These are vertical lines running from the pleural line to the bottom of the image in time with cardiac pulsation (Supplementary data, Fig. S1).

Alveolar syndrome

The sonographic entity of alveolar syndrome encompasses alveolar consolidation and atelectasis.

Consolidation

Consolidations are highly fluid filled, and over 95% reach the pleura,[4] so US can image the pathology directly. Three US patterns are typical with consolidation.

Anterior consolidations

These are (usually small) echo poor areas beneath the pleura. Peri-lesional B lines and comets deep to the far margins are common. The margins of pneumonic consolidation are indistinct (Fig. 7).

Tissue-like sign

When the lung is highly fluid filled, it resembles the liver in echogenicity—it becomes hepatisized. Extensive consolidation will allow the opposite pleural line to be seen (8–11 cm deep) with mediastinum deeper still with the aorta or IVC visible (Fig. 8). Severe consolidation will often be accompanied by a pleural effusion.

Shred sign

If consolidations are less extensive, and the percentage of air therefore greater, it looks as if chunks have been taken out of the lung (echo poor areas). These areas will be bordered by aerated lung identified by sliding and comets. The border of

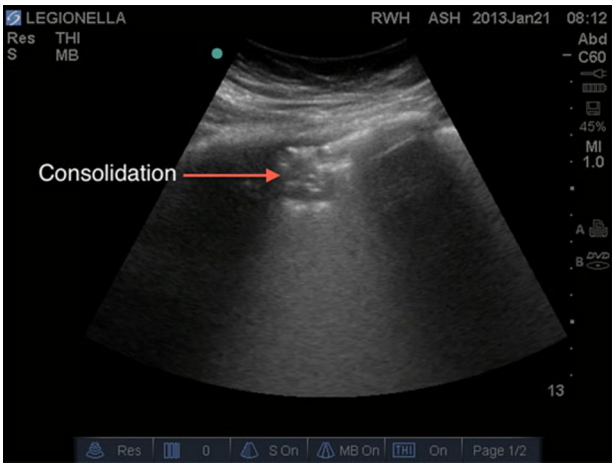

Fig 7 A small anterior consolidation with indistinct margins.

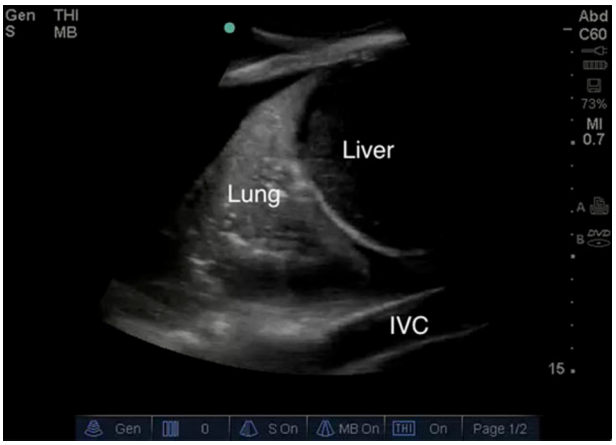

Fig 8 A fully consolidated lung base surrounded by an effusion.

consolidated and aerated lung is not sharp. This sign is highly suggestive of pneumonia (Supplementary data, Fig. S2).

Air and fluid bronchograms

Air bronchograms appear white while fluid bronchograms are black. They are punctiform if transverse to the beam and linear if longitudinal (Fig. 9 online video). Fluid bronchograms are specific to pneumonia. They can be distinguished from vessels with colour Doppler and by the angulation of their branches. An air bronchogram which moves with respiration excludes bronchial obstruction and helps distinguish between consolidation and atelectasis. Dynamic air bronchograms make pneumonia more likely; static or no air bronchograms make atelectasis more likely (Fig. 9 online video).

Atelectasis

Atelectasis and consolidation are difficult to tell apart with US. Bronchograms are suggestive as above but have a low specificity. If there is a very large pleural effusion, then compression atelectasis is more likely. A small effusion makes consolidation much more likely. If there is significant collapse, then associated signs such as a raised hemidiaphragm will be present. Virtually all pleural effusions in critical ill patients have underlying consolidated/atelectatic lung underneath. The only sure way to distinguish compression atelectasis from consolidation is to drain the effusion and see if the lung re-aerates.

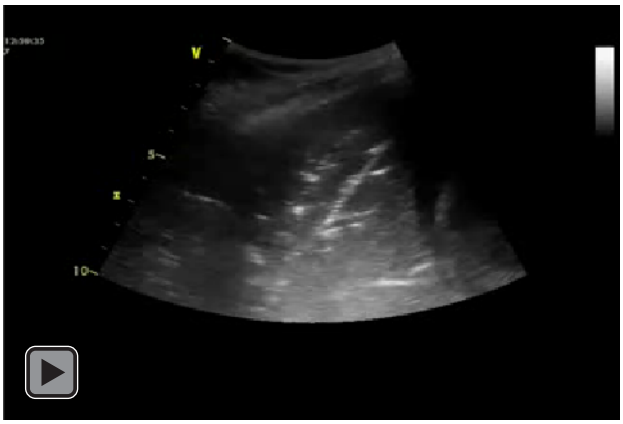

Fig 9 Online video Linear air bronchograms (white and branching) within a consolidated lung base. If reading the pdf online, click on the image to view the video.

Diaphragm

The diaphragm is easily visualized if there is basal consolidation or an effusion (Supplementary data, Fig. S3). It is mostly obscured by aerated lung (unless looked at from below through the liver), but its position will be identified by air above (on the left of the screen) and abdominal organs below (on the right). The diaphragm is raised if above the normal phrenic line. The normal inspiratory amplitude longitudinally is between 15 and 20 mm. Low amplitude reflects atelectasis, low tidal volume, raised intra-abdominal pressure, and muscle weakness. Paradoxical movement indicates phrenic nerve palsy.

Pleural effusion

Up to 500 ml of fluid is easily missed with chest radiography. The sensitivity and specificity of US approach 100%. US will reveal septations and can help distinguish between transudates and exudates. Effusions are dependent because of gravity so collect caudad and posteriorly in ICU patients. They are easily identified between the diaphragm and lung postero-laterally. The lung will float on top of an effusion.

The quad sign—with the diaphragm out of view an effusion will be seen as a rectangular shape (usually anechoic) whose borders are the ribs cephalad and caudad and the parietal and visceral pleura at the top and bottom. It is imperative not to confuse an A line for the visceral pleura. The lung moves towards and away from the probe with respiration which can be visualized in 2D or M-mode (the sinusoid sign) (Supplementary data, Fig. S4). This is important for distinguishing pleural thickening from an effusion as is colour Doppler which will identify fluid movement within an effusion. With the diaphragm in view a significant effusion will be seen surrounding the basal lung and separating it from the diaphragm. Atelectatic or consolidated lung base is usually seen floating around.

Size

There are a number of published sizing techniques for effusions which vary significantly as an accurate volume is difficult to define with US. It is more practical and clinically relevant to classify an effusion volume as small, moderate, or large. As a rule of thumb, an effusion depth of >4–5 cm at the widest point will mean an effusion of >1000 ml.

Transudates and exudates

Transudates and exudates are defined biochemically, but the nature of effusions can be suggested by LU.[5] An anechoic effusion may be a transudate, exudate, or acute haemothorax. Echoic effusions (uniform or particles) signify an exudate or subacute haemothorax. A septated effusion is a result of inflammation so is an exudate (Supplementary data, Video).

Thoracocentesis

Thoracocentesis can be done in real time (in or out of plane) or the site can be marked. If marked, then the patient should not be moved before the procedure. If done in real time, then the curvilinear probe makes needle visualization easiest (with minimum depth and highest frequency settings) as the needle will be at 90° to the probe. The site selected should be where the effusion is largest and as far removed as possible from other structures (lung, diaphragm, etc.). It is advisable to remain anterior to the posterior axillary line to avoid the intercostal vessels. There should be a reasonable distance between the pleura in inspiration to avoid pneumothorax (minimum 1 cm depending on skill). It is essential that the needle is inserted at the same angle as the US beam. Tapping can be done with a green needle. Evacuation can be achieved with a 14G cannula or a small Seldinger drain.

Pulmonary emboli

A normal LU is a very sensitive but not specific sign of PE. Small, peripheral infarcts can sometimes be seen which are wedge shaped with defined margins. The main strength of LU in PE is to rule out other causes of respiratory failure—it should not be used in place of normal imaging techniques if PE is suspected. Identification of peripheral emboli is not a core competence.

COPD/asthma

As these conditions affect the airways, LU will be normal (if no pneumonia is present). LU is particularly useful in distinguishing between pulmonary oedema, pneumonia, and a COPD exacerbation in patients in whom the diagnosis is not clear.

Acute respiratory failure (the BLUE protocol)

For patients presenting acutely with respiratory failure, LU provides a diagnostic accuracy of 90.5% (compared with about 75% for physical examination plus chest radiography) with a scan that takes <5 min.[1] The scan requires the operator to seek lung sliding anteriorly and look for B lines at two anterior points on each hemithorax. If a diagnosis is not reached, then the operator scans the leg veins for a deep venous thrombosis (DVT). If there is no DVT, then consolidation is looked for postero-laterally. This simple protocol has the ability to greatly enhance the speed and accuracy of diagnosis in patients with acute respiratory failure (Supplementary data).

Intensive care setting

Diagnosis and treatment

The BLUE protocol was designed for spontaneously breathing patients with acute respiratory failure. Other studies confirm the very high diagnostic accuracy of LU in ventilated intensive care patients.[6,7] Expert practitioners can distinguish between cardiogenic and non-cardiogenic pulmonary oedema and other interstitial diseases. The high diagnostic accuracy allows appropriate treatment to be instituted (diuretics, antibiotics, thoracocentesis, etc.).

Fluid management

The absence of B lines can reassure that fluid will not be detrimental to gas exchange. Their presence should, in most circumstances, dissuade you from giving further fluid. B lines appear with interstitial oedema (before alveolar oedema). It has been proposed that the appearance of B lines be the stopping point when giving a fluid challenge with B lines corresponding to the flat portion of the Starling curve.[8] B lines will disappear with treatment of pulmonary oedema.

Lung aeration, PEEP, and weaning

Lung re-aeration can be assessed after pleural drainage. LU has been used to assess lung recruitment with PEEP (it is important to note that hyperinflation cannot be assessed).[9] Loss of aeration assessed by LU during a spontaneous breathing trial (SBT) predicts post extubation distress.[10] Crucially this applies to patients who pass the SBT.

Training

Publications by the Royal College of Radiologists and a joint document by the Association of Anaesthetists of Great Britain and Ireland, Intensive Care Society and Royal Collage of Anaesthetists provide guidance for training non-radiologists in US. The Intensive Care Society has recently launched an accreditation pathway, Core Ultrasound in intensive Care (CUSIC) which includes all the key aspects of LU outlined in this article. Information can be found at www.ics.ac.uk. It is anticipated that lung US will be incorporated into the ICM syllabus in the future.

Supplementary material

Supplementary material is available at *BJA Education* online.

Online videos

The videos associated with this article can all be viewed from the article in *BJA Education* online.

MCQs

The associated MCQs (to support CME/CPD activity) can be accessed at https://access.oxfordjournals.org by subscribers to *BJA Education*.

References

1. Lichtenstein DA, Meziere GA. Relevance of lung ultrasound in the diagnosis of acute respiratory failure: the BLUE protocol. *Chest* 2008; **134**: 117–25
2. Copetti R, Soldati G, Copetti P. Chest sonography: a useful tool to differentiate acute cardiogenic pulmonary edema from acute respiratory distress syndrome. *Cardiovasc Ultrasound* 2008; **6**: 16
3. Volpicelli G. Sonographic diagnosis of pneumothorax. *Intensive Care Med* 2011; **37**: 224–32
4. Lichtenstein DA, Lascols N, Meziere G, Gepner A. Ultrasound diagnosis of alveolar consolidation in the critically ill. *Intensive Care Med* 2004; **30**: 276–81

5. Yang PC, Luh KT, Chang DB, Wu HD, Yu CJ, Kuo SH. Value of sonography in determining the nature of pleural effusion: analysis of 320 cases. *AJR Am J Roentgenol* 1992; **159**: 29–33
6. Lichtenstein D, Goldstein I, Mourgeon E, Cluzel P, Grenier P, Rouby JJ. Comparative diagnostic performances of auscultation, chest radiography, and lung ultrasonography in acute respiratory distress syndrome. *Anesthesiology* 2004; **100**: 9–15
7. Xirouchaki N, Magkanas E, Vaporidi K *et al*. Lung ultrasound in critically ill patients: comparison with bedside chest radiography. *Intensive Care Med* 2011; **37**: 1488–93
8. Lichtenstein D. Fluid administration limited by lung sonography: the place of lung ultrasound in assessment of acute circulatory failure (the FALLS-protocol). *Expert Rev Respir Med* 2012; **6**: 155–62
9. Bouhemad B, Brisson H, Le-Guen M, Arbelot C, Lu Q, Rouby JJ. Bedside ultrasound assessment of positive end-expiratory pressure-induced lung recruitment. *Am J Respir Crit Care Med* 2011; **183**: 341–7
10. Soummer A, Perbet S, Brisson H *et al*. Ultrasound assessment of lung aeration loss during a successful weaning trial predicts postextubation distress. *Crit Care Med* 2012; **40**: 2064–72