

Anesthesia for Interventional Cardiology

Mark Hayman, FANZCA, MBBS, MPH, BSc(Med)(Hons), Paul Forrest, FANZCA, MBChB, and Peter Kam, MBBS, MD, FANZCA, FRCA, FCARCSI, FHKCA(Hon)

THE DEMAND FOR anesthetic support for interventional cardiology procedures is increasing as the number and complexity of these procedures rapidly expand. Providing safe anesthesia care to patients undergoing these procedures requires comprehensive preoperative assessment, involvement in the multidisciplinary planning of these cases, and a detailed understanding of the procedures and their potential complications. This article reviews the common implantation and electrophysiology (EP) procedures undertaken in cardiac catheterization laboratories. An outline of the procedures undertaken and their major periprocedural complications are addressed along with recommendations for their anesthetic management. The first section covers closure of intracardiac shunts, closure of patent ductus arteriosus (PDA), left atrial appendage (LAA) occlusion devices, transcatheter valves, and the implantation and removal of pacemaker and rhythm management devices. The second section covers EP procedures and anesthetic management issues in patients with congenital heart disease (CHD). It also covers the anesthetic implications of ionizing radiation and practice in a remote location.

CARDIAC CATHETERIZATION LABORATORY PROCEDURES

Endovascular devices are available for the closure of patent foramen ovale (PFO), atrial septal defects (ASDs), ventricular septal defects (VSDs), PDAs, and for occlusion of the LAA.

Intracardiac Shunt Closures

PFO Closure

PFOs are present in approximately 25% of the adult population.¹ The most common indication for PFO closure is the prevention of paradoxical embolic or “cryptogenic” stroke. From observational studies, the incidence of cryptogenic stroke is increased in patients with either PFO or atrial septal aneurysm

and further increased when both are present.² However, the evidence that PFO closure decreases the risk of stroke remains inconclusive. A prospective, nonrandomized study from Switzerland of 308 patients with cryptogenic stroke showed a lower risk of recurrent stroke or transient ischemic attack in patients who underwent percutaneous PFO closure compared with medical therapy alone (7.3% v 33.2%, $p = 0.01$).³ However, population-based studies suggest that the presence of a PFO does not increase the risk of stroke.⁴ Two ongoing randomized studies comparing PFO closure with medical treatment should help define the indications for PFO closure in the near future (available at <http://www.clinicaltrials.gov>, NCT00201461 and NCT00562289).

PFO closure also has been performed for the treatment of migraines. Although several nonrandomized trials have identified an association between PFO closure and migraine resolution,⁵ a recent prospective trial found no difference in migraine rates at 6 months.⁶ Further prospective studies of PFO closure for this indication are in progress.

ASD Closure

ASDs are present in about 1 in 1,500 children at birth⁷ and account for 30% to 40% of CHD in adults. ASD closure usually is performed for the prevention of stroke or right ventricular volume overload and pulmonary hypertension. Current American Heart Association guidelines recommend closure of ASDs for right atrial or right ventricular enlargement (with or without symptoms), paradoxical embolism, documented orthodeoxia-platypnea (a rare condition in which dyspnea and deoxygenation are induced by standing), and pulmonary hypertension.⁸ ASD closure results in symptomatic improvement and reductions in right ventricular size and pulmonary arterial pressures at any age, but outcomes are better in patients who have normal pulmonary arterial pressures and no functional impairment before closure.⁹ A multicenter nonrandomized trial showed similar efficacy rates for percutaneous secundum ASD closure and surgery in children and adults (98.5% v 100%, $p = 0.331$).¹⁰ The closure device was associated with fewer total complications than surgery (7.2% v 24%, $p < 0.001$). Major complications occurred in 1.6% of the device cases, including arrhythmias and device embolism requiring surgical removal. In contrast, 5.4% of patients treated surgically experienced major complications such as pericardial effusion with tamponade, wound complications, and repeat surgery. The most common minor complication in the device group was arrhythmias and in the surgical group pericardial effusion without tamponade. The authors of this study emphasize that although efficacy may be similar between surgery and device closure, patient selection is important because anatomic features, such as lim-

From the Department of Anaesthesia, Royal Prince Alfred Hospital, Sydney, Australia.

Address reprint requests to Mark Hayman, FANZCA, MBBS, MPH, BSc(Med)(Hons), Department of Anaesthesia and Pain Management, Royal Prince Alfred Hospital, Missenden Road, Camperdown, New South Wales, 2050, Australia. E-mail: mwhayman@gmail.com

© 2012 Elsevier Inc. All rights reserved.

1053-0770/2601-0023\$36.00/0

doi:10.1053/j.jvca.2011.09.004

Key words: anesthesia, interventional cardiology, cardiac catheterization laboratory, cardiac electrophysiology

ited ASD rims, large or irregular ASD size, and anomalous pulmonary venous drainage, limit the effectiveness of closure devices.

Transesophageal echocardiography (TEE) is a crucial part of the preprocedural assessment. A recent study suggested that 3-dimensional (3D) TEE may be more accurate for sizing the percutaneous closure device and reduce the risk of residual shunt after closure when compared with conventional 2-dimensional (2D) TEE.¹¹

PFO/ASD Closure Technique

The closure of both PFOs and ASDs involves the placement of a catheter-deployed closure device that usually is advanced from the femoral vein into the right atrium and across the septal defect (Fig 1). Procedural times generally are shorter for PFO closures than for ASD closures (30 minutes¹² v 2.5 hours,¹³ respectively). Fluoroscopy and TEE or intracardiac echocardiography (ICE) are used to guide the positioning and deployment of the device and to confirm the adequacy of closure. ICE allows these procedures to be performed without general anesthesia or sedation and reduces fluoroscopy and procedural time compared with TEE-guided PFO closure.¹⁴ In a series of 53 patients, the mean duration of ICE-guided PFO closure was 31 minutes, with a complete closure rate of 94%.¹² However, probe cost often limits their use to patients with contraindications to TEE or patients at high risk for general anesthesia.

For patients who require TEE-guided ASD or PFO closure, general anesthesia with an endotracheal tube is routine. Meticulous de-airing of all fluid lines should be undertaken to reduce the potential for right-to-left air embolization during device placement.

Heparin should be administered for these procedures to

minimize the risk of thrombus formation. The heparin doses reported for these procedures have varied between 7,500 and 10,000 IU¹⁵ and 10,000 to 20,000 IU.¹⁶ In the Closure I trial, heparin was given to maintain an activated coagulation time (ACT) >200 seconds.¹⁷ Outside of the percutaneous coronary intervention (PCI) literature, there are no published guidelines regarding heparin administration for cardiac interventional procedures.¹⁸ The authors' institutional practice is to administer heparin boluses to maintain a celite ACT >300 seconds (Hemochron; ITC Nexus Dx, Edison, NJ). Protamine reversal of heparin has been associated with a high rate of thrombus formation in patients undergoing ASD and PFO closure,¹⁶ and therefore should be avoided if possible.

Analgesic requirements should be minimal following these procedures. Sternal pain should alert the anesthesiologist to the possibility of myocardial perforation, which complicates 0.1% of ASD closures.¹⁹ Most perforations occur within 72 hours, but about a third of cases are delayed for up to 3 years. Acute or delayed aortic root perforation also can occur if the closure device abuts the aortic root; this may present as aortoatrial fistula or cardiac tamponade.²⁰

Other potential complications include acute or delayed device embolization and stroke although these are extremely rare. Atrial thrombus, predominantly left-sided and attached to the implanted device, is a more common complication that affects 2% of patients and usually resolves with oral or intravenous anticoagulation.¹⁶ Measures to prevent atrial thrombus include new closure device designs with reduced prosthetic material exposed in the left atrium (LA) and alternative PFO closure techniques, such as radiofrequency (RF) ablation.²¹

Despite the recognized risk of atrial thrombus, there are no universally accepted guidelines for antiplatelet therapy after PFO or ASD device deployment. Single antiplatelet therapy for 6 months has been reported (aspirin, 100 mg daily⁴), whereas others used dual therapy with aspirin and clopidogrel for 6 months followed by single antiplatelet therapy.¹⁷

VSD Closure

Most VSD repairs are performed in childhood. Adults who present for VSD closure usually have small congenital defects or acute defects after myocardial infarction. The latter patients may be hemodynamically unstable because of intracardiac shunting or arrhythmias. Percutaneous closure in selected cases may provide better outcomes than open surgical repair, which has a mortality rate of about 50%.²² In a series of 10 adult patients with acute VSDs up to 18 mm in size (5 postmyocardial infarction and 5 secondary to surgical trauma), percutaneous closure was successful in all patients, and 9 patients survived to 6 months.²²

In addition to these considerations in percutaneous ASD and PFO closure cases, invasive monitoring and inotropic support with the placement of external defibrillator pads is recommended in these patients. In a single-center series of 28 patients undergoing percutaneous VSD closure (17 congenital, 10 postoperative, and 1 traumatic, up to 16 mm in diameter), TEE was used in conjunction with fluoroscopic guidance in 22 cases, ICE in 5 cases, and both in 2 cases.²³ General anesthesia was used in 25 patients, and procedural times ranged from 46 to 300 minutes. Closure was successful in all patients.



Fig 1. AMPLATZER PFO Occluder (St Jude Medical, Plymouth, MN). Limited by Federal US law to investigational use. (Color version of figure is available online.)

PDA Closure

PDA closure was the first transcatheter closure procedure performed and was conducted in Germany in 1967.²⁴ Although most PDAs are identified and treated in infancy, a small group of patients may present as adults with heart failure or pulmonary hypertension. There is substantial variability in the size and shape of PDAs, and there are a variety of closure devices available. Coils can be used to occlude small PDAs, but self-expanding occluders (such as the AMPLATZER Duct Occluder [St Jude Medical, Plymouth, MN] in Fig 2) are used for larger ducts.²⁵ Successful closure of PDAs >10 mm in diameter has been reported in adults.²⁶ PDA closure was successful in 99% of patients in a series of 359 pediatric and adult cases.²⁷ In this study, the Amplatzer Duct Occluder and Gianturco coils (Cook, Inc, Bloomington, IN) were the most commonly used occlusion devices, with overall success rates of 96.9% and 89.7%, respectively. Major complications (predominantly device embolization) occurred in 0.6% of coil closures and 1.7% of Amplatzer cases.

These procedures require retrograde placement of a fine guidewire into the PDA from the femoral or upper-limb artery under fluoroscopic guidance. Sedation or general anesthesia may be required because the procedures can be of unpredictable duration and because patients must be immobile to allow accurate catheter deployment across the orifice of the PDA. In patients with secondary pulmonary hypertension and right-heart failure, general anesthesia may be preferable if supine positioning is poorly tolerated. Increases in pulmonary vascular resistance (PVR) caused by hypoxia, hypercarbia, or high ventilating pressures must be avoided because this will exacerbate right-heart failure. Systemic heparinization should be used throughout the procedure to prevent arterial thrombotic embolization. Although there are no specific guidelines for heparin dosage, 75 IU/kg has been reported.²⁵ Although fluoroscopy/angiography is the main imaging modality in PDA closure, descending aortic ICE has been used and potentially can reduce fluoroscopy time.²⁸




Fig 2. The AMPLATZER Duct Occluder. (Color version of figure is available online.)



Fig 3. The WATCHMAN Left Atrial Appendage Occlusion device. (Image courtesy Atritech © 2011.) (Color version of figure is available online.)

LAA Occlusion

The LAA is prone to in situ thrombus formation because of its long, narrow lumen and trabeculations. It is thought to be the source of most atrial thrombi in patients with nonvalvular atrial fibrillation (AF).²⁹ Atrial appendage occlusion devices, such as the WATCHMAN LAA Closure Device (Atritech, Minneapolis, MN) (Fig 3), are similar to PFO/ASD closure devices and are placed in the orifice of the LAA. In a randomized trial of 707 patients with AF, closure of the LAA was shown to be as effective in stroke prevention as warfarin therapy alone.³⁰ However, the Watchman device group was associated with a higher rate of adverse events, particularly bleeding complications. The Amplatzer device also is effective for LAA closure (96%), with a similar reported rate of serious complications to the Watchman closure device (7%, including pericardial effusions in 3.5%).³¹ The anesthetic plan for these cases in the authors' institution includes invasive monitoring and preparation for the management of pericardial tamponade and major bleeding.

Transcatheter Aortic Valve Implantation

Aortic stenosis is the most common valvular heart disease in adults,³² and replacement of the aortic valve is the only treatment that reduces mortality in these patients. Transcatheter aortic valve implantation (TAVI) involves the catheter deployment of a bioprosthetic valve in a Nitinol stent (Nitinol Devices and Components, Fremont, CA). These valves were developed as an alternative to open aortic valve replacement for high-risk patients.

The first successful TAVI was performed in 2002.³³ Currently, there are 2 valves in clinical use: the Edwards SAPIEN balloon expandable transcatheter Heart Valve (Edwards Lifesciences, Irvine, CA) (Fig 4A) and the Corevalve Percutaneous

Aortic Valve Implantation System (Medtronic, Inc, Minneapolis, MN) (Fig 4B). There are 2 approaches to deploying the valve: the retrograde approach via the femoral artery or an antegrade transapical approach via a left minithoracotomy and left ventricular puncture.³⁴ The first prospective, randomized trial comparing TAVI versus nonsurgical medical care recently has been published.³⁵ Study patients had severe aortic stenosis and a greater than 50% risk of surgical mortality or a serious irreversible condition. Compared with the medical care group,

the TAVI group had significantly lower all-cause mortality (30.7% v 50.7%, $p < 0.001$) and cardiac symptoms (New York Heart Association [NYHA] class III or IV) (25.2% v 58%, $p < 0.001$) at 1 year. However, there were more major vascular complications (16.2% v 1.1%, $p < 0.001$) and a trend toward more strokes (5% v 1%, $p = 0.06$) in the TAVI group. In the parallel Placement of Aortic Transcatheter Valves (PARTNER) study comparing TAVI with open surgical valve replacement in 699 high-risk patients, all-cause mortality at 1 year was similar in both groups (24.2% v 26.8%, $p = 0.44$).³⁶ Both groups showed an improvement in cardiac symptoms at 1 year. In the TAVI group, the incidence of stroke and transient ischemic attack (TIA) at 1 year was higher (8.3% v 4.3%, $p < 0.05$) as was the rate of major vascular complications (11.3% v 3.5%, $p < 0.001$), but the rate of major bleeding was lower than in the surgical group (14.7% v 25.7%, $p < 0.001$).

Given the positive findings, interest in the use of TAVI as an alternative to surgery or medical therapy certainly will increase. Further developments are underway in valve design, delivery systems, and implantation techniques (eg, via the subclavian artery³⁷). The long-term durability of these valves is unknown.

ANESTHETIC AND PROCEDURAL MANAGEMENT OF TAVIs

At the authors' institution, anesthetic management of TAVIs was developed with reference to descriptions provided by Fassl and Augoustides,^{38,39} Walther,³⁴ and Billings.⁴⁰ During preoperative planning, there should be agreement among the attending physicians as to whether rescue open aortic valve replacement would be performed if required. Therefore, these cases ideally should be performed in a hybrid operating room. Because major hemorrhage can occur at any time in these cases, large-bore venous access is required, and cross-matched blood should be readily available. Invasive arterial and central venous pressure monitoring are routine.

Transapical TAVIs are performed if femoral access is unsuitable; a single-lumen endotracheal tube usually is sufficient for surgical access to the left ventricular apex. Although transfemoral cases can be performed under sedation, general anesthesia usually is performed because of the risks of major vascular injury, hemodynamic instability, and stroke. In addition, general anesthesia facilitates the use of TEE throughout the procedure. TEE is useful to confirm the preoperative assessment of the native aortic valve; to guide placement of the TAVI; and to identify procedural complications, such as paravalvular leak, mitral valve damage, and pericardial tamponade.

After induction, the proceduralist first places a right ventricular pacing lead via the femoral vein. Balloon aortic valvuloplasty then is performed. This may require several attempts and is performed with rapid ventricular pacing to prevent balloon migration. It is important to maintain systemic vascular resistance and adequate coronary blood flow during this period. A mean arterial pressure >75 mmHg has been recommended before the commencement of rapid pacing.⁴¹ Rapid ventricular pacing may cause acute myocardial ischemia or ventricular fibrillation; hence, external defibrillators and preparation for immediate resuscitation are required in all patients. After aortic valvuloplasty, the TAVI is advanced into position through the aortic valve. For the Edwards TAVI device, rapid ventricular

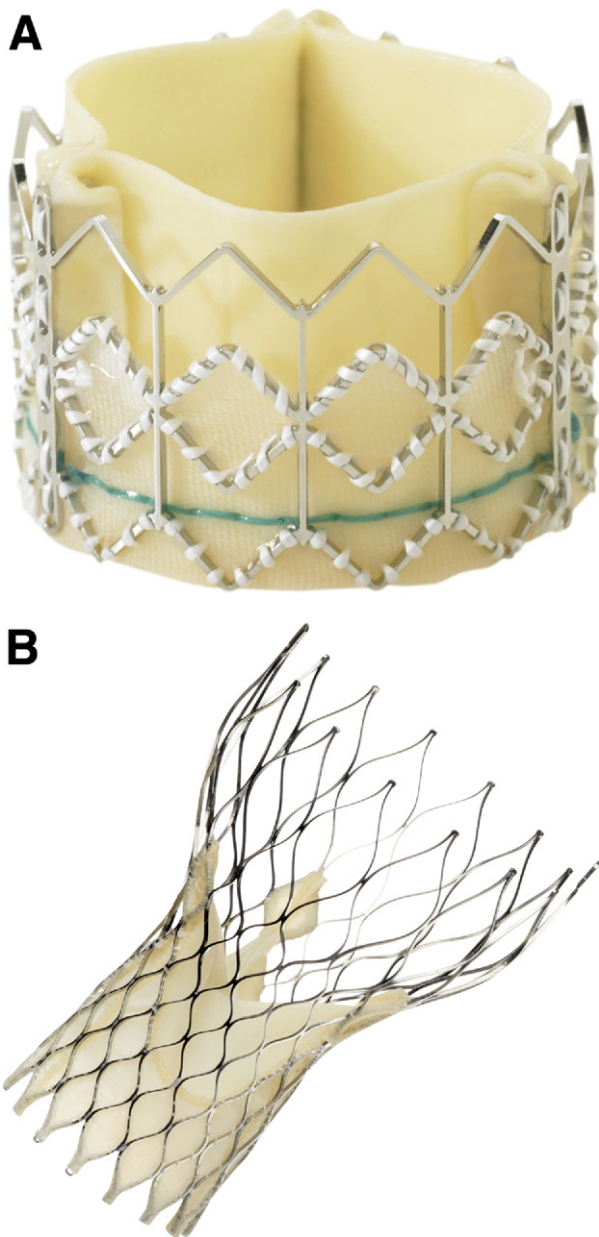


Fig 4. (A) The Edwards SAPIEN balloon expandable transcatheter heart valve (Edwards Lifesciences). Limited by Federal US law to investigational use. (B) The CoreValve Percutaneous Aortic Valve Implantation System (Medtronic, Inc). Limited by US law to investigational use. (Color version of figure is available online.)

pacing is performed as the expandable valve is deployed by balloon inflation. Rapid pacing is not required for deployment of the Corevalve device because it is self-expanding. The valve then is assessed for position, function, and paravalvular leak. Major complications that may occur at this time include myocardial ischemia caused by coronary artery occlusion, device embolization, and atrioventricular (AV) conduction defects.

Most patients can be extubated at the end of the procedure. Postoperatively, they should be monitored for delayed complications, such as bleeding or arterial dissection after the removal of the femoral arterial catheters. Delayed AV conduction defects can occur; hence, the temporary pacing wire should remain in situ at the end of the procedure.

TRANSCATHETER PULMONARY, TRICUSPID, AND MITRAL VALVE REPLACEMENTS

Transcatheter pulmonary valve replacement was first performed in 2000 for valve dysfunction in a right ventricle-to-pulmonary artery prosthetic conduit⁴² and subsequently has been performed for other indications, such as right ventricular outflow tract conduit failure⁴³⁻⁴⁵ and pulmonary atresia.⁴⁶ In patients with pulmonary valve conduit failure, the Melody Transcatheter Pulmonic Valve (Medtronic Inc) (Fig 5) effectively reduces outflow tract obstruction and restores valve function in 93% of cases.⁴⁷ This valve is now approved for this indication in the United States under the Humanitarian Device Exemption.

The main acute complication of this procedure is right ventricular outflow tract rupture. Therefore, invasive blood pressure monitoring, preparation for rapid transfusion, and conversion to open surgery is indicated in these cases. Preoperative 3D imaging of the reimplanted coronary arteries in patients with prior Ross procedures also is important because there is a theoretic risk of coronary artery compression during valve deployment.⁴⁴ Other complications include brachial plexus or upper-limb nerve injury caused by prolonged arm abduction during fluoroscopic imaging and delayed valve fracture.

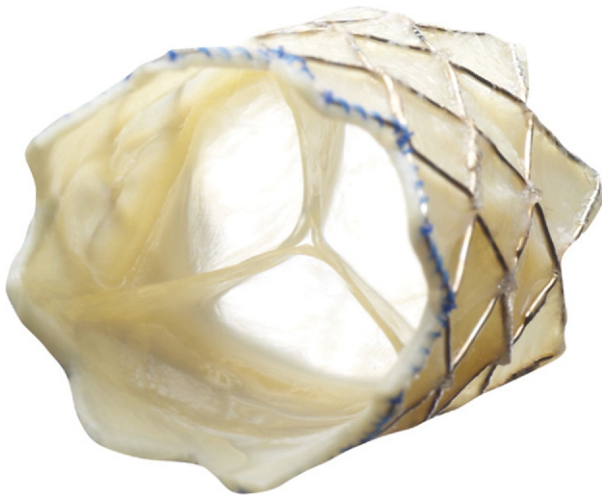


Fig 5. The Melody® transcatheter pulmonary valve. Approved for use in the United States under the Humanitarian Device Exemption. (Color version of figure is available online.)

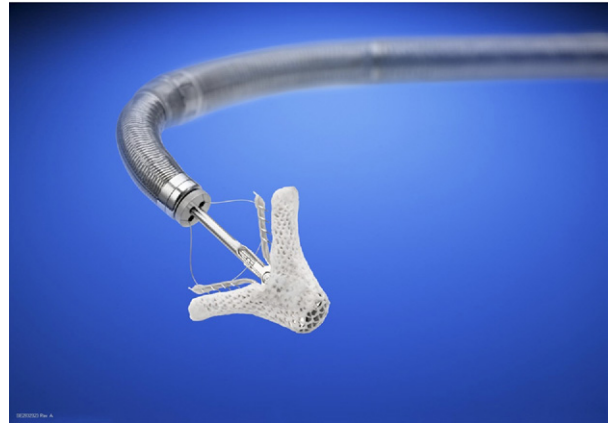

Fig 6. The Mitraclip edge-to-edge endovascular mitral valve repair device. (Color version of figure is available online.)

Transcatheter valve replacement of the tricuspid valve only has been performed in a few complex cases. In one patient who had severe prosthetic tricuspid regurgitation after 2 previous sternotomies, the valve was deployed via thoracotomy and right atrial puncture.⁴⁸ These valves also have been deployed via the inferior vena cava.⁴⁹

There are several transcatheter mitral valve repair procedures in various stages of development.⁵⁰ For mitral regurgitation (MR), a catheter-mounted clip device can tether the midportion of the free edge of the mitral leaflets, creating a double-orifice valve similar to the surgical Alfieri technique (MitraClip; Abbott Vascular, Abbott Park, IL Santa Clara, CA) (Fig 6).⁵¹ The MitraClip is deployed with transesophageal echocardiographic guidance via the femoral vein and interatrial septum. The MitraClip technique has been compared with surgery in a multicenter randomized trial of patients with moderate or severe MR (EVEREST II).⁵² Preliminary results showed that the MitraClip group had worse outcomes than the surgical group, with lower clinical success rates (72.4% v 87.8%, $p < 0.01$) and a lower composite endpoint (eg, survival, freedom from mitral surgery, or more-than-mild MR at 1 year).⁵³ These disappointing results will generate interest in alternative mitral valve techniques, such as stented mitral valves for minimally invasive implantation.⁵⁴ Although there are no trials comparing the MitraClip system with medical management of heart failure associated with severe MR, a retrospective series reported procedural success rates of 94%, 6-month survival rates of 81%, and a reduction in MR from grade 3+ to $\leq 2+$ in all patients.⁵⁵

The MitraClip procedure poses fewer perioperative risks than TAVI procedures because it is a venous access procedure and cardiac standstill is not required for device deployment. However, invasive monitoring is prudent because hemodynamic instability still can occur in high-risk patients (eg, because of arrhythmia or pericardial tamponade).

Collectively, transcatheter cardiac valve procedures will almost certainly increase as the technology develops and the indications for their use become more clearly defined. These procedures ideally should be managed by a multidisciplinary team and performed in a hybrid operating room.

AORTIC COARCTATION AND PULMONARY ARTERY STENTING

Coarctation of the aorta represents approximately 5% to 10% of CHD cases and is associated with poor long-term survival if untreated. In a prospective, multicenter CHD intervention registry of 351 stent procedures performed in 302 patients (55% primary and 45% recurrent coarctations), the short-term procedural success rate was 96%, declining to 77% at 18 months.⁵⁶ Acute complications included stent malposition and unplanned repeat interventions in 4% of cases. Hypertension persisted in almost 25% of patients. Rapid ventricular pacing was used in 22% of cases to prevent stent movement during deployment, and intravenous adenosine also was used for this indication. General anesthesia was used in most cases, with invasive blood pressure monitoring in the right arm. Because of the potential for aortic dissection or rupture, rapid transfusion facilities and cardiac surgical backup should be available immediately. In one patient, carotid artery dissection caused by guidewire trauma presented as Horner syndrome after the procedure.⁵⁷ Delayed arterial complications such as stent migration and pseudoaneurysm also have been reported.⁵⁸

In addition to pulmonary valve replacement (see earlier), stenting of the right ventricular-to-pulmonary artery conduit may be used to prolong conduit lifespan.⁵⁹ Endovascular stents also have been used in cases of pulmonary arterial compression caused by tumor⁶⁰ or after lung transplantation. Coronary arterial compression has been reported during stenting of a right pulmonary arterial conduit.⁶¹ In a patient with 1 lung, extracorporeal circulatory support was used during pulmonary artery stenting.⁶²

THE USE OF ASSIST DEVICES FOR PCI

Anesthesia support for PCI may be required emergently (eg, because of hemodynamic instability caused by acute ischemia) or electively in patients with major comorbidities or poor cardiac functional reserve or for high-risk procedures. Stenting of the left main coronary artery is a particularly high-risk PCI. This can produce periods of severe myocardial ischemia and left ventricular dysfunction. Patients can be hemodynamically supported during these procedures by the use of left ventricular assist devices, such as the Impella device (Abiomed Inc, Danvers, MA), the Tandem Heart (CardiacAssist, Inc, Pittsburgh, PA) or venoarterial extracorporeal membrane oxygenation.

The Impella device is a catheter-mounted pump that is deployed retrogradely into the left ventricle (LV) via the femoral artery. Blood is aspirated from the LV via an Impeller rotor within the catheter and ejected into the ascending aorta at up to 2.5 L/min (percutaneous version) or 5 L/min (open insertion version). The Tandem Heart device is a catheter-mounted centrifugal pump. The inflow is positioned in the LA via the interatrial septum, with outflow to the femoral artery. In a recent single-center comparison, the Impella and Tandem Heart left ventricular assist devices were associated with similar outcomes and rates of major vascular complications (7%).⁶³ Venoarterial extracorporeal membrane oxygenation also has been used successfully to support patients undergoing high-risk PCI procedures.⁶⁴ The anesthetic considerations for PCI procedures are outlined in the section on remote locations.

PACEMAKERS, IMPLANTABLE CARDIAC DEFIBRILLATORS, AND BIVENTRICULAR PACEMAKERS

Electrical device implantation commonly is performed under local anesthesia in cardiac catheterization laboratories. Anesthetic support for these cases may be required for more complex cases because of patient comorbidities or procedural difficulties.⁶⁵

ICD Implantation

The indications for ICDs are broad and include patients at risk of sudden cardiac death because of ischemic or nonischemic dilated cardiomyopathy, inherited arrhythmia syndromes, hypertrophic cardiomyopathy, long QT syndrome, and syncope with inducible sustained ventricular tachycardia.⁶⁶ The technique for ICD insertion is the same as for pacemakers, but the leads and pulse generators are larger.

The decision to perform these cases under general anesthesia or sedation will depend on patient comorbidities and the expected duration of the procedure. Invasive arterial pressure monitoring is routine in patients with poor ventricular function for hemodynamic monitoring during defibrillation. External defibrillator pads must be placed before ICD testing in the event of device failure. TEE sometimes is used to exclude intracardiac thrombus before testing. Diligent attention to infection prophylaxis is important because infected devices usually require removal and replacement.

Biventricular Pacemaker Implantation

There is increasing evidence that cardiac resynchronization therapy (CRT) improves heart failure symptoms and reduces mortality in patients with broad QRS complexes, impaired ejection fractions, and class III or IV NYHA heart failure symptoms.⁶⁶ Patients with NYHA class I and II symptoms also may benefit.⁶⁷

CRT involves the placement of biventricular pacemaker leads that are adjusted to optimize intraventricular conduction. Most CRT devices also function as ICDs. CRT device insertion usually is performed under general anesthesia, with invasive arterial pressure monitoring. The leads may be placed de novo or as an upgrade to a previously implanted right ventricular pacemaker. The LV pacing lead can be attached to the epicardium during cardiac surgery or percutaneously via the coronary sinus to pace the lateral wall of the LV. Coronary sinus lead placement can be technically challenging and prolonged and can be complicated by cardiac perforation or arrhythmias. Preoperative computed tomography scanning of the coronary sinus may aid planning of these cases.⁶⁸ TEE also can be useful in guiding the placement of the coronary sinus lead.⁶⁹

Device and Lead Removal

The most common indications for lead removal are infection and dysfunction (eg, because of lead fracture).⁷⁰⁻⁷² Other indications are device upgrade or myocardial perforation. Lead removal can be technically difficult and may cause major complications, including cardiac tamponade, vascular avulsion, valvular damage, hemothorax, pneumothorax, and thromboembolism. Leads less than 12 months old usually can be removed by simple traction.⁷³ Beyond this time, they can become fixed

to the myocardium and at other locations such as the right atrium or superior vena cava. This latter group requires more sophisticated extraction techniques.

Laser sheath removal has been available since 2000. A sheath containing a small excimer laser (using ultraviolet light) at its tip is advanced over the lead. The laser is used in short bursts to divide adherent fibrotic tissue, enabling progressive release of the lead and removal within the sheath. In the PLEXES trial, the laser sheath technique was more successful than nonlaser methods (94% v 64%, $p = 0.001$).⁷¹ Major complications occurred in 1.2% of cases in the laser group (including 1 death) and in none of the nonlaser group. Comparable success rates with laser sheath extraction were shown in a large retrospective series.⁷⁴ In a prospective series of 200 patients undergoing the laser technique, the only independent predictor of acute complications appeared to be lead extraction from both the left and right sides during the same procedure.⁷⁵

Occasionally, it may be necessary to extract a lead via the femoral vein if it is broken or not accessible via the subclavian vein. This may be performed with a sheath and snare or basket. Femoral extraction appears to be as effective and safe as the laser sheath method but exposes the patient to more fluoroscopy because of longer procedural times.⁷²

Finally, another extraction technique is incremental mechanical dilatation of the vein combined with traction along the course of the lead via multiple venous approaches. This was found to be highly effective (98.4%) and safe (0.7% major morbidity) in 1 large series.⁷⁶ In view of the potential for significant complications in these cases, the North American Society of Pacing and Electrophysiology recommends that immediate support for thoracotomy, pericardiocentesis, and on-site cardiac surgical support be available.⁷⁷ Whether or not these procedures are performed in an operating room, the presence of a cardiac surgeon and immediate availability of cardiopulmonary bypass are vital.⁷⁸ Large-bore venous access is essential, and lower-limb cannulation should be considered in case of superior vena cava rupture. Cross-matched blood should be readily available.

Device Infection

Cardiac device infections complicate about 1% of cases, and, of these, 40% present after 3 months. Risk factors for infection include renal failure, chronic steroid or anticoagulant use, surgical hematoma formation, and diabetes mellitus. Other risk factors for infection include pacemaker replacement surgery and multiple lead insertions.⁷⁹ The American Heart Association has highlighted that staphylococcal infections account for most device infections and emphasized the requirement for routine antibiotic prophylaxis for all device implants.⁸⁰ This should be administered intravenously 1 hour before incision if using a first-generation cephalosporin or 90 to 120 minutes before incision if using vancomycin.

EP PROCEDURES

The demand for cardiac EP procedures is increasing, as is the range of procedures performed. Although diagnostic studies may be performed in isolation, they are almost always combined with therapeutic ablations if treatable aberrant conduct-

ing pathways are identified. Ablation creates an endocardial scar, which can be produced by RF energy, cryotherapy, or high-intensity focused ultrasound. Ablation procedures can be classified by the level of complexity or by the location (eg, supraventricular tracts, AV node, ventricular re-entrant pathways, and pulmonary vein isolation [PVI] procedures).

Noncomplex Catheter Ablations

Noncomplex ablations include procedures for AV nodal re-entry tachyarrhythmias, atrial flutter, and tachycardia mediated by accessory pathways, such as Wolff-Parkinson-White (WPW) syndrome. Ablation catheters are deployed under fluoroscopic guidance via large peripheral veins (usually the femoral vein). These procedures commonly are performed under sedation and generally take less than 2 hours to perform.

Complex Catheter Ablations

Complex catheter ablations are performed for AF and for tachyarrhythmias because of ventricular foci, multiple foci, or CHD. Electro-anatomic mapping systems using previously acquired 3D computed tomography scanning or magnetic resonance imaging reconstructions of the heart and thoracic vessels commonly are used to guide these procedures. These systems provide a 3D representation of the cardiac chambers and catheters as well as displaying the cardiac electrical activation timing.⁸¹

Diligent attention to the volume of fluid administered by the cardiology team is important because this may amount to several liters during the procedure; hence, a urinary catheter should be placed. Hypothermia can occur during these long procedures, particularly in elderly patients, so the use of forced air warming devices also is recommended.

These patients should receive heparin to prevent catheter thrombosis and thromboembolic stroke, particularly when transarterial or transeptal catheters are used. Clear delineation of the responsibility for the management of anticoagulation must occur. The target ACT range for these cases is based on the PCI guidelines.

Complex ablations may produce prolonged periods of induced or persisting tachyarrhythmia. Hemodynamic instability is a particular concern in patients with pre-existing ventricular dysfunction or CHD. Hypotension may be tolerated poorly in patients with coronary artery disease, carotid artery stenoses, or chronic hypertension. Acute elevations in PVR (eg, because of hypercapnia, hypoxemia, or acidosis) are tolerated poorly in patients with severe pulmonary hypertension or passive pulmonary circulations. Therefore, external pads should be placed for defibrillation or external pacing.

Reactive pericardial collections occur in up to 33% of patients undergoing extensive left atrial ablations.⁸² Therefore, it is important to remain alert to the risk of cardiac tamponade in these patients. TEE is useful for the early detection of this complication, which is more likely if multiple, extensive ablations are performed. The recognition of tamponade may otherwise be delayed if hypotension is attributed to poor underlying ventricular function. Facilities for pericardiocentesis or surgical drainage should be readily available. Ablations near the coronary sinus and coronary arteries may be complicated by acute occlusion of these vessels, especially in patients with aberrant

coronary arterial anatomy. This rare complication should be considered if unexplained hemodynamic deterioration occurs.

PVI

PVI is a treatment for AF and involves the creation of an electrically isolated band between the junction of the pulmonary veins and the right atrium. It is performed with RF energy or cryotherapy using an epicardial or endocardial approach. In a large retrospective series, the success rate for PVI was 80% overall (after 1.3 procedures) and was higher for paroxysmal AF (83%) than AF of intermediate or chronic duration (72% and 75%, respectively; $p < 0.0001$).⁸³ Major complications occurred in 4.5% of cases, including pericardial tamponade (1.3%), femoral pseudoaneurysm (1.0%), TIA (0.71%), and stroke (0.23%).

The rate of cerebral embolism varied between PVI techniques in a small transcranial Doppler study.⁸⁴ The microembolic load was significantly higher with conventional RF ablation catheters than with irrigated RF catheters or cryoablation balloons. However, the recently developed thoracoscopic approach had a much lower incidence of microembolism than any of the endocardial techniques.

Esophageal perforation may complicate RF PVI because of thermal injury to the esophagus, especially after ablation of left-sided pulmonary veins (due to their posterior location). This should be suspected if a pericardial effusion develops within the oblique sinus (between the right atrium and esophagus) or if a pneumopericardium occurs.⁸⁵ Esophageal mucosal lesions were reported in 14% of cases in which a robotic navigation system was used.⁸⁶ In this study, the risk of injury was greater in patients with a body mass index below 57.8 lb/m² although spontaneous recovery occurred within 2 weeks in all patients. Therefore, esophageal temperature probes should be used in these cases and should be positioned behind the LA with fluoroscopic guidance.

Because of their close anatomic relationship, right superior pulmonary vein (RSPV) ablation may be complicated by injury to the right phrenic nerve.⁸⁷ Balloon ablation techniques, which produce a circumferential scar at the orifice of the pulmonary vein, may increase the risk of this complication irrespective of the energy source used. This is because inflation of the balloon brings the pulmonary vein closer to the phrenic nerve.⁸⁸ Intermittent phrenic nerve stimulation may be performed to monitor for this complication. Deep neuromuscular blockade should be avoided if phrenic nerve monitoring is used.

During PVI procedures, acute increases in heart rate and heart rate variability may occur, especially during ablation at the LA/RSPV junction. Conversely, bradycardia and hypotension may occur because of vagal reflexes. Vagal responses are more common during ablation of left pulmonary veins, especially the inferior pulmonary vein, whereas heart rate acceleration typically occurs while ablating near the RSPV.⁸⁹

INTERVENTIONAL PROCEDURES AND CHD

The number of adult survivors of pediatric congenital heart surgery is increasing.⁹⁰ Although the leading cause of death in patients with congenital cyanotic heart disease is arrhythmia followed by heart failure, in noncyanotic patients it is now

ischemic heart disease.⁹¹ Right-heart catheter studies frequently are indicated in these patients to define the anatomy of previous corrective procedures, to determine the direction and size of shunts, and to assess the reversibility of pulmonary hypertension. These patients also may present for coronary angiography or EP procedures for the management of arrhythmias.

These patients present a number of anesthetic challenges. Careful preoperative assessment is essential to determine the presence and severity of heart failure and cyanosis. Consultation with the attending cardiologist regarding the procedural aims may aid in anesthetic planning in patients with complex cardiac anatomy. Preoperative evaluation of noncardiac comorbidities is important (such as cervical spine instability in trisomy 21) together with correct timing of antibiotic prophylaxis.

In patients with right-to-left shunts, it is important to avoid increasing PVR and decreasing system vascular resistance (SVR) because this will increase shunt flow and worsen cyanosis. Systemic vasodilatation, hypercarbia, and high ventilating pressures must be avoided. Volatile anesthetics should be titrated carefully and SVR maintained with vasopressors if required. In patients with systemic-to-pulmonary shunts, decreased SVR and increased PVR should be avoided because this will decrease pulmonary blood flow.

Right-to-left shunting also will affect end-tidal CO₂ measurement; the arterial-to-alveolar pCO₂ gradient increases as shunting worsens.⁹² The direct measurement of arterial CO₂ will be more accurate than end-tidal CO₂ monitoring in patients who are at risk of elevated PVR because of hypercarbia.

Acute elevations in PVR caused by high positive airway pressures may be tolerated poorly in patients with passive venoatrial pulmonary circulations.⁹³ In these patients, the driving pressure gradient providing pulmonary blood flow is the central venous pressure (rather than mean pulmonary artery pressure) minus left atrial pressure. If positive-pressure ventilation is used, the inspiratory time and pressure should be titrated to the lowest level that will maintain normocarbia at the lowest mean airway pressures.⁹⁴ Spontaneous ventilation, with inspiratory pressure support if required, may be used as an alternative to positive-pressure ventilation to minimize ventilating pressure, provided that normocarbia is strictly maintained.

The venous anatomy should be considered when placing central catheters. In a Fontan circulation, caution should be exercised when administering drugs that may be thrombogenic, such as calcium, because the SVC is connected directly to the pulmonary artery. Arterial pressure monitoring in the presence of arterial shunts (such as the Blalock-Taussig shunts or variants) should be performed on the contralateral side to avoid under-reading systemic pressures. Venous access can be difficult in these patients because they have often had multiple, prolonged hospitalizations. Finally, thromboprophylaxis should be considered in patients with high hematocrits because of cyanotic heart disease.

ANESTHETIC ISSUES

Sedation in Contrast to General Anesthesia

Most cardiac catheter procedures can be performed under sedation although general anesthesia may be preferable for

longer cases or in patients with major comorbidities. In a study from the Mayo Clinic of 208 patients undergoing a variety of EP ablations, sedation was planned in 90% of cases. However, some form of airway device was required in 40% of patients, and the rate of conversion to general anesthesia was 10%.⁹⁵

For atrial ablation procedures, minimizing patient movement and respiratory motion (which can be significant with a partially obstructed airway in sedated patients) is especially important when 3D guidance systems are used.⁹⁶ Although carefully titrated sedation can be used for these procedures, general anesthesia with endotracheal intubation may be preferable because of their long duration, patient comorbidities, or the use of TEE. In a recent prospective, randomized trial of general anesthesia with endotracheal intubation versus sedation for patients undergoing PVI, the general anesthesia group had a higher procedural success rate (88% v 69%, $p < 0.001$) and shorter total duration and fluoroscopy times.⁹⁷ The authors suggested that these differences might be caused by better control of movement and respiration in the general anesthesia group.

General anesthesia with spontaneous ventilation via a laryngeal mask airway also can provide excellent procedural conditions. When intermittent respiratory pauses are required to reduce movement of the heart, a low dose of muscle relaxant (such as cisatracurium) and gentle controlled ventilation may be used.

Choice of Anesthetic

The ideal anesthetic for EP procedures would not affect intrinsic pacemaker function, impulse propagation, refractoriness, or autonomic tone although most anesthetic agents have some effect on cardiac conduction.⁹⁸ Despite anecdotal preferences and published opinion, there are little data on the effects of anesthetic agents on cardiac conducting pathways relevant to EP procedures.

Volatile Anesthetics

In dogs, halothane (but not sevoflurane or isoflurane) at 1 to 2 minimum alveolar concentration prolongs AV conduction parameters.⁹⁹ Volatile anesthetics, including sevoflurane, have been shown to prolong QT intervals,¹⁰⁰ and in vitro data show that volatile anesthetics increase the action potential duration in cloned human cells.¹⁰¹ However, the clinical significance of these findings is unknown. In 15 adults undergoing WPW ablation, sevoflurane did not affect SA and AV nodal function or accessory pathway conduction.¹⁰² However, there is a case report of a patient who had an increase in accessory pathway refractory period during general anesthesia with sevoflurane but not with propofol.¹⁰³ Although the clinical significance of these findings is uncertain, it may be prudent to avoid volatile anesthetics in patients with prolonged QT intervals who are undergoing EP procedures.

Intravenous Anesthetics

QTc may be increased by barbiturates and decreased by propofol; however, neither agent increases QTc dispersion (which could theoretically increase susceptibility to ventricular arrhythmias).¹⁰⁴ In a small series of adult WPW patients,

propofol had no clinically significant effect on SA node function or on AV or accessory pathway conduction.¹⁰⁵ Opioids may attenuate increases in heart rate by increasing parasympathetic tone. They do not affect the QT interval. In pigs, remifentanyl depresses SA node function and AV conduction parameters, which may explain the bradycardia it produces in humans.¹⁰⁶ Remifentanyl does not affect intra-atrial, AV conduction or QT intervals.

In the absence of clinical evidence regarding the choice of anesthetic, the authors' preference is the use of a target-controlled propofol infusion, combined with an opioid, such as low-dose alfentanil. Deeper sedation should be provided for periods of RF ablation (which can cause pericardial pain), cardioversions, and the insertion of catheters.

Prolonged, high-dose infusions of propofol can be complicated by propofol infusion syndrome (PRIS).¹⁰⁷ This can present with 1 or more of the following: metabolic acidosis, cardiac failure, Brugada-like electrocardiogram changes (right bundle-branch pattern and ST-segment elevation in right precordial leads), ventricular tachycardia or fibrillation, rhabdomyolysis, and renal failure. The pathophysiology of PRIS is poorly understood but may be related to the inhibition of free fatty acid oxidation and the mitochondrial electron transport chain. Although severe PRIS is uncommon, occurring in approximately 1% of high-risk patients,¹⁰⁸ it is possible that an early subclinical form of PRIS may cause metabolic acidosis alone. This was shown in a retrospective, cohort analysis of AF ablation cases.¹⁰⁹ The average duration of propofol infusion was 7 hours, and cumulative dosages were 20 mg/kg. Metabolic acidosis (defined as a base excess ≤ -2) occurred in 24% of patients, which was higher than a matched cohort of patients undergoing carotid endarterectomy under general anesthesia without propofol. However, this finding was not replicated in a retrospective study of patients undergoing prolonged spinal surgery.¹¹⁰ Further trials are needed on the anesthetic implications of PRIS.

Dexmedetomidine Sedation

Dexmedetomidine is a potentially attractive alternative or adjunct to conventional combinations of fentanyl and midazolam.¹¹¹ In a recent prospective trial of 326 patients undergoing a variety of surgical procedures, dexmedetomidine (0.5 $\mu\text{g}/\text{kg}$, 1.0 $\mu\text{g}/\text{kg}$, or placebo loading dose followed by an infusion) caused less respiratory depression (3.7% and 2.3% v 12.7%, respectively; $p = 0.018$).¹¹² It also significantly reduced the requirement for supplemental midazolam and fentanyl and improved patient satisfaction scores.

The most frequent side effect of dexmedetomidine was hypotension, defined as a 30% or greater decline from baseline, which was significantly increased in the 0.5 $\mu\text{g}/\text{kg}$ group compared with placebo (11.9% v 3.2%, $p = 0.046$). Bradycardia requiring treatment, defined as a 30% or greater decline from baseline, occurred in 0.7% and 4.7% of the treatment groups compared with none in the placebo arm although this did not reach statistical significance ($p > 0.08$).

In children, dexmedetomidine inhibits SA and AV node function as well as increasing the PR interval and Wenckebach cycle length.¹¹³ Dexmedetomidine has not been studied in adult EP

cases; however, theoretically, it may inhibit the induction of tachyarrhythmias during EP procedures because of the inhibition of cardiac conduction via centrally mediated reductions in circulating catecholamines and cardiac α -2A-adrenergic receptor activation.¹¹³ Dexmedetomidine sedation can be guided using the Observer Assessment of Alertness Scale or by quantitative electroencephalographic parameters (such as bispectral index or state entropy^{114,115}). Dexmedetomidine produces lower bispectral index scores for a given Observer Assessment of Alertness Scale score than propofol.¹¹⁴

Inotropes

Isoproterenol often is used during EP procedure to simulate sympathetically mediated activation of tachyarrhythmias during mapping and pathway ablations. Isoproterenol may increase anesthetic requirements. This possibly is mediated via a central pharmacodynamic effect or via hemodynamically mediated effects on the pharmacokinetics of propofol.¹¹⁶ Potentially this could lead to awareness or movement; hence, titration of anesthesia with BIS or entropy guidance may be helpful.

Paradoxically, isoproterenol can cause bradycardia in a minority of patients (7%). This effect has been postulated to be secondary to increased vagal tone from beta-adrenergic stimulation.¹¹⁷ Similarly, atropine-responsive bradycardia also has been observed during dobutamine stress testing. Patients with impaired LV function, coronary artery disease, or adult CHD may tolerate diastolic hypotension poorly because of reduced coronary blood flow. The use of phenylephrine or metaraminol before the induction of tachyarrhythmias may attenuate the subsequent fall in cardiac output and arterial pressure.

Ionizing Radiation Exposure

Ionizing radiation in the cardiac catheter and EP laboratories is a hazard to both patients and staff. Cancer and genetic injury are unpredictable side effects of ionizing radiation because there is no known safe lower limit of exposure.¹¹⁸ In contrast, nonmutagenic radiation injury only occurs above a threshold level, above which it becomes dose dependent. This includes somatic effects, such as cataracts, erythema, and desquamation.

There are case reports of patients suffering radiation burns from prolonged procedures, especially when close to the x-ray source.¹¹⁹ The reported incidence of cutaneous radiation injury of <0.01% may be an underestimate because it frequently is unrecognized or misdiagnosed.¹²⁰

The traditional unit of radiation dose absorbed by any material is the radiation-absorbed dose (rad = gray [Gy] in SI-derived units).¹¹⁸ The SI-derived unit of radiation, the sievert (Sv), quantifies the biologic effect of ionizing radiation. Sv dose limits are expressed as the equivalent dose (for the dose absorbed in a particular tissue or organ) and the effective dose (for the total weighted sum of an equivalent dose across the entire body). Normal annual background radiation exposure is about 0.5 mSv/y. The occupational limits are based on the International Commission on Radiological Protection guidelines.¹²¹ In the European Union, this is an effective dose limit of 20 mSv/y (averaged over 5 years), with an annual maximum limit of 50 mSv. In the United States, the annual occupational limit is 50 mSv, and the lifetime limit is 10 mSv multiplied by

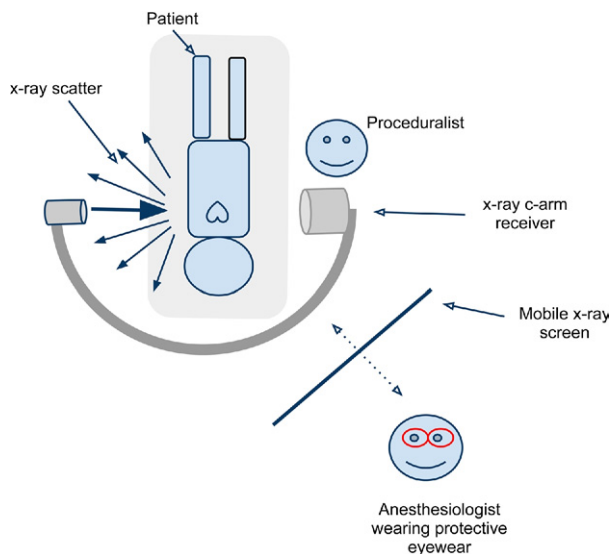


Fig 7. Optimizing the position of the anesthesiologist to minimize radiation exposure in the cardiac catheter and EP laboratories. (Color version of figure is available online.)

age in years.¹²² Most cardiac catheter studies report dose exposure well below these limits, in the range of 2 to 4 mSv/y.¹²² In a study of occupational exposure in anesthesia personnel, mean radiation exposure doubled after commencing work in an EP Laboratory but still remained well below the annualized recommended dose limits.¹²³ The maximum dose recorded in this study was an annualized dose of 3.6 mSv, but most staff received doses below 1.6 mSv/y.

There are 3 principles that should be applied to protect staff from radiation: maximize distance from the radiation source, limit the exposure time, and use adequate radiation protection. First, the intensity of radiation is proportional to the square root of distance, hence doubling the distance from the source will reduce the exposure by a factor of 4. The establishment of a remote anesthetic monitor in the control room will limit radiation exposure to anesthesia staff by increasing the distance from the source. Second, limiting exposure time for all staff is important. Although the duration of imaging is under the control of the proceduralist, asking the proceduralist to cease imaging when physical attendance to the patient is required will help limit occupational exposure. Third, protective radiation barriers must be used. Lead aprons and thyroid shields must be worn in the laboratory; however, they do not provide total body coverage, and they do not provide complete protection from radiation scatter. Because staff should never be in the direct line of the x-ray beam, most exposure to radiation occurs because of scatter. Most of the scattered radiation comes from the surface of the patient nearest the x-ray source. To minimize this exposure, it is advisable to remain on the receiver side of the x-ray arm. This means that when horizontal views are used, staff should, if possible, remain on the image intensifier side of the arm (Fig 7). When vertical planes are used, the x-ray source should be below the patient so that most scattered radiation will be reflected onto the floor.¹²¹ Mobile shields on rollers provide

excellent radiation protection and should be available in these locations.

The current recommended annual equivalent dose limit for eyes is 150 mSv/y.¹²² Protective lead eyewear routinely is recommended for interventional radiologists and cardiologists but is not yet recommended for anesthesia staff. This is despite significant ocular radiation exposure in anesthesiologists during neurointerventional procedures.¹²⁴ Given that anesthesiologists who regularly work in cardiac catheter laboratories might be exposed to similar levels of radiation, the use of protective eyewear would be prudent.

The guiding principle for radiation exposure is the ALARA principle (ie, As Low As Reasonably Achievable). Minimizing exposure time, maximizing distance from the x-ray source and scatter, the use of shields, the monitoring of personal exposure through dosimeter use, and education and training should guide anesthesia practice in these procedural areas.¹²² The International Atomic Energy Agency provides online information and training material on radiation protection for medical personnel (available at <https://rpop.iaea.org/RPOP>).

Remote Locations

Cardiology catheter laboratories typically are remote from general operating room complexes, so it is important to anticipate potential complications and be aware of available resources. For example, TAVI cases may be complicated by major, unexpected bleeding, but blood gas analysis or blood storage may not be readily available. If there is no hybrid operating room available for these cases, the practicalities of urgently transferring these patients to an operating room if cardiac surgery is required also need to be considered.

CONCLUSIONS

As the scope and complexity of interventional cardiology procedures continue to advance, anesthesiologists are assuming an increasingly important role in the multidisciplinary management of these cases. A comprehensive understanding of these procedures is essential to provide a high level of anesthetic care and maintain patient safety.

REFERENCES

- O'Gara PT, Messe SR, Tuzcu EM, et al: Percutaneous device closure of patent foramen ovale for secondary stroke prevention: A call for completion of randomized clinical trials: A science advisory from the American Heart Association/American Stroke Association and the American College of Cardiology Foundation. *Circulation* 119:2743-2747, 2009
- Overell JR, Bone I, Lees KR: Interatrial septal abnormalities and stroke: A meta-analysis of case-control studies. *Neurology* 55:1172-1179, 2000
- Windecker S, Wahl A, Nedeltchev K, et al: Comparison of medical treatment with percutaneous closure of patent foramen ovale in patients with cryptogenic stroke. *J Am Coll Cardiol* 44:750-758, 2004
- Di Tullio MR, Sacco RL, Sciacca RR, et al: Patent foramen ovale and the risk of ischemic stroke in a multiethnic population. *J Am Coll Cardiol* 49:797-802, 2007
- Butera G, Biondi-Zoccai GG, Carminati M, et al: Systematic review and meta-analysis of currently available clinical evidence on migraine and patent foramen ovale percutaneous closure: Much ado about nothing? *Catheter Cardiovasc Interv* 75:494-504, 2010
- Dowson A, Mullen MJ, Peatfield R, et al: Migraine Intervention with STARFlex Technology (MIst) trial: A prospective, multicenter, double-blind, sham-controlled trial to evaluate the effectiveness of patent foramen ovale closure with STARFlex septal repair implant to resolve refractory migraine headache. *Circulation* 117:1397-1404, 2008
- Kaplan S: Congenital heart disease in adolescents and adults. Natural and postoperative history across age groups. *Cardiol Clin* 11:543-556, 1993
- Warnes CA, Williams RG, Thomas M, et al: ACC/AHA 2008 guidelines for the management of adults with congenital heart disease: A report of the American College of Cardiology/American Heart Association Task Force on Practice Guidelines (Writing Committee to Develop Guidelines on the Management of Adults with Congenital Heart Disease). Developed in Collaboration with the American Society of Echocardiography, Heart Rhythm Society, International Society for Adult Congenital Heart Disease, Society for Cardiovascular Angiography and Interventions, and Society of Thoracic Surgeons. *J Am Coll Cardiol* 52:e1-121, 2008
- Humenberger M, Rosenhek R, Gabriel H, et al: Benefit of atrial septal defect closure in adults: Impact of age. *Eur Heart J* 32:553-560, 2011
- Du ZD, Hijazi ZM, Kleinman CS, et al: Comparison between transcatheter and surgical closure of secundum atrial septal defect in children and adults: Results of a multicenter nonrandomized trial. *J Am Coll Cardiol* 39:1836-1844, 2002
- Johri AM, Witzke C, Solis J, et al: Real-time three-dimensional transesophageal echocardiography in patients with secundum atrial septal defects: Outcomes following transcatheter closure. *J Am Soc Echocardiogr* 24:431-437, 2011
- Ponnuthurai FA, van Gall WJ, Mitchell A, et al: Safety and feasibility of day case patent foramen ovale (PFO) closure facilitated by intracardiac echocardiography. *Int J Cardiol* 131:438-440, 2009
- Du ZD, Hijazi ZM, Kleinman CS, et al: Comparison between transcatheter and surgical closure of secundum atrial septal defect in children and adults: Results of a multicenter nonrandomized trial. *J Am Coll Cardiol* 39:1836-1844, 2002
- Bartel T, Konorza T, Arjumand J, et al: Intracardiac echocardiography is superior to conventional monitoring for guiding device closure of interatrial communications. *Circulation* 107:795-797, 2003
- Fischer D, Haentjes J, Klein G, et al: Transcatheter closure of patent foramen ovale (PFO) in patients with paradoxical embolism: Procedural and follow-up results after implantation of the Amplatzer-occluder device. *J Interv Cardiol* 24:85-91, 2011
- Krumsdorf U, Ostermayer S, Billinger K, et al: Incidence and clinical course of thrombus formation on atrial septal defect and patent foramen ovale closure devices in 1,000 consecutive patients. *J Am Coll Cardiol* 43:302-309, 2004
- Furlan AJ, Reisman M, Massaro J, et al: Study design of the CLOSURE I Trial: A prospective, multicenter, randomized, controlled trial to evaluate the safety and efficacy of the STARFlex septal closure system versus best medical therapy in patients with stroke or transient ischemic attack due to presumed paradoxical embolism through a patent foramen ovale. *Stroke* 41:2872-2883, 2010
- Smith SC, Dove JT, Jacobs AK, et al: ACC/AHA guidelines of percutaneous coronary interventions (revision of the 1993 PTCA guidelines)—Executive summary. A report of the American College of Cardiology/American Heart Association Task Force on Practice Guide-

lines (committee to revise the 1993 guidelines for percutaneous transluminal coronary angioplasty). *J Am Coll Cardiol* 37:2215-2239, 2001

19. Amin Z, Hijazi ZM, Bass JL, et al: Erosion of Amplatzer septal occluder device after closure of secundum atrial septal defects: Review of registry of complications and recommendations to minimize future risk. *Catheter Cardiovasc Interv* 63:496-502, 2004

20. Girდაuskas E, Diab M, Secknus MA, et al: Late cardiac perforation after transcatheter closure of patent foramen ovale mimicking acute type A aortic dissection. *Ann Thorac Surg* 89:1649-1651, 2010

21. Di Biase LJ, Burkhardt D, Horton R, et al: Patent foramen ovale closure with a conventional radiofrequency ablation catheter: Early feasibility. *J Am Coll Cardiol* 55:A15.e141, 2010

22. Martinez MW, Mookadam F, Sun Y, et al: Transcatheter closure of ischemic and post-traumatic ventricular septal ruptures. *Catheter Cardiovasc Interv* 69:403-407, 2007

23. Al-Kashkari W, Balan P, Kavinsky CJ, et al: Percutaneous device closure of congenital and iatrogenic ventricular septal defects in adult patients. *Catheter Cardiovasc Interv* 77:260-267, 2011

24. Porstmann W, Wierny L, Warnke H: Closure of ductus arteriosus persistens without thoracotomy. *Radiol Diagn (Berl)* 9:168-169, 1968

25. Grifka RG: Transcatheter closure of the patent ductus arteriosus. *Catheter Cardiovasc Interv* 61:554-570, 2004

26. Yu ML, Huang XM, Wang JF, et al: Safety and efficacy of transcatheter closure of large patent ductus arteriosus in adults with a self-expandable occluder. *Heart Vessels* 24:440-445, 2009

27. Brunetti MA, Ringel R, Owada C, et al: Percutaneous closure of patent ductus arteriosus: A multiinstitutional registry comparing multiple devices. *Catheter Cardiovasc Interv* 76:696-702, 2010

28. Bartel T, Gleich V, Müller S: Device closure of patent ductus arteriosus: Optimal guidance by transaortic phased-array imaging. *Eur J Echocardiogr* 12:E9, 2011

29. Blackshear JL, Odell JA: Appendage obliteration to reduce stroke in cardiac surgical patients with atrial fibrillation. *Ann Thorac Surg* 61:755-759, 1996

30. Holmes DR, Reddy VY, Turi ZG, et al: Percutaneous closure of the left atrial appendage versus warfarin therapy for prevention of stroke in patients with atrial fibrillation: A randomised non-inferiority trial. *Lancet* 374:534-542, 2009

31. Park JW, Bethencourt A, Sievert H, et al: Left atrial appendage closure with Amplatzer cardiac plug in atrial fibrillation: Initial European experience. *Catheter Cardiovasc Interv* 77:700-706, 2011

32. Iung B, Baron G, Butchart EG, et al: A prospective survey of patients with valvular heart disease in Europe: The Euro Heart Survey on valvular heart disease. *Eur Heart J* 24:1231-1243, 2003

33. Cribier A, Eltchaninoff H, Bash A, et al: Percutaneous transcatheter implantation of an aortic valve prosthesis for calcific aortic stenosis: First human case description. *Circulation* 106:3006-3008, 2002

34. Walther T, Dewey T, Borger MA, et al: Transapical aortic valve implantation: Step by step. *Ann Thorac Surg* 87:276-283, 2009

35. Leon, Smith CR, Mack M, et al: Transcatheter aortic-valve implantation for aortic stenosis in patients who cannot undergo surgery. *N Engl J Med* 363:1597-1607, 2010

36. Smith CR, Leon MB, Mack MJ, et al: Transcatheter versus surgical aortic-valve replacement in high-risk patients. *N Engl J Med* 364:2187-2198, 2011

37. Petronio AS, De Carlo M, Bedogni F, et al: Safety and efficacy of the subclavian approach for transcatheter aortic valve implantation with the CoreValve revalving system. *Circ Cardiovasc Interv* 3:359-366, 2010

38. Fassel J, Augoustides JG: Transcatheter aortic valve implantation—Part 1: Development and status of the procedure. *J Cardiothorac Vasc Anesth* 24:498-505, 2010

39. Fassel J, Augoustides JG: Transcatheter aortic valve implantation—Part 2: Anesthesia management. *J Cardiothorac Vasc Anesth* 24:691-699, 2010

40. Billings FT, Kodali SK, Shanewise JS: Transcatheter aortic valve implantation: Anesthetic considerations. *Anesth Analg* 108:1453-1462, 2009

41. Fassel J, Walther T, Groesdonk HV, et al: Anesthesia management for transapical transcatheter aortic valve implantation: A case series. *J Cardiothorac Vasc Anesth* 23:286-291, 2009

42. Bonhoeffer P, Boudjemline Y, Saliba Y, et al: Percutaneous replacement of pulmonary valve in a right-ventricle to pulmonary-artery prosthetic conduit with valve dysfunction. *Lancet* 356:1403-1405, 2000

43. Boone RH, Webb JG, Horlick E, et al: Transcatheter pulmonary valve implantation using the Edwards SAPIEN transcatheter heart valve. *Catheter Cardiovasc Interv* 75:286-294, 2010

44. Nordmeyer J, Lurz P, Tsang VT, et al: Effective transcatheter valve implantation after pulmonary homograft failure: A new perspective on the Ross operation. *J Thorac Cardiovasc Surg* 138:84-88, 2009

45. Zahn EM, Hellenbrand WE, Lock JE, et al: Implantation of the melody transcatheter pulmonary valve in patients with a dysfunctional right ventricular outflow tract conduit. Early results from the US clinical trial. *J Am Coll Cardiol* 54:1722-1729, 2009

46. Bertels RA, Blom NA, Schaliq MJ: Edwards SAPIEN transcatheter heart valve in native pulmonary valve position. *Heart* 96:661, 2010

47. McElhinney DB, Hellenbrand WE, Zahn EM, et al: Short- and medium-term outcomes after transcatheter pulmonary valve placement in the expanded multicenter US melody valve trial. *Circulation* 122:507-516, 2010

48. Webb JG, Wood DA, Ye J, et al: Transcatheter valve-in-valve implantation for failed bioprosthetic heart valves. *Circulation* 121:1848-1857, 2010

49. Lauten A, Ferrari M, Hekmat K, et al: Heterotopic transcatheter tricuspid valve implantation: First-in-man application of a novel approach to tricuspid regurgitation. *Eur Heart J* 32:1207-1213, 2011

50. Piazza N, Asgar A, Ibrahim R, et al: Transcatheter mitral and pulmonary valve therapy. *J Am Coll Cardiol* 53:1837-1851, 2009

51. Fucci C, Sandrelli L, Pardini A, et al: Improved results with mitral valve repair using new surgical techniques. *Eur J Cardiothorac Surg* 9:621-626, 1995

52. Mauri L, Garg P, Massaro JM, et al: The EVEREST II Trial: Design and rationale for a randomized study of the eValve MitraClip system compared with mitral valve surgery for mitral regurgitation. *Am Heart J* 160:23-29, 2010

53. Cleland JG, Coletta AP, Buga L, et al: Clinical trials update from the American College of Cardiology meeting 2010. Dose, Aspire Connect STICH STOP-AF Cabana Race II, EVEREST II, ACCORD, and NAVIGATOR. *Eur J Heart Fail* 12:623-629, 2010

54. Attmann T, Pokorny S, Lozonschi L, et al: Mitral valve stent implantation: An overview. *Minim Invasive Ther Allied Technol* 20:78-84, 2011

55. Franzen O, van der Heyden J, Baldus S, et al: MitraClip(R) therapy in patients with end-stage systolic heart failure. *Eur J Heart Fail* 13:569-576, 2011

56. Holzer R, Qureshi S, Ghasemi A, et al: Stenting of aortic coarctation: Acute, intermediate, and long-term results of a prospective multi-institutional registry—Congenital cardiovascular Interventional Study Consortium (CCISC). *Catheter Cardiovasc Interv* 76:553-563, 2010

57. De Vlieger G, Budts W, Dubois CL: Horner syndrome after stenting of a coarctation of the aorta. *Heart* 96:714, 2010

58. Moltzer E, Roos-Hesselink JW, Yap SC, et al: Endovascular stenting for aortic (re)coarctation in adults. *Neth Heart J* 18:430-436, 2010
59. Peng LF, McElhinney DB, Nugent AW, et al: Endovascular stenting of obstructed right ventricle-to-pulmonary artery conduits: A 15-year experience. *Circulation* 113:2598-2605, 2006
60. Meckel S, Buitrago-Téllez C, Herrmann R, et al: Stenting for pulmonary artery stenosis due to a recurrent primary leiomyosarcoma. *J Endovasc Ther* 10:141-146, 2003
61. Gewillig M, Brown S: Coronary compression caused by stenting a right pulmonary artery conduit. *Catheter Cardiovasc Interv* 74:144-147, 2009
62. Heid F, Guth S, Mayer E, et al: Extracorporeal circulation and cardiac arrest in an awake patient: A safe approach for single lung pulmonary artery stenting? *Ann Thorac Surg* 82:746-747, 2006
63. Kovacic JC, Nguyen HT, Karajikar R, et al: The impella recover 2.5 and TandemHeart ventricular assist devices are safe and associated with equivalent clinical outcomes in patients undergoing high-risk percutaneous coronary intervention. *Catheter Cardiovasc Interv* 2011
64. Spina RS, Forrest AP, Adams MR, et al: Veno-arterial extracorporeal membrane oxygenation for high-risk cardiac catheterisation procedures. *Heart Lung Circ* 19:736-741, 2010
65. Bourke ME, Healey JS: Pacemakers, recent directions and developments. *Curr Opin Anaesthesiol* 15:681-686, 2002
66. Epstein AE, DiMarco JP, Ellenbogen KA, et al. ACC/AHA/HRS: Guidelines for Device-Based Therapy of Cardiac Rhythm Abnormalities: A report of the American College of Cardiology/American Heart Association Task Force on Practice Guidelines (Writing Committee to Revise the ACC/AHA/NASPE 2002 Guideline Update for Implantation of Cardiac Pacemakers and antiarrhythmia Devices). *Circulation* 117:e350-e408, 2008
67. Moss AJ, Hall WJ, Cannom DS, et al: Cardiac-resynchronization therapy for the prevention of heart-failure events. *N Engl J Med* 361:1329-1338, 2009
68. Jongbloed MR, Lamb HJ, Bax JJ, et al: Noninvasive visualization of the cardiac venous system using multislice computed tomography. *J Am Coll Cardiol* 45:749-753, 2005
69. Plotkin IM, Collard CD, Sary F, et al: Percutaneous coronary sinus cannulation guided by transesophageal echocardiography. *Ann Thorac Surg* 66:2085-2087, 1998
70. Kratz JM, Toole JM: Pacemaker and internal cardioverter defibrillator lead extraction: A safe and effective surgical approach. *Ann Thorac Surg* 90:1411-1417, 2010
71. Wilkoff BL, Byrd CL, Love CJ, et al: Pacemaker lead extraction with the laser sheath: Results of the pacing lead extraction with the excimer sheath (PLEXES) trial. *J Am Coll Cardiol* 33:1671-1676, 1999
72. Bordachar P, Defaye P, Peyrouse E, et al: Extraction of old pacemaker or cardioverter-defibrillator leads by laser sheath versus femoral approach. *Circarrhythm J Electrophysiol* 3:319-323, 2010
73. Farooqi FM, Talsania S, Hamid S, et al: Extraction of cardiac rhythm devices: Indications, techniques and outcomes for the removal of pacemaker and defibrillator leads. *Int J Clin Pract* 64:1140-1147, 2010
74. Byrd CL, Wilkoff BL, Love CJ, et al: Intravascular extraction of problematic or infected permanent pacemaker leads: 1994, 1996: U.S. Extraction Database, MED Institute. *Pacing Clin Electrophysiol* 22:1348-1357, 1999
75. Roux JF, Pagé P, Dubuc M, et al: Laser lead extraction: Predictors of success and complications. *Pacing Clin Electrophysiol* 30:214-220, 2007
76. Bongiorno MG, Soldati E, Zucchelli G, et al: Transvenous removal of pacing and implantable cardiac defibrillating leads using single sheath mechanical dilatation and multiple venous approaches: High success rate and safety in more than 2000 leads. *Eur Heart J* 29:2886-2893, 2008
77. Love CJ, Wilkoff BL, Byrd CL, et al: Recommendations for extraction of chronically implanted transvenous pacing and defibrillator leads: Indications, facilities, training. North American Society of Pacing and Electrophysiology Lead Extraction Conference Faculty. *Pacing Clin Electrophysiol* 23:544-551, 2000
78. Maytin M, Epstein LM: The challenges of transvenous lead extraction. *Heart* 97:425-434, 2011
79. Nery PB, Fernandes R, Nair GM, et al: Device-related infection among patients with pacemakers and implantable defibrillators: Incidence, risk factors, and consequences. *J Cardiovasc Electrophysiol* 21:786-790, 2010
80. Baddour LM, Epstein AE, Erickson CC, et al: Update on cardiovascular implantable electronic device infections and their management: A scientific statement from the American Heart Association. *Circulation* 121:458-477, 2010
81. LaPage MJ, Saul JP: Update on rhythm mapping and catheter navigation. *Curr Opin Cardiol* 26:79-85, 2011
82. Kalla M, Rajappan K, Kalra S, et al: Routine transthoracic echocardiography to assess pericardial collections in patients after extensive left atrial catheter ablation: A prospective study. *J Cardiovasc Electrophysiol* 2011 [Epub ahead of print]
83. Cappato R, Calkins H, Chen SA, et al: Updated worldwide survey on the methods, efficacy, and safety of catheter ablation for human atrial fibrillation. *Circarrhythm J Electrophysiol* 3:32-38, 2010
84. Sauren LD, van Belle Y, Roy DE, et al: Transcranial measurement of cerebral microembolic signals during endocardial pulmonary vein isolation: Comparison of three different ablation techniques. *J Cardiovasc Electrophysiol* 20:1102-1107, 2009
85. Macedo PG, Kapa S, Mears JA, et al: Correlative anatomy for the electrophysiologist: Ablation for atrial fibrillation. Part II: Regional anatomy of the atria and relevance to damage of adjacent structures during AF ablation. *J Cardiovasc Electrophysiol* 21:829-836, 2010
86. Rillig A, Meyerfeldt U, Birkemeyer R, et al: Oesophageal temperature monitoring and incidence of oesophageal lesions after pulmonary vein isolation using a remote robotic navigation system. *Europace* 12:655-661, 2010
87. Lachman N, Syed FF, Habib A, et al: Correlative Anatomy for the electrophysiologist, part II: Cardiac Ganglia, phrenic Nerve, Coronary venous System. *J Cardiovasc Electrophysiol* 20:104-110, 2011
88. Okumura Y, Henz BD, Bunch TJ, et al: Distortion of right superior pulmonary vein anatomy by balloon catheters as a contributor to phrenic nerve injury. *J Cardiovasc Electrophysiol* 20:1151-1157, 2009
89. Ketels S, Houben R, Van Beeumen K, et al: Incidence, timing, and characteristics of acute changes in heart rate during ongoing circumferential pulmonary vein isolation. *Europace* 10:1406-1414, 2008
90. Boneva RS, Botto LD, Moore CA, et al: Mortality associated with congenital heart defects in the United States: Trends and racial disparities, 1979-1997. *Circulation* 103:2376-2381, 2001
91. Pillutla P, Shetty KD, Foster E: Mortality associated with adult congenital heart disease: Trends in the US population from 1979 to 2005. *Am Heart J* 158:874-879, 2009
92. Lovell AT: Anaesthetic implications of grown-up congenital heart disease. *Br J Anaesth* 93:129-139, 2004
93. Redington AN, Penny D, Shinebourne EA: Pulmonary blood flow after total cavopulmonary shunt. *Br Heart J* 65:213-217, 1991
94. Bailey PD, Jobs DR: The Fontan patient. *Anesthesiol Clin* 27:285-300, 2009
95. Trentman TL, Fassett SL, Mueller JT, et al: Airway interventions in the cardiac electrophysiology laboratory: A retrospective review. *J Cardiothorac Vasc Anesth* 23:841-845, 2009

96. Klemm HU, Steven D, Johnsen C, et al: Catheter motion during atrial ablation due to the beating heart and respiration: Impact on accuracy and spatial referencing in three-dimensional mapping. *Heart Rhythm* 4:587-592, 2007
97. Di Biase L, Conti S, Mohanty P, et al: General anesthesia reduces the prevalence of pulmonary vein reconnection during repeat ablation when compared with conscious sedation: Results from a randomized study. *Heart Rhythm* 8:368-372, 2011
98. Renwick J, Kerr C, McTaggart R, et al: Cardiac electrophysiology and conduction pathway ablation. *Can J Anaesth* 40:1053-1064, 1993
99. Nakaigawa Y, Akazawa S, Shimizu R, et al: Comparison of the effects of halothane, isoflurane, and sevoflurane on atrioventricular conduction times in pentobarbital-anesthetized dogs. *Anesth Analg* 81:249-253, 1995
100. Viskin S: Long QT syndromes and torsade de pointes. *Lancet* 354:1625-1633, 1999
101. Kang J, Reynolds WP, Chen XL, et al: Mechanisms underlying the QT interval-prolonging effects of sevoflurane and its interactions with other QT-prolonging drugs. *Anesthesiology* 104:1015-1022, 2006
102. Sharpe MD, Cuillerier DJ, Lee JK, et al: Sevoflurane has no effect on sinoatrial node function or on normal atrioventricular and accessory pathway conduction in Wolff-Parkinson-White syndrome during alfentanil/midazolam anesthesia. *Anesthesiology* 90:60-65, 1999
103. Caldwell JC, Fong C, Muhyaldeen SA: Should sevoflurane be used in the electrophysiology assessment of accessory pathways? *Eurpace* 12:1332-1335, 2010
104. Higashijima U, Terao Y, Ichinomiya T, et al: A comparison of the effect on QT interval between thiamylal and propofol during anaesthetic induction. *J Anesth* 65:679-683, 2010
105. Sharpe MD, Dobkowski WB, Murkin JM, et al: Propofol has no direct effect on sinoatrial node function or on normal atrioventricular and accessory pathway conduction in Wolff-Parkinson-White syndrome during alfentanil/midazolam anesthesia. *Anesthesiology* 82:888-895, 1995
106. Caballos M, Jimeno C, Almendral J, et al: Cardiac electrophysiological effects of remifentanyl: Study in a closed-chest porcine model. *Br J Anaesth* 103:191-198, 2009
107. Wong JM: Propofol infusion syndrome. *Am J Ther* 17:487-491, 2010
108. Roberts RJ, Barletta JF, Fong JJ, et al: Incidence of propofol-related infusion syndrome in critically ill adults: A prospective, multicenter study. *Crit Care* 13:R169, 2009
109. Cravens GT, Packer DL, Johnson ME: Incidence of propofol infusion syndrome during noninvasive radiofrequency ablation for atrial flutter or fibrillation. *Anesthesiology* 106:1134-1138, 2007
110. Rozet I, Tontisirin N, Vavilala MS, et al: Prolonged propofol anesthesia is not associated with an increase in blood lactate. *Anesth Analg* 109:1105-1110, 2009
111. Carollo DS, Nossaman BD, Ramadhyani U: Dexmedetomidine: A review of clinical applications. *Curr Opin Anaesthesiol* 21:457-461, 2008
112. Candiotti KA, Bergese SD, Bokesch PM, et al: Monitored anesthesia care with dexmedetomidine: A prospective, randomized, double-blind, multicenter trial. *Anesth Analg* 110:47-56, 2010
113. Hammer GB, Drover DR, Cao H, et al: The effects of dexmedetomidine on cardiac electrophysiology in children. *Anesth Analg* 106:79-83, 2008
114. Kasuya Y, Govinda R, Rauch S, et al: The correlation between bispectral index and observational sedation scale in volunteers sedated with dexmedetomidine and propofol. *Anesth Analg* 109:1811-1815, 2009
115. Maksimow A, Snapir A, Särkelä M, et al: Assessing the depth of dexmedetomidine-induced sedation with electroencephalogram (EEG)-based spectral entropy. *Acta Anaesthesiol Scand* 51:22-30, 2007
116. Andrzejewski J, Sleigh JW, Johnson IA, et al: The effect of intravenous epinephrine on the bispectral index and sedation. *Anaesthesia* 55:761-763, 2000
117. Brembilla-Perrot B, Muhanna I, Nippert M, et al: Paradoxical effect of isoprenaline infusion. *Eurpace* 7:621-627, 2005
118. Limacher MC, Douglas PS, Germano G, et al: ACC expert consensus document. Radiation safety in the practice of cardiology. American College of Cardiology. *J Am Coll Cardiol* 31:892-913, 1998
119. Slovut DP: Cutaneous radiation injury after complex coronary intervention. *JACC Cardiovasc Interv* 2:701-702, 2009
120. Vlietstra RE, Wagner LK, Koenig T, et al: Radiation burns as a severe complication of fluoroscopically guided cardiological interventions. *J Interv Cardiol* 17:131-142, 2004
121. International Commission on Radiological Protection: The 2007 recommendations of the International Commission on Radiological Protection. ICRP Publication, 2007: p 103. *Ann ICRP* 37:1-332
122. Miller DL, Vañó E, Bartal G, et al: Occupational radiation protection in interventional radiology: A joint guideline of the Cardiovascular and Interventional Radiology Society of Europe and the Society of Interventional Radiology. *Cardiovasc Interv Radiol* 33:230-239, 2010
123. Katz JD: Radiation exposure to anesthesia personnel: The impact of an electrophysiology laboratory. *Anesth Analg* 101:1725-1726, 2005
124. Anastasian ZH, Strozyk D, Meyers PM, et al: Radiation exposure of the anesthesiologist in the neurointerventional Suite. *Anesthesiology* 114:512-520, 2011